

MINI-FOCUS ISSUE: AMYLOIDOSIS

STATE-OF-THE-ART REVIEW

AL Amyloidosis for Cardiologists

Awareness, Diagnosis, and Future Prospects:

JACC: CardioOncology State-of-the-Art Review



Ashutosh D. Wechalekar, MBBS, MD, DM,^a Marianna Fontana, MD, PhD,^{a,b} C. Cristina Quarta, MD, PhD,^c
Michaela Liedtke, MD^d

ABSTRACT

Amyloid light chain (AL) amyloidosis is a rare, debilitating, often fatal disease. Symptoms of cardiomyopathy are common presenting features, and patients often are referred to cardiologists. Cardiac amyloid infiltration is the leading predictor of death. However, the variable presentation and perceived rarity of the disease frequently lead to delay in suspecting amyloidosis as a cause of heart failure, leading to misdiagnoses and a marked delay in diagnosis, with devastating consequences for the patient. A median time from symptom onset to correct diagnosis of about 2 years is often too long when median survival from diagnosis for patients with AL amyloidosis and cardiomyopathy is 4 months to 2 years. The authors highlight the challenges to diagnosis, identify gaps in the current knowledge, and summarize novel treatments on the horizon to raise awareness about the critical need for early recognition of symptoms and diagnosis of AL amyloidosis aimed at accelerating treatment and improving outcomes for patients. (J Am Coll Cardiol CardioOnc 2022;4:427-441)
© 2022 The Authors. Published by Elsevier on behalf of the American College of Cardiology Foundation. This is an open access article under the CC BY-NC-ND license (<http://creativecommons.org/licenses/by-nc-nd/4.0/>).

Amyloid light chain (AL) amyloidosis is a rare, severe, progressive, debilitating, systemic disease that is slightly more common in men, with a median age at diagnosis of about 65 years.¹⁻⁴ Median survival depends on the cardiac stage of the disease at diagnosis.⁵ The median survival is nearly 5 years in contemporary cohorts. However, up to 43% of patients may die in the first year.⁶ The median survival of patients with very advanced cardiac disease is only 4 months and is about 2 years among patients with less severe cardiac involvement.⁷ The introduction of new therapeutic agents and regimens and earlier diagnosis have improved overall survival of patients.⁸⁻¹¹ The underlying

etiology of AL amyloidosis is clonal plasma cell expansion (plasma cell dyscrasia [PCD]), producing amyloidogenic immunoglobulin (Ig) light chains that aggregate to form insoluble fibrils, which deposit in tissues and cause organ dysfunction.^{1-4,12,13} In 80% of cases, the amyloidogenic light chain is the λ subtype.¹³ Preclinical studies demonstrated the proteotoxicity of the amyloidogenic light chains, especially in cardiac tissue.^{14,15} The heart is the most commonly involved organ in AL amyloidosis, with >75% of patients exhibiting symptoms of cardiac amyloid infiltration at diagnosis.^{16,17} As shown in **Figure 1**, other common presentations at diagnosis among patients with AL amyloidosis include nephropathy (>60% of

From the ^aNational Amyloidosis Centre, London, United Kingdom; ^bRoyal Free London NHS Foundation Trust, London, United Kingdom; ^cAlexion Pharmaceuticals, AstraZeneca Rare Disease, Boston, Massachusetts, USA; and the ^dStanford Amyloid Center, Stanford University School of Medicine, Stanford, California, USA.

The authors attest they are in compliance with human studies committees and animal welfare regulations of the authors' institutions and Food and Drug Administration guidelines, including patient consent where appropriate. For more information, visit the [Author Center](#).

Manuscript received May 5, 2022; revised manuscript received August 5, 2022, accepted August 9, 2022.

ABBREVIATIONS AND ACRONYMS

AL	= amyloid light chain
ASCT	= autologous stem cell transplantation
ATTR	= transthyretin
CMR	= cardiac magnetic resonance imaging
CR	= complete response
CyBorD	= cyclophosphamide-bortezomib-dexamethasone
FLC	= free light chain
Ig	= immunoglobulin
LGE	= late gadolinium enhancement
NT-proBNP	= N-terminal pro-brain natriuretic peptide
PCD	= plasma cell dyscrasia
QoL	= quality of life
VGPR	= very good partial response

patients), hepatomegaly (>50% of patients), neuropathy (10%-20% of patients), macroglossia (17% of patients), and periorbital purpura (15% of patients).^{2,13,17,18}

Cardiac amyloid infiltration is the leading cause of death, accounting for >61% of fatalities and the primary determinant of survival in patients with AL amyloidosis.^{13,19} Cardiovascular events leading to death include progressive heart failure or arrhythmias, although the exact cause is often unclear.¹⁹ Common cardiovascular complications include atrial or ventricular (less common, but often fatal) arrhythmia, heart failure, embolism, stroke, and conduction delays, including advanced degrees of atrioventricular block. Patients with cardiac involvement experience the greatest impact on all aspects of quality of life (QoL), including physical health, work productivity, and emotional health, which includes depression and role limitation, compared

with patients with involvement of other organs.^{20,21}

Cardiac amyloidosis is often listed as a cause of heart failure with preserved ejection fraction, but this does not fully characterize the functional phenotype that typically shows both systolic and diastolic impairment.^{13,19} In patients with AL amyloidosis, amyloid infiltration results in symmetrical biventricular wall thickening with nondilated or small ventricles. Ejection fraction is typically normal until late disease stage.²² The reduction in systolic function disproportionately affects the longitudinal rather than the radial axes.²² This is much more marked than other causes of thick-walled heart failure, and the reduction in longitudinal strain typically spares the apex, giving the characteristic relatively apical sparing picture (“bull’s-eye pattern”) on parametric longitudinal strain polar maps.²³ Initial infiltration in the left ventricle is characterized by impaired relaxation, which then invariably progresses to typical restrictive physiology. Nonspecific extensively described findings include thickening of the valves and the interatrial septum and a speckled appearance of the myocardium. Pericardial and pleural effusions are relatively common findings.²²

AL amyloidosis is difficult to diagnose because many of the presenting symptoms are not specific to this disease.^{2,12,24,25} Delays in diagnosis and misdiagnoses are common and result in increased symptom burden, cumulative organ damage, poorer prognosis, and higher early mortality.²⁵⁻²⁸ Rapid

HIGHLIGHTS

- There is an acute need for increased awareness of AL amyloidosis.
- Early diagnosis and correct treatment selection are critical in AL management.
- Combined targeted amyloid removal with current therapies may improve outcomes.

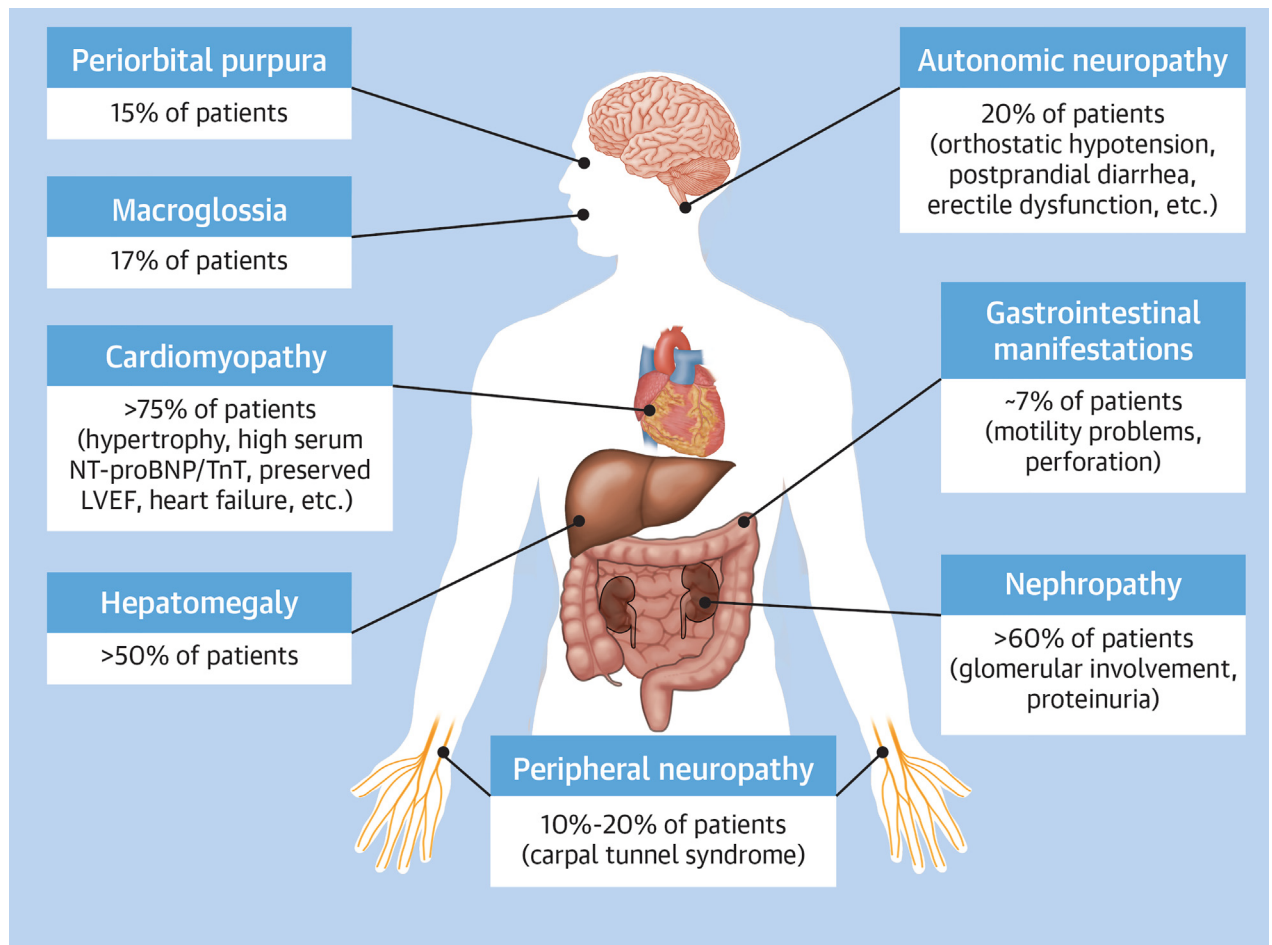
accurate diagnosis within 6 months of symptom onset correlated positively with survival, whereas diagnostic delay (>6 months) correlated with poor survival.¹⁰ Worsening organ damage due to diagnostic delay limits treatment options, such as making patients ineligible for autologous stem cell transplantation (ASCT) or having poorer tolerance to standard-of-care chemotherapy. As many patients present with cardiovascular symptoms or complications, they are often referred to cardiologists by their primary care physicians.^{26,29} A survey of patients and caregivers indicated that about 44% of patients initially were misdiagnosed and treated as having unrelated cardiomyopathy, with 3 of 4 cardiologists surveyed reporting that lack of disease awareness was the most common cause of misdiagnosis.²⁶ Delays in diagnosis can increase the risk for death 3- to 5-fold.³⁰ Thus, it is critical to increase awareness among health care providers to ensure timely diagnosis and improved outcomes.

Previously published state-of-the-art reviews focused on the utility of supportive therapy for cardiac involvement, chemotherapy, or immunotherapy.^{31,32} This review, focusing on cardiac aspects of AL amyloidosis, builds on that foundation, with the aim of improving awareness about suspicion, diagnosis, gaps in treatment and response evaluations, and recent advances in the management of this disease (**Central Illustration**).

DIAGNOSIS

Most of the symptoms and clinical manifestations of AL amyloidosis are nonspecific.^{33,34} Diagnosis of AL amyloidosis is a multistep process (**Figure 2**).^{25,35} The first step is suspicion of amyloidosis, which initiates specific diagnostic tests to verify the diagnosis.^{25,35} This is followed by tests to identify the amyloid fibril type, which is critical to differentiate AL amyloidosis from other subtypes.^{25,35} The final step of diagnosis is to identify the organs involved and the extent to which they are affected by the deposition of

FIGURE 1 Common Pathologies Among Patients With Amyloid Light Chain Amyloidosis

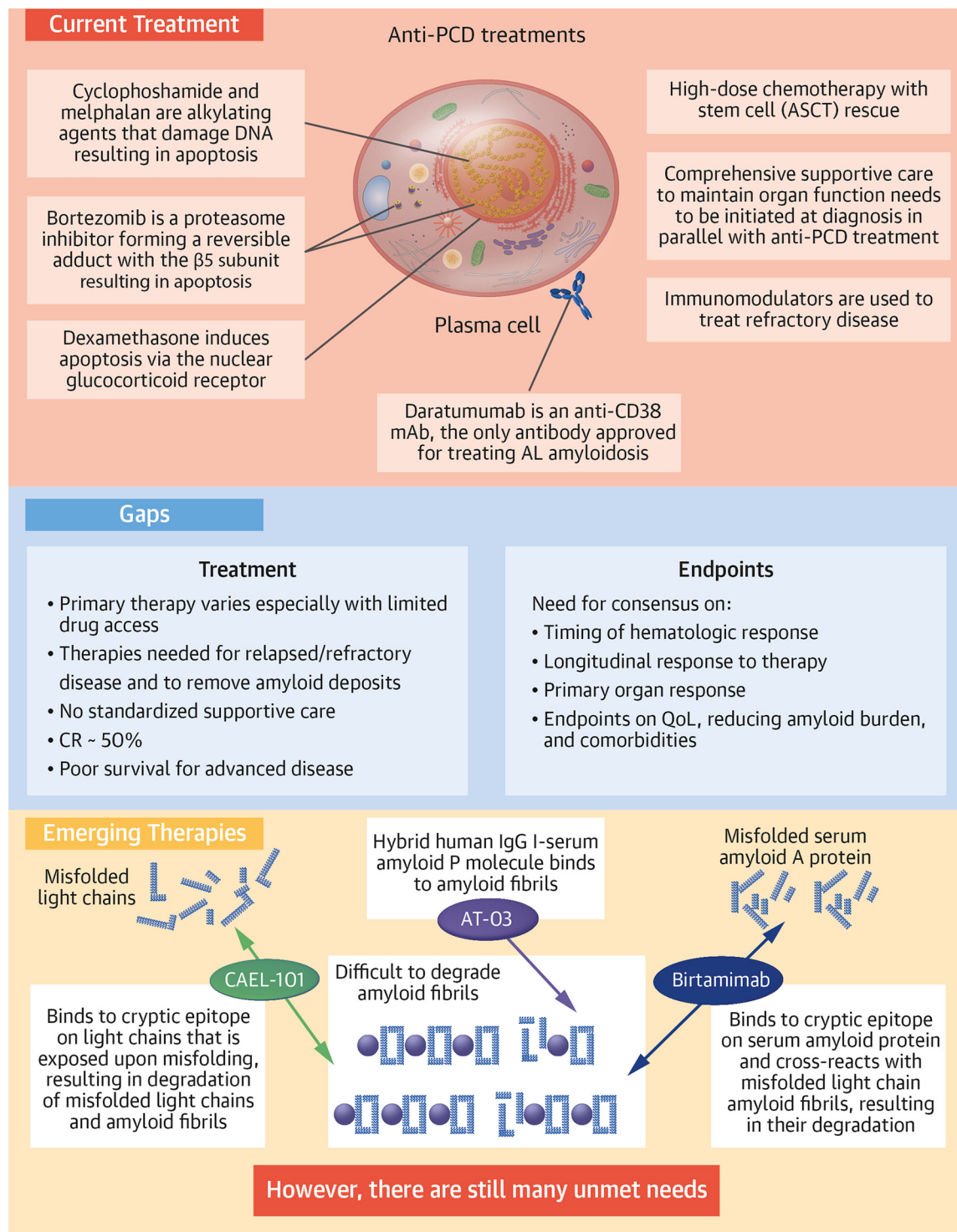


This figure illustrates the systemic nature of amyloid light chain amyloidosis, the number of organs and tissues that are affected, the percentage of patients in whom these organs are affected at diagnosis, and some commonly observed symptoms for the affected organ or system. LVEF = left ventricular ejection fraction; NT-proBNP = N-terminal pro-brain natriuretic peptide; TnT = troponin T.

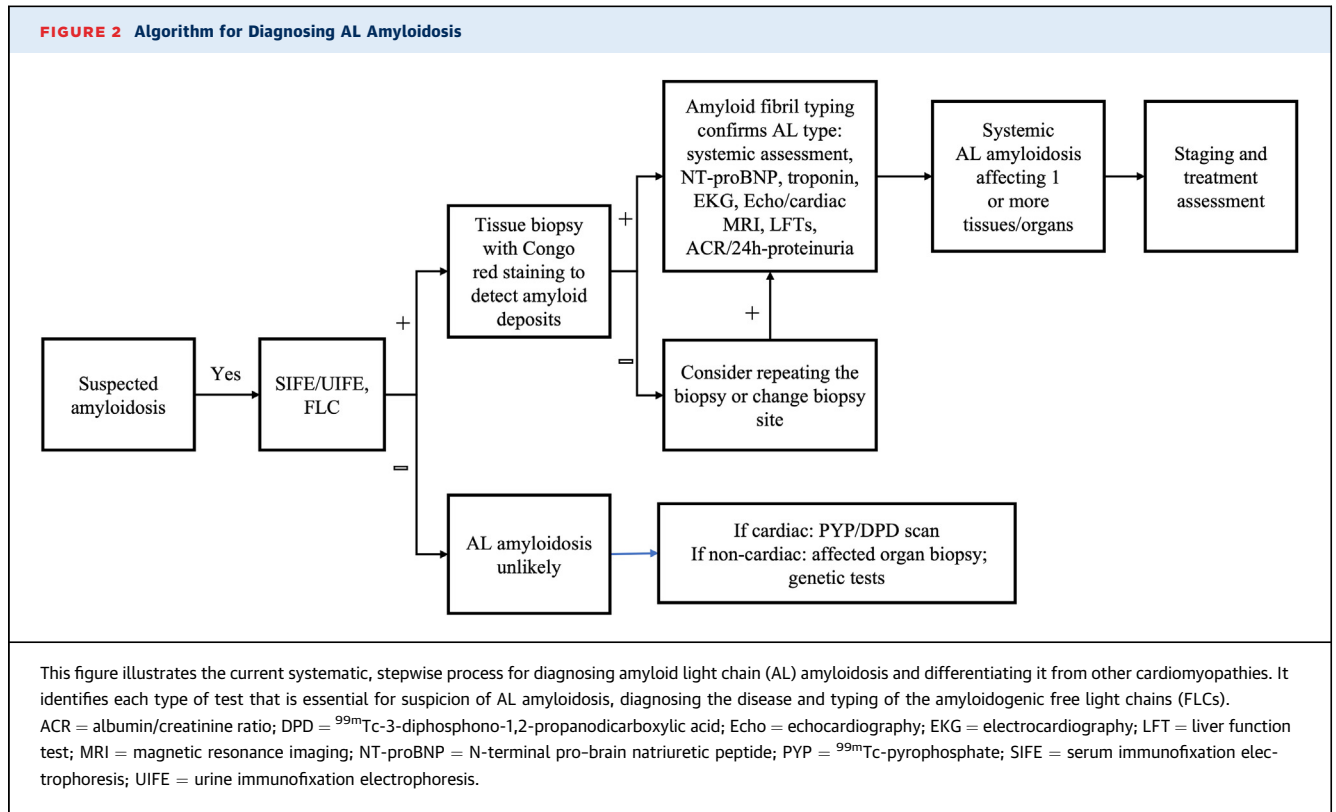
amyloid fibrils.^{25,35} This forms the basis of accurate diagnosis and a risk-adapted treatment plan for patients with AL amyloidosis.

STEP 1: SUSPICION OF AMYLOIDOSIS. Suspicion of amyloidosis should be very high when a patient presents with heart failure combined with a constellation of unexplained extracardiac symptoms such as neuropathy, bleeding, carpal tunnel syndrome, nephrotic syndrome, proteinuria, diarrhea, hepatomegaly, peripheral and autonomic neuropathy, macroglossia, and periorbital purpura.^{2,35-37} Another key cardiovascular presentation that should trigger suspicion of amyloidosis is an increase in left ventricular mass or wall thickness in the absence of hypertension or the

presence of hypotension, especially when associated with increased right ventricular mass.^{35,36,38} Cardiovascular findings that suggest amyloidosis include restrictive cardiomyopathy with disproportionately impaired longitudinal function compared with radial contraction (apical sparing on longitudinal strain imaging) and low-voltage electrocardiogram or pseudoinfarct pattern.³⁵⁻³⁸ Elevated serum cardiac troponin T and/or N-terminal pro-brain natriuretic peptide (NT-proBNP) are common in patients with cardiac AL amyloidosis.^{2,35,37} Although macroglossia and periorbital purpura are considered pathognomonic for AL amyloidosis, they occur in only about 15% of patients.² Although no single symptom is

CENTRAL ILLUSTRATION Current Treatment, Knowledge Gaps, and Emerging Therapies for Amyloid Light Chain AmyloidosisWechalekar AD, et al. *J Am Coll Cardiol CardioOnc.* 2022;4(4):427-441.

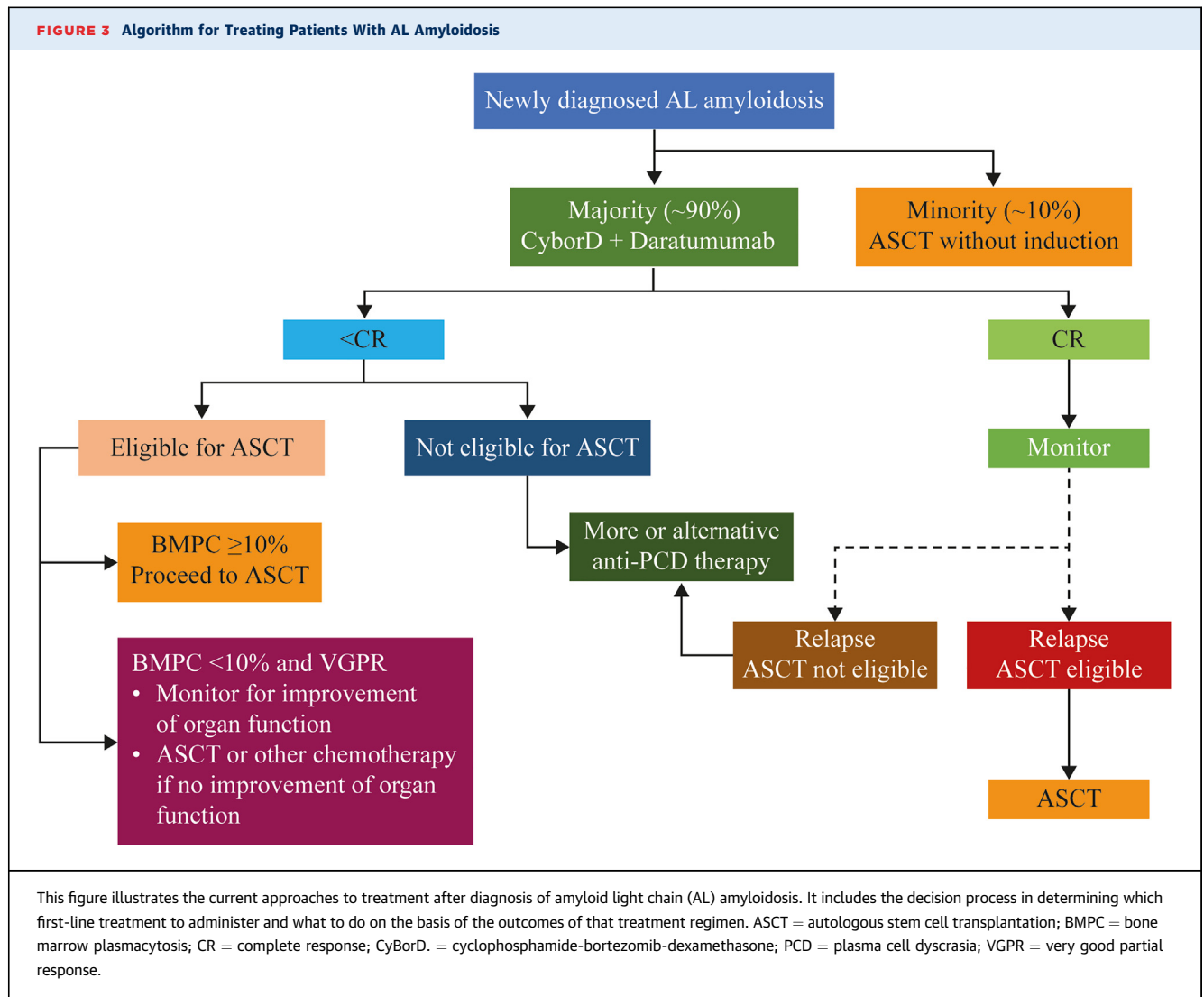
This figure summarizes (A) the current treatment paradigm, (B) the gaps that still exist in treatment and in relevant endpoints, and (C) emerging therapies that target removal of existing amyloid fibril deposits from organs and tissues. AL = amyloid light chain; ASCT = autologous stem cell transplantation; CR = complete response; IgG = immunoglobulin G; PCD = plasma cell dyscrasia; QoL = quality of life.



specific for AL amyloidosis, it should be suspected when there is a combination of cardiomyopathy and/or other aforementioned nonspecific symptoms.

STEP 2: DIAGNOSIS OF AMYLOIDOSIS. Once amyloidosis is suspected, there are several tests that can be undertaken to verify the diagnosis, detect the presence of an underlying PCD, and determine which organs are involved (Figure 3). Free light chain (FLC) assays can detect abnormal levels of Ig light chain in serum.³⁹⁻⁴¹ Serum and urine immunofixation electrophoresis assays are used to quantify and determine the type of abnormal Ig light chains or monoclonal protein.⁴⁰⁻⁴² Positive results in these assays would indicate the presence of a monoclonal gammopathy of undetermined significance, multiple myeloma, indolent B cell lymphoma, Waldenström macroglobulinemia, or AL amyloidosis.⁴⁰⁻⁴³ The combination of these assays can be very effective in detecting amyloidogenic light chain in most patients with AL amyloidosis.⁴³ The absence of a detectable monoclonal protein in the serum and urine by immunofixation electrophoresis and serum FLC assays makes AL amyloidosis less likely. Congo red staining of a tissue biopsy sample is required for confirmation of the diagnosis. Abdominal fat pad biopsies are a fast

and safe option to detect amyloid deposits.⁴⁴ Although the presence of amyloid deposits by Congo red staining in fat pad confirms the diagnosis of amyloidosis, their absence does not rule out disease.⁴⁴ Bone marrow examination is an essential component of AL amyloidosis diagnosis. Combination of abdominal fat and bone marrow biopsies will identify 85% of patients with AL amyloidosis.⁴⁵ In case of a negative biopsy result, alternative sites (labial salivary glands, gut) or a biopsy of the affected organ (eg, heart, kidney) should be considered.⁴ There are structural and functional differences between cardiac AL amyloidosis and other hypertrophic cardiomyopathies, but significant overlap exists.⁴⁶ Echocardiography can provide an assessment of the likelihood of cardiac amyloid infiltration vs other hypertrophic cardiomyopathies and can assess the severity of cardiac involvement.^{23,47-49} Although echocardiography is useful in patients with proven amyloidosis for both diagnosis and monitoring of heart involvement, the overlap of echocardiographic features among multiple diseases makes echocardiography poorly suited to rule out the diagnosis definitively.²³ Cardiac magnetic resonance imaging (CMR) offers accurate information regarding the heart's structure and function with precision

FIGURE 3 Algorithm for Treating Patients With AL Amyloidosis

advantages over echocardiography; the key is its unique ability to give information about the tissue composition by “myocardial tissue characterization,” making it a highly sensitive and specific imaging modality to distinguish cardiac amyloidosis from other hypertrophic phenocopies.^{38,50-59} CMR with late gadolinium enhancement (LGE) can visualize the continuum of cardiac infiltration, from sub-endocardial LGE to increasing transmural as the disease progresses.^{52,60,61} When combined with T1 mapping, CMR with LGE can be used to characterize and measure the degree of cardiac amyloid infiltration with 70% to 80% accuracy in patients with known systemic AL amyloidosis.⁶²⁻⁶⁹ It should be mentioned that although CMR is sensitive for distinguishing AL from other cardiomyopathies, it may not be suggestive in patients with early involvement

of the heart by AL amyloidosis (ie, the absence of LGE on CMR does not rule out early cardiac involvement). Extracellular volume mapping should be considered in the CMR protocol to exclude early cardiac amyloid infiltration.

STEP 3: TYPING AND CONFIRMING DIAGNOSIS OF AL AMYLOIDOSIS. It is critical to identify the type of amyloid fibril to avoid misdiagnosis and initiation of incorrect or inappropriate treatment, which could have disastrous consequences for a patient. This has become even more important with increasing recognition of cardiac amyloidosis in older patients (differential diagnosis between wild-type transthyretin [ATTR] and AL amyloidosis). The most common methods of amyloid fibril typing include immunohistochemistry or laser capture, followed by mass

TABLE 1 Criteria for Treatment Response

Category	Response	Criteria
Hematologic ⁷⁶	Complete response	Absence of amyloidogenic light chains (either free and/or as part of a complete immunoglobulin) defined by negative IFE of both serum and urine AND Either an FLC ratio within the reference range or uninvolved FLC concentration greater than involved FLC concentration with or without an abnormal FLC ratio
	Very good partial response	dFLC <40 mg/L
	Partial response	dFLC decrease >50% from baseline
	No response	All other patients
Cardiac ⁷⁵	Improvement	Decrease in NT-proBNP by >30% AND >300 pg/mL decrease (if baseline NT-proBNP >650 pg/mL) ^a OR ≥2-point decrease in NYHA functional class (if baseline NYHA functional class III or IV)
		Proteinuria decreases ≥30% or a drop in proteinuria to <0.5 g/24 h in patients without renal progression ^b (>25% decrease in eGFR)
Renal ^{75,78}	Improvement	Decrease in abnormal alkaline phosphatase levels by ≥50% OR Decrease in radiographic liver size by ≥2 cm
Hepatic ^{75,79}	Improvement	

^aPatients with baseline NT-proBNP ≤ 650 pg/mL are not considered to have cardiac involvement. ^bRenal progression is defined as a >25% decrease in eGFR.
 dFLC = difference between involved and uninvolved free light chain; eGFR = estimated glomerular filtration rate; FLC = free light chain; IFE = immunofixation electrophoresis; NT-proBNP = N-terminal pro-brain natriuretic peptide; NYHA = New York Heart Association.

spectrometry to identify the amyloid subtype.^{70,71} As the accuracy of immunohistochemistry is dependent on the expertise of the laboratory and needs an extensive panel of antibodies for accurate reporting, laser capture with mass spectrometry has become the method of choice for amyloid fibril typing.⁷⁰

Biopsy has been an essential step in diagnosis of amyloidosis until recent advances, showing accurate diagnosis of cardiac ATTR amyloidosis using ^{99m}Tc-labeled bone scintigraphy tracers, a noninvasive procedure.⁷² Specifically, in the absence of a detectable monoclonal protein in blood or urine by immunofixation and normal serum FLCs, grade 2 or greater uptake on ^{99m}Tc-pyrophosphate or ^{99m}Tc-3-diphosphono-1,2-propanodicarboxylic acid scintigraphy is considered diagnostic of cardiac ATTR amyloidosis.⁷² Conversely, among patients who present with abnormal results on serum protein electrophoresis or FLC assays, no cardiac uptake on ^{99m}Tc-pyrophosphate or ^{99m}Tc-3-diphosphono-1,2-propanodicarboxylic acid scan can only exclude cardiac ATTR amyloidosis but crucially does not rule out cardiac AL amyloidosis.^{73,74} Indeed, in AL amyloidosis, a full nonbiopsy path to diagnosis does not exist.

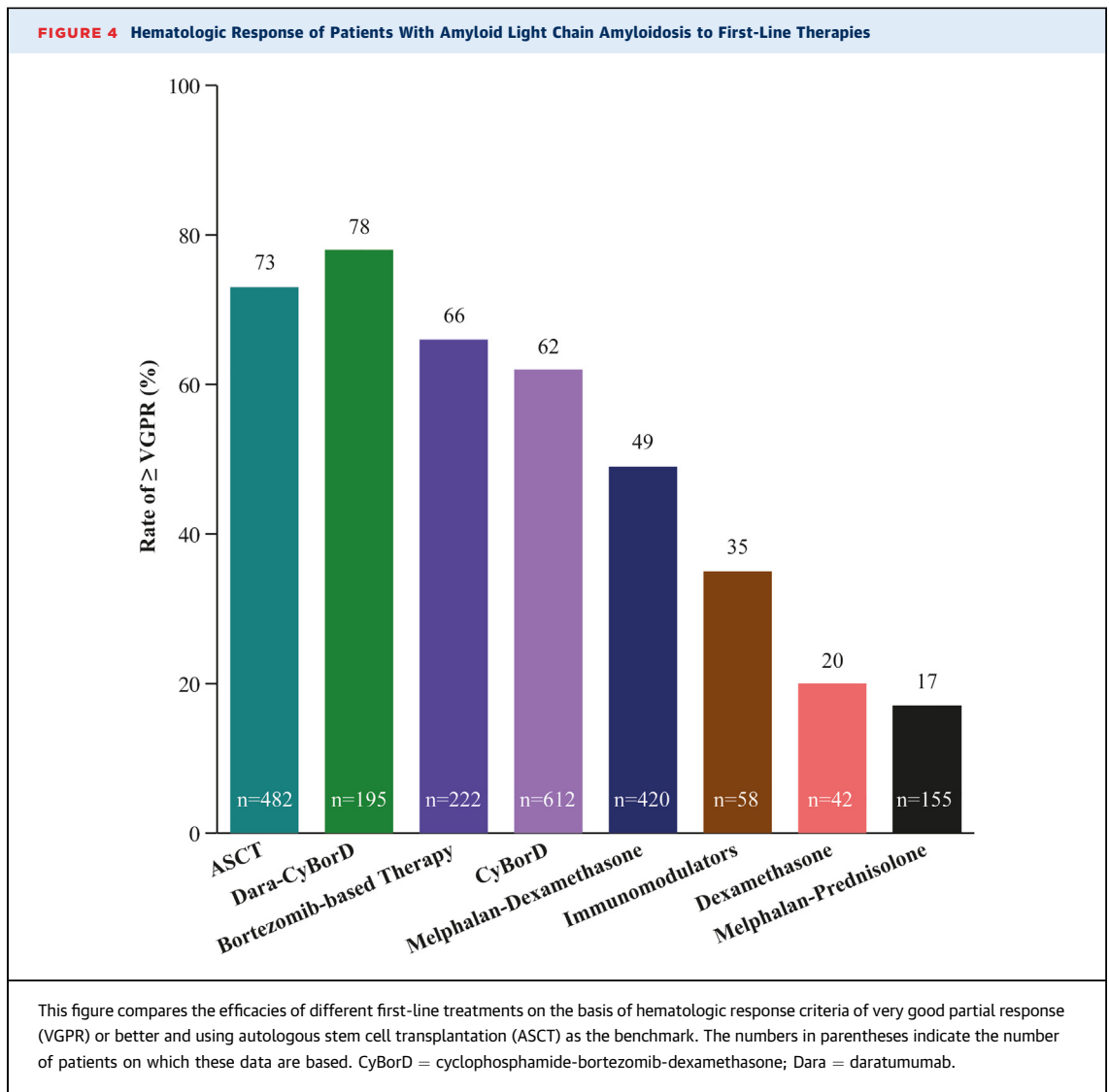
For cardiac AL amyloidosis, different centers may have different approaches as it pertains to cardiac biopsy, given the associated risks of cardiac biopsy and given that noninvasive cardiac imaging confirming cardiac involvement along with Congo red staining and typing of a noncardiac biopsy can diagnose AL amyloidosis with high sensitivity.^{58,75} However, if

there is high clinical suspicion of cardiac AL amyloidosis, cardiac biopsy should be performed if biopsy of noncardiac sites is negative.⁷⁶

CURRENT STANDARD OF CARE

The current standard of care is based on observations of improved overall survival and organ function when synthesis of amyloidogenic light chain is suppressed or stopped, along with supportive care to address specific organ dysfunction.⁴² The response to treatment requires dual assessment: 1) primary assessment of hematologic response of the underlying clone to chemotherapy, which can manifest within a few weeks of treatment initiation; and 2) assessment of change in organ function for organ response or progression.^{77,78} Improved organ function is usually delayed by several months (median 10.4 months), and only 25% to 50% of all patients treated with current chemotherapy regimens achieve an organ response.⁷⁹ The criteria for evaluating hematologic and organ responses are given in **Table 1**.^{80,81}

At diagnosis, patients are first evaluated to determine whether they are eligible to receive ASCT (~20% of patients) or will be receiving combination chemotherapy (~80% of patients) (**Figure 3**).^{82,83} The criteria for ASCT are very strict to minimize treatment-related mortality, and many patients opt to not undergo the procedure even when eligible.⁸⁴ Data suggest better outcomes for patients who undergo induction chemotherapy prior to ASCT, with the



caveat that a small proportion of patients may become ASCT ineligible during induction treatment.⁸⁵ Among patients receiving ASCT as first-line therapy to treat AL amyloidosis, 73% exhibited complete response (CR) or very good partial response (VGPR) as determined by hematologic response criteria (Figure 4).^{9,86} Patients not eligible for ASCT (~80%) and those who have opted not to receive it are treated with one of several options of anti-PCD therapy.^{77,87} Current guidelines recommend a combination of cyclophosphamide, bortezomib, and dexamethasone (CyBorD) and daratumumab as the preferred first-line anti-PCD therapy, with CyBorD and bortezomib-melphalan-dexamethasone as alternatives when there is limited access to daratumumab.⁸⁷ Efficacy of the most commonly used

first-line treatments with respect to hematologic response are shown in Figure 4. The hematologic efficacy of daratumumab-CyBorD is very high, with 78% of patients achieving VGPR or better.⁸⁸⁻⁹¹ More than 20% of patients discontinue at least 1 therapy, and >30% of patients reduce treatments because of adverse events.⁹² Patients who present with significant neuropathy can be treated with regimens that avoid bortezomib and use daratumumab monotherapy. Ixazomib may be useful in patients with relapsed disease who have not been previously exposed to a proteasome inhibitor.^{87,93-96}

Orthostatic hypotension, a highly debilitating symptom experienced by patients with AL amyloidosis as a consequence of autonomic neuropathy, can be managed by adjunct supportive treatment,

including wearing compression garments and medications such as midodrine or droxidopa.^{2,12,97} Although fludrocortisone may help some patients, it often causes fluid retention and is often not well tolerated.²

ANTIFIBRIL TREATMENTS IN DEVELOPMENT

At the present time, 2 antibodies, birtamimab and CAEL-101, are being investigated as antifibril agents.⁹⁸⁻¹⁰⁶ Dezamizumab, another such agent, is no longer being investigated. Antifibril antibodies have the potential to remove existing amyloid fibrils from organs by activating immune cells to cause chemical and enzymatic degradation of existing amyloid fibrils and inducing antibody-dependent phagocytosis of the fibrils.^{107,108} In addition, although this utility has not yet been adequately investigated, antifibril antibodies have the potential to be used as diagnostic agents to image amyloid deposits and for amyloid typing on tissue biopsies.

BIRTAMIMAB. Birtamimab (NEOD0001) is a fully humanized monoclonal antibody that targets a cryptic epitope on serum amyloid A protein that is revealed when misfolded.¹⁰⁹ It cross-reacts with Ig light chain amyloid fibrils and reportedly activates macrophage-mediated degradation and clearance of light chain fibrils. A first-in-human phase 1/2 study (NCT01707264) of intravenous birtamimab given every 4 weeks was conducted in 27 patients who had experienced at least a partial hematologic response to prior light chain-suppressive chemotherapy but had persistent organ dysfunction. The treatment was well tolerated, with no dose-limiting toxicities or discontinuations due to drug-related adverse events. Organ responses were observed in 57% of cardiac-evaluable patients and 60% of renal-evaluable patients.¹¹⁰ Birtamimab, given as an intravenous infusion every 28 days, was well tolerated up to 24 mg/kg and demonstrated cardiac or renal response in the majority of patients, with the remainder having stable disease.¹¹⁰ In some cases, organ response was delayed by several months relative to hematologic response.¹¹¹ On the basis of these promising results, the phase 3 VITAL study (NCT02312206) randomized 260 patients with newly diagnosed AL amyloidosis with cardiac involvement to receive standard-of-care chemotherapy plus either birtamimab or placebo. A futility analysis performed after 103 primary endpoint events (time to all-cause mortality or cardiac hospitalization) showed no advantage for the birtamimab arm, and the study was therefore terminated. However, a post hoc analysis identified a benefit for both primary endpoints in patients with Mayo stage IV

cardiac disease, with median survival of 8.3 months in the placebo group compared with not reached (>12 months) in the birtamimab group, leading to the initiation of AFFIRM-AL (A Study to Evaluate the Efficacy and Safety of Birtamimab in Mayo Stage IV Patients With AL Amyloidosis; NCT04973137), a new phase 3 trial in patients with advanced cardiac disease.

CAEL-101. CAEL-101 is a chimeric monoclonal antibody that targets a cryptic epitope on Ig light chains that is exposed when the light chains are misfolded.^{107,112} It binds to misfolded free Ig light chains as well as amyloid fibrils deposited in organs.^{107,113,114} It is hypothesized that CAEL-101 opsonizes the amyloid fibrils and misfolded light chains, thereby attracting and activating macrophages that degrade the complex by phagocytosis and/or enzymatic and chemical proteolysis.¹⁰⁷ Preclinical studies further demonstrated that treatment with CAEL-101 resulted in regression of transplanted human amyloidomas in a mouse model.^{113,115,116} Phase 1 studies with CAEL-101 (NCT00807872 and NCT02245867) demonstrated that it recognized amyloid fibrils deposited in tissues. Furthermore, CAEL-101 had a dose-proportional pharmacokinetic profile without any dose-limiting toxicities.^{114,117,118} Preliminary results also showed that there were reductions in biomarkers of cardiomyopathy and nephropathy.^{117,118} The phase 2 study (NCT04304144) confirmed that there were no dose-limiting toxicities up to 1,000 mg/m² and that it could be administered with CyBorD or CyBorD plus daratumumab.^{100,101} Furthermore, the exposure to CAEL-101 was not affected by adding daratumumab to the anti-PCD treatment regimen. Initial evaluations also confirmed the improvements in biomarkers of cardiomyopathy and nephropathy.¹⁰⁰ On the basis of these promising results, 2 randomized, double-blind phase 3 studies are currently enrolling patients at more than 70 sites in several countries to evaluate the efficacy and safety of coadministering CAEL-101 with standard-of-care anti-PCD therapy in patients with AL amyloidosis and severe cardiomyopathy in stages IIIa (NCT04512235) and IIIb (NCT04504825). These are the first time-to-event studies focusing exclusively on patients with severe cardiomyopathy.

GAPS

TREATMENT GAPS. At present, although treatment guidelines exist, there is no consensus on which regimen should be used as first-line treatment.⁸⁷ The anti-PCD treatment recommended in current National Comprehensive Cancer Network guidelines is CyBorD with daratumumab.⁸⁷ The components of this

treatment, namely, bortezomib and dexamethasone, can increase NT-proBNP levels and even risk for death, especially among patients with advanced cardiomyopathy.^{119,120} In addition, these drugs are not always available or accessible, especially in developing countries, where other regimens do not appear to be inferior with respect to hematologic response and overall survival.¹²¹ However, the reasons for this equivalence in response is unclear. Despite advances, the rate of overall CR is about 50% under the best circumstances for any of the currently available treatments, indicating that the disease may continue to progress for more than one-half of patients.⁷⁷ Furthermore, ASCT does not appear to have an advantage over chemotherapy, especially among patients receiving daratumumab.¹²² Furthermore, none of the currently available treatments substantially improves survival rates among patients who are diagnosed with stage IIIb AL amyloidosis, although a small number of patients who achieve a rapid deep hematologic response appear to have a survival advantage.^{79,123}

All currently available treatment options, including ASCT, are adapted from treatments and regimens developed for multiple myeloma.^{89,124-126} The goal of the current treatments is to eliminate the source of the amyloidogenic protein production, and none targets removal of amyloid deposits.^{24,38,124,127,128} Thus, current therapies prevent further amyloid formation and deposition, with no treatment for the organ damage that has already occurred prior to treatment initiation or the damage that can continue to be caused by these preexisting deposits.^{24,38,124,127,128} Reducing or eliminating amyloid burden by partial or complete removal of preexisting amyloid deposits to repair and/or restore organ function, especially that of the heart, remains a huge treatment gap.

Immunomodulatory agents, such as lenalidomide and pomalidomide, usually in combination with dexamethasone, are commonly used to treat relapsed or refractory AL amyloidosis.^{129,130} However, this combination has a low hematologic response rate and can result in hematological toxicity, increased NT-proBNP, and sometimes nephrotoxicity.^{129,130} Most of the current chemotherapy regimens include dexamethasone (or other corticosteroids) as a key component. However, it is poorly tolerated, often causing worsening of heart failure, fatigue, increased skin fragility, and risk for sudden death in patients with advanced cardiac AL amyloidosis.^{119,120,130} Careful monitoring for complications and using the lowest doses possible are crucial. Results from a retrospective analysis show that venetoclax may be

effective among patients with AL amyloidosis with a t(11:14) translocation and refractory to standard anti-PCD treatment, suggesting that genetics may play a role in response.¹³¹ Thus, there is a need to better understand resistance to treatment and more effective and safer treatment options for patients with relapsed or refractory AL amyloidosis. This has become especially important with use of daratumumab as a frontline agent in treatment of AL amyloidosis.

Because AL amyloidosis is very heterogeneous in its presentation, supportive care to help manage the many symptoms experienced by patients is critical.¹³² However, the heterogeneous nature of AL amyloidosis also makes standardization of supportive care very difficult. At present, there are no consensus standards for supportive care. Diuretic agents, β -blockers, and angiotensin-converting enzyme inhibitors are the principal drugs used to prevent cardiac failure among patients with nonamyloid cardiomyopathy.^{2,132,133} However, in patients with AL amyloidosis with advanced cardiomyopathy, hypotension is common, and β -blockers and angiotensin-converting enzyme inhibitors are poorly tolerated and can be dangerous.^{2,132,133} These drugs should not be used for this group of patients except in very particular circumstances, determined on an individual case basis.¹³³ Bradyarrhythmia may require implantation of pacemakers, but the role of cardiac resynchronization devices remains unclear. Hypotension can also severely limit hemodialysis, which is essential for patients with renal involvement.^{132,133} Management of autonomic neuropathy remains challenging. In addition, there is a huge unmet need for supportive care among patients with comorbid gastrointestinal symptoms, for whom the current drugs and dietary modifications are not sufficient.¹³²

GAPS IN RELEVANT ENDPOINTS. The primary endpoint preferred by regulatory agencies is overall survival.¹³⁴ However, as many patients, especially those with minimal or no cardiomyopathy, can live for 5 years or longer after diagnosis, determining median overall survival requires very long trials, which proves difficult with a rare disease because of the paucity of patients available and delaying trial readouts. Better understanding from regulators is needed to accept surrogate endpoints such as the established criteria for hematologic response and NT-proBNP for cardiac response.¹³⁴ However, outcomes that reduce comorbidities, reduce amyloid burden, improve organ function, or improve patient QoL are less likely to be accepted as primary endpoints for trials, even if they are clinically relevant. It is

essential that this gap be addressed, and preferably eliminated, to ensure that the best treatments are available to patients.

The goal for hematologic response has been for patients to achieve VGPR or better (Table 1).^{16,77,79} Recently, the goal changed to achieving CR because it correlated better with improved patient survival and QoL. However, the current criteria for CR do not include measurement of the difference between involved and uninvolved FLC (<10 mg/dL) or involved FLC (<20 mg/dL) in the serum, both of which are significant predictors of survival and organ response.¹²⁴ There also is no consensus on the timing of hematologic response assessment. Hematologic response is variously reported 1, 3, or 6 months after treatment initiation, making it difficult to objectively evaluate the relative benefits of different treatment regimens as also is the lack of validated hematologic progression criteria. Time to retreatment often is used as a surrogate endpoint. These limitations in current hematologic response and progression criteria highlight the need for better means to measure initial and longitudinal response to treatment.

Organ response is typically determined only for a few organs, mainly the heart, kidneys, and liver, as these are considered the most relevant for survival.^{26,122} There are no established criteria for response to treatment for other organs, such as the gastrointestinal system, or for the neuropathy often experienced by patients. Although the hematologic and cardiac response criteria may reflect the level of cardiomyopathy, they do not inform the patients or those treating them about the disease state of other organs and tissues. Furthermore, neither the hematologic nor the organ response criteria measure the amyloid burden remaining in the body and continuing to have an adverse impact. Typically, organ response is observed much later than hematologic response, sometimes being delayed by months.^{79,135} Although achieving organ response within 1 year is predictive of longer survival, there are no standardized criteria on when organ response should be reported.⁷⁹

Functional changes are often measured in clinical trials using the 6-minute walk test and various QoL instruments.^{21,136-138} The 6-minute walk test is a simple method to determine improvements in physical function and requires only an even flat surface at least 30 m in length and a timer.¹³⁶ It is an easy test to implement and can reflect a patient's level of cardiac impairment and the ability to perform an activity of daily living.¹³⁶ The most commonly used instruments to measure QoL among patients with AL amyloidosis are the Short Form-36 (SF-36) and the Kansas City

Cardiomyopathy Questionnaire.^{21,68,137-139} Both are measures of patient-reported outcomes. While the Short Form 36 is a robust, generic instrument that provides a reasonable snapshot of the physical and mental health of the patient, the Kansas City Cardiomyopathy Questionnaire is more disease specific and provides an estimation of the health of the heart of the patient at the time the test is administered. Both instruments have been validated for use with patients with AL amyloidosis.^{21,137-139} Although it is understandable that QoL instruments are focused on general and cardiac health because survival is most closely associated with degree of cardiomyopathy, there are gaps in understanding the health of other organs or systems from a patient's perspective, despite instruments' being available to determine the degree of nephropathy or hepatopathy.^{140,141}

Structural improvements in the heart and decrease in myocardial amyloid deposits can be determined with CMR.⁵⁰ Functional improvements of the heart can be determined with echocardiography and global longitudinal strain measurements, which can help with predicting survival.¹⁴²⁻¹⁴⁵ There are also several studies under way to validate positron emission tomography-based scintigraphy as a relatively noninvasive method to determine health of and the amount of amyloid deposited in the heart.^{47,106,146-151}

Given the spectrum of endpoints used to evaluate response to treatment, there is no consensus on what defines a clinically meaningful response that translates to patient benefit in survival and QoL. Thus, there is a lack of consensus on what defines disease progression and, consequently, how to define progression-free survival.

It must be noted that the endpoints measured and the criteria for response to treatment were developed exclusively on the basis of the effectiveness of anti-PCD therapy, including ASCT. There are no generally accepted endpoints for reduction in amyloid burden or functional changes in organs other than the heart. Thus, there is a huge informational gap that needs to be addressed.

CONCLUSIONS

AL amyloidosis is a very devastating disease with continuing high early mortality. A significant majority of patients present with cardiomyopathy and are usually referred to cardiologists for diagnosis. However, for a substantial number of these patients, accurate diagnosis is either delayed or completely missed. These delays lead to poor prognosis and survival. It is therefore critical to increase awareness, knowledge, and understanding of AL amyloidosis

among all health care providers, cardiologists in particular. In this review, we have attempted to provide a concise overview of this very complex rare disease. Furthermore, we have summarized the promising novel interventions under investigation to address removal of amyloid fibrils already deposited in the organs, an important treatment gap that currently exists. This review is but one step toward improving the diagnostic and treatment odysseys experienced by patients with AL amyloidosis.

ACKNOWLEDGMENT Medical writing support was provided by Mukund Nori, PhD, MBA, CMPP, of rareLife solutions and funded by Alexion.

FUNDING SUPPORT AND AUTHOR DISCLOSURES

Support for the development of this paper was provided by Alexion, AstraZeneca Rare Disease. Drs Wechalekar, Fontana, and Liedtke have received trial support from Alexion, AstraZeneca Rare Disease. Dr Quarta is an employee of Alexion and AstraZeneca Rare Disease, and has stock in the company.

ADDRESS FOR CORRESPONDENCE: Dr Ashutosh D. Wechalekar, National Amyloidosis Centre, University College London (Royal Free Campus), Rowland Hill Street, London NW3 2PF, United Kingdom. E-mail: a.wechalekar@ucl.ac.uk. Twitter: [@awechalekar](https://twitter.com/awechalekar), [@dr_m_fontana](https://twitter.com/dr_m_fontana), [@cristina_quarta](https://twitter.com/cristina_quarta).

REFERENCES

- Blank M, Campbell M, Clarke JO, et al. The amyloidosis forum: a public private partnership to advance drug development in AL amyloidosis. *Orphanet J Rare Dis*. 2020;15:268.
- Desport E, Bridoux F, Sirac C, et al. AL amyloidosis. *Orphanet J Rare Dis*. 2012;7:54.
- Quock TP, Yan T, Chang E, Guthrie S, Broder MS. Epidemiology of AL amyloidosis: a real-world study using US claims data. *Blood Adv*. 2018;2:1046-1053.
- Vaxman I, Gertz M. Recent advances in the diagnosis, risk stratification, and management of systemic light-chain amyloidosis. *Acta Haematol*. 2019;141:93-106.
- Kumar S, Dispenzieri A, Lacy MQ, et al. Revised prognostic staging system for light chain amyloidosis incorporating cardiac biomarkers and serum free light chain measurements. *J Clin Oncol*. 2012;30:989-995.
- Kumar SK, Gertz MA, Lacy MQ, et al. Recent improvements in survival in primary systemic amyloidosis and the importance of an early mortality risk score. *Mayo Clin Proc*. 2011;86:12-18.
- Manwani R, Cohen O, Sharpley F, et al. A prospective observational study of 915 patients with systemic AL amyloidosis treated with upfront bortezomib. *Blood*. 2019;134:2271-2280.
- Barrett CD, Dobos K, Liedtke M, et al. A changing landscape of mortality for systemic light chain amyloidosis. *J Am Coll Cardiol HF*. 2019;7:958-966.
- Muchtar E, Gertz MA, Kumar SK, et al. Improved outcomes for newly diagnosed AL amyloidosis between 2000 and 2014: cracking the glass ceiling of early death. *Blood*. 2017;129:2111-2119.
- Schulman A, Connors LH, Weinberg J, et al. Patient outcomes in light chain (AL) amyloidosis: the clock is ticking from symptoms to diagnosis. *Eur J Haematol*. 2020;105:495-501.
- Vaxman I, Kumar SK, Buadi F, et al. Outcomes among newly diagnosed AL amyloidosis patients with a very high NT-proBNP: implications for trial design. *Leukemia*. 2021;35:3604-3607.
- Baker KR, Rice L. The amyloidoses: clinical features, diagnosis and treatment. *Methodist Debakey Cardiovasc J*. 2012;8:3-7.
- Merlini G. AL amyloidosis: from molecular mechanisms to targeted therapies. *Hematology Am Soc Hematol Educ Program*. 2017;2017:1-12.
- Imperlini E, Gnecci M, Rognoni P, et al. Proteotoxicity in cardiac amyloidosis: amyloidogenic light chains affect the levels of intracellular proteins in human heart cells. *Sci Rep*. 2017;7:15661.
- Lavattelli F, Imperlini E, Orrù S, et al. Novel mitochondrial protein interactors of immunoglobulin light chains causing heart amyloidosis. *FASEB J*. 2015;29:4614-4628.
- Gertz MA, Dispenzieri A. Systemic amyloidosis recognition, prognosis, and therapy: a systematic review. *JAMA*. 2020;324:79-89.
- Gillmore JD, Hawkins PN. Pathophysiology and treatment of systemic amyloidosis. *Nat Rev Nephrol*. 2013;9:574-586.
- Merlini G, Bellotti V. Molecular mechanisms of amyloidosis. *N Engl J Med*. 2003;349:583-596.
- Escher F, Senoner M, Doerler J, et al. When and how do patients with cardiac amyloidosis die? *Clin Res Cardiol*. 2020;109:78-88.
- Shu J, Lo S, Phillips M, et al. Depression and anxiety in patients with AL amyloidosis as assessed by the SF-36 questionnaire: experience in 1226 patients. *Amyloid*. 2016;23:188-193.
- Bayliss M, McCausland KL, Guthrie SD, White MK. The burden of amyloid light chain amyloidosis on health-related quality of life. *Orphanet J Rare Dis*. 2017;12:15.
- Falk RH. Diagnosis and management of the cardiac amyloidoses. *Circulation*. 2005;112:2047-2060.
- Boldrini M, Cappelli F, Chacko L, et al. Multiparametric echocardiography scores for the diagnosis of cardiac amyloidosis. *J Am Coll Cardiol Img*. 2020;13:909-920.
- Lin HM, Gao X, Cooke CE, et al. Disease burden of systemic light-chain amyloidosis: a systematic literature review. *Curr Med Res Opin*. 2017;33:1017-1031.
- McCausland KL, White MK, Guthrie SD, et al. Light chain (AL) amyloidosis: the journey to diagnosis. *Patient*. 2018;11:207-216.
- Lousada I, Comenzo RL, Landau H, Guthrie S, Merlini G. Light chain amyloidosis: patient experience survey from the amyloidosis research consortium. *Adv Ther*. 2015;32:920-928.
- Fotiu D, Dimopoulos MA, Kastritis E. Systemic AL amyloidosis: current approaches to diagnosis and management. *HemaSphere*. 2020;4:e454.
- Muchtar E, Buadi FK, Dispenzieri A, Gertz MA. Immunoglobulin light-chain amyloidosis: from basics to new developments in diagnosis, prognosis and therapy. *Acta Haematologica*. 2016;135:172-190.
- Grogan M, Dispenzieri A, Gertz MA. Light-chain cardiac amyloidosis: strategies to promote early diagnosis and cardiac response. *Heart*. 2017;103:1065-1072.
- Oubari S, Naser E, Papanthasiou M, et al. Impact of time to diagnosis on Mayo stages, treatment outcome, and survival in patients with AL amyloidosis and cardiac involvement. *Eur J Haematol*. 2021;107:449-457.
- Wittles RM, Liedtke M. AL amyloidosis for the cardiologist and oncologist. *J Am Coll Cardiol CardioOnc*. 2019;1:117-130.
- Bianchi G, Zhang Y, Comenzo RL. AL amyloidosis: current chemotherapy and immune therapy treatment strategies. *J Am Coll Cardiol CardioOnc*. 2021;3:467-487.
- Bishop E, Brown EE, Fajardo J, Barouch LA, Judge DP, Halushka MK. Seven factors predict a delayed diagnosis of cardiac amyloidosis. *Amyloid*. 2018;25:174-179.
- Zumbo G, Sadeghi-Alavijeh O, Hawkins PN, Fontana M. New and developing therapies for AL amyloidosis. *Expert Opin Pharmacother*. 2017;18:139-149.
- Bhutani D, Lentzsch S. Diagnosis and management of systemic light chain AL amyloidosis. *Pharmacol Ther*. 2020;214:107612.
- Ash S, Shorer E, Ramgobin D, et al. Cardiac amyloidosis—a review of current literature for the

- practicing physician. *Clin Cardiol*. 2021;44:322-331.
37. Griffin JM, Rosenblum H, Maurer MS. Pathophysiology and therapeutic approaches to cardiac amyloidosis. *Circ Res*. 2021;128:1554-1575.
38. Fikrlle M, Paleček T, Kuchynka P, et al. Cardiac amyloidosis: a comprehensive review. *Cor Vasa*. 2013;55:e60-e75.
39. Kumar S, Dispenzieri A, Katzmann JA, et al. Serum immunoglobulin free light-chain measurement in primary amyloidosis: prognostic value and correlations with clinical features. *Blood*. 2010;116:5126-5129.
40. Kim H-S, Kim HS, Shin K-S, et al. Clinical comparisons of two free light chain assays to immunofixation electrophoresis for detecting monoclonal gammopathy. *Biomed Res Int*. 2014;2014:647238.
41. Rubinstein SM, Stockerl-Goldstein K. How to screen for monoclonal gammopathy in patients with a suspected amyloidosis. *J Am Coll Cardiol CardioOnc*. 2021;3:590-593.
42. Sancharawala V. Light-chain (AL) amyloidosis: diagnosis and treatment. *Clin J Am Soc Nephrol*. 2006;1:1331-1341.
43. Palladini G, Russo P, Bosoni T, et al. Identification of amyloidogenic light chains requires the combination of serum-free light chain assay with immunofixation of serum and urine. *Clin Chem*. 2009;55:499-504.
44. Wisniewski B, Wechalekar A. Confirming the diagnosis of amyloidosis. *Acta Haematologica*. 2020;143:312-321.
45. Gertz MA. Immunoglobulin light chain amyloidosis: 2016 update on diagnosis, prognosis, and treatment. *Am J Hematol*. 2016;91:947-956.
46. Sankaranarayanan R, Fleming EJ, Garratt CJ. Mimics of hypertrophic cardiomyopathy—diagnostic clues to aid early identification of phenocopies. *Arrhythm Electrophysiol Rev*. 2013;3:36-40.
47. Manwani R, Page J, Lane T, et al. A pilot study demonstrating cardiac uptake with ¹⁸F-florbetapir PET in AL amyloidosis patients with cardiac involvement. *Amyloid*. 2018;25:247-252.
48. Quarta CC, Kruger JL, Falk RH. Cardiac amyloidosis. *Circulation*. 2012;126:e178-e182.
49. Yang H, Wright L, Negishi T, Negishi K, Liu J, Marwick TH. Research to practice. *J Am Coll Cardiol Img*. 2018;11:1196-1201.
50. Banypersad SM. The evolving role of cardiovascular magnetic resonance imaging in the evaluation of systemic amyloidosis. *Magn Reson Insights*. 2019;12:1178623X19843519.
51. Banypersad SM, Sado DM, Flett AS, et al. Quantification of myocardial extracellular volume fraction in systemic AL amyloidosis: an equilibrium contrast cardiovascular magnetic resonance study. *Circ Cardiovasc Imaging*. 2013;6:34-39.
52. Austin BA, Tang WH, Rodriguez ER, et al. Delayed hyper-enhancement magnetic resonance imaging provides incremental diagnostic and prognostic utility in suspected cardiac amyloidosis. *J Am Coll Cardiol Img*. 2009;2:1369-1377.
53. Di Bella G, Pizzino F, Minutoli F, et al. The mosaic of the cardiac amyloidosis diagnosis: role of imaging in subtypes and stages of the disease. *Eur Heart J Cardiovasc Imaging*. 2014;15:1307-1315.
54. Ruberg FL, Appelbaum E, Davidoff R, et al. Diagnostic and prognostic utility of cardiovascular magnetic resonance imaging in light-chain cardiac amyloidosis. *Am J Cardiol*. 2009;103:544-549.
55. Syed IS, Glockner JF, Feng D, et al. Role of cardiac magnetic resonance imaging in the detection of cardiac amyloidosis. *J Am Coll Cardiol Img*. 2010;3:155-164.
56. Vogelsberg H, Mahrholdt H, Deluigi CC, et al. Cardiovascular magnetic resonance in clinically suspected cardiac amyloidosis: noninvasive imaging compared to endomyocardial biopsy. *J Am Coll Cardiol*. 2008;51:1022-1030.
57. Fontana M, Banypersad SM, Treibel TA, et al. Differential myocyte responses in patients with cardiac transthyretin amyloidosis and light-chain amyloidosis: a cardiac MR imaging study. *Radiology*. 2015;277:388-397.
58. Fontana M, Chung R, Hawkins PN, Moon JC. Cardiovascular magnetic resonance for amyloidosis. *Heart Fail Rev*. 2015;20:133-144.
59. Treibel TA, Bandula S, Fontana M, et al. Extracellular volume quantification by dynamic equilibrium cardiac computed tomography in cardiac amyloidosis. *J Cardiovasc Comput Tomogr*. 2015;9:585-592.
60. Aquaro GD, Pugliese NR, Peretto F, et al. Myocardial signal intensity decay after gadolinium injection: a fast and effective method for the diagnosis of cardiac amyloidosis. *Int J Cardiovasc Imaging*. 2014;30:1105-1115.
61. Fontana M, Pica S, Reant P, et al. Prognostic value of late gadolinium enhancement cardiovascular magnetic resonance in cardiac amyloidosis. *Circulation*. 2015;132:1570-1579.
62. Banypersad SM, Fontana M, Maestrini V, et al. T1 mapping and survival in systemic light-chain amyloidosis. *Eur Heart J*. 2015;36:244-251.
63. Fontana M, Banypersad SM, Treibel TA, et al. Native T1 mapping in transthyretin amyloidosis. *J Am Coll Cardiol Img*. 2014;7:157-165.
64. Karamitsos TD, Piechnik SK, Banypersad SM, et al. Noncontrast T1 mapping for the diagnosis of cardiac amyloidosis. *J Am Coll Cardiol Img*. 2013;6:488-497.
65. White JA, Kim HW, Shah D, et al. CMR imaging with rapid visual T1 assessment predicts mortality in patients suspected of cardiac amyloidosis. *J Am Coll Cardiol Img*. 2014;7:143-156.
66. Khaliq Z, Ferreira PF, Scott AD, et al. Diffusion tensor cardiovascular magnetic resonance in cardiac amyloidosis. *Circ Cardiovasc Imaging*. 2020;13:e009901.
67. Orini M, Graham AJ, Martinez-Naharro A, et al. Noninvasive mapping of the electrophysiological substrate in cardiac amyloidosis and its relationship to structural abnormalities. *J Am Heart Assoc*. 2019;8:e012097.
68. Green CP, Porter CB, Bresnahan DR, Spertus JA. Development and evaluation of the Kansas City Cardiomyopathy Questionnaire: a new health status measure for heart failure. *J Am Coll Cardiol*. 2000;35:1245-1255.
69. Muchtar E, Dispenzieri A, Magen H, et al. Systemic amyloidosis from A (AA) to T (ATTR): a review. *J Intern Med*. 2021;289:268-292.
70. Schönland SO, Hegenbart U, Bochtler T, et al. Immunohistochemistry in the classification of systemic forms of amyloidosis: a systematic investigation of 117 patients. *Blood*. 2012;119:488-493.
71. Abildgaard N, Rojek AM, Møller HEH, et al. Immunoelectron microscopy and mass spectrometry for classification of amyloid deposits. *Amyloid*. 2020;27:59-66.
72. Treglia G, Glaudemans A, Bertagna F, et al. Diagnostic accuracy of bone scintigraphy in the assessment of cardiac transthyretin-related amyloidosis: a bivariate meta-analysis. *Eur J Nucl Med Mol Imaging*. 2018;45:1945-1955.
73. Tsutsui Y, Kubota T, Kato S, et al. Utility of ^{99m}Tc-pyrophosphate scintigraphy in diagnosing transthyretin cardiac amyloidosis in real-world practice. *Circ Rep*. 2019;1:277-285.
74. Bokhari S, Castaño A, Pozniakoff T, Desliste S, Latif F, Maurer MS. ^{99m}Tc-pyrophosphate scintigraphy for differentiating light-chain cardiac amyloidosis from the transthyretin-related familial and senile cardiac amyloidoses. *Circ Cardiovasc Imaging*. 2013;6:195-201.
75. Brownrigg J, Lorenzini M, Lumley M, Elliott P. Diagnostic performance of imaging investigations in detecting and differentiating cardiac amyloidosis: a systematic review and meta-analysis. *ESC Heart Failure*. 2019;6:1041-1051.
76. Cooper LT, Baughman KL, Feldman AM, et al. The role of endomyocardial biopsy in the management of cardiovascular disease. *Circulation*. 2007;116:2216-2233.
77. Dispenzieri A, Buadi F, Kumar SK, et al. Treatment of immunoglobulin light chain amyloidosis: Mayo Stratification of Myeloma and Risk-Adapted Therapy (mSMART) consensus statement. *Mayo Clin Proc*. 2015;90:1054-1081.
78. Palladini G, Schönland SO, Sancharawala V, et al. Clarification on the definition of complete haematologic response in light-chain (AL) amyloidosis. *Amyloid*. 2021;28:1-2.
79. Kaufman GP, Dispenzieri A, Gertz MA, et al. Kinetics of organ response and survival following normalization of the serum free light chain ratio in AL amyloidosis. *Am J Hematol*. 2015;90:181-186.
80. Palladini G, Hegenbart U, Milani P, et al. A staging system for renal outcome and early markers of renal response to chemotherapy in AL amyloidosis. *Blood*. 2014;124:2325-2332.
81. Gertz MA, Comenzo R, Falk RH, et al. Definition of organ involvement and treatment response in immunoglobulin light chain amyloidosis (AL): a consensus opinion from the 10th International Symposium on Amyloid and Amyloidosis, Tours, France, 18-22 April 2004. *Am J Hematol*. 2005;79:319-328.
82. Gertz MA. Immunoglobulin light chain amyloidosis: 2018 update on diagnosis, prognosis, and treatment. *Am J Hematol*. 2018;93:1169-1180.

- 83.** Gertz MA. Immunoglobulin light chain amyloidosis diagnosis and treatment algorithm 2018. *Blood Cancer J.* 2018;8:44.
- 84.** Roy V. Autologous stem cell transplant for AL amyloidosis. *Bone Marrow Res.* 2012;2012:238961.
- 85.** Hwa YL, Kumar SK, Gertz MA, et al. Induction therapy pre-autologous stem cell transplantation in immunoglobulin light chain amyloidosis: a retrospective evaluation. *Am J Hematol.* 2016;91:984-988.
- 86.** Dispenzieri A, Seenithamby K, Lacy MQ, et al. Patients with immunoglobulin light chain amyloidosis undergoing autologous stem cell transplantation have superior outcomes compared with patients with multiple myeloma: a retrospective review from a tertiary referral center. *Bone Marrow Transplant.* 2013;48:1302-1307.
- 87.** National Comprehensive Cancer Network. Systemic light chain amyloidosis: NCCN Evidence Blocks™ v2. Accessed March 12, 2021. https://www.nccn.org/professionals/physician_gls/pdf/amyloidosis_blocks.pdf
- 88.** Kastritis E, Palladini G, Minnema MC, et al. Daratumumab-based treatment for immunoglobulin light-chain amyloidosis. *N Engl J Med.* 2021;385:46-58.
- 89.** Palladini G, Kastritis E, Maurer MS, et al. Daratumumab plus CyBorD for patients with newly diagnosed AL amyloidosis: safety run-in results of andromeda. *Blood.* 2020;136:71-80.
- 90.** Sidiqi MH, Gertz MA. Daratumumab for the treatment of AL amyloidosis. *Leuk Lymphoma.* 2019;60:295-301.
- 91.** Janssen Biotech Inc. Daralex Faspro® (daratumumab and hyaluronidase-fihj). Accessed February 5, 2021. <https://www.janssenlabels.com/package-insert/product-monograph/prescribing-information/DARZALEX+Faspro-pi.pdf>
- 92.** Rizio AA, White MK, McCausland KL, et al. Treatment tolerability in patients with immunoglobulin light-chain amyloidosis. *Am Health Drug Benefits.* 2018;11:430-437.
- 93.** Chakraborty R, Lentsch S. Emerging drugs for the treatment of light chain amyloidosis. *Expert Opin Emerg Drugs.* 2020;25:299-317.
- 94.** Cohen OC, Sharpley F, Gillmore JD, et al. Use of ixazomib, lenalidomide and dexamethasone in patients with relapsed amyloid light-chain amyloidosis. *Br J Haematol.* 2020;189:643-649.
- 95.** Lentsch S, Lagos GG, Comenzo RL, et al. Bendamustine with dexamethasone in relapsed/refractory systemic light-chain amyloidosis: results of a phase II study. *J Clin Oncol.* 2020;38:1455-1462.
- 96.** Dispenzieri A, Kastritis E, Wechalekar AD, et al. A randomized phase 3 study of ixazomib-dexamethasone versus physician's choice in relapsed or refractory AL amyloidosis. *Leukemia.* 2022;36:225-235.
- 97.** Ho AH, Kinter CW, Wight J, Neelam AR, Krakow D. Droxidopa as an effective treatment for refractory neurogenic orthostatic hypotension and reflex bradycardia in amyloid light-chain amyloidosis: a case report. *J Med Case Rep.* 2020;14:73.
- 98.** Ehsan H, Wahab A, Sana MK, et al. Updates on emerging therapies in cardiac light chain (AL) amyloidosis. *Blood.* 2020;136:39-41.
- 99.** Kaufman GP, Cerchione C. Beyond andromeda: improving therapy for light chain amyloidosis. *Front Oncol.* 2021;10:624573.
- 100.** Khouri J, Anwer F, Samaras CJ, et al. Safety, tolerability and efficacy of CAEL-101 in AL amyloidosis patients treated on a phase 2, open-label, dose selection study to evaluate the safety and tolerability of CAEL-101 in patients with AL amyloidosis. *Blood.* 2020;136:21.
- 101.** Valent J, Silowsky J, Kurman MR, et al. CAEL-101 is well-tolerated in AL amyloidosis patients receiving concomitant cyclophosphamide-bortezomib-dexamethasone (CyBorD): a phase 2 dose-finding study (NCT04304144). *Blood.* 2020;136:26-27.
- 102.** Palladini G, Milani P, Merlini G. Management of AL amyloidosis in 2020. *Hematology.* 2020;2020:363-371.
- 103.** Richards DB, Cookson LM, Barton SV, et al. Repeat doses of antibody to serum amyloid P component clear amyloid deposits in patients with systemic amyloidosis. *Sci Transl Med.* 2018;10:eaa3128.
- 104.** Hasib Sidiqi M, Gertz MA. Immunoglobulin light chain amyloidosis diagnosis and treatment algorithm 2021. *Blood Cancer J.* 2021;11:90.
- 105.** Itzhaki Ben Zadok O, Kornowski R. Cardiac care of patients with cardiac amyloidosis. *Acta Haematol.* 2020;143:343-351.
- 106.** Cuddy SAM, Bravo PE, Falk RH, et al. Improved quantification of cardiac amyloid burden in systemic light chain amyloidosis: redefining early disease? *J Am Coll Cardiol Img.* 2020;13:1325-1336.
- 107.** Solomon A, Weiss DT, Wall JS. Immunotherapy in systemic primary (AL) amyloidosis using amyloid-reactive monoclonal antibodies. *Cancer Biother Radiopharm.* 2003;18:853-860.
- 108.** Popkova T, Hajek R, Jelinek T. Monoclonal antibodies in the treatment of AL amyloidosis: co-targeting the plasma cell clone and amyloid deposits. *Br J Haematol.* 2020;189:228-238.
- 109.** Wall JS, Kennel SJ, Williams A, et al. AL amyloid imaging and therapy with a monoclonal antibody to a cryptic epitope on amyloid fibrils. *PLoS ONE.* 2012;7:e52686.
- 110.** Gertz MA, Landau H, Comenzo RL, et al. First-in-human phase I/II study of NEOD001 in patients with light chain amyloidosis and persistent organ dysfunction. *J Clin Oncol.* 2016;34:1097-1103.
- 111.** Gertz MA, Landau HJ, Weiss BM. Organ response in patients with AL amyloidosis treated with NEOD001, an amyloid-directed monoclonal antibody. *Am J Hematol.* 2016;91:E506-E508.
- 112.** O'Nuallain B, Allen A, Kennel SJ, Weiss DT, Solomon A, Wall JS. Localization of a conformational epitope common to non-native and fibrillar immunoglobulin light chains. *Biochemistry.* 2007;46:1240-1247.
- 113.** Solomon A, Weiss DT, Wall JS. Therapeutic potential of chimeric amyloid-reactive monoclonal antibody 11-1f4. *Clin Cancer Res.* 2003;9:3831s-3838s.
- 114.** Wall JS, Kennel SJ, Stuckey AC, et al. Radioimmunodetection of amyloid deposits in patients with AL amyloidosis. *Blood.* 2010;116:2241-2244.
- 115.** Hrcnc R, Wall J, Wolfenbarger DA, et al. Antibody-mediated resolution of light chain-associated amyloid deposits. *Am J Pathol.* 2000;157:1239-1246.
- 116.** Wall JS, Kennel SJ, Paulus M, et al. Radioimaging of light chain amyloid with a fibril-reactive monoclonal antibody. *J Nucl Med.* 2006;47:2016-2024.
- 117.** Edwards CV, Bhutani D, Mapara M, et al. One year follow up analysis of the phase 1a/b study of chimeric fibril-reactive monoclonal antibody 11-1f4 in patients with AL amyloidosis. *Amyloid.* 2019;26:115-116.
- 118.** Edwards CV, Gould J, Langer AL, et al. Interim analysis of the phase 1a/b study of chimeric fibril-reactive monoclonal antibody 11-1f4 in patients with AL amyloidosis. *Amyloid.* 2017;24:58-59.
- 119.** Bézard M, Oghina S, Vitiello D, et al. Dexamethasone is associated with early deaths in light chain amyloidosis patients with severe cardiac involvement. *PLoS ONE.* 2021;16:e0257189.
- 120.** Le Bras F, Molinier-Frenkel V, Guellich A, et al. Sequential cyclophosphamide-bortezomib-dexamethasone unmasks the harmful cardiac effect of dexamethasone in primary light-chain cardiac amyloidosis. *Eur J Cancer.* 2017;76:183-187.
- 121.** Liu B, Wang Y, Bai M, et al. Cyclophosphamide + thalidomide + dexamethasone versus melphalan + dexamethasone for the treatment of amyloid light-chain amyloidosis with kidney involvement: a retrospective study in Chinese patients. *Clin Ther.* 2019;41:1186-1198.
- 122.** Sharpley FA, Manwani R, Petrie A, et al. Autologous stem cell transplantation vs bortezomib based chemotherapy for the first-line treatment of systemic light chain amyloidosis in the UK. *Eur J Haematol.* 2021;106:537-545.
- 123.** Ravichandran S, Cohen OC, Law S, et al. Impact of early response on outcomes in AL amyloidosis following treatment with frontline bortezomib. *Blood Cancer J.* 2021;11:118.
- 124.** Cohen OC, Wechalekar AD. Systemic amyloidosis: moving into the spotlight. *Leukemia.* 2020;34:1215-1228.
- 125.** Chung A, Kaufman GP, Sidana S, et al. Organ responses with daratumumab therapy in previously treated AL amyloidosis. *Blood Adv.* 2020;4:458-466.
- 126.** Sancharawala V, Sarosiek S, Schulman A, et al. Safety, tolerability, and response rates of daratumumab in relapsed AL amyloidosis: results of a phase 2 study. *Blood.* 2020;135:1541-1547.
- 127.** Cohen AD, Comenzo RL. Systemic light-chain amyloidosis: advances in diagnosis, prognosis, and therapy. *Hematology Am Soc Hematol Educ Program.* 2010;2010:287-294.
- 128.** Kastritis E, Dimopoulos MA. Recent advances in the management of AL amyloidosis. *Br J Haematol.* 2016;172:170-186.
- 129.** Basset M, Kimmich CR, Schreck N, et al. Lenalidomide and dexamethasone in relapsed/refractory immunoglobulin light chain (AL)

amyloidosis: results from a large cohort of patients with long follow-up. *Br J Haematol*. 2021;195:230-243.

130. Milani P, Palladini G. Conventional therapy for amyloid light-chain amyloidosis. *Acta Haematologica*. 2020;143:365-372.

131. Premkumar VJ, Lentzsch S, Pan S, et al. Venetoclax induces deep hematologic remissions in t(11;14) relapsed/refractory AL amyloidosis. *Blood Cancer J*. 2021;11:10.

132. Cibeira MT, Ortiz-Pérez JT, Quintana LF, Fernández de Larrea C, Tovar N, Bladé J. Supportive care in AL amyloidosis. *Acta Haematologica*. 2020;143:335-342.

133. Wong SW, Fogaren T. Supportive care for patients with systemic light chain amyloidosis. *Hematol Oncol Clin North Am*. 2020;34:1177-1191.

134. Amyloidosis Research Consortium. Guidance for industry: AL amyloidosis—developing drugs for treatment. Accessed December 14, 2020. <https://www.fda.gov/oc/industry-guidance-for-treatment-of-al-amyloidosis-developing-drugs-for-treatment-12-16.pdf>

135. Muchtart E, Dispenzieri A, Leung N, et al. Depth of organ response in AL amyloidosis is associated with improved survival: grading the organ response criteria. *Leukemia*. 2018;32:2240-2249.

136. Giannitsi S, Bougiakli M, Bechlioulis A, Kotsia A, Michalis LK, Naka KK. 6-Minute walking test: a useful tool in the management of heart failure patients. *Ther Adv Cardiovasc Dis*. 2019;13:1753944719870084.

137. Bayliss M, Quock TP, Guthrie SD, White MK, McCausland KL. Longitudinal associations between health-related quality of life and healthcare

utilization in AL amyloidosis. *Haematologica*. 2017;102:599-600.

138. Santhorawala V, Palladini G, Minnema MC, et al. Health-related quality of life in patients with AL amyloidosis treated with daratumumab, bortezomib, cyclophosphamide, and dexamethasone: results from the phase 3 Andromeda study. *Blood*. 2020;136:37-40.

139. McCausland KL, Quock TP, Rizio AA, et al. Cardiac biomarkers and health-related quality of life in patients with light chain (AL) amyloidosis. *Br J Haematol*. 2019;185:998-1001.

140. Jay CL, Butt Z, Ladner DP, Skaro AL, Abecassis MM. A review of quality of life instruments used in liver transplantation. *J Hepatol*. 2009;51:949-959.

141. Zazzeroni L, Pasquinelli G, Nanni E, Cremonini V, Rubbi I. Comparison of quality of life in patients undergoing hemodialysis and peritoneal dialysis: a systematic review and meta-analysis. *Kidney Blood Press Res*. 2017;42:717-727.

142. Hwang IC, Koh Y, Park JB, et al. Time trajectory of cardiac function and its relation with survival in patients with light-chain cardiac amyloidosis. *Eur Heart J Cardiovasc Imaging*. 2021;22:459-469.

143. Lei C, Zhu X, Hsi DH, et al. Predictors of cardiac involvement and survival in patients with primary systemic light-chain amyloidosis: roles of the clinical, chemical, and 3-D speckle tracking echocardiography parameters. *BMC Cardiovasc Disord*. 2021;21:43.

144. Nahhas O, Chuy KL, Yang JC, et al. Incremental value of GLS for classification of prognosis in patients with advanced light chain

(AL) amyloidosis. *J Am Coll Cardiol*. 2020;75:1006.

145. Chuy KL, Drill E, Yang JC, et al. Incremental value of global longitudinal strain for predicting survival in patients with advanced AL amyloidosis. *J Am Coll Cardiol CardioOnc*. 2020;2:223-231.

146. Ehman EC, El-Sady MS, Kijewski MF, et al. Early detection of multiorgan light-chain amyloidosis by whole-body ¹⁸F-florbetapir PET/CT. *J Nucl Med*. 2019;60:1234-1239.

147. Khor YM, Cuddy S, Harms HJ, et al. Quantitative [¹⁸F]florbetapir PET/CT may identify lung involvement in patients with systemic AL amyloidosis. *Eur J Nucl Med Mol Imaging*. 2020;47:1998-2009.

148. Santarelli MF, Genovesi D, Positano V, et al. Deep-learning-based cardiac amyloidosis classification from early acquired PET images. *Int J Cardiovasc Imaging*. 2021;37:2327-2335.

149. Santarelli MF, Genovesi D, Scipioni M, et al. Cardiac amyloidosis characterization by kinetic model fitting on [¹⁸F]florbetaben PET images. *J Nucl Cardiol*. 2021;29:1919-1932.

150. Santarelli MF, Scipioni M, Genovesi D, Giorgetti A, Marzullo P, Landini L. Imaging techniques as an aid in the early detection of cardiac amyloidosis. *Curr Pharm Des*. 2021;27:1878-1889.

151. Seo M, Cha HJ, Kim M, et al. Clinical utility of ¹⁸F-florbetaben PET for detecting amyloidosis associated with multiple myeloma: a prospective case-control study. *Clin Nucl Med*. 2019;44:e503-e509.

KEY WORDS AL amyloidosis, awareness, diagnosis, future therapies