

A video of this technique is available online.

Open camera or QR reader and scan code to access this article and other resources online.



SURGICAL PEARLS

Aesthetic

Ultrasound-Guided Temple Filler Injection

Stella Desyatnikova, MD*

Abstract

Temple filler volumization can significantly improve facial balance and appearance, but has significant risks, including contour irregularities, vascular occlusion, skin necrosis, hair loss, blindness, stroke, and nonthrombotic pulmonary embolism. To improve the safety and precision of temple volumization, we have introduced ultrasound-guided injections of hyaluronic acid filler. We use the interfascial space as a target for our filler placement. We review relevant anatomy, including figures, describe a technique of ultrasound-guided filler injection in the interfascial plane with real-time visualization of the cannula and filler deposition, and include a detailed video of the procedure.

Introduction

Temple filler volumization can significantly improve facial balance and appearance. Unfortunately, the treatment has significant risks, including contour irregularities, vascular occlusion, skin necrosis, hair loss, blindness, stroke, and nonthrombotic pulmonary embolism.^{1,2} To mitigate these risks and optimize the aesthetic result, several methods and anatomic targets of injection have been described, such as suprapariosteal, interfascial, and subcutaneous.³⁻⁵

The interfascial space offers the benefit of using less filler than deep injections, and lower risk of surface irregularities than subcutaneous injections, but accessing it with a cannula or needle may be precarious.^{4,5}

We describe a technique of ultrasound-guided hyaluronic acid (HA) filler injection in the interfascial plane, with real-time visualization of the cannula and filler deposition (Supplementary Video S1).

Surgical Technique

We use a linear ultrasound transducer with a medium size footplate (L4-20t-RS, GE Healthcare), 23 mg/g pre-

served network technology HA gel, and a 22-gauge 50 mm cannula. After proper ergonomic alignment of the operator, the patient, and the monitor, a preliminary ultrasound scan of the area is performed to assess the anatomy and presence of prior filler.

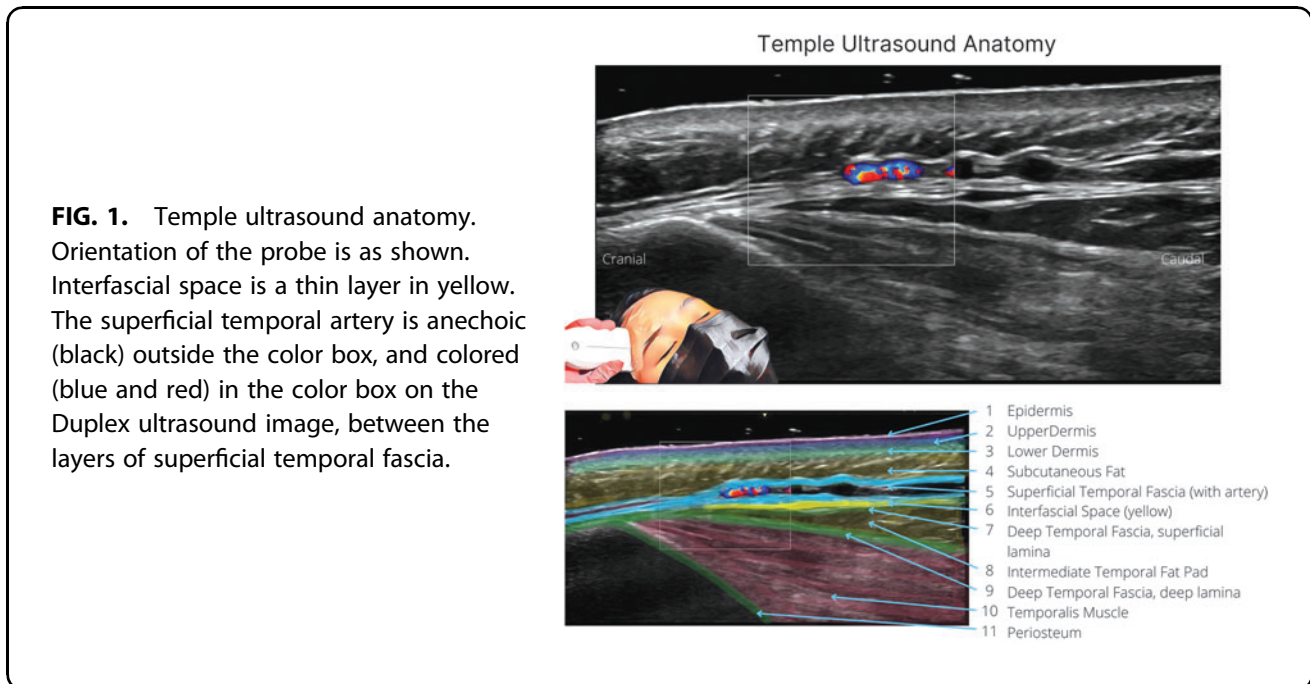
A pilot hole for the cannula is made using a 21-gauge needle over the posterior third of the zygomatic arch, to avoid the temporal facial nerve branch. Inferior approach from the zygomatic arch with a longer cannula allows us to reach the upper temporal space, and to extend into the retro-orbicularis oculi fat (ROOF) for additional brow lift and the lateral orbital rim contouring, if necessary.

The cannula is placed through the skin and superficial temporal fascia using gentle pressure. It is then advanced superomedially along the deep temporal fascia. Sterile ultrasound gel is placed on the temple, and the transducer is positioned in-plane, orienting the long axis of the footplate along the cannula. A large amount of gel and light pressure on the transducer are necessary for adequate visualization and to prevent vascular compression. Duplex ultrasound (combination of the B-mode and color Doppler) is used to visualize the tissue layers, blood vessels, and the

Facial Plastic Surgery, The Stella Center, Seattle, Washington, USA.

*Address correspondence to: Stella Desyatnikova, MD, Facial Plastic Surgery, The Stella Center, Seattle, WA 98101, USA, Email: stella@doctorstella.com

© Stella Desyatnikova. 2022; Published by Mary Ann Liebert, Inc. This Open Access article is distributed under the terms of the Creative Commons Attribution Noncommercial License [CC-BY-NC] (<http://creativecommons.org/licenses/by-nc/4.0/>) which permits any noncommercial use, distribution, and reproduction in any medium, provided the original author(s) and the source are cited.



hyperechoic (white) cannula. If the cannula and, especially, the tip are not seen, gentle sliding and rotating transducer movements help to locate the cannula and confirm placement in the proper plane, away from blood vessels.

The interfascial space is a thin plane between the deep and superficial temporal fascia layers (Fig. 1), containing loose connective tissue, not easily seen on ultrasound; therefore, a small amount of filler is injected to confirm proper cannula placement. Anechoic (black) filler is easily seen between the two hyperechoic (white) fascial layers. Additional filler is then injected in linear retrograde or anterograde manner, sliding the cannula over the deep temporal fascia, and observing expansion of this space and elevation of the superficial temporal fascia on the monitor in real time (Supplementary Video S1). Changes in relative and absolute thickness of the interfascial space serve as a proxy for predicting the aesthetic outcome.

The cannula then is reoriented in a fanning manner, and the transducer is readjusted. Another linear thread of filler is injected, and the procedure continues until the interfascial space is properly volumized, usually with 0.5–1.0 mL of HA filler per side.

Occasionally the cannula needs to be advanced cranially through the inferior temporal septum to volumize the upper temporal space. It can also be further advanced across the temporal line to volumize the ROOF, with real-time monitoring.

The transducer is then removed, the cannula is withdrawn, and the ultrasound gel is wiped clean to properly assess the three-dimensional aesthetic effect of filler. Gentle massage of the area helps to spread any irregularities. Figure 2 shows the results and ultrasound appearance after 1 month.

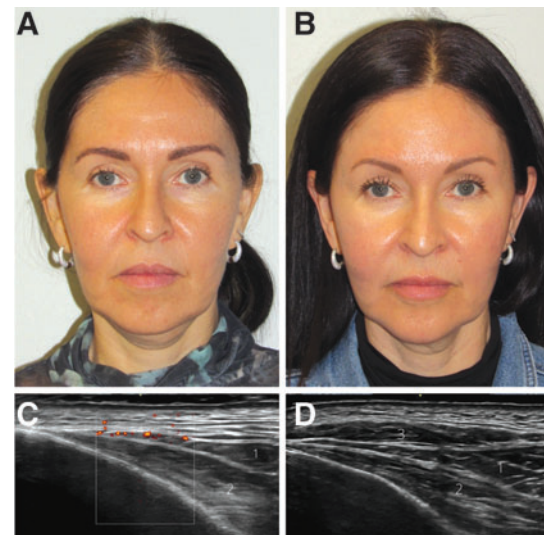


FIG. 2. A 48-year-old patient. Hyaluronic acid filler 1.0 mL was injected to each temporal fossa. **(A)** Preoperative front view. **(B)** Postoperative front view after 1 month.

(C) Preoperative ultrasound image of the temporal fossa. **(D)** Postoperative ultrasound image of the temporal fossa after 1 month. Anechoic (black) filler in the interfascial space, with visible septations of the loose connective tissue. Structures on ultrasound images:

1. Intermediate temporal fat pad
2. Temporalis muscle
3. Filler in the interfascial space

Discussion

Traditionally ultrasound-guided techniques position the needle or cannula tip in the proper spot and keep it stationary for injecting a bolus of medication. Ultrasound use for temple volumization has been previously described in a similar manner by Kadouch et al⁶ for fat injections in the supraperiosteal and subcutaneous plane, and by Lee et al⁵ for HA filler injection in the interfascial plane.

We expand on this technique by using linear threads and fanning injection techniques, following the cannula with the transducer, and assessing the aesthetic result through real-time monitoring of the interfascial plane expansion. Linear threads of filler can frequently provide a better aesthetic result than bolus injections, and we describe how this is done under ultrasound guidance. In addition, despite the dictum of only moving the transducer or the probe at once, we find that the temple area is amenable to sliding both simultaneously, if necessary.

The disadvantages of the described method include the need for specialized equipment, and experience with ultrasound-guided injections and cannula use. However, after gaining expertise, this technique allows for an unparalleled level of safety and precision of filler placement.

Author Disclosure Statement

No competing financial interests exist.

Funding Information

No funding was received for this article.

Supplementary Material

Supplementary Video S1

References

1. Wang HC, Yu N, Wang X, et al. Cerebral embolism as a result of facial filler injections: A literature review. *Aesthet Surg J* 2022;42(3):NP162–NP175; doi: 10.1093/asj/sjab193.
2. Kapoor KM, Bertossi D, Li CQ, et al. A systematic literature review of the middle temporal vein anatomy: 'Venous danger zone' in temporal fossa for filler injections. *Aesthetic Plast Surg* 2020;44(5):1803–1810; doi: 10.1007/s00266-020-01791-2.
3. Cotofana S, Gaete A, Hernandez CA, et al. The six different injection techniques for the temple relevant for soft tissue filler augmentation procedures—Clinical anatomy and danger zones. *J Cosmet Dermatol* 2020;19(7):1570–1579; doi: 10.1111/jocd.13491.
4. Cohn JE, Pion T, Greco TM. "Not above, not below: Right in the middle!"—Novel filler technique for temporal augmentation and rejuvenation. *Facial Plast Surg* 2020;36(5):623–627; doi: 10.1055/s-0040-1709710.
5. Lee W, Park JW, Yang EJ. Temple augmentation by injecting a hyaluronic acid filler between the superficial and deep temporal fasciae. *J Cosmet Dermatol* 2022.
6. Kadouch J, Schelke LW, Swift A. Ultrasound to improve the safety and efficacy of lipofilling of the temples. *Aesthet Surg J* 2021;41(5):603–612; doi: 10.1093/asj/sjaa066.