



Application of Machine Learning and Deep Learning Techniques for COVID-19 Screening Using Radiological Imaging: A Comprehensive Review

Asifuzzaman Lasker¹ · Sk Md Obaidullah¹ · Chandan Chakraborty² · Kaushik Roy³

Received: 22 January 2022 / Accepted: 18 October 2022 / Published online: 24 November 2022
© The Author(s), under exclusive licence to Springer Nature Singapore Pte Ltd 2022

Abstract

Lung, being one of the most important organs in human body, is often affected by various SARS diseases, among which COVID-19 has been found to be the most fatal disease in recent times. In fact, SARS-COVID 19 led to pandemic that spreads fast among the community causing respiratory problems. Under such situation, radiological imaging-based screening [mostly chest X-ray and computer tomography (CT) modalities] has been performed for rapid screening of the disease as it is a non-invasive approach. Due to scarcity of physician/chest specialist/expert doctors, technology-enabled disease screening techniques have been developed by several researchers with the help of artificial intelligence and machine learning (AI/ML). It can be remarkably observed that the researchers have introduced several AI/ML/DL (deep learning) algorithms for computer-assisted detection of COVID-19 using chest X-ray and CT images. In this paper, a comprehensive review has been conducted to summarize the works related to applications of AI/ML/DL for diagnostic prediction of COVID-19, mainly using X-ray and CT images. Following the PRISMA guidelines, total 265 articles have been selected out of 1715 published articles till the third quarter of 2021. Furthermore, this review summarizes and compares varieties of ML/DL techniques, various datasets, and their results using X-ray and CT imaging. A detailed discussion has been made on the novelty of the published works, along with advantages and limitations.

Keywords COVID-19 · X-ray · CT · Radiological imaging · Machine learning · Deep learning

Asifuzzaman Lasker, Sk Md Obaidullah and Chandan Chakraborty have contributed equally.

✉ Kaushik Roy
kaushik.mrg@gmail.com

Asifuzzaman Lasker
asifuzzaman.lasker@gmail.com

Sk Md Obaidullah
sk.obaidullah@gmail.com

Chandan Chakraborty
chakraborty.nittrk@gmail.com

¹ Department of Computer Science & Engineering, Aliah University, Kolkata, India

² Department of Computer Science & Engineering, National Institute of Technical Teachers' Training & Research Kolkata, Kolkata, India

³ Department of Computer Science, West Bengal State University, Barasat, India

Introduction

The world is anxious about a submicroscopic agent known as the coronavirus. Before the declaration of COVID-19 by the WHO in February 2020, the old virus belonged to severe acute respiratory syndrome coronavirus 2 (SARS-CoV-2). COVID-19 is a zoonotic virus that is positive and mono-stranded RNA. It has four main structural proteins: the spike protein, the envelope protein, the membrane protein, and the nucleocapsid protein [1]. It is a highly infectious virus spread by aerosol and respiratory droplets [2]. Initially, there were no significant clinical symptoms when first infected by COVID-19. However, gradually the general symptoms became more severe for those who do not have a better immune system, especially aged people. In such a crucial situation, fast, reliable, and sensitive testing is required. In that place, RT-PCR plays a vital role in identifying COVID-19 suspects within a few days or hours [3, 4].

Coronaviruses belong to the Coronaviridae family, and their virion architecture resembles that of a crown when seen under an electron microscope. In December 2019, a novel coronavirus was identified in Wuhan, China, that could potentially infect humans (2019 novel coronavirus) [5]. SARS-CoV-2 (severe acute respiratory syndrome coronavirus) was named by the International Committee on Virus Taxonomy (ICTV) on February 11, 2020, based on its genetic relationship to the coronavirus responsible for the SARS outbreak in 2002–2003 [6]. It differs from past coronavirus outbreaks, such as the SARS coronavirus in 2002–2003 and the Middle East respiratory syndrome (MERS) coronavirus in 2012. The transmission rates of these viruses are extremely fast [5]. COVID-19 is highly infectious because it contains spike glycoprotein in its outer envelope. A unique amino acid stretch in the spike protein of the coronavirus SARS-CoV-2 is located in the S1/S2 region. It is speculated that this region is responsible for viral pathogenicity and transmissibility. After infection, the glycoprotein binds to the ACE-II receptor protein of the human airway tract. Most of SARS-CoV-2 patients have shown a spectrum of symptoms, ranging from mild flu-like symptoms to high fever. The WHO (World Health Organization) officially designated the disease associated with this virus as COVID-19 in the International Classification of Diseases (ICD) [6]. The emergence of COVID-19 has resulted in millions of deaths, industries' destruction, and economies' collapse [7, 8].

Tests are one of the most challenging aspects of identifying COVID-19. A patient infected with COVID-19 can be identified and treated with a list of contacts who need to be found and quarantined to prevent transmission. Therefore, the initial screening and quarantine of COVID-19 patients can save many lives. RT-PCR (real-time reverse

transcriptase-polymerase chain reaction) is the most confirmatory test for diagnosing this type of virus [9]. RT-PCR testing is insufficient to manage this pandemic because preparing RT-PCR testing kits takes time. Radiographic images are alternative diagnostic tools for the identification of lung disease. But one disadvantage of radiographic images is that an expert doctor is required to identify the infected region in the lung.

This solution also required time and an expert doctor. Expert doctors are rare compared to the number of patients in this case. Thus, healthcare experts are searching for the fastest and most automated way to detect COVID-19 disease. Therefore, AI/ML can provide support using radiographic images in parallel with traditional methods. It is possible for doctors to analyze X-rays and CT scans more quickly and efficiently by integrating AI/ML techniques.

ML and DL have added value in detecting various lung diseases [10, 11] with higher accuracy and efficiency. It is well-known that radiological imaging, mainly X-ray and CT, helps in predicting the disease signature in a non-invasive way. From this point of view, X-ray imaging is the safest and most readily available diagnostic tool for COVID-19 like other diseases. On the other side, CT provides a high-resolution image with more prominent microstructural information related to lung damage. Here, Fig. 1 shows about how ML/DL can effectively identify lung image samples such as normal, COVID-19, and different types of pneumonia by automatically analyzing CT and X-ray images [12, 13]. Deep learning, a type of machine learning, integrates concepts of artificial neural networks (ANN) [17] as a result of substantial advancements in radiology imaging technology [14, 15]. DL and ML assist healthcare experts with the tracing, controlling, and managing of COVID-19 cases within quarantined periods through the use of mobile devices.

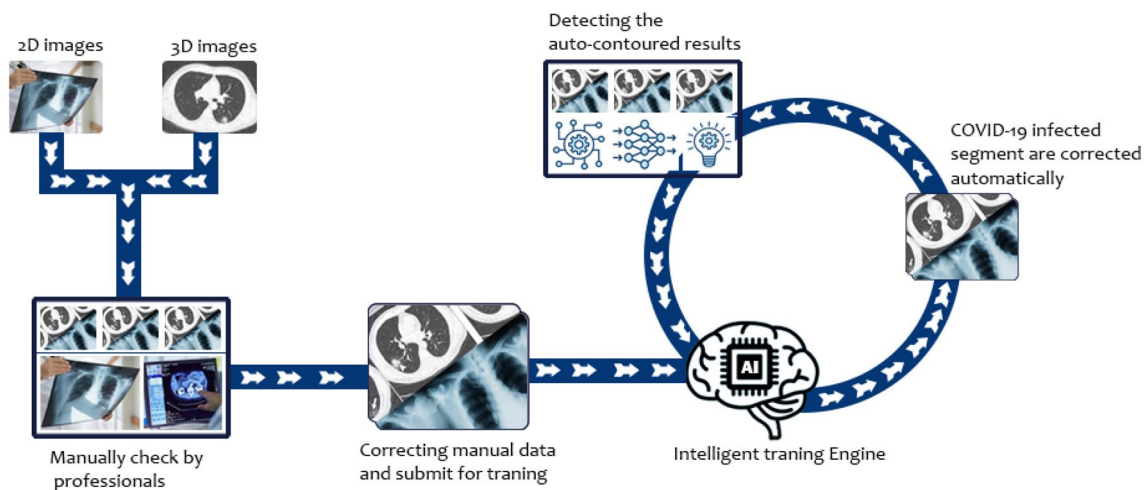


Fig. 1 General flow of an AI system for detecting infected segments and training the model accordingly

Using LSTM (long short-term memory) [16], the susceptible–exposed–infected–recovered (SEIR) epidemiological model is used to estimate the COVID-19 peaks accurately. The method utilizes time series data to conduct the analysis.

To potentially reduce the transmission of COVID-19, strategies such as patient quarantine, contact tracing, and positive counseling were used [18, 19]. Supporting an essential technology data network through a terminal tracking system and data transfer to improve urban management may also improve viral detection efficacy and forecast the location of the next epidemic [20]. The researchers applied a bidirectional gated recurrent unit (GRU) and attentional techniques to predict tachypnea, which might be a first-order diagnostic feature for COVID-19 screening [21]. IoT connects different networking gadgets in today's environment, giving people comfort and simplicity of living [22]. As new technological advances are made, the Internet of things (IoT) provides us with intelligent solutions based on X-ray images [23]. These solutions will range from IoT-based industrial development of ventilation systems, masks, and other medical devices to safely tracking patient conditions in hospitals or self-isolation at home, designing new passive, privacy-preserving contact-tracing techniques, and diagnosing IoT and cell-phone data collection and analytics-based COVID-19 conditions [24].

Many of those vaccinations, if they are active at all, may not be able to elicit an immunological response in some populations. The effects of vaccination may vary among people due to the different reactions of their bodies to the elements in vaccines that activate virus-fighting T cells. There is a major part to the vaccination puzzle that goes beyond how many people have received a vaccine, but also how many will mount an immune response in the future [22]. AI might be used to build a platform that analyses clinical and immunological data automatically and effectively using the supervised classification model-based Vaxign reverse vaccinology machine learning platform for COVID-19. Other responsive approaches like artificial neural networks (ANN), convolutional neural networks (CNN), deep generative neural networks (DGNN), and other responsive approaches are used.

The primary objective of this paper is to discuss current advances in ML/DL-based diagnostic systems that use radiographic images such as X-rays, CTs, MRIs, and ultrasound. This study focuses on summarizing various databases used and class sizes, ML and DL algorithms, and customized CNN frameworks. Here, 36 customized solutions using CNN methods having their unique architectural patterns have been reported.

For better readability, the paper is organized as follows: “Introduction” Section describes the introduction of the paper. “X-Ray and CT imaging modality” Section will demonstrate various medical imaging modalities and their advantages and disadvantages, as well as digital image processing.

“Available benchmark datasets” Section represents various manifestations of different imaging modalities. “Reported works” Section discusses reported work from the perspective of ML/DL using various classifiers and architectures. In “Discussion” Section, X-rays and CT imaging modalities are discussed along with their challenges and solutions. An overview of future directions and a conclusion are included.

To start with the notion of understanding the COVID-19 disease, it is worthwhile to know about the verities of clinical symptoms and its impact on disease severity, as discussed below.

Clinical Symptoms of COVID-19

There are no major symptoms associated with COVID-19, but it is a very serious condition that starts with minor symptoms. The twenty-first-century human society is confronted with a potentially fatal disease with numerous symptoms [25]. Patients can be separated into mild, moderate, extreme, and seriously ill stages depending on the progression of their illness [26, 27]. The condition has significant and harmful implications for the lungs as a whole. Fever, cough, shortness of breath, body pain, and fatigue are among the disease's most frequent fourteen clinical signs [28] in statistical analysis [29]. These patients' clinical care and effectiveness were recorded, with information on ICU assistance and length of stay, respiratory oxygen time, sputum NAT-positive time, health center stay time, and outcome in terms of full recovery, partial recovery with residual pulmonary injury, delayed recovery, and death gathered [30].

Figure 2 depicts different symptoms at different stages. A significant percentage of COVID-19 patients recover early with few generic symptoms. Moderate symptoms may not need hospitalization, but severe health concerns, such as muscle pain and a chronic cough, should be examined by a physician. Approximately 5% of patients require urgent hospitalization and oxygen support. Using demographic data with the assistance of machines and deep learning, researchers can make diverse predictions from multiple perspectives [31]. In clinical diagnostics, early signs based on machine learning lowered mortality risk [32].

Systematic Review Strategy

This systematic literature review used the Preferred Reporting Items for Systematic Reviews and Meta-Analyses (PRISMA) procedure for its preparation and reporting [33]. In Fig. 3, we go over the whole PRISMA analysis.

Search and Selection Strategy for Relevant Articles

We systematically searched the databases to identify COVID-19 using computer-based intelligent algorithms.

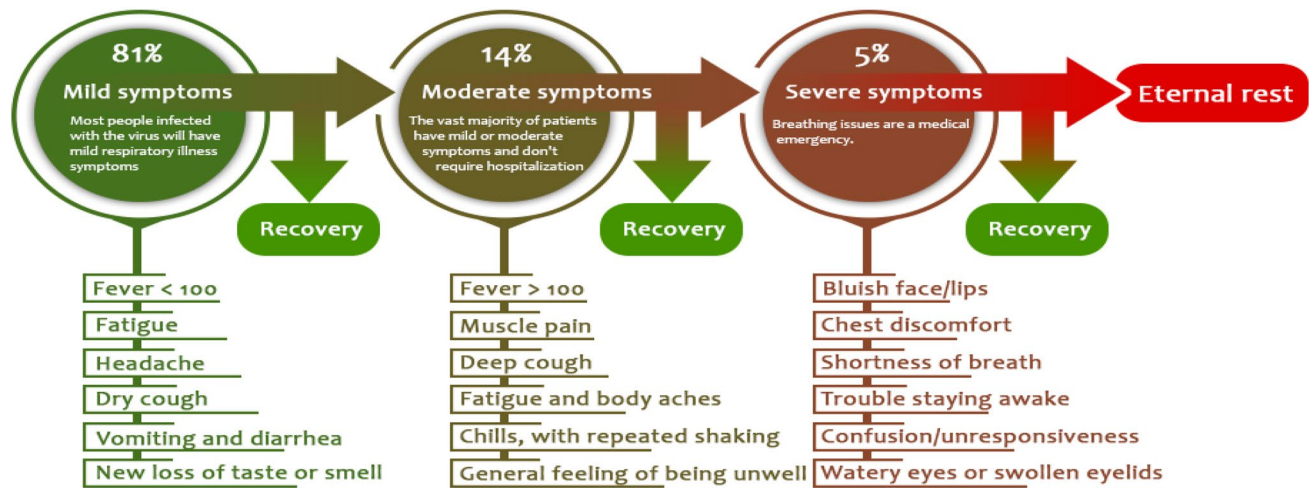


Fig. 2 Based on the severity of symptoms, the percentage share among COVID-19 infected patients

For this purpose, we consider basically five full-text digital repositories, including Google Scholar, PubMed, DBLP and Scopus. Between November 1, 2020, and September 15, 2021, PubMed systematically searched for peer-reviewed publications written in English. Several queries were used to enhance the search-related quality of various deep and machine learning approaches for detecting COVID-19. The following were some of the most important search terms used to get data: “COVID-19 screening”, “machine learning”, “deep learning”, “X-ray using machine learning”, “X-ray using deep learning”, “CT using machine learning”, “CT using deep learning”, and “X-ray and CT using deep and machine learning”. These phrases were discovered in the titles, abstracts, and keywords of published publications. Furthermore, only original research publications relating to the identification of COVID-19 using ML/DL methods were included in the collection.

Inclusion–Exclusion Criteria

The articles were chosen based on the following inclusion criteria: (1) Research that used deep and machine learning for predicting COVID-19. (2) Several deep learning algorithms for COVID-19. (3) Transfer learning applied to a limited amount of data. (4) Different classifiers of machine learning algorithms. (5) Several image modalities for the chest.

The following studies were not included in the analysis: (1) Research that does not combine machine and deep learning with X-ray, CT, and other image modalities. (2) The classification methods of different lung diseases are

not well described. (3) Articles that only use segmentation techniques without describing classification methods.

Data Segregation and Categorization

Based on two of the most common imaging modalities, the data were extracted and classified into four sections: X-ray images, CT images, machine learning classifiers, and deep learning comprehensive models. The CT and X-ray images analyzed in this research belong to distinct categories. However, it should be noted that the COVID-19 images are a common element among all of the datasets. Two other significant findings in a research paper are segmentation and transfer learning.

This comprehensive review study looks at some COVID-19 detection techniques that use machine learning and deep learning to help clinicians and doctors rapidly identify COVID-19 patients. We looked at chest X-ray and CT, a hybrid-COVID-19 network, and other deep learning methods.

X-Ray and CT Imaging Modality

Medical imaging is the practice of generating transparent representations of internal body structures for biomedical and therapeutic analysis and care, as well as a visual view of the role of internal tissues. The purpose of this treatment is to recognize and cure the condition [34]. This procedure creates a database of the organs' normal structure and function, making anomalies easier to spot [35]. This spotting can be achieved using a series of imaging tests, including X-ray,

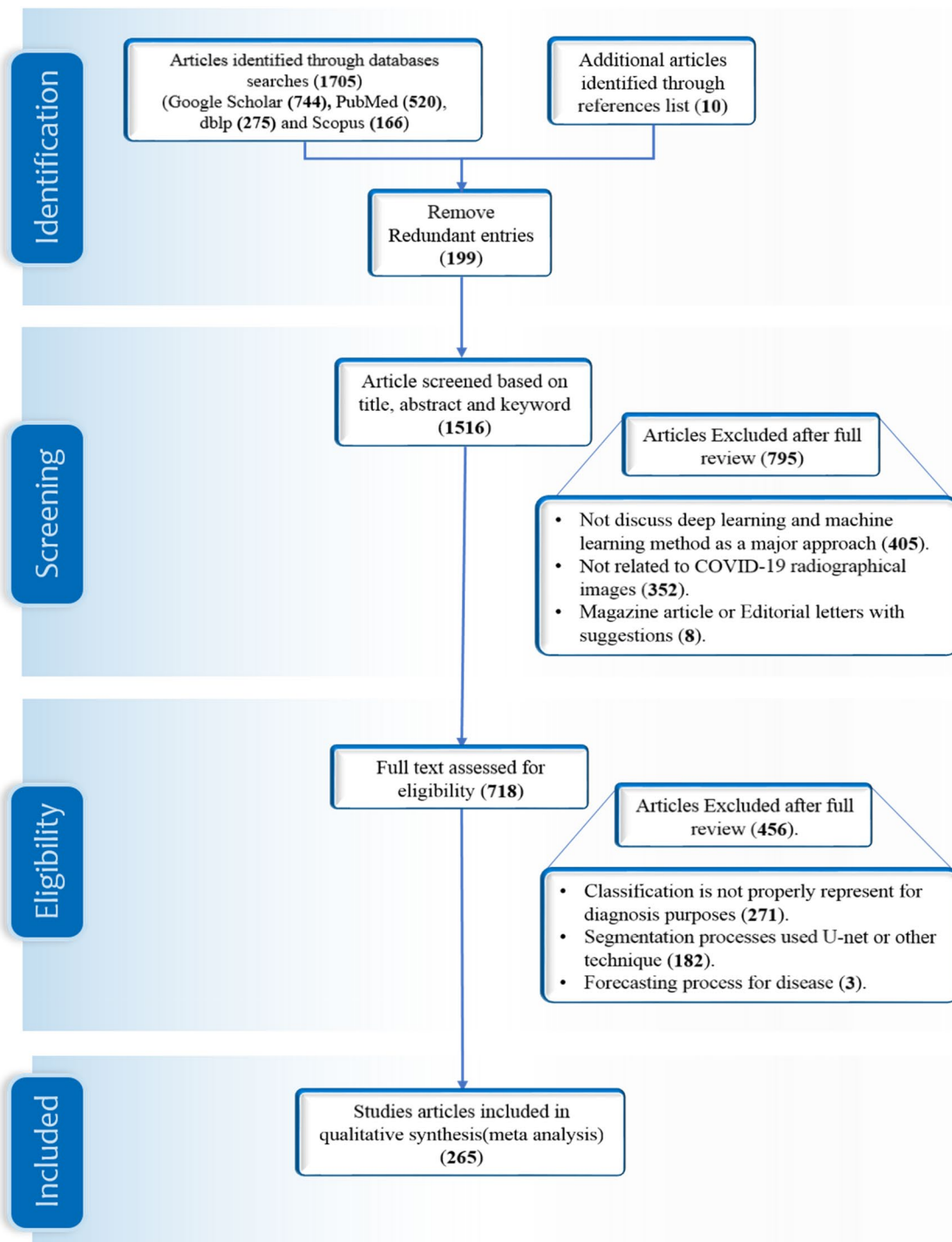


Fig. 3 A four-phase search and selection strategy for a systematic review based on keywords published papers excluded or included in the review

MRI, ultrasound, CT, mammography, nuclear medicine, fluoroscopy, bone mineral densitometry, and PET scan [36].

We are trying to represent a very informative comparison and contrast for medical image capture tools. Figure 4 shows those machines' brief overview and important parameters, which is very helpful for selecting machines according to

patient conditions. Each section is divided into four different parts according to several imaging tool parameters. Here, yellow boxes indicate radiation exposure, while blue boxes represent the cost of different machines to capture a single image. Green boxes represent the time it takes to generate

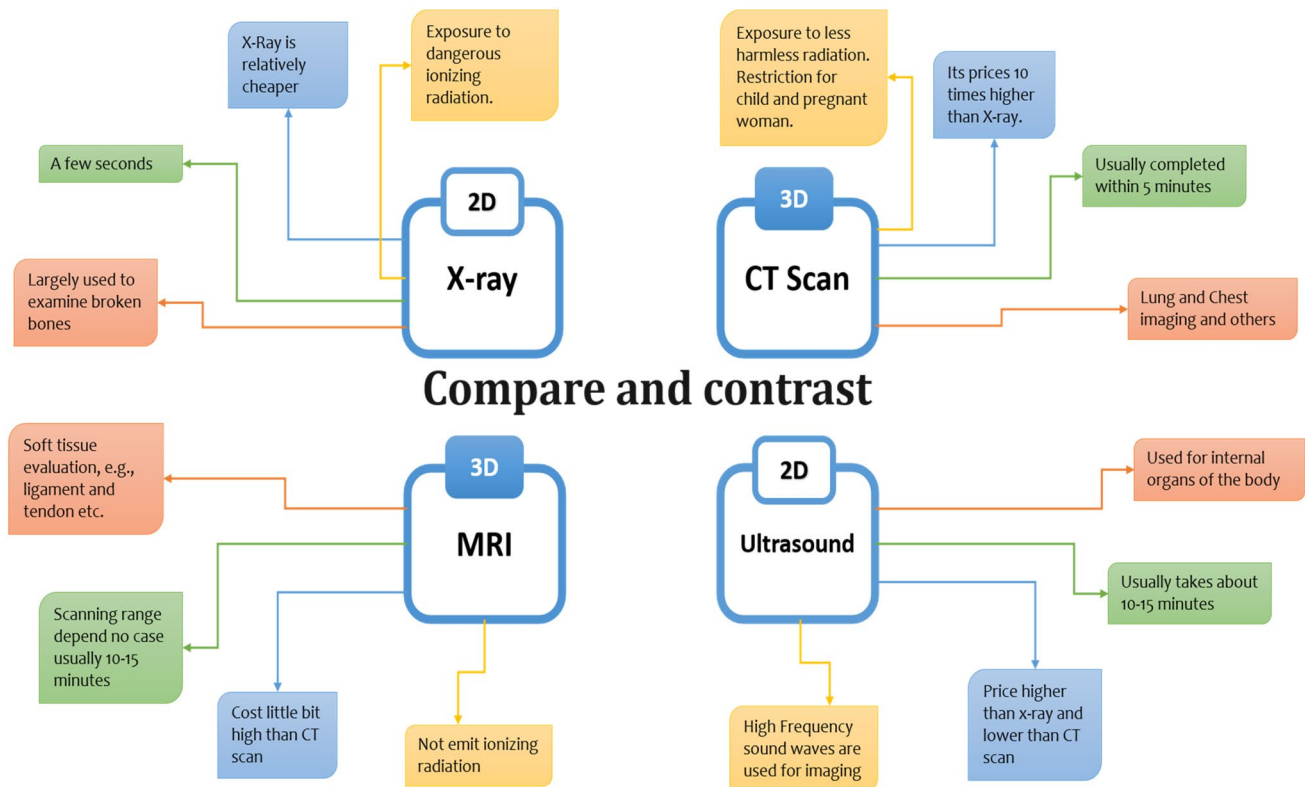


Fig. 4 Compare and contrast a variety of medical imaging instruments based on four criteria: radiation exposure, processing cost, image processing time, and appropriate organ for scanning [37]

a single image, and red boxes show the suitable targeted organs for a better image.

A CT scan provides a three-dimensional image with a detailed view of the lungs and soft tissues [38], whereas other medical imaging devices do not produce that high-quality image. It is more time saving and higher sensitivity than other radiological images [39]. Compared to X-ray-based assessment, CT provides a better diagnostic scope because of its clear visibility into organ tissues. But one of the significant drawbacks of CT scans is that different age groups and issues require different radiation doses [40].

Medical Image Preprocessing for Classification

After being collected from various medical devices, sample images must be enhanced. The most common image processing techniques include calibration, filter optimization, transformation, and registration [41]. There are 71 characteristics that may be examined to process images for analysis [42], but 3 significant features must be extracted. Those critical features are pixel-based, edge-based, and texture-based features [43]. Y. Wan shows more extracted features from differing perspectives [44]. Image segmentation based on characteristics is a significant step in medical image processing, and it contributes to the method of

applying biological identifiers to image pixels [45, 46]. The main three image segmentation methods for biological purposes are pixel base, geometry base, and others [47]. A segmentation-based approach identifies three challenges: network design, training, and data [43]. A. Voulodimos [49] and A. Saood [50] describe a very efficient segmentation algorithm for the segmenting process of medical images.

Follow these four procedures in Fig. 5 to automatically classify COVID-19 using a segmentation algorithm and lung-based infections [51–53]. Medical image segmentation is useful for detecting sick regions and conducting further in-depth analysis [54, 55]. Image segmentation may be done on both two-dimensional [56–58] and three-dimensional [59] images. Most of the segmentation processes are done by the three-dimensional or CT images. Image conversion is necessary before a computer can understand it. The non-digital image needs to be converted to digital form and sent to the image processor for feature extraction. After extracting the features, a machine-based algorithm segments the functional area. For segmentation, the U-net is preferred. [60, 61]. Finally, various classes are determined based on algorithm interpretation and measurement [41]. Image segmentation and classification are essential jobs for diagnosing illness, and various researchers are working on it [62, 63].

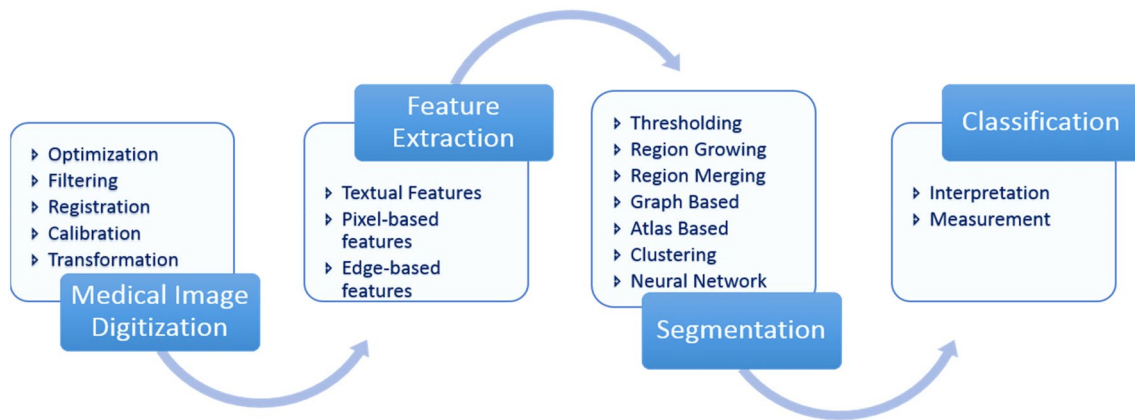


Fig. 5 Medical image processing covers four main areas: image formation, analysis, visualization, and management. The algorithms of image enhancement can be assigned as pre and post in all areas [41]

Fourth, classification is used to detect or analyse patterns and insights in images. It comprises testing a series of classifiers, comparing their results, and selecting the best one. Some classifying algorithms are used for this purpose, such as the fuzzy-based segmentation method [64] and fuzzy-based color technique [65], nearest neighbor, neural networks, and learning vector quantization [66, 67].

Available Benchmark Datasets

Our collection comprises a variety of sources, so both X-rays and CTs were not accessible from a single source, and it currently contains large databases [68, 69]. A collection of datasets is distributed into two tables based on their categories. The images from these sources are used for two purposes. First, it is diverse, with images obtained from numerous sites, making it possible to design a sophisticated method to assist radiologists in diagnosing COVID-19 worldwide. Second, the images of the datasets are widely available to the scientific community and the general public. All public two-dimensional and three-dimensional datasets originate from three sources: Kaggle, GitHub, and Radiopaedia, presented in Fig. 6. In addition to these three, more sources are represented, including ultrasound [70, 71] and various dimensions of the image [72]. Every dataset image shows COVID infected and non-COVID infected cases.

X-Ray Image Dataset

Basic medical support systems is very much needed due to the rapid growth of pandemic all around the world in minimum time. In almost all hospitals around the world, one of the low-cost radiography or X-ray machines can produce 2D (two-dimensional) images of the patient's chest. This chest

X-ray machine is the standard for diagnosing problems with the lungs, valves, heart, blood vessels, chest, spinal cord, and bones [73]. X-ray produced radiographic images within less than half an hour with low-cost radiographic images [74], which is mentioned in Table 1.

To highlight the various X-ray datasets in Table 2. Machines need more data for training purposes, but the current situation makes gathering correct and valid data extremely difficult. X-ray has more data globally than other radiographic data since it is used in almost every hospital. Most of the data were gathered from three separate sources: GitHub, Kaggle, and the Radiological Society of North America. In the X-ray image, we are trying to characterize five separate groups of data, including viral and bacterial pneumonia, and their highest accuracy using various deep learning and machine learning models.

CT Image Dataset

CT is the gold standard for image processing because it provides better image quality. It is preferred over X-rays because it gives a more detailed three-dimensional (3D) overview of the lungs. In recent works [84], CT slices were used to detect early-stage infection signs like ground-glass opacity (GGO) and late-stage infection symptoms like lung consolidation [85, 86]. Table 3 identifies CT scan of the lungs as a clinical feature of COVID-19 patients. Bilateral lung lesions resemble "white lungs" as the infection spreads [87]. The density of the lesion steadily reduces, and the region of the lesion narrows in the latter stages. The density of the lesions increases significantly a few days later, and halo and reversed-halo symptoms emerge [88].

The CT imaging manifestations of COVID-19 patients are depicted in Fig. 7 in three categories: lesion density, lesion signs, and interstitial pulmonary involvement. The density of lesions is pure GGO consolidation, and the halo sign reversal

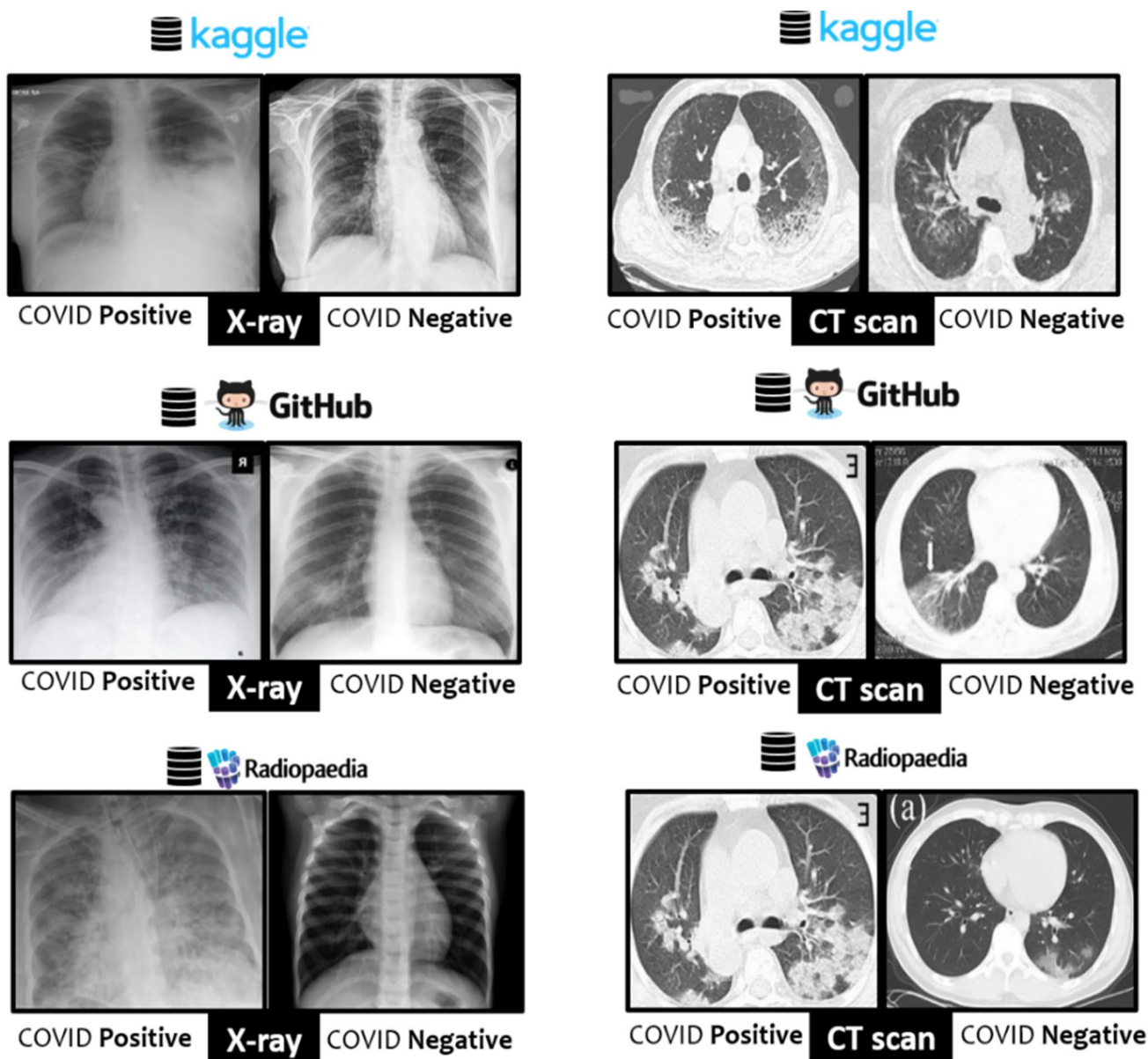


Fig. 6 Public datasets are available that contain primarily positive and negative labels on the images of COVID-19 suspects

indicates that the lesion is in its early stages. There is vascular enlargement, air bronchogram signs, and bronchial wall thickening in interstitial pulmonary involvement.

The amount of data in a CT scan is limited due to certain technical and economic drawbacks [40, 90], which affect the performance of deep and machine learning. On the other hand, a CT scan learns image features of multiscale inputs that allow it to outperform large-scale training data [91]. Table 2 focuses on various CT scan

data sources, such as image types and capture parameters. Capturing parameters is vital for CT scan machines because different parameters provide different results, and radiation is one of the major concerns. Another factor of the CT image is ROI delineation [92–94].

Table 2 Dataset of CT image for different sources

Authors	No. of images	Image categories	CT Image capturing parameters	Data sources	Results	
Cai et al. [30]	99	Moderate Severe Critical	25 47 27	• Automatic tube current • Tube Voltage 120kVp • Position is supine • Collimation 0.725 mm • Reconstruction 1 mm	First affiliated hospital at Zhejiang University School of Medicine	92.7
Gao et al. [45]	2870	COVID-19 non-COVID-19	1008 1862	• Automatic tube current (120-240 mA) • Tube voltage 120kv • Slice thickness 5 mm to 6 mm • Detector 64 mm Iterative reconstruction	Not reported	97.71
Budak et al. [56]	305	COVID-19 Pneumonia	249 56	• Tube voltage 120kv • Slice thickness 1 mm • Detector 64 mm Pitch 0.625 mm	Ethics Committees of Shanghai Public [95]	72%
Ying et al. [96]	1485	COVID-19 Healthy Others	88 86 1311	• Tube voltage 120kv • Slice thickness 5 mm • Rotation time 0.35 s • Pitch 0.75 mm Spacing 10 mm	Renmin Hospital of Wuhan University[96]	99%
Wang et al. [97]	216	COVID-19 positive	110	Slice thickness range 1.25–5 mm	Data taken from two China hospital and one USA	75%
Zhang et al. [98]	2460	COVID-19 Pneumonia	2215 245	• Automatic tube current 145mAs • Tube voltage 120kv • Slice thickness 0.625 mm • After reconstruction 10 mm	Huoshenshan Hospital in Wuhan from February 11 to March 16, 2020	91%
Ghomi et al. [99]	96	COVID-19 Healthy	51 44	• Tube voltage 120kv • Slice thickness 1.5 mm • Collimation 0.75 mm Lung window width 1000 to 1500HU	Data taken from three expert radiologists [99]	95.4%
Shan et al. [100]	249	COVID-19	249	• Automatic tube current 180-400mAs • Tube voltage 120kv • Slice thickness 5 mm Collimation 0.625 mm	From Shanghai, china	91.6%
Zheng et al. [101]	659	COVID-19 Bacterial pneumonia Typical viral pneumonia Healthy controls	262 100 219 78	• Automatic tube current 200-250mAs • Tube voltage 120kv • Slice thickness 5.0 mm • Slice space: 5.0 mm FOV: 500 mm	Sun Yat-sen Memorial Hospital and Renmin Hospital of Wuhan University	85%

discussed in "Radiomic signatures of COVID-19" Section, when compared to other medical imaging modalities, X-rays and CT are both widely available medical imaging modalities that are useful for detecting COVID-19. Researchers all over the world have applied automated frameworks like ML and DL to detect lung diseases such as COVID-19, pneumonia, and others. In recent studies, many researchers have been experimenting with their work using two imaging modalities and two automated techniques, such as ML and DL. Figure 8 uses X-ray and CT images to illustrate the

percentage share of an ML and DL used by several researchers. In ML, we put a lot of focus on different classifiers and approaches with their accuracy value in Table 4. Similarly, a number of ANN and CNN models are listed in Table 5, along with their accuracy, specificity, sensitivity, precision, recall, and f-measure.

The comparative study found some novel techniques to classify diseases with limited resources [45, 78]. One of the most problematic aspects of the COVID-19 study is the lack of reliable and precise data. Several studies employed

Table 3 Chest manifestation of different image modalities tools

Image modality	Characteristic signs
X-ray	<ul style="list-style-type: none"> • They typically damage the lungs' peripheral and lower lobes • Despite the fact that separate COVID-19 X-ray tests cover a small number of individuals, a comparable set of data is emerging [102–105] <ul style="list-style-type: none"> oGround-glass opacity (GGO) oConfluent consolidation oPeripheral lung opacity (PLO) oReticular opacity
CT	<p>The CT image of the COVID-19 patient identified a number of distinguishing features [106]. Some of the most important discoveries are as follows:</p> <ul style="list-style-type: none"> • Ground-glass opacities: GGO are characterized by a small increase in lung attenuation, resulting in semi-transparent lungs that do not obscure underneath vascular systems. It is the most common and early discovery, independent of illness stage [85, 107] • Consolidations: It is characterized by lung attenuation, which distorts arteries and airways. The second most common pattern is acquisitions with varying ground-glass opacities. [108] • Crazy paving pattern: Linear trends are caused by interlobular septa thickening overlapping with underlying ground-glass patterns. Alveolar edema and acute interstitial inflammation are to blame. These signs indicate worsening conditions [85, 108, 109] • Peripheral reticulation: The reticular form was described as a collection of numerous tiny linear opacities on CT images caused by thickened pulmonary interstitial tissues, interlobular septa and intralobular lines [108]. Interstitial lymphocyte infiltration, which causes interlobular septal expansion, may be linked to the creation of this pattern [110]
MRI	<p>S. Klironomos et al. [111] finding abnormalities of patients from MRI. Major abnormalities that they found are as follows:</p> <ul style="list-style-type: none"> • Susceptibility weighted imaging abnormalities are the most common MRI finding with corpus callosum • White matter changes significantly confluent and Juxtacortical white matter • Prominent subarachnoid spaces around the optic nerves
Ultrasound	<p>Subpleural, consolidations, and bronchograms with bilateral diffuse B-lines, inconsistent pleural line, and punctate defects [112–115]</p>

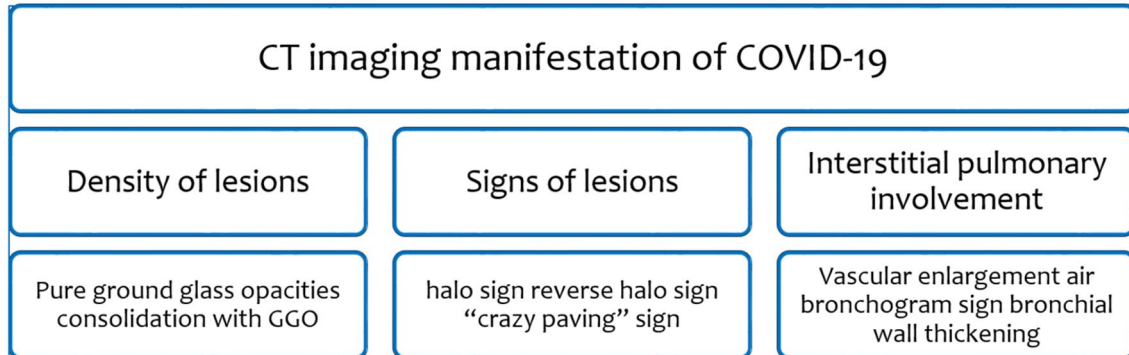


Fig.7 Severity levels of COVID-19 disease indicate a variety of CT imaging manifestations [89]

transfer learning in both two-dimensional [116–119] and three-dimensional [120–122] images due to a shortage of appropriate datasets to improve better evaluation performance [123]. Another study used both X-ray and CT images to use transfer learning techniques [124]. The proposed approach is still in its early stages of adoption, and it will require technological enhancements before healthcare institutions can extensively use it. We also carefully evaluated several useful review articles [125–130] that used

different classifiers of ML and several architectures of DL in our comprehensive review article.

Machine Learning Models

The main objective is to develop automated approaches by integrating and improving machine-learning models to detect and categorize coronavirus-infected patients from non-infected ones quickly. In the machine learning field, researchers discuss diverse areas of tracing, identifying,

Fig. 8 Percentage distribution of ML/DL techniques for COVID-19 screening using X-ray and CT images

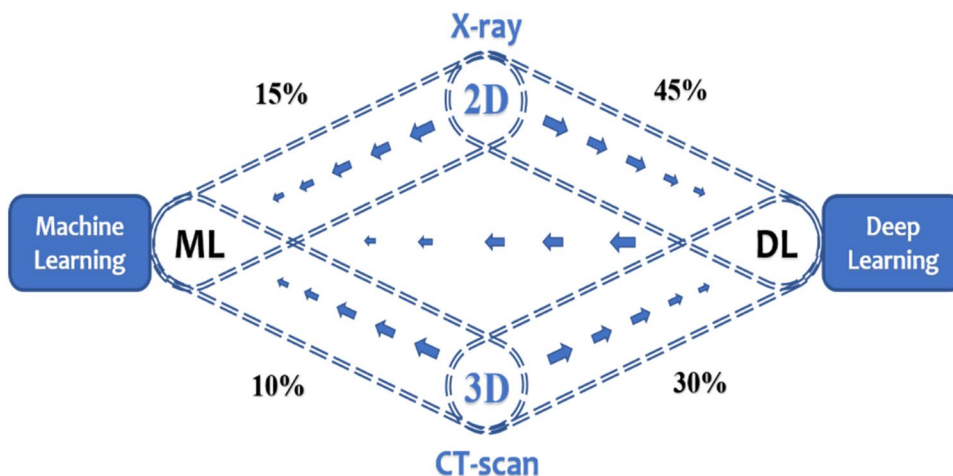


Table 4 Summary of the conventional machine learning techniques applied on X-ray and/or CT images

Image Type	Authors	Dataset	Classifiers used	Accuracy (%)	
X-ray	Hussain et al. [139]	Github repository “covid-chest X-Ray dataset” Kaggle repository—pault imothymooney/ chest-X-Ray pneumonia	KNN, NB, XGB-Tree, CART, XGB	96.34	
	Mahdy et al. [140]	Montgomery County X-ray Set, covid-chest X-Ray-dataset-master	SVM	98.81	
	Farhat et al. [142]	Kaggle repository, GitHub (Dr. Joseph Cohen)	LBP + SVM, HOG + SVM and GLCM + SVM	98.66	
	Kumar et al. [143]	public dataset from Italy	LR, NN, DT, RF, AdaBoost, NB, XGBoost	97.77	
	Pereira et al. [144]	RYDLS-20, NIH dataset	KNN, SVM, MLP, DT, RF	89.0	
	Tuncer et al. [149]	Github, Kaggle	DT, LD, KNN, SVM, SD	100.0	
	Saha et al. [153]	Github repository developed by Cohen et al. [154]	RF, DT, SVM, AB	98.91	
	Rasheed et al. [155]	Kaggle dataset	LR	97.97	
	Gilanie et al. [156]	Data collected four medical center in Israel	KNN	90.3	
	Mijwil [157]	Kaggle [158, 159]	RF, NB, SVM, LR	97.7	
	imad et al. [160]	Kaggle	SVM, DT, NB, KNN, RF	96.0	
	Samsir et al. [161]	Kaggle	SVM, KNN	98.0	
	CT	Shi et al. [138]	Huazhong University of Science and Technology [138]	LR, SVM, NN	87.9
		Liu et al. [151]	National Health Commission of the People’s Republic of China [151]	SVM, LR, DT, KNN	94.16
Perumal et al. [162]		Data used from three sources Kaggle, Radiopedia and Zenodo	SVM, RF, DT, KNN, NB	96.96	
Feng et al. [163]		Seven Hospital in China	LR, SVM, RF, XGBoost	94.6	
X-ray, CT	Hosseinzadeh et al. [164]	X-ray from Kaggle dataset and CT from RSNA Pneumonia Detection	LightGBM, Bagging, Adaboost, R, XGBoost, DT	99	
	Muhammad et al. [165]	Kaggle databases	KNN, SVM, LR, NB, (AB)	95.94	

SVM support vector machine, LR logistic regression, CART classification and regression tree, DT decision tree, KNN K-nearest neighbor, MLP multilayer perceptron, NB naive Bayes, AB AdaBoost

Table 5 Deep learning architecture specially used in COVID-19 and compared with other architecture

Image type	Publication	Custom deep learning architecture	Pre-train architecture or comparison of other architecture	No. of class with class name	Results (%)
X-ray	Khan <i>et al</i> [13]	CoroNet	VGG-19, Mobile Net, ResNet	No of class: 3 COVID-19, Normal, Pneumonia, Bacterial	Acc: 90.00, PR: 93.17, RE: 98, SP: 97.9, F: 95.61
	Gupta <i>et al</i> [2]	InstaCovNet-19	CovidAID, COVIDiagnosis-Net, CoroNet, ResNet50+DCNN, COVID-Net, DarkCovid-Net, MobileNet v2 and CovidAID	No. of class: 3 Normal, Pneumonia, COVID-19	Acc: 99.08, F: 99.00, PR: 99.00
	Mahmud <i>et al</i> [190]	CovXNet	DarkCovidNet, COVID-Net, VGG-19, ReNet-50/SVM, ResNet50	No. of class: 4 Normal, Viral pneumonia, Bacterial pneumonia, COVID-19	Acc: 91.70, AUC: 94.10, PR: 92.90, RE: 92.10, SP: 93.60, F: 92.60
	Madaan <i>et al.</i> [191]	XCOVNet	Three dimensional-CNN classification, Inception, ResNet50 + SVM, CNN + ResNet + Inception	No. of class: 2 COVID-19, Normal	Acc: 98.71, PR: 97.95, RE: 69.89, F: 82.28
	Zhang <i>et al.</i> [123]	COVID19Xray-Net	ResNet34	No. of class: 3 Normal, Pneumonia, COVID-19	Acc: 91.92, AUC: 98.50, SP: 90.00, SN: 97.00
	Chowdhury <i>et al.</i> [192]	PDCOVID-Net	VGG16, ResNet50, InceptionV3, DenseNet121	No. of class: 3 COVID-19, Normal, Viral pneumonia	Acc: 96.58, PR: 96.58, RE: 96.59, F: 96.58
	Ucar and D. Korkmaz [193]	COVIDiagnosis-Net	DenseNet, Tailored CNN, Capsule Networks, ResNet50, Sgdm-SqueezeNet	No. of class: 3 COVID-19, Normal, Pneumonia	Acc: 98.26, CR: 98.30, CM: 98.30, SP: 99.10, F: 98.30, MCC: 97.4
	Ozturk <i>et al.</i> [194]	DarkCovid Net	COVID-Net, COVIDX-Net, ResNet50, VGG-19, M-Inception, DRE-Net	No. of class: 2 COVID-19, non-COVID-19	Acc: 95.13, SN: 85.35, SP: 92.18, PR: 89.96, F: 87.37
	Ambati <i>et al.</i> [195]	AC-CovidNet	DarkCovidNet Covid-Caps, CovXnet COVID-Net, CovidAID,	No. of class: 3 COVID, Pneumonia, Normal	Acc: 96.66, SN: 96.66
	Hanafi <i>et al.</i> [196]	Cae-covidx	VGG16, Custom CNN	No. of class: 2 Normal, COVID	Acc: 98.00
X-ray	Hussain <i>et al.</i> [197]	CoroDet	COVID-Net, COVIDX-Net, Inception-ResNetV2, ResNet152	No. of class: 4 COVID-19, Normal, Viral pneumonia, Bacterial pneumonia	Acc: 91.2, SN: 91.76, SP: 93.48, PR: 92.04, RE: 91.9, F: 90.04
	Elbishlawi <i>et al.</i> [198]	Corona-Net	VGG-19, ResNet50, COVID-Net	No. of class: 3 COVID-19, Pneumonia, Normal	Acc: 100.00, F: 99.80

Table 5 (continued)

Image type	Publication	Custom deep learning architecture	Pre-train architecture or comparison of other architecture	No. of class with class name	Results (%)
	Haghanifar et al. [199]	COVID-CXNET	ShuffleNetV2, InceptionV3, COVID-Net, DenseNet	No. of class: 3 Normal, COVID-19, Pneumonia, non-COVID-19	Acc: 87.21, F: 92.21
	Khan et al. [200]	CovidMulti-Net	Pre-trainModel	No. of class: 4 Normal, COVID-19, Viral pneumonia, Bacterial pneumonia	Acc: 98.40, PR: 83.00, RE: 100.00, F: 91.0
	Wang et al. [201]	COVID-Net	VGG19, ResNet50	No. of class: 2 COVID-19, non-COVID-19	Acc: 93.30, SN: 91.00
	R. K. Singh et al. [202]	COVIDScreen	Covid-net, Coronet, COVID-CXNet, Covid- AID	No. of class: 3 Normal, COVID-19, Pneumonia	Acc: 98.67, PR:100.00, RE: 100.00, F: 100.00
	Das et al. [203]	CoviLearn	CovidNet, VGG-19, ResNet50, DarkNet	No. of class: 2 Normal, COVID-19	Acc: 98.98, SN: 100.00, SP: 98.00, AUC: 99.00
	Umer et al. [204]	COVINet	VGG16, AlexNet	No. of class: 4 Normal, COVID-19, Virus pneumonia, Bacterial pneumonia	Acc: 84.76, PR: 89.29, RE: 98.99, F: 93.89
	Hertel et al. [205]	COV-SNET	Covid-cxnet, ChestX-Ray8, Deep- covid-xr, Covid-net	No. of class: 3 COVID-19, Normal, Pneumonia	Acc: 83.30, SN: 95.00, SP: 85.00, F: 86.00
	Ouchicha et al. [206]	CVDNet	MobileNetV2, VGG19, InceptionV3, DenseNet201, Inception- ResNetV2, ResNetV2, Xception	No. of class: 3 COVID-19, Normal, Pneumonia	Acc: 94.00, SP: 96.00, SN: 90.00, AUC: 96.00
	Minaee et al. [207]	Deep-COVID	ResNet18, ResNet50, SqueezeNet, DenseNet121	No. of class: 2 COVID-19, non-COVID-19	SN: 98.00, SP: 92.00
	Quan et al. [208]	DenseCapsNet	DenseNet, ResNet50, CapsNet	No. of class: 3 Normal, Pneumonia, COVID-19	Acc: 90.70, F: 90.90
	Cheng et al. [209]	DPN-SENet	ResNet, DenseNet, DPNNet, VGG16, Inceptionv4	No. of class: 4 COVID-19, Normal, Bacterial pneumonia, Viral pneumonia	Acc: 93.00, RE: 98.00, PR: 97.00, F: 98.00
	Chowdhury et al. [210]	ECOVNet	COVID-Net, Efficient- Net-B3, DarkCovidNet, CoroNet	No. of class 3 COVID-19, Normal, Pneumonia	Acc: 95.00, PR: 90.29, RE: 93.00, F: 91.63
X-ray	Tang et al. [211]	EDL-COVID	ResNet50, Inception V3, Inception- ResNetV2	No. of class 3 COVID-19, Normal, Pneumonia	Acc: 95.0, SN: 96.0

Table 5 (continued)

Image type	Publication	Custom deep learning architecture	Pre-train architecture or comparison of other architecture	No. of class with class name	Results (%)
	Agrawal et al. [212]	FocusCovid	DarkCovidNet, nCOV-Net, Capsnet, COVID-Net, ResNet18, VGG-19	No. of class 3 COVID-19, Normal, Pneumonia	Acc: 95.20, PR: 95.0, SN: 95.20, F: 95.20
	Monshi et al. [213]	CovidXrayNet	VGG-16, VGG-19 ResNet18, ResNet34 ResNet50, EfficientNet-B0	No. of class 3 COVID-19, Normal, Pneumonia	Acc: 95.82, AUC: 99.29, F: 96.16, PR: 96.93, RE: 95.43
	Toraman et al. [214]	Convolutional CapsNet	DarkCovidNet, VGG19, MobileNetV2 DeCov- Net andDRE-Net	No. of class 3 COVID-19, Pneumonia, No finding	Acc: 97.24, SP: 98.00,
	Hemalatha et al. [215]	FractalCovNet	ResNet5, Xception, Inception- ResNetV2, VGG-16, Den- seNet	No. of class 2 COVID-19, Others	Acc: 99.00 PR: 99.00 RE: 87.00 F: 92.00
CT	Ghaderzad et al. [216]	NASNet	SqueezeNet, ShuffleNet, VGG-19, Modified VGG-19, COVID-CT-Net	No of class 2 COVID-19, non-COVID-19	Acc: 99.60, SP: 98.60, SN: 99.90,
	Ibrahim et al. [217]	Deep-chest	VGG19-CNN, ResNet152V2, ResNet152V2 + Gated Recurrent Unit (GRU), ResNet152V2 + Bidi- rectional GRU (Bi-GRU)	No. of class: 4 Covid-19, Normal, Pneumonia, Lung cancer	Acc: 98.05, RE: 98.05, SP: 98.43, F: 98.24, AUC: 99.66
	Shah et al [218]	CTnet-10	ResNet50, InceptionV3, DenseNet- 169, VGG- 16, VGG-19	No. of class: 2 COVID-19, non-COVID-19	Acc: 94.52
	Bhansali et al. [219]	CoronaNet	Pure CNN based	No. of class: 2 COVID-19, Normal	Acc: 92.14, PR: 91.07, RE: 89.38, F: 87.35
	Wu et al. [220]	COVID-AL	Not reported	No. of class: 3 COVID-19, Pneumonia, Common pneumonia, Normal	Acc: 86.6, R-AUC: 96.62, ROC-AUC: 96.8
	Javaheri et al. [221]	CovidCTNet	EfficientNet B4, ResNet18, Resnet50, 3D Resnet-18	No. of class: 2 COVID-19, non-Covid-19	Acc: 95.00, PR: 88.00, RE: 74.00, F: 80.00
X-ray/CT	Afshar et al [222]	COVID-CAPS	ImageNet	No. of class: 4 Normal, Bacterial pneumonia, Viral pneumonia, COVID-19, non-COVID-19	Acc: 83.50, AUC: 97.00, SN: 90.00, SP: 95.80

Acc accuracy, PR precision, RE recall, SP specificity, F F-measure, SN sensitivity, MCC Matthew correlation coefficient, CR correctness, CM completeness, projection expansion projection extension (PEPX), FC fully connected, BN batch normalization

treatment, and monitoring [131]. Figure 9 depicts the general workflow of machine learning prediction and evaluated it for final output [132]. For the machine learning model, preparing data according to features for training and testing is critical. Different classifiers were applied for validation to select the appropriate features [133]. Because of its image features, the machine learning method can be used to detect COVID-19 disease in both two-dimensional and three-dimensional images [134].

In this case, classification is an extremely important task in classifying normal, bacterial pneumonia, viral pneumonia, positive COVID-19, and negative COVID-19. Several machine learning classifiers were used for classification purposes after extracting features from traditional methods [135]. M. A. Elaziz et al. [136] introduce two new reliable classification methods, and the first focused on descriptors and the second based on feature selection [42]. The classifier represents the input data using feature sequences generated from feature extraction [137]. Table 4 shows machine learning classifiers, their maximum results, and the various datasets used by machine learning models. SVM and Random forest (RF) provide better results than all the classifiers, but it mainly depends on the dataset.

Shi et al. [138] presented the iSARF (infection Size Aware Random Forest technique), which classified individuals based on the size of infected lesions and used random forests to identify each class of people. Using five-fold cross-validation, the proposed procedure had a sensitivity of 0.907, precision of 0.833, and an accuracy of 0.879. This approach may be used as a decision support system but not relied on because the false-positive rate is relatively high, and the system performance increases slightly.

Hussain et al. [139] showed morphological and texture characteristics to immediately determine whether a patient is infected or not with COVID-19. The method's key benefit is identifying adaptive image features and classification concurrently. They evaluate the hypothesis of texture features in addition to optimizing machine learning classifiers. They attempted to demonstrate more significant 95% accuracy in five different machine learning classifiers. However, the fundamental flaw in this strategy was that it only used a limited images dataset. Mahdy et al. [140] proposed an automated lung X-ray image assessment method that combines multi-level thresholding and support vector machines. A multilevel threshold is a technique for dividing a gray image into several regions. The COVID-19 damaged lung X-ray images are classified using deep features by the support vector gadget. They describe with equation that two-class boundaries can be used to enhance hyperplane distance. SVM improves the interval between the hyperplane and the edge. Other researchers employed CNN with SVM classifiers [141], similarly to Mahdy's study. But CNN with SVM is more flexible from a future search perspective.

The survey article by Farhat et al. [142] analyzed medical image processing using deep learning in depth with five different sections. The second section covers a broad range of medical image modalities. However, for the final section, the remaining three sections use DL to process COVID-19 images and use it for pulmonary medical images. They clustered with various DL parameters on pulmonary medical image analysis. But they are not discussed the DL-based efficient framework and future work related to the DL model. In this paper [143], they show how ResNet152 and ML classifiers can be used to classify COVID-19 effectively. Since being developed on two publicly accessible datasets, the suggested technique has outperformed all groups. The synthetic minority oversampling technique (SMOTE) algorithm was also applied to balance intra-class heterogeneity among the datasets. ML algorithms are applied to the training dataset using SMOTE-based features, leading to the best possible result achieved by random forest. We observed that apart from ResNet152, some other models worked best in the feature extraction field.

Pereira et al. [144] have introduced a classification scheme that combines two forms of classification: multiclass classification and hierarchical classification. Since pneumonia follows a hierarchical classification structure, they placed a particular emphasis on it. To rebalance the distribution of classes in this domain, they proposed resampling techniques in the schema. One of the most important features of X-ray images is texture. Several well-known texture descriptors, as well as a pre-trained CNN model, are used in our classification scheme to extract features. Similar to this research, other researchers have used DL models for feature extraction and selection [145–147]. They looked at early and late fusion methods in the hierarchy to incorporate the strengths of various texture descriptors and base classification methods. Few papers introduced different fusion-related techniques for COVID-19 diagnosis [148].

Tuncer et al. [149] introduced a hybrid approach for extracting and selecting features. The main goal is to extract an essential feature and use the most discriminative one. Five classifiers classified the most discriminative functionality. Few papers introduced important correlations between laboratory extracted data and deep learning segmentation data using the machine learning classification technique [150]. Liu et al. [151] used an ensemble of bagged tree algorithms to explore a promising approach for distinguishing COVID-19 from general pneumonia. After selecting the feature, they used an ensemble of bagged trees, four ML classifiers, and ten-fold cross-validation [152].

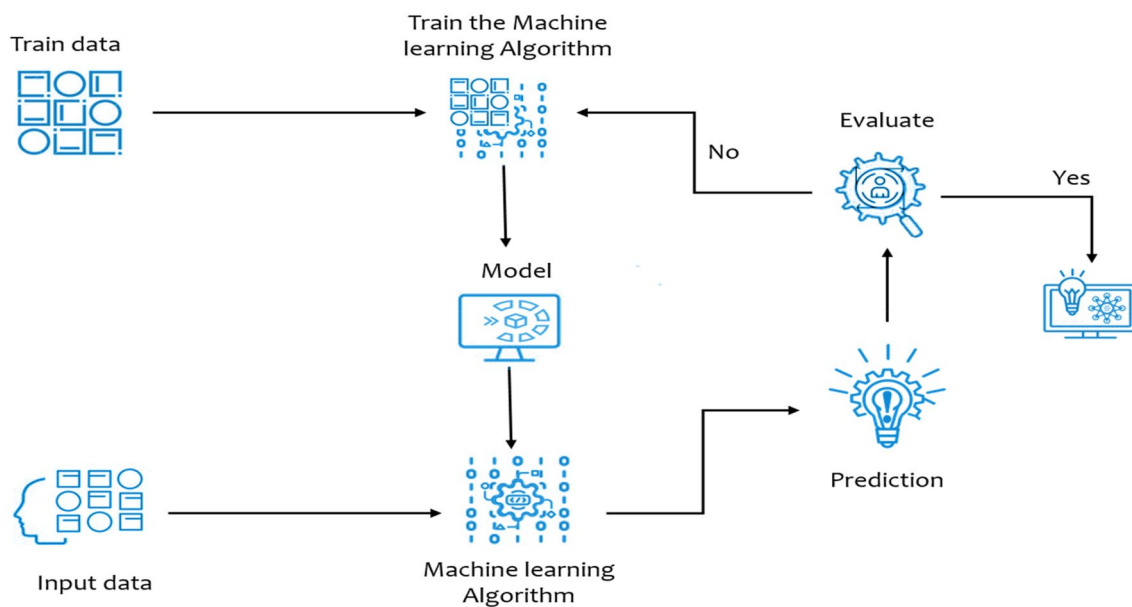


Fig. 9 Machine learning model depicts several states from input data through performance evaluation

Deep Learning-Based Work

Deep learning is the most popular category of artificial intelligence systems, which performs well for analyzing unstructured data using several layers. Data are processed across multiple layers in this model, with each layer using the output of the previous one to provide its specific output. There are many of DL algorithms that can be used for different purposes. Among all the deep learning algorithms, the convolution neural network (CNN) plays a significant role in analyzing visual imagery. Many frameworks have been proposed that use CNN algorithms for image classification, segmentation, and object detection, such as VGG16 [166], MobileNet [167], ResNet [168], InceptionV3[169]. Using this standard CNN framework, researchers have developed custom CNN models, which are represented in Table 5. Those frameworks are specially built for COVID-19 detection. With the help of CNN, researchers were able to find in-depth analyses of medical imaging modalities [170] using a variety of deep learning frameworks [171]. By analyzing biomedical and clinical data, healthcare experts and academics can learn about new ways to serve the patient community [21]. According to recent studies, DL approaches almost accurately identify a wide range of diseases using radiographic images, reducing the burden on medical practitioners while simultaneously improving diagnosis performance [172–175].

Data gathering, preparation, division, package selection, validation, and model performance are all phases in deep learning-based systems in general. It has been widely used in the prediction and diagnosis of COVID-19 in patients

in recent years. Figure 10 depicts the general pipeline of a deep learning system. Data can be taken in various forms for deep learning training, such as X-ray, CT, MRI, and ultrasound. Due to some complicated structures in the medical system, handling unstructured data is a big issue. After evaluating image severity levels, an ANN was applied to the data to obtain a basic classification result. Compared to ANN (artificial neural networks), DNN (deep neural networks) performed well due to their multiple hidden layer features, which increased accuracy. However, because of the problem of vanishing gradients in DNNs, convolution neural networks (CNNs) were considered as an alternative [176–179]. Compared to other image recognition learning models, CNNs are proven to produce better outcomes. CNNs are recommended because they give better visual processing models for detecting noisy input. Therefore, DL approaches are increasingly being used to automatically extract related features and automatically identify the object of interest [180].

Ensemble, fusion, and segmentation [181, 182] are three additional techniques that significantly enhance the overall classification performance in deep learning [183, 184]. Here we focus on an ensemble of classifiers that generally outperform a single classifier in categorizing many lung-related diseases, particularly pneumonia and COVID-19, by lowering variation in the final prediction [185, 186]. The performance of the COVID-19 disease classification is being boosted through ensemble-based learning [187]. Different deep transfer learning techniques may be used to build an ensemble of classifiers by altering the architecture of pre-trained CNN models in the setting of deep transfer learning

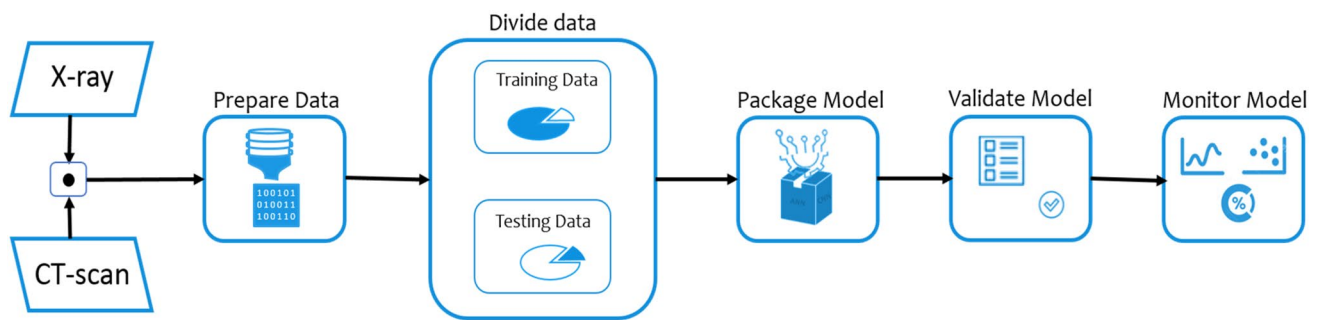


Fig.10 The deep learning architecture depicts several states from pre-process data through performance monitoring of several classes

[188]. Another method is the snapshot ensemble technique [189]. We will cover segmentation and fusion in the next section.

In Table 5, we explore several custom-built deep learning convolutional network architectures. The third column addresses two objectives, which depend on deep learning architecture. One is a custom model compared to a standard model, and the other is pre-trained architecture. We also addressed other pre-train custom models with their own names, which are as follows: MANet [223], MDCNN [71], CSEN [224], MSCovCNN [225], ToraxIA [226], FJCovNet [227], ReCoNet [228], ReCOV-101 [229], COVID-CLNet [230], FCONet [231], CNR-IEMN [232], COVID-NET CT-S [233], and CovFrameNet [234].

Apart from the custom network mentioned above, several researchers are experimenting with pre-training deep learning architecture by modifying specific parameters or implementing transfer learning techniques. Nanochest-net [235] experimented with five datasets, and the base architecture is ResNet50, Xception, and DenseNet121. F. Saiz et al. [236] are working on two different approaches, one is histogram-based, and the other is decoder based. K. Hammoudi et al. [237] split the input images and fine-tuned them by Inception, ResNetV2, and predicting the final image using the directional LSTM method. CT and X-ray of suspected patient cases were classified as infected or non-infected COVID-19 using VGG16 [238, 239] and VGG19 [240], including other architectures [241]. It is necessary to fine-tune VGG16 because it always does not offer better results [242]. Another fine-tune process was done for this pre-train network AlexNet, GoogleNet, and SqueezeNet [243]. Several researchers have been experimenting with various ResNet architectural variants as a result of their findings [244–246]. Along with pre-train deep learning architectures, some other articles used only CNN models with different types of layer sizes [247–249]. To improve the convolution neural network performance for identifying COVID-19, geometric image augmentation is one of the essential factors [250, 251]. Rahhal et al. [252]’s article is divided into four parts. To begin, the EfficientNet backbone of the

CNN model was used. In the second step, multiscale feature extraction was used. Third, the extracted features from the multiscale feature map extractor were combined using a weighted average fusion operator. In the final phase, the modules were classified and the network was optimized. Besides optimizing the network, B. Sekeroglu and I. Ozsahin [253] used the extreme machine learning technique to achieve the first training. Other studies show extreme learning with different activation functions [254].

Khan et al. [13] article represents an extreme version of Inception, which falls under the CNN architecture and its name is CoroNet. This architecture prepared 71 layers with the help of deep CNN pre-trained on ImageNet. CoroNet is inspired by Xception, with two fully connected layers added at the last and a single dropout layer. This extended model provided a satisfactory result for an insufficient dataset to avoid the overfitting they used for transfer learning. In these custom CNN architectures, it does not perform well in the four-class X-ray images dataset. Like CoroNet, other experiments used various versions of Inception architecture [255] [256], experimenting with other versions of Inception architecture. Gupta et al. [2] proposed a DL classification model applying X-ray images. It implemented two image preprocessing or regeneration techniques which were used to achieve better functionality for its model. One method is a fuzzy color image enhancement, and another is image stacking. Fuzzy color is used to improve image quality and reduce image noise. This method divides the picture into fuzzy windows, assigning a weight to each pixel according to the distance between the window and the pixel. Focus blending, z-stacking, and central plane consolidation are used in image stacking to enhance accuracy to 99.08 percent. Because it can reduce the noise from low-quality X-ray images, this fuzzy color image processing method is highly efficient. Authors may use social mimic optimization in addition to fuzzy color and stacking to improve comparison.

Ozturk et al. [194] proposed five pre-trained convolutional neural network-based models for diagnosing coronavirus pneumonia-infected patients in this research. Three

separate binary classifications of four different levels have been introduced. Out of the five models, ResNet50 provides the best classification results. Mahmud et al. [190] proposed CovXNet. It is a deep learning model for identifying pneumonia with distinct localization using chest X-rays. Active depth-wise convolution with different dilation frequencies is used instead of traditional convolution. A produced class activation map allows for discriminative localization of irregular areas, which may aid in diagnosing pneumonia's various clinical features. Z. Wang [257] discusses automatic discrimination and localization of areas using DL.

Zhang et al. [123] proposed a model, modified version of ResNet32, called COVID19XrayNet. A large database of pneumonia chest X-ray images was used to fine-tune a pre-trained deep residual network (DRN) model called ResNet34. Shiri et al. [258] introduced the ultra-low-dose CT imaging residual model, and few researchers worked on this model [259–261]. To diagnose coronavirus from chest X-ray, researchers Chowdhury et al. [192] created PDCOV-IDNet, a CNN application. The proposed model is divided into two parts, the first of which is feature extraction and the second of which is classification and visualization. They created an architecture that implements a dilated convolution in a parallel stack of convolutional blocks to collect and distribute essential features in actual environments through the network, achieving good detection accuracy.

Ucar et al. [193] proposed a new architecture for detecting COVID-19 patients rapidly and reduced diagnostic complexity. The COVIDiagnosis-Net architecture is built on a deep Bayes-SqueezedNet model. SqueezeNet is a cutting-edge deep learning architecture based on the well-known AlexNet, but with a much smaller model scale. In the architecture, offline augmentation is performed. One of the main advantages of this network is that it can operate well in an embedded environment. Zhou et al. [1] research article implements a novel approach using the symmetry characteristics of the lungs and other tissues to break down the three-dimensional segment problem into two-dimensional one, which greatly improves segmentation accuracy while reducing the number of model parameters by order of magnitude.

For the comparative and critical analysis, Majeed et al. [3] used class activation maps (CAM) to examine the classification made by CNNs. In these cases, they used a total of 12 CNN architectures using natural images to assist radiologists in identifying COVID-19 disease that is dependent on X-ray images. In addition to comparative research, they also suggested a simplified CNN architecture with fewer parameters than many well-known CNN architectures. Wang et al. [82] used an automatic feature extraction method and directly extracted features from five pre-trained CNN models. They observe high accuracy with 99.33% for implementing the deep model with various classifiers. In the proposed method, they prepared in three steps. First step is preprocessing of

the input dataset. In the second step, bottleneck features are extracted using deep learning models that have been pre-trained and the last step is machine learning classifier. However, none of the three approaches is optimized, and evaluation may take a long time.

Asraf et al. [21] introduce the battlefield of the world's fastest-spreading virus, and scientists are ready to fight with various technologies and methods, especially in artificial intelligence. They came up with several technologies, from disease tracking to drug discovery. With the help of CNN and LSTM, they used CT and X-ray images to predict the COVID-19 suspect with significant accuracy. A deep learning-based disease tracking system using camera footage, a gated recurrent unit (GRU), and a satellite for geographical risk assessment is also discussed. Identifying disease from an image is a challenging task in the medical domain. Since DL is a difficult area, long short-term memory (LSTM) networks play a key role. It may be used in conjunction with CNN and entropy feature extraction or independently with the feature section [262, 263].

Ahsan et al. [264] proposed a method that uses numerical and categorical data, as well as an X-ray image, to construct a COVID-19 diagnostic model that was evaluated on a balanced and imbalanced dataset using the multilayer perceptron and convolutional neural network (MLP-CNN). Hamadneh et al. [265] also applied MLP, which was based on single-country demographic data and used the prey-predator algorithm. Elzeki [266] employed a different technique for working with an imbalance dataset and two-layer image fusion in DL. This paper's [267] primary focus is deep feature fusion (DFF), which is the fusion of several deep feature representations from both convolutional neural networks (CNN) and graph convolutional networks (GCN). They selected the best method from eight suggested network models and then applied it to fifteen state-of-the-art methods. They experimented with batch normalization, dropout, average pooling to replace max pooling, and multi-way data augmentation. Zhang et al. [268] introduced stochastic pooling instead of average pooling. A few other papers introduced different fusion-related techniques for COVID-19 diagnosis [200, 269, 270] and other approaches to multimodal fusion learning [271].

In deep learning, convolutional neural networks were used to distinguish between COVID-19, non-COVID-19, and pneumonia. In most cases, pre-trained CNN methods are used. Many research articles [272–276] show their experiments with more than five pre-trained architectures. M. M. Rahaman et al. [277] experimented with 15 pre-trained CNN architectures with transfer learning and represented the confusion matrix very organized way.

As per Apostolopoulos et al. [76] research, deep learning combined with X-ray imaging could extract important biomarkers linked to the COVID-19 disease. They used two

key strategies: function extraction through transfer learning with a pre-trained model parameter tuning and architecture improvements. The analysis recognizes two shortcomings in this field. Panwar et al. [77] introduced a transfer learning-based algorithmic model known as 'nCOVnet'. The top layer of the VGG16 model is used as the base model in this algorithm, and is then added to the custom five layers as the head layers. They claim that the nCOVnet model is 97.62 percent accurate and that an RT-PCR test can replace it. Jain et al. [78] explain this using a comparative study of deep learning models based on CNN. In addition, the proposed algorithm is based on the three models and is explicitly clarified with each step evaluated using Inception Net V3, Xception Net, and ResNet. They tested their accuracy by activating LeakyReLU, a novel modification. Instead of the relu, this activation mechanism was used.

Albahli et al. [79] describe comparative analysis with existing three DL models and fine-tuning for automatically detecting COVID-19. They used ImageNet for transfer learning due to a lack of data. InceptionNet-V3 is the best approach for the overfitting problem. This paper discusses the average solution for automatically detecting COVID-19 from X-ray images. Authors [80] used a VGG16 model that was well-trained and evaluated with a vast range of X-ray image datasets from three different classes. In the image processing step, most of the diaphragm region was removed, the segmented grayscale image was converted, and a bilateral low-pass filter and histogram equalization was applied. They illustrate that their suggested graph of a transfer learning model effectively overcomes overfitting and underfitting.

Mohammadi et al. [81] explain using a comparative analysis of the CNN model with some modifications to achieve better accuracy. The picture is scaled to a normalized form, and the pixel value is changed from zero to one. The other is to tune and enhance the outcome by processing the transfer learning layer portion. They also mention that MobileNet performs better than the other three CNN models. According to Gao et al. [45], since it has been discovered that classification outcomes are strongly dependent on segmentation, authors have merged classification and segmentation processes. They used U-net for slice-level segmentation and classification. At the segmentation level, they proposed a novel weighted dice loss. They compared their model with five deep learning networks achieving better accuracy both in internal and external validation. N. Paluru et al. [278] introduced Anam-Net as state-of-the-art U-Net technology with a fully convolutional AD-block developed inside a symmetric encoder–decoder architecture. This architecture is also compared with heavyweight segmentation methods such as Enet, DeepLabV3, LED-Net etc. Similar to this work, other CNN-based segmentation methods help to detect COVID-19 diseases [279–283].

Ying et al. [96] proposed novel deep learning architecture for CT images. Comparison to the other common three deep learning models, VGG16, ResNet, and DenseNet, the details relation extraction neural network (DRENet) architecture performs well on CT images. DRENet outperformed other architectures because it has a powerful ability to retrieve data from images. They detach key areas of the lungs, fill in the vacant lung segment in the design to avoid noises, and extract top-K images for image-level predictions that result in patient-level diagnoses. Wang et al. [97] identify basic DL and radiomics features related to COVID-19 pneumonia in an attempt to optimize ML algorithm interpretability and increase the overall efficiency of COVID-19 pneumonia imaging phenotypes. They also demonstrate the result of DL and radiomics models for COVID-19 pneumonia prediction using chest CT, showing the ability for ML predictions to enhance radiologist's predictive sensitivity.

S. Karakanis and G. Leontidis [284] discuss lightweight DL models for detecting COVID-19 using chest X-ray. They try to prepare synthetic images to overcome the limitation of COVID-19, which is previously present in conditional generative adversarial networks, adapted for our purpose (cGANs). G. Ciano et al. [285] and D. Mahapatra et al. [286] elaborately explain synthetic image generation, including different types of GAN for segmentation purposes. Y. Karbhari et al. [287] proposed a novel model using synthetic image generation to overcome the limitation of COVID-19. They discuss the whole topic in four major points. First, they develop an auxiliary classifier generative adversarial network (ACGAN) to generate chest X-ray images. Apply a different CNN model to these synthetic X-ray images, then fine-tune the method for better accuracy. After that, using the harmony search algorithm to reduce the dimension of the feature vector, feature selection is made on the CNN extracted feature vector.

Other Reported Works

Arshadi et al. [11] survey article elaborately discusses drug discovery and vaccine development, which is one of the prime targets of the AI ecosystem in the coronavirus pandemic. The molecular mechanism section explains how viruses spread from one host to another host via the viral spike protein and its structures. The main aim of drugs and vaccine development is to manipulate and predict intertwined biological pathways or off-target biology of current proven safe drugs. New clinical trials will be easily conducted using deep learning and machine learning. Wu et al. [18] suggested a deep learning method focused on hybrid weak labels to learn infection and consolidation information from CT datasets with the help of expectation–maximization(EM). A UNet was first trained with supervised learning to predict the infected areas based on

clear semantic labels. Single-class contours were used to train the network, which was then fine-tuned using poor patient-level labels. The proposed framework's feasibility is demonstrated by evaluations focused on databases from various hospitals worldwide. Training a semantic segmentation network is divided into two labels, strong label and weak label. The results section discusses severity segmentation, consolidation segmentation, and statistical testing of consolidation score.

Allam et al. [20] article discussed sharing pandemic data and preparing technological devices and labs around the world to exchange data and cooperate to create systems and cures. Related activities should be discussed by smart city practitioners on how collaboration initiatives could allow for the maximization of public safety in those and similar scenarios. Managing a huge amount of data, artificial intelligence can give added benefits to accurately and efficiently solve the current situation. Gupta et al. [24] show the great perspective of smart connectivity for quickly and efficiently taking steps according to fetching data. This smart connectivity fetches data from many areas such as smart city, E-health, smart locality, smart supply chain management, and even collects data from home. For collaboration, this proposed smart networking is separated into separate layers. IoT and CPS architecture are used in this communication scheme. The e-health ecosystem is now applied centrally with AWS, thanks to smart connectivity.

García et al. [26] discuss the details of antibody response and immunological profile of COVID-19 patients. It also shows clinical and immunological with different stages, including protective immunity and inflammatory spectra. It is important to remember that very little time has passed since the pandemic began and how little data have been gathered. The evidence presented in the papers examined strongly supports quantitative and qualitative variations in immune responses among SARS-CoV-2-infected people. Mohamed et al. [35] discuss all aspects of medical imaging, and also explain certain fundamental features of digital images and their applications. They describe four major types of diagnostic images in the medical image section: X-ray, CT, nuclear medicine, and ultrasound. Image analysis, such as enhancement, segmentation, thresholding, edge detections, and k-mean segmentation, is the main objective of this paper. This research paper covers any important aspect of medical imaging in great detail.

Lightweight design provides several advantages, particularly in the area of overfitting. H. Mukherjee et al. [288] proposed shallow CNN architecture with only four layers. Because of the multiple layers and a large number of parameters, most CNN architectures take longer to train, even though they suffer from overfitting. However, the architecture developed by Mukherjee and co-researchers performs exceptionally well with unseen data, with 99.69 percent

accuracy. Zhang et al. [98] say that using a CT image, the uAI (intelligent assistant analysis system) can correctly classify COVID-19 pneumonia. The capacity of the uAI to rapidly and reliably localize and measure infection locations from CT can help practitioners not only diagnose COVID-19 but also evaluate the disease and direct treatment plans. Multifocal bilateral GGOs are typical CT traits of COVID-19 pneumonia, with the dorsal section of the right lower lobe being one of the most usual sites of infection.

Fan et al. [289] suggested approach works on CT slices, but CT slices have several challenges due to their low strength and high variation. Most recent studies on three-dimensional image slices used GGO in the early stages and pulmonary consolidation in the later stages. But proposed methods named Inf-Net and Semi-Inf-Net identify infected sections using reverse and edge attention, which is an explicit and implicit method, respectively. To build a global map from the high-level attributes, Inf-Net is used as a parallel partial decoder. But actual practice is classifying the COVID-19 patients before segmentation. Shan et al. [95] built a DL-based method to overcome the significant challenges of identifying COVID-19 from CT images due to low contrast, shape, and segment position. This system measures infection based on volume and contours infection regions automatically. Another necessary procedure was computed to show the entire pipeline for quantitative segmentation and infection assessment [290, 291].

Discussion

Our study included 265 research papers encompassing various medical image analyses using ML and DL. In Fig. 11, 118 research articles solely look at X-rays, 96 articles look at CT images, and 36 articles look at CT, X-ray, and other related radiography images. In the years 2020 and 2021, most of the articles were published. We observed that these infectious diseases could be distinguished by two visual indicators: ground-glass opacity and crazy pavement patterns. Based on these two most significant visual indications, ML and DL methods classify disease. Most artificial intelligence researchers were interested in the CNN architecture for automatically identifying a disease from chest radiography. However, the CNN architecture has several drawbacks, such as overfitting, for a low number of image datasets. In medical research, researchers work with sensitive human data, and false-positive values may infect more people.

Our study observed that medical image data and computer-based automated systems face several challenges [292]. In both ML and DL, a sufficient amount of high-quality data is required to train the model. The training time is considerably longer for poor-quality images [293]. Specific problems in the automated diagnostic process are directly or

indirectly related to our review. However, our study might be incomplete if we did not highlight such challenges. First, we observed that, for the limited number of sample sizes and imbalanced datasets, DL performance was degraded in a few cases. The researchers used augmentation techniques and transfer learning to overcome this issue [153, 294]. Second, one of the essential areas is the DL method for radiographic segmentation. However, since segmentation requires numerous annotated datasets, in the case of COVID-19, it is challenging for the current situation. On the other hand, performing annotation on new images will also be a tedious task. Another problem with medical image segmentation is that the target organs are heterogeneous [48]. The target organ or lesion's scale, shape, and place can vary significantly from patient to patient [295]. Third, due to the viral mutation of the virus, it is now difficult to predict the virus with the previously standard trained model [296]. Fourth, the lack of a chest X-ray orientation (posterior or anteroposterior, upright or supine) may have delayed X-ray-based research. Another disadvantage is that the timing of chest X-rays about symptoms is not documented, which is a severe flaw in this X-ray image-based study [297, 298]. Fifth, X-rays and CT produce images based on radiation technology. The virus is particularly prevalent in people of all ages, so the radiation dose is essential, and the slightest variation in radiation can cause significant harm to the patient [299]. Sixth, since the target organ is heterogeneous, the idea of feature hierarchy grows, and the complexity of the neural network continues to grow [176]. The time consumption of feature engineering increases the difficulty of specific models [300].

During this pandemic, the radiologists in spite of their significant shortage [301] were constantly engaged to provide the diagnostic support to the huge amount of the patients. In effect, sufficient number of X-ray, CT, MRI image data were not properly stored and also not available to the researchers for the development of the AI/ML algorithms. To overcome the limited amount of data, most researchers applied transfer learning techniques to increase accuracy and reduce overfitting [302–305]. There are two main problems with transfer learning: negative transfer and overfitting. Most studies deal with overfitting in a generic approach and do not discuss negative transfer challenges. Negative transfer learning only works if both models' beginning and target problems are sufficiently comparable. However, because we are still in the experimental stage, our target problem does not give precise or pure data, which might lead to unexpected results. Synthetic image generation [102] is another approach for dealing with this problem, although it is still in its early stages and is unsuitable for sensitive image data.

Some studies used only two classes of images to train their deep learning models: normal and COVID-19, which is confusing because pneumonia and COVID-19 images are quite similar. If the DL model is not adequately trained

with pneumonia and COVID-19 images, typical pneumonia patients may experience needless fear as a result of this outcome [306]. To overcome this misclassification, deep learning architecture should be trained with three class images and added extra features like stack ensemble learning [307]. This technique makes the model robust to classify diseases more elegantly. A few researchers implemented feature extraction techniques to extract relevant features from radiographic and applied several ML approaches to reduce misclassification as much as possible. In the context of misclassification, the DL model works like a black box, which does not represent why these images are misclassified. In these situations, visualization is essential to display the infected region of the lung to the clinician in a more transparent manner. To overcome the transparency problem for the DL researcher, they applied Grad-CAM [308] visualization to show the infected region of the chest X-ray image.

Conclusions and Possible Future Work

This article reviews the various DL and ML approaches for detecting COVID-19 from various radiographic images. Moreover, the most popular pre-trained and custom-built CNN architectures were discussed. The datasets used in various research are explained, as well as the shortcomings of current techniques. Our study has found that custom CNN approaches have a lot of promise for automatic COVID-19 diagnosis from the already available datasets. Here, we discussed how to deal with a variety of problems. We hope that this article will assist researchers in selecting the appropriate network structure for their topic, and be aware of potential problems and solutions. Medical professionals and computer scientists, on the other hand, should collaborate closely to confirm the use of CNN approaches by combining their respective skills.

Several researchers applied conventional transfer learning algorithms to COVID-19 research using radiographic images. Hybrid heterogeneous transfer learning will be used in the future to bridge the gap with the small radiography dataset. Apart from the dataset's limited number of images, multiclass lung disease might be another useful, efficient, and accurate COVID-19 diagnosis method. In some cases, radiological instruments may not be able to produce high-quality images suitable for DL training. Another technique for detecting COVID-19 from noisy and unclear images in this situation is to employ synthetic image synthesis. It is far better than their previous version in synthetic image generation, with the advantage of a smaller number of images for COVID-19 research. Other approaches can benefit from the scarcity of training data for the COVID-19 class that is few-shot, zero-shot, and deep reinforcement learning. These approaches ensure

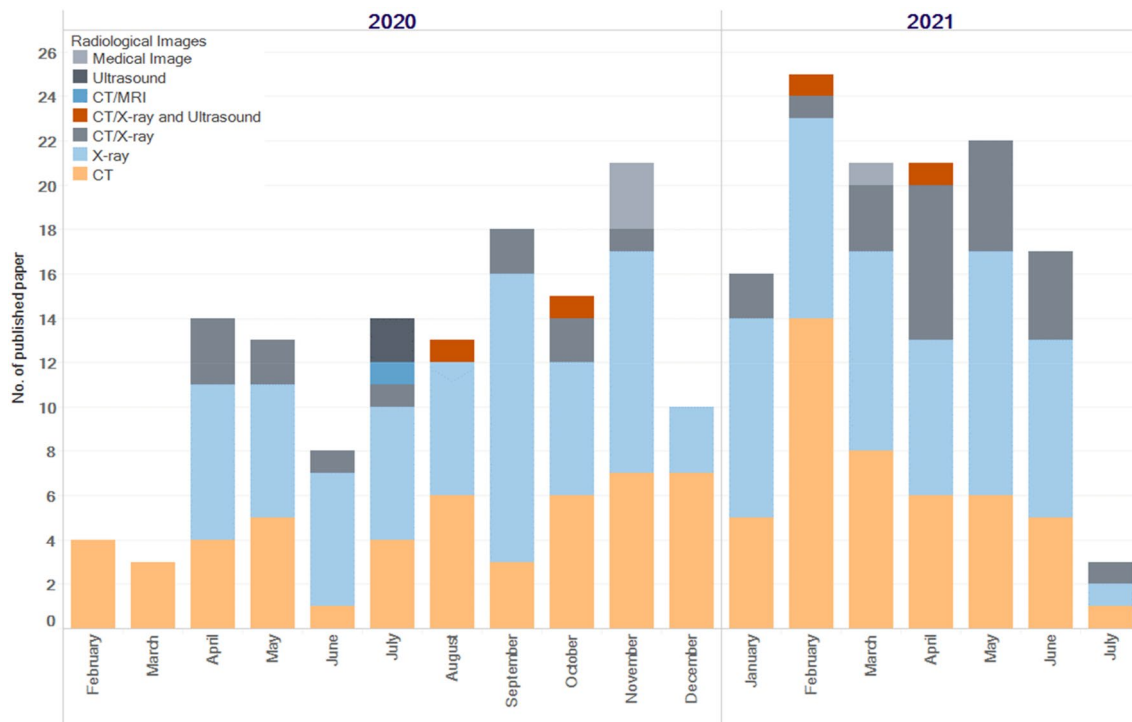


Fig. 11 Papers published in the last 2 years based on various medical imaging formats, from February 2020 to July 2021

minimal human intervention in the diagnosis. Aside from working with a few images in several datasets to avoid overfitting or undefining, the well-defined DL architecture is also a significant concern in this research. In the future, analyzing the several DL and ML architectures and their supporting methods will make them reliable and efficient models for diagnosis in a more resource-friendly and time-efficient manner.

Acknowledgements The third author would like to acknowledge Indian Council of Medical Research, GoI, for support [Ref. no. BMI/12(81)/2021] to carry out this work.

Declarations

Conflict of Interest The authors declare that there is no conflict of interest. The authors declare that there are no human participants and/or animals involved in this study. The authors also declare that they have no known competing financial interests or personal relationships that could have appeared to influence the work reported in this paper.

References

- Zhou L, Li Z, Zhou J, Li H, Chen Y, Huang Y, Xie D, Zhao L, Fan M, Hashmi S, Abdelkareem F, Eiada R, Xiao X, Li L, Qiu Z, Gao X. A rapid, accurate and machine-agnostic segmentation and quantification method for CT-Based COVID-19 Diagnosis. *IEEE Trans Med Imag.* 2020;39(8):2638–52. <https://doi.org/10.1109/TMI.2020.3001810>.
- Gupta A, Anjum, Gupta S, Katarya R. InstaCovNet-19: A deep learning classification model for the detection of COVID-19 patients using Chest X-ray. *Appl Soft Comput J.* 2020;99:106859. <https://doi.org/10.1016/j.asoc.2020.106859>.
- Majeed T, Rashid R, Ali D, Asaad A. Issues associated with deploying CNN transfer learning to detect COVID-19 from chest X-rays. *Phys Eng Sci Med.* 2020. <https://doi.org/10.1007/s13246-020-00934-8>.
- Hwang EJ, Kim H, Yoon SH, Goo JM, Park CM. Implementation of a deep learning-based computer-aided detection system for the interpretation of chest radiographs in patients suspected for covid-19. *Korean J Radiol.* 2020;21(10):1150–60. <https://doi.org/10.3348/kjr.2020.0536>.
- Laskar R, Ali S. Phylo-geo-network and haplogroup analysis of 611 novel Coronavirus (nCov-2019) genomes from India. *bioRxiv*, p. 2020.09.03.281774, 2020, [Online]. Available: <https://doi.org/10.1101/2020.09.03.281774>
- W. Official. Naming the coronavirus disease (COVID-19) and the virus that causes it. 2019. 2019, [Online]. Available: [https://www.who.int/emergencies/diseases/novel-coronavirus-2019/technical-guidance/naming-the-coronavirus-disease-\(covid-2019\)-and-the-virus-that-causes-it#:~:text=The official names are%3A,Virus](https://www.who.int/emergencies/diseases/novel-coronavirus-2019/technical-guidance/naming-the-coronavirus-disease-(covid-2019)-and-the-virus-that-causes-it#:~:text=The official names are%3A,Virus)
- Latest W, Information M, Version E. Mutational analysis and assessment of its impact on proteins of SARS-CoV-2 genomes from India. *Gene.* 2020;45:122–3.
- Chen Y. COVID-19: A Necessity for Changes and Innovations. 2021;60. doi: https://doi.org/10.1007/978-981-15-9682-7_6.
- Zhu N, Zhang D, Wang W, Li X, Yang B, Song J, Zhao X, Huang B, Shi W, Lu R, Niu P, Zhan F, Ma X, Wang D, Xu W, Wu G,

- Gao GF, Tan W. Use of chest CT in combination with negative RT-PCR assay for the 2019 novel coronavirus but high clinical suspicion. *N Engl J Med.* 2020;382(8):727–33. <https://doi.org/10.1056/nejmoa2001017>.
10. Dipayan D, Santosh KC, Pal U. Inception-based Deep Learning Architecture for Tuberculosis Screening using Chest X-rays. *IEEE*, 2021;3612--3619.
 11. Keshavarzi Arshadi A, Webb J, Salem M, Cruz E, Calad-Thomson S, Ghadirian N, Collins J, Diez-Cecilia E, Kelly B, Goodarzi H, Yuan JS. Artificial Intelligence for COVID-19 Drug Discovery and Vaccine Development. *Front Artif Intell.* 2020;3(August):1–13. <https://doi.org/10.3389/frai.2020.00065>.
 12. Mukherjee H, Das B, Das S, Dhar A, Sk MO, Santosh K, Phadikar S, Roy K. Deep Neural Network Pneumonia Detection using Chest X-rays. Allahabad, India: Computer Vision & Image Processing; 2021.
 13. Khan AI, Shah JL, Bhat MM. CoroNet: A deep neural network for detection and diagnosis of COVID-19 from chest x-ray images. *Comput Methods Programs Biomed.* 2020;196:105581. <https://doi.org/10.1016/j.cmpb.2020.105581>.
 14. Ghaderzadeh M, Asadi F. Deep Learning in the Detection and Diagnosis of COVID-19 Using Radiology Modalities: A Systematic Review. *J. Healthc. Eng.* 2021; 2021, doi: <https://doi.org/10.1155/2021/6677314>.
 15. Dino HI, Zeebaree SRM, Hasan DA, Abdulrazzaq MB, Haji LM, Shukur HM. COVID-19 diagnosis systems based on deep convolutional neural networks techniques: a review. 3rd Int Conf Adv Sci Eng ICOASE. 2020;2020:184–9. <https://doi.org/10.1109/ICOASE51841.2020.9436542>.
 16. Liao Z, Lan P, Fan X, Kelly B, Innes A, Liao Z. SIRVD-DL: A COVID-19 deep learning prediction model based on time-dependent SIRVD. *Comput Biol Med.* 2021;138(September):104868. <https://doi.org/10.1016/j.compbimed.2021.104868>.
 17. Naseem M, Akhund R, Arshad H, Ibrahim MT. Exploring the Potential of Artificial Intelligence and Machine Learning to Combat COVID-19 and Existing Opportunities for LMIC: A Scoping Review. *J. Prim. Care Community Heal.* 2020;11. doi: <https://doi.org/10.1177/2150132720963634>.
 18. D. Wu, K. Gong, C. Arru, F. Homayounieh, B. Bizzo, V. Buch, H. Ren, K. Kim, N. Neumark, W. Y. Tak MK, Kang A, Carriero L, Saba I, Dayan M, Masjedi R, Babaei MK, Kalra, Li Q. Severity and Consolidation Quantification of COVID-19 from CT Images Using Deep Learning Based on Hybrid Weak Labels. *IEEE J. Biomed. Heal. Informatics* 2020;2194(c), doi: <https://doi.org/10.1109/JBHI.2020.3030224>.
 19. Sufian A, Ghosh A, Sadiq AS, Smarandache F. A survey on deep transfer learning to edge computing for mitigating the COVID-19 pandemic: DTL-EC. *J Syst Archit.* 2020;108:101830. <https://doi.org/10.1016/j.sysarc.2020.101830>.
 20. Allam Z, Jones DS. On the Coronavirus (COVID-19) Outbreak and the Smart City Network: universal data sharing standards coupled with Artificial Intelligence (AI) to benefit urban health monitoring and management. *Healthcare.* 2020;8(1):46. <https://doi.org/10.3390/healthcare8010046>.
 21. Asraf A, Islam MZ, Haque MR, Islam MM. Deep Learning Applications to Combat Novel Coronavirus (COVID-19) Pandemic. *SN Comput Sci.* 2020;1(6):1–7. <https://doi.org/10.1007/s42979-020-00383-w>.
 22. Ray T. Machine learning designed a COVID-19 vaccine that could cover a lot more people. MIT, 2021. <https://www.fda.gov/media/143737/download/>
 23. Almezghwi K, Serte S, Al-Turjman F. Convolutional neural networks for the classification of chest X-rays in the IoT era. *Multimed Tools Appl.* 2021. <https://doi.org/10.1007/s11042-021-10907-y>.
 24. Gupta D, Bhatt S, Gupta M, Tosun AS. Future smart connected communities to fight COVID-19 outbreak. *arXiv*, 2020;100342. doi: <https://doi.org/10.1016/j.ijot.2020.100342>.
 25. Zoabi Y, Deri-Rozov S, Shomron N. Machine learning-based prediction of COVID-19 diagnosis based on symptoms. *npj Digit Med.* 2021;4(1):1–5. <https://doi.org/10.1038/s41746-020-00372-6>.
 26. García LF. Immune Response, Inflammation, and the Clinical Spectrum of COVID-19. *Front Immunol.* 2020;11(June):4–8. <https://doi.org/10.3389/fimmu.2020.01441>.
 27. Lorencin I, Šegota SB, Anđelić N, Blagojević ANĐELA, Šušteršić T, Protic A, Arsenijević M, Cabov T, Filipović N, Car Z. Automatic evaluation of the lung condition of COVID-19 patients using X-ray images and convolutional neural networks. *J Pers Med.* 2021;11(1):1–31. <https://doi.org/10.3390/jpm11010028>.
 28. Arpacı I, Huang S, Al-Emran M, Al-Kabi MN, Peng M. Predicting the COVID-19 infection with fourteen clinical features using machine learning classification algorithms. *Multimed Tools Appl.* 2021;80(8):11943–57. <https://doi.org/10.1007/s11042-020-10340-7>.
 29. Ren HW, Wu Y, Dong JH, An WM, Yan T, Liu Y, Liu CC. Analysis of clinical features and imaging signs of COVID-19 with the assistance of artificial intelligence. *Eur Rev Med Pharmacol Sci.* 2020;24(15):8210–8. https://doi.org/10.26355/eurrev_202008_22510.
 30. Cai W, Liu T, Xue X, Luo G, Wang X, Shen Y, Fang Q, Sheng J, Chen F, Liang T. CT quantification and machine-learning models for assessment of disease severity and prognosis of COVID-19 patients. *Acad Radiol.* 2020;27(12):1665–78. <https://doi.org/10.1016/j.acra.2020.09.004>.
 31. Abdulaal A, Patel A, Charani E, Denny S, Alqahtani SA, Davies GW, Mughal N, Moore LSP. Comparison of deep learning with regression analysis in creating predictive models for SARS-CoV-2 outcomes. *BMC Med Inform Decis Mak.* 2020;20(1):1–11. <https://doi.org/10.1186/s12911-020-01316-6>.
 32. Gao Y, Cai GY, Fang W, Li HY, Wang SY, Chen L, Yu Y, Liu D, Xu S, Cui PF, Zeng SQ, Feng XX, Di Yu R, Wang Y, Yuan Y, Jiao XF, Chi JH, Liu JH, Li RY, Zheng X, Song CY, Jin N, Gong WJ, Liu XY, Huang L, Tian X, Li L, Xing H, Ma D, Li CR, Ye F, Gao QL. Machine learning based early warning system enables accurate mortality risk prediction for COVID-19. *Nat Commun.* 2020;11(1):1–10. <https://doi.org/10.1038/s41467-020-18684-2>.
 33. Moher D, Liberati A, Tetzlaff J, Altman DG. Preferred reporting items for systematic reviews and meta-analyses: The PRISMA statement. *Int J Surg.* 2010;8(5):336–41. <https://doi.org/10.1016/j.jisu.2010.02.007>.
 34. Nabavi S, Ejmalian A, Moghaddam ME, Abin AA, Frangi AF, Mohammadi M, Rad HS. Medical imaging and computational image analysis in COVID-19 diagnosis: A review. *Comput Biol Med.* 2021;135(November):104605. <https://doi.org/10.1016/j.compbimed.2021.104605>.
 35. Mohamed Y, Abdallah Y, Alqahtani T. Research in Medical Imaging Using Image Processing Techniques. *Med. Imaging - Princ. Appl.* [Working Title], 2019. doi: <https://doi.org/10.5772/intechopen.84360>.
 36. Importance of Radiology | Ontario Association of Radiologists. <https://oarinfo.ca/radiologists/importanceradiology#:~:text=Understanding%20the%20Role%20of%20Radiology&text=Radiology's%20role%20is%20central%20to,structural%20or%20disease%20related%20changes>
 37. “X-Ray vs. CT vs. MRI,” *Envision Radiology*. <https://www.envrad.com/difference-between-x-ray-ct-scan-and-mri/>

38. Bhandary A, Prabhu GA, Rajinikanth V, Thanaraj KP, Satapathy SC, Robbins DE, Shasky C, Zhang YD, Tavares JMRS, Raja NSM. Deep-learning framework to detect lung abnormality – A study with chest X-Ray and lung CT scan images. *Pattern Recognit Lett.* 2020;129:271–8. <https://doi.org/10.1016/j.patrec.2019.11.013>.
39. Gu Y, Kumar V, Hall LO, Goldgof DB, Li CY, Korn R, Bendtsen C, Velazquez ER, Dekker A, Aerts H, Lambin P, Li X, Tian J, Gatenby RA, Gillies RJ. Automated delineation of lung tumors from CT images using a single click ensemble segmentation approach. *Pattern Recognit.* 2013;46(3):692–702. <https://doi.org/10.1016/j.patcog.2012.10.005>.
40. Fred HL. Drawbacks and limitations of computed tomography: Views from a medical educator. *Texas Hear Inst J.* 2004;31(4):345–8.
41. Deserno TM. *Fundamentals of Medical Image Processing.* pp. 1139–1165.
42. Tamal M, Alshammari M, Alabdullah M, Hourani R, Alola HA, Hegazi TM. An integrated framework with machine learning and radiomics for accurate and rapid early diagnosis of COVID-19 from Chest X-ray. *Expert Syst Appl.* 2021;180:115152. <https://doi.org/10.1016/j.eswa.2021.115152>.
43. Kim T, Son J, Kim K. The Recent Progress in Quantitative Medical Image Analysis for Computer Aided Diagnosis Systems. 2014;(September 2011) doi: <https://doi.org/10.4258/hir.2011.17.3.143>.
44. Wan Y, Zhou H, Zhang X. An interpretation architecture for deep learning models with the application of COVID-19 diagnosis. *Entropy.* 2021;23(2):1–19. <https://doi.org/10.3390/e23020204>.
45. Gao K, Su J, Jiang Z, Zeng LL, Feng Z, Shen H, Rong P, Xu X, Qin J, Yang Y, Wang W, Hu D. Dual-branch combination network (DCN): Towards accurate diagnosis and lesion segmentation of COVID-19 using CT images. *Med Image Anal.* 2021;67:101836. <https://doi.org/10.1016/j.media.2020.101836>.
46. Shi G, Wu Y, Palaiahnakote S, Pal U, Lu T. ARNET : ACTIVE-REFERENCE NETWORK FOR FEW-SHOT IMAGE SEMANTIC SEGMENTATION College of Computer and Information , Hohai University Department of Computer System and Information Technology , University of Malaya , Computer Vision and Pattern Recognition Unit. 2021;6–11.
47. Thengade A, Rajurkar A. A Comprehensive Survey of Articular Cartilage Segmentation Methods on Knee MRI. *Int J Adv Sci Technol.* 2019;27(1):148–59.
48. Hesamian MH, Jia W, He X, Kennedy P. Deep Learning Techniques for Medical Image Segmentation: Achievements and Challenges. *J Digit Imaging.* 2019;32(4):582–96. <https://doi.org/10.1007/s10278-019-00227-x>.
49. Voulodimos A, Protopapadakis E, Katsamenis I, Doulamis A. A Few-Shot U-Net Deep Learning Model for COVID-19 Infected Area Segmentation in CT Images. pp. 1–22, 2021.
50. Saood A, Hatem I. COVID - 19 lung CT image segmentation using deep learning methods : U - Net versus SegNet. *BMC Med. Imaging* 2021;1–10. doi: <https://doi.org/10.1186/s12880-020-00529-5>.
51. Amyar A, Modzelewski R, Li H, Ruan S. Multi-task deep learning based CT imaging analysis for COVID-19 pneumonia: Classification and segmentation. *Comput Biol Med.* 2020;126(October):104037. <https://doi.org/10.1016/j.combiomed.2020.104037>.
52. Ranjbarzadeh R, Jafarzadeh Ghouschi S, Bendeche M, Amirabadi A, Ab Rahman MN, Baseri Saadi S, Aghamohammadi A, Kooshki Forooshani M. Lung Infection Segmentation for COVID-19 Pneumonia Based on a Cascade Convolutional Network from CT Images. *Biomed Res. Int.* 2021; 2021, doi: <https://doi.org/10.1155/2021/5544742>.
53. Ma J, Wang Y, An X, Ge C, Yu Z, Chen J, Zhu Q, Dong G, He J, He Z, Cao T, Zhu Y, Nie Z, Yang X. Toward data-efficient learning: A benchmark for COVID-19 CT lung and infection segmentation. *Med Phys.* 2021;48(3):1197–210. <https://doi.org/10.1002/mp.14676>.
54. Budak Ü, Çibuk M, Cömert Z, Şengür A. Efficient COVID-19 Segmentation from CT Slices Exploiting Semantic Segmentation with Integrated Attention Mechanism. *J. Digit. Imaging.* 20210123456789. doi: <https://doi.org/10.1007/s10278-021-00434-5>.
55. Qiu B, Van Der Wel H, Kraeima J, Glas HH, Guo J, Borra RJH, Johannes M, Witjes H, Van Ooijen PMA. Automatic Segmentation of Mandible from Conventional Methods to Deep Learning — A Review,” 2021.
56. Teixeira LO, Pereira RM, Bertolini D, Oliveira LS, Nanni L, Cavalcanti GDC, Costa YMG. Impact of lung segmentation on the diagnosis and explanation of COVID-19 in chest X-ray images. pp. 1–16, 2020, [Online]. Available: <http://arxiv.org/abs/2009.09780>
57. Lizancos Vidal P, de Moura J, Novo J, Ortega M. Multi-stage transfer learning for lung segmentation using portable X-ray devices for patients with COVID-19. *Expert Syst. Appl.,* 2021;173. doi: <https://doi.org/10.1016/j.eswa.2021.114677>.
58. Rahman MF, Tseng T-LB, Pokojovy M, Qian W, Totada B, Xu H. An automatic approach to lung region segmentation in chest x-ray images using adapted U-Net architecture. 2021;(February): 180. doi: <https://doi.org/10.1117/12.2581882>.
59. Laradji I, Rodriguez P, Manas O, Lensink K, Law M, Kurzman L, Parker W, Vazquez D, Nowrouzezahrai D. A Weakly Supervised Consistency-based Learning Method for COVID-19 Segmentation in CT Images. 2021;2452–2461. doi: <https://doi.org/10.1109/wacv48630.2021.00250>.
60. Walvekar S, Shinde S. Efficient medical image segmentation of COVID-19 Chest CT images based on deep learning techniques. *2021 Int. Conf. Emerg. Smart Comput. Informatics, ESCI 2021,* 2021;203–206. doi: <https://doi.org/10.1109/ESCI50559.2021.9397043>.
61. Saedzadeh N, Minaee S, Kafieh R, Yazdani S, Sonka M. (2021) COVID TV-Unet: segmenting COVID-19 chest CT images using connectivity imposed Unet. *Comput Methods Programs Biomed Updat.* 2020;1:100007. <https://doi.org/10.1016/j.cmpbup.2021.100007>.
62. Wu YH, Gao SH, Mei J, Xu J, Fan DP, Zhang RG, Cheng MM. JCS: An Explainable COVID-19 Diagnosis System by Joint Classification and Segmentation. *IEEE Trans Image Process.* 2021;30(5):3113–26. <https://doi.org/10.1109/TIP.2021.3058783>.
63. Ter-Sarkisov A. One Shot Model For COVID-19 Classification and Lesions Segmentation In Chest CT Scans Using LSTM With Attention Mechanism. *medRxiv.* p. 2021.02.16.21251754, 2021, [Online]. Available: <http://medrxiv.org/content/early/2021/02/19/2021.02.16.21251754.abstract>
64. Chandrasekaran B, Fernandes S. SUFMACS: A machine learning-based robust image segmentation framework for COVID-19 radiological image interpretation. *Diabetes Metab Syndr.* 2020;14(4)(January):337–9.
65. Ergen B and Zafer C, “COVID-19 detection using deep learning models to exploit Social Mimic Optimization and structured chest X-ray images using fuzzy color and stacking approaches,” no. January, 2020.
66. Lu D, Weng Q. A survey of image classification methods and techniques for improving classification performance. *Int J Remote Sens.* 2007;28(5):823–70. <https://doi.org/10.1080/0143160600746456>.
67. Houssein EH, Abohashima Z, Elhoseny M, Mohamed MW. Hybrid quantum convolutional neural networks model for

- COVID-19 prediction using chest X-Ray images. 2021, [Online]. Available: <http://arxiv.org/abs/2102.06535>
68. Santosh K, Ghosh S. Covid-19 Imaging Tools: How Big Data is Big?. *J. Med. Syst.*, 2021;45(7). doi: <https://doi.org/10.1007/s10916-021-01747-2>.
 69. Misztal K, Pocha A, Durak-Kozica M, Wator M, Kubica-Misztal A, Hartel M. The importance of standardisation – COVID-19 CT & Radiograph Image Data Stock for deep learning purpose. *Comput. Biol. Med.*, 2020;127(January), doi: <https://doi.org/10.1016/j.compbiomed.2020.104092>.
 70. Rehouma R, Buchert M, Chen YPP. Machine learning for medical imaging-based COVID-19 detection and diagnosis. *Int. J. Intell. Syst.*, 2021;(February):1–31. doi: <https://doi.org/10.1002/int.22504>.
 71. S. Syedhusain, S. Vairaprakash, Nayagam R. D., K. Mahendran, S. Sakthimani (2021) MDCNN - Modified Deep Convolutional Neural Network System for Classifying COVID-19 Image Dataset. 25(5), 1667–1680.
 72. Alghamdi HS, Amoudi G, Elhag S, Saeedi K, Nasser J. Deep Learning Approaches for Detecting COVID-19 from Chest X-Ray Images: A Survey. *IEEE Access*. 2021;9:20235–54. <https://doi.org/10.1109/ACCESS.2021.3054484>.
 73. Padma T, Usha Kumari C. Deep Learning Based Chest X-Ray Image as a Diagnostic Tool for COVID-19,” *Proc. - Int. Conf. Smart Electron. Commun. ICOSCE 2020*, 2020;(Icosce), 589–592. doi: <https://doi.org/10.1109/ICOSCE49089.2020.9215257>.
 74. Rahman T, Khandakar A, Qiblawey Y, Tahir A, Kiranyaz S, Bin Abul Kashem S, Islam MT, Al Maadeed S, Zughaier SM, Khan MS, Chowdhury MEH. Exploring the effect of image enhancement techniques on COVID-19 detection using chest X-ray images”. *Comput Biol Med*. 2021;132:104319. <https://doi.org/10.1016/j.compbiomed.2021.104319>.
 75. Narin A, Kaya C, Pamuk Z. Automatic Detection of Coronavirus Disease (COVID-19) Using X-ray Images and Deep Convolutional Neural Networks. *arXiv Prepr. arXiv2003.10849.*, 2020, [Online]. Available: <https://arxiv.org/abs/2003.10849>
 76. Apostolopoulos ID, Mpesiana TA. Covid-19: automatic detection from X-ray images utilizing transfer learning with convolutional neural networks. *Phys Eng Sci Med*. 2020;43(2):635–40. <https://doi.org/10.1007/s13246-020-00865-4>.
 77. Panwar H, Gupta PK, Siddiqui MK, Morales-Menendez R, Singh V. Application of deep learning for fast detection of COVID-19 in X-Rays using nCOVnet. *Chaos, Solitons Fractals*. 2020;138:109944. <https://doi.org/10.1016/j.chaos.2020.109944>.
 78. Jain R, Gupta M, Taneja S, Hemanth DJ. Deep learning based detection and analysis of COVID-19 on chest X-ray images. *Appl Intell*. 2020. <https://doi.org/10.1007/s10489-020-01902-1>.
 79. Albahli S, Albattah W. Detection of coronavirus disease from X-ray images using deep learning and transfer learning algorithms. *J Xray Sci Technol*. 2020;28(5):841–50. <https://doi.org/10.3233/XST-200720>.
 80. Heidari M, Mirniaharikandehei S, Khuzani AZ, Danala G, Qiu Y, Zheng B. Improving the performance of CNN to predict the likelihood of COVID-19 using chest X-ray images with preprocessing algorithms. *Int J Med Inform*. 2020;144(September):104284. <https://doi.org/10.1016/j.ijmedinf.2020.104284>.
 81. Mohammadi R, Salehi M, Ghaffari H, Rohani AA, Reiazi R. Transfer learning-based automatic detection of coronavirus disease 2019 (COVID-19) from chest x-ray images. *J Biomed Phys Eng*. 2020;10(5):559–68. <https://doi.org/10.31661/jbpe.v0i0.2008-1153>.
 82. Wang D, Mo J, Zhou G, Xu L, Liu Y. An efficient mixture of deep and machine learning models for COVID-19 diagnosis in chest X-ray images. *PLoS ONE*. 2020;15(11):e0242535. <https://doi.org/10.1371/journal.pone.0242535>.
 83. Fontanellaz M, Ebner L, Huber A, Peters A, Löbelenz L, Horsch C, Klaus J, Munz J, Ruder T, Drakopoulos D, Sieron D, Primitis E, Heverhagen JT, Mougiakakou S, Christe A. A deep-learning diagnostic support system for the detection of COVID-19 using chest radiographs: a multireader validation study. *Invest Radiol*. 2021;56(6):348–56. <https://doi.org/10.1097/RLI.0000000000000748>.
 84. Strunk JL, Temesgen H, Andersen H, Packalen P. Correlation of Chest CT and RT-PCR Testing in Coronavirus Disease 2019 (COVID-19) in China: a report of 1014 Cases. *Radiology*. 2014;80(2):1–8. <https://doi.org/10.14358/PERS.80.2.000>.
 85. Ye Z, Zhang Y, Wang Y, Huang Z, Song B. Chest CT manifestations of new coronavirus disease 2019 (COVID-19): a pictorial review. *Eur Radiol*. 2020;30(8):4381–9. <https://doi.org/10.1007/s00330-020-06801-0>.
 86. Tello-Mijares S, Woo L. Computed Tomography Image Processing Analysis in COVID-19 Patient Follow-Up Assessment. *J. Healthc. Eng*. 2021; 2021, doi: <https://doi.org/10.1155/2021/8869372>.
 87. Chung M, Bernheim A, Mei X, Zhang N, Huang M, Zeng X, Cui J, Xu W, Yang Y, Fayad ZA, Jacobi A, Li K, Li S, Shan H. CT imaging features of 2019 novel coronavirus (2019-nCoV). *Radiology*. 2020;295(1):202–7. <https://doi.org/10.1148/radiol.2020200230>.
 88. Li Y, Xia L. Coronavirus disease 2019 (COVID-19): Role of chest CT in diagnosis and management. *Am J Roentgenol*. 2020;214(6):1280–6. <https://doi.org/10.2214/AJR.20.22954>.
 89. Zhou T, Lu H, Yang Z, Qiu S, Huo B, and Dong Y. The ensemble deep learning model for novel COVID-19 on CT images. *Appl. Soft Comput.*, 2020;(xxxx), 106885. doi: <https://doi.org/10.1016/j.asoc.2020.106885>.
 90. Kamnitsas K, Ledig C, Newcombe VFJ, Simpson JP, Kane AD, Menon DK, Rueckert D, Glocker B. Efficient multi-scale 3D CNN with fully connected CRF for accurate brain lesion segmentation. *Med Image Anal*. 2017;36:61–78. <https://doi.org/10.1016/j.media.2016.10.004>.
 91. Yan T, Wong PK, Ren H, Wang H, Wang J, Li Y. Automatic distinction between COVID-19 and common pneumonia using multi-scale convolutional neural network on chest CT scans. *Chaos, Solitons Fractals*. 2020;140:110153. <https://doi.org/10.1016/j.chaos.2020.110153>.
 92. Wang S, Kang B, Ma J, Zeng X, Xiao M, Guo J, Cai M, Yang J, Li Y, Meng X, Xu B. A deep learning algorithm using CT images to screen for Corona virus disease (COVID-19). *Eur Radiol*. 2021. <https://doi.org/10.1007/s00330-021-07715-1>.
 93. Fang L, Wang X. COVID-19 deep classification network based on convolution and deconvolution local enhancement. *Comput Biol Med*. 2021;135(May):104588. <https://doi.org/10.1016/j.compbiomed.2021.104588>.
 94. Zhang X, Wang D, Shao J, Tian S, Tan W, Ma Y, Xu Q, Ma X, Li D, Chai J, Wang D, Liu W, Lin L, Wu J, Xia C, Zhang Z. A deep learning integrated radiomics model for identification of coronavirus disease 2019 using computed tomography. *Sci Rep*. 2021;11(1):1–12. <https://doi.org/10.1038/s41598-021-83237-6>.
 95. Shan F, Gao Y, Wang J, Shi W, Shi N, Han M, Xue Z, Shen D, Shi Y. Abnormal Lung Quantification in Chest CT Images of COVID-19 Patients with Deep Learning and its Application to Severity Prediction. *Med Phys*. 2020;48(4):1633–45. <https://doi.org/10.1002/mp.14609>.
 96. Ying S, Zheng S, Li L, Zhang X, Zhang X, Huang Z, Chen J, Zhao H, Wang R, Chong Y, Shen J, Zha Y, Yang Y. Deep learning enables accurate diagnosis of novel coronavirus (COVID-19) with CT images. *medRxiv*, 2020;(February). doi: <https://doi.org/10.1101/2020.02.23.20026930>.

97. Wang H, Wang L, Lee EH, Zheng J, Zhang W, Halabi S, Liu C, Deng K, Song J, Yeom KW. Decoding COVID-19 pneumonia: comparison of deep learning and radiomics CT image signatures. *Eur J Nucl Med Mol Imaging*. 2020. <https://doi.org/10.1007/s00259-020-05075-4>.
98. Tao Zhang H, Song Zhang J, Hua Zhang H, Dong Nan Y, Zhao Y, Qing Fu E, Hong Xie Y, Liu W, Ping Li W, Jun Zhang H, Jiang H, Mei Li C, Yan Li Y, Na Ma R, Kang Dang S, Bo Gao B, Jing Zhang X, Zhang T. Automated detection and quantification of COVID-19 pneumonia: CT imaging analysis by a deep learning-based software. *Eur J Nucl Med Mol Imag*. 2020;47(11):2525–32. <https://doi.org/10.1007/s00259-020-04953-1>.
99. Ghomi Z, Mirshahi R, Bagheri AK, Fattahpour A, Mohammadiun S, Gharahbagh AA, Djavadifar A, Arabalibeik H, Sadiq R, Hewage K. Segmentation of COVID-19 pneumonia lesions: A deep learning approach. *Med J Islam Repub Iran*. 2020;34(1):1–7. <https://doi.org/10.34171/mjiri.34.174>.
100. Fei Shan YS, Yaozong Gao, Jun Wang, Weiya Shi, Nannan Shi, Miaofei Han, Zhong Xue, Dinggang Shen. Lung Infection Quantification of COVID-19 in CT Images with Deep Learning. 2020;(15), 235–250.
101. Zheng F, Li L, Zhang X, Song Y, Huang Z, Chong Y, Chen Z, Zhu H, Wu J, Chen W, Lu Y, Yang Y, Zha Y, Zhao H, Shen J. Accurately Discriminating COVID-19 from Viral and Bacterial Pneumonia According to CT Images Via Deep Learning. *Interdiscip Sci Comput Life Sci*. 2021;13(2):273–85. <https://doi.org/10.1007/s12539-021-00420-z>.
102. Nagarajan B, Autkar G, Monga A, Toshniwal N. Lung Manifestations of COVID-19 on Chest Radiographs—Indian Experience in a High-Volume Dedicated COVID center. *SN Compr Clin Med*. 2021;3(1):16–21. <https://doi.org/10.1007/s42399-020-00643-z>.
103. Elkholy KO, Hegazy O, Erdinc B, Abowali H. Ivermectin: A Closer Look at a Potential Remedy. *Cureus*. 2020;21(January):12593–608. <https://doi.org/10.7759/cureus.10378>.
104. Xiang C, Huang L, Xia L. Mobile chest X-ray manifestations of 54 deceased patients with coronavirus disease 2019: Retrospective study. *Medicine (Baltimore)*. 2020;99(46):e23167. <https://doi.org/10.1097/MD.00000000000023167>.
105. Revzin MV, Raza S, Warshawsky R, D'agostino C, Srivastava NC, Bader AS, Malhotra A, Patel RD, Chen K, Kyriakakos C, Pellerito JS. Multisystem imaging manifestations of covid-19, part 1: Viral pathogenesis and pulmonary and vascular system complications. *Radiographics*. 2020;40(6):1574–99. <https://doi.org/10.1148/rg.2020200149>.
106. Kumar I. Deep Learning Method for Quantitative Analysis of Covid -19 using CT Chest Images.
107. Munster VJ, Koopmans M, van Doremalen N, van Riel D, de Wit E. CT Imaging of the 2019 Novel Coronavirus (2019-nCoV) Pneumonia. *N Engl J Med*. 2020;382(8):692–4. <https://doi.org/10.1056/nejmp2000929>.
108. Hansell DM, Bankier AA, MacMahon H, McLoud TC, Müller NL, Remy J. Fleischner society: glossary of terms for thoracic imaging. *Radiology*. 2008;246(3):697–722. <https://doi.org/10.1148/radiol.2462070712>.
109. Covid- CD, Pan F, Ye T, Sun P, Gui S, Liang B, Li L. Time Course of Lung Changes at Chest CT during Recovery". *Radiology*. 2020;295(3):715–21. <https://doi.org/10.1148/radiol.2020200370>.
110. Xu Z, Shi L, Wang Y, Zhang J, Huang L, Zhang C, Liu S, Zhao P, Liu H, Zhu L, Tai Y, Bai C, Gao T, Song J, Xia P, Dong J, Zhao J, Wang FS. Pathological findings of COVID-19 associated with acute respiratory distress syndrome. *Lancet Respir Med*. 2020;8(4):420–2. [https://doi.org/10.1016/S2213-2600\(20\)30076-X](https://doi.org/10.1016/S2213-2600(20)30076-X).
111. Klironomos S, Tzortzakakis A, Kits A, Öhberg C, Kollia E, Aho-romazdae A, Almqvist H, Aspelin Å, Martin H, Ouellette R, Al-Saadi J, Hasselberg M, Haghgou M, Pedersen M, Petersson S, Finnsson J, Lundberg J, Delgado AF, Granberg T. Nervous system involvement in coronavirus disease 2019: Results from a retrospective consecutive neuroimaging cohort. *Radiology*. 2020;297(3):E324–34. <https://doi.org/10.1148/radiol.2020202791>.
112. Zhang Y, Xue H, Wang M, He N, Lv Z, Cui L. Lung ultrasound findings in patients with coronavirus disease (COVID-19). *Am J Roentgenol*. 2021;216(1):80–4. <https://doi.org/10.2214/AJR.20.23513>.
113. Ultrasound in COVID-19: a timeline of ultrasound findings in relation to CT. 2020;(January).
114. Allinovi M, Parise A, Giacalone M, Amerio A, Delsante M, Odone A, Franci A, Gigliotti F, Amadasi S, Delmonte D, Parri N, Mangia A. Lung Ultrasound may support diagnosis and monitoring of COVID-19 Pneumonia. *Ultrasound Med Biol*. 2020;46(11):2908–17. <https://doi.org/10.1016/j.ultrasmedbio.2020.07.018>.
115. Mukherjee H, Sreerama P, Dhar A, Obaidullah SM, Roy K, Mahmud M, Santosh KC (2021) Automatic Lung Health Screening Using Respiratory Sounds. *J. Med. Syst.*, 2021;45(2) doi: <https://doi.org/10.1007/S10916-020-01681-9>.
116. Narayan Das N, Kumar N, Kaur M, Kumar V, Singh D. Automated Deep transfer learning-based approach for detection of COVID-19 Infection in Chest X-rays. *Irbm*. 2020;1:1–6. <https://doi.org/10.1016/j.irbm.2020.07.001>.
117. Chanda PB, Banerjee S, Dalai V, Ray R. CNN based transfer learning framework for classification of COVID-19 disease from chest X-ray. *Proc. - 5th Int. Conf. Intell. Comput. Control Syst. ICIACS 2021*, 2021; Iccics, 1367–1373 doi: <https://doi.org/10.1109/ICIACS51141.2021.9432181>.
118. Priyatharshini R, Aswath RAS, Sreenidhi MN, Joshi SS, Dhandapani R. An Efficient Approach for Automatic detection of COVID-19 using Transfer Learning from Chest X-Ray Images. 2021; (May), 741–746. doi: <https://doi.org/10.1109/icpsc51351.2021.9451819>.
119. Rezaee K, Badiie A, Meshgini S. A hybrid deep transfer learning based approach for COVID-19 classification in chest X-ray images. *27th Natl. 5th Int. Iran. Conf. Biomed. Eng. ICBME 2020*, 2020; (November 2020), 234–241, doi: <https://doi.org/10.1109/ICBME51989.2020.9319426>.
120. Xue S, Abhayaratne C. Covid-19 Diagnostic Using 3d Deep Transfer Learning for Classification of Volumetric Computerised Tomography Chest Scans. 2021; 8573–8577, doi: <https://doi.org/10.1109/icassp39728.2021.9414947>.
121. Ahuja S, Panigrahi BK, Dey N, Rajinikanth V, Gandhi TK. Deep transfer learning-based automated detection of COVID-19 from lung CT scan slices. *Appl Intell*. 2021;51(1):571–85. <https://doi.org/10.1007/s10489-020-01826-w>.
122. Karatepe Ş, Kuluöztürk MF. Detection of Covid-19 from Chest CT Images Using Xception Architecture: A Deep Transfer Learning Based Approach. *SAUJS*. 2019;23(43328):663–75. <https://doi.org/10.16984/saufenbilder.459659>.
123. Zhang R, Guo Z, Sun Y, Lu Q, Xu Z, Yao Z, Duan M, Liu S, Ren Y, Huang L, Zhou F. COVID19XrayNet: a two-step transfer learning model for the COVID-19 detecting problem based on a limited number of chest X-Ray images. *Interdiscip Sci Comput Life Sci*. 2020;12(4):555–65. <https://doi.org/10.1007/s12539-020-00393-5>.
124. Horry MJ, Chakraborty S, Paul M, Ulhaq A, Pradhan B, Saha M, Shukla N. COVID-19 detection through transfer learning using multimodal imaging data. *IEEE Access*. 2020;8:149808–24. <https://doi.org/10.1109/ACCESS.2020.3016780>.

125. Bhattacharya S, Reddy Maddikunta PK, Pham QV, Gadekallu TR, Krishnan SR, Chowdhary CL, Alazab M, Jalil Piran M. Deep learning and medical image processing for coronavirus (COVID-19) pandemic: A survey. *Sustain. Cities Soc.*, 2020;(November), 102589 doi: <https://doi.org/10.1016/j.scs.2020.102589>.
126. Rehman A, Iqbal MA, Xing H, Ahmed I. COVID-19 detection empowered with machine learning and deep learning techniques: A systematic review,” *Appl. Sci.*, 2021;11(8), doi: <https://doi.org/10.3390/app11083414>.
127. Aishwarya T, Ravi Kumar V. Machine Learning and Deep Learning Approaches to Analyze and Detect COVID-19: A Review”. *SN Comput Sci.* 2021;2(3):1–9. <https://doi.org/10.1007/s42979-021-00605-9>.
128. Han ES, Daniel AG, Richard MB. Machine learning for COVID-19 detection and prognostication using chest radiographs and CT scans: a systematic review. *J Chem Inf Model.* 2019;53(9):1689–99.
129. Montazeri M, ZahediNasab R, Farahani A, Mohseni H, Ghasemian F. Machine learning models for image-based diagnosis and prognosis of COVID-19: Systematic review. *JMIR Med. Informatics.* 2021;9(4). doi: <https://doi.org/10.2196/25181>.
130. Bhargava A, Bansal A. Novel coronavirus (COVID-19) diagnosis using computer vision and artificial intelligence techniques: a review. *Multimed Tools Appl.* 2021;80(13):19931–46. <https://doi.org/10.1007/s11042-021-10714-5>.
131. El-rashidy N, Abdelrazik S, Abuhamed T, Amer E, El-sappagh S. Comprehensive survey of using machine learning in COVID-19 pandemic. 2021.
132. Mohammad-Rahimi H, Nadimi M, Ghalyanchi-Langeroudi A, Taheri M, Ghafouri-Fard S. Application of Machine Learning in Diagnosis of COVID-19 Through X-Ray and CT Images: A Scoping Review. *Frontiers in Cardiovascular Medicine.* 2021;8(March). doi: <https://doi.org/10.3389/fcvm.2021.638011>.
133. Shiri I, Sorouri M, Geramifar P, Nazari M, Abdollahi M, Salimi Y, Khosravi B, Askari D, Aghaghazvini L, Hajianfar G, Kasaeian A, Abdollahi H, Arabi H, Rahmim A, Radmard AR, Zaidi H. Machine learning-based prognostic modeling using clinical data and quantitative radiomic features from chest CT images in COVID-19 patients. *Comput Biol Med.* 2021;132(March):104304. <https://doi.org/10.1016/j.compbiomed.2021.104304>.
134. Chandrasekaran B, Fernandes S. A new approach for computer-aided detection of coronavirus (COVID-19) from CT and X-ray images using machine learning methods. *Diabetes Metab Syndr.* 2020;14(4):337–9.
135. Lasker A, Ghosh M, Sk MO, Chakraborty C, Roy K. Deep Features for COVID-19 Detection: performance evaluation on multiple classifiers. Kolkata: CIPR; 2022.
136. Elaziz MA, Hosny KM, Salah A, Darwish MM, Lu S, Sahlol AT. New machine learning method for imagebased diagnosis of COVID-19. *PLoS ONE.* 2022;15(6):e0235187. <https://doi.org/10.1371/journal.pone.0235187>.
137. Sedik A, Iliyasa AM, El-Rahiem BA, Abdel Samea ME, Abdel-Raheem A, Hammad M, Peng J, Abd El-Samie FE, Abd El-Latif AA. Deploying machine and deep learning models for efficient data-augmented detection of COVID-19 infections. *Viruses.* 2020;12(7):769. <https://doi.org/10.3390/v12070769>.
138. Shi F, Xia L, Shan F, Wu D, Wei Y, Yuan H, Jiang H, Gao Y, Sui H, Shen D. Large-scale screening of COVID-19 from community acquired pneumonia using infection size-aware classification. *arXiv*, 2020, doi: <https://doi.org/10.1088/1361-6560/abe838>.
139. Hussain L, Nguyen T, Li H, Abbasi AA, Lone KJ, Zhao Z, Zaib M, Chen A, Duong TQ. Machine-learning classification of texture features of portable chest X-ray accurately classifies COVID-19 lung infection. *Biomed Eng Online.* 2020;19(1):1–18. <https://doi.org/10.1186/s12938-020-00831-x>.
140. Mahdy LN, Ezzat KA, Elmousalami HH, Ella HA, Hassanien AE. “Automatic X-ray COVID-19 Lung Image Classification System based on Multi-Level Thresholding and Support Vector Machine. *medRxiv*, 2020;1–8. doi: <https://doi.org/10.1101/2020.03.30.20047787>.
141. Khan MA. An automated and fast system to identify COVID-19 from X-ray radiograph of the chest using image processing and machine learning. *Int J Imaging Syst Technol.* 2021;31(2):499–508. <https://doi.org/10.1002/ima.22564>.
142. Farhat H, Sakr GE, Kilany R. Deep learning applications in pulmonary medical imaging: recent updates and insights on COVID-19. *Mach Vis Appl.* 2020;31(6):1–42. <https://doi.org/10.1007/s00138-020-01101-5>.
143. Kumar R, Arora R, Bansal V, Sahayasheela VJ, Buckchash H, Imran J, Narayanan N, Pandian GN, Raman B. Accurate Prediction of COVID-19 using Chest X-Ray Images through Deep Feature Learning model with SMOTE and Machine Learning Classifiers. *medRxiv*, 2020;1–10, doi: <https://doi.org/10.1101/2020.04.13.20063461>.
144. Pereira RM, Bertolini D, Teixeira LO, Silla CN, Costa YMG. COVID-19 identification in chest X-ray images on flat and hierarchical classification scenarios. *Comput Methods Programs Biomed.* 2020;194:105532. <https://doi.org/10.1016/j.cmpb.2020.105532>.
145. Habib N, Rahman MM. Diagnosis of corona diseases from associated genes and X-ray images using machine learning algorithms and deep CNN. *Informatics Med Unlocked.* 2021;24:100621. <https://doi.org/10.1016/j.imu.2021.100621>.
146. Zargari Khuzani A, Heidari M, Shariati SA. COVID-Classifier: an automated machine learning model to assist in the diagnosis of COVID-19 infection in chest X-ray images. *Sci Rep.* 2021;11(1):9887. <https://doi.org/10.1038/s41598-021-88807-2>.
147. Yasar H, Ceylan M. A novel comparative study for detection of Covid-19 on CT lung images using texture analysis, machine learning, and deep learning methods. *Multimed Tools Appl.* 2020. <https://doi.org/10.1007/s11042-020-09894-3>.
148. Sharifrazi D, Alizadehsani R, Roshanzamir M, Joloudari JH, Shoeibi A, Jafari M, Hussain S, Sani ZA, Hasanzadeh F, Khozeimeh F, Khosravi A, Nahavandi S, Panahiazar M, Zare A, Islam SMS, Acharya UR. Fusion of convolution neural network, support vector machine and Sobel filter for accurate detection of COVID-19 patients using X-ray images. *Biomed Signal Process Control.* 2021;68:102622. <https://doi.org/10.1016/j.bspc.2021.102622>.
149. Tuncer T, Dogan S, Ozyurt F. An automated Residual Exemplar Local Binary Pattern and iterative ReliefF based corona detection method using lung X-ray image. *Chemom Intell Lab Syst.* 2020;203(May):104054. <https://doi.org/10.1016/j.chemolab.2020.104054>.
150. Wang X, Che Q, Ji X, Meng X, Zhang L, Jia R, Lyu H, Bai W, Tan L, Gao Y. Correlation between lung infection severity and clinical laboratory indicators in patients with COVID-19: a cross-sectional study based on machine learning. *BMC Infect Dis.* 2021;21(1):1–9. <https://doi.org/10.1186/s12879-021-05839-9>.
151. Liu C, Wang X, Liu C, Sun Q, Peng W. Differentiating novel coronavirus pneumonia from general pneumonia based on machine learning. *Biomed Eng Online.* 2020;19(1):1–14. <https://doi.org/10.1186/s12938-020-00809-9>.
152. Ragb HK, Dover IT, Ali R. Fused deep convolutional neural network for precision diagnosis of COVID-19 using Chest X-Ray Images. 100, 2020, [Online]. Available: <http://arxiv.org/abs/2009.08831>
153. Saha P, Sadi MS, Islam MM. EMCNet: Automated COVID-19 diagnosis from X-ray images using convolutional neural network and ensemble of machine learning classifiers. *Informatics Med*

- Unlocked. 2021;22:100505. <https://doi.org/10.1016/j.imu.2020.100505>.
154. Cohen JP, Morrison P, Dao L, Roth K, Duong TQ, Ghassemi M. COVID-19 Image Data Collection: Prospective predictions are the future. *arXiv*, 2020; 1–38.
 155. Rasheed J, Hameed AA, Djeddi C, Jamil A, Al-Turjman F. A machine learning-based framework for diagnosis of COVID-19 from chest X-ray images. *Interdiscip Sci Comput Life Sci*. 2021;13(1):103–17. <https://doi.org/10.1007/s12539-020-00403-6>.
 156. Keidar D, Yaron D, Goldstein E, Shachar Y, Blass A, Charbinsky L. COVID-19 classification of X-ray images using deep neural networks (2021).
 157. Mijwil MM. Implementation of Machine Learning Techniques for the Classification of Lung X-Ray Images Used to Detect COVID-19 in Humans. *مجلة COVID-19 في* *فاندتكلا ةينيدلا COVID-19 في* *ةشلا رهص في نرتل يلالا ممعتلا تايانفت قيبطت نادلا*. 2109–2099, (6)62;2021 doi: <https://doi.org/10.24996/ijcs.2021.62.6.35>.
 158. Khoong WH. COVID-19 Xray Dataset (Train & Test Sets). *kaggle*.
 159. Mooney P. Chest X-Ray Images (Pneumonia). *kaggle*, 2018.
 160. Imad M, Khan N, Ullah F, Hassan MA, Hussain A, Faiza. COVID-19 Classification based on Chest X-Ray Images Using Machine Learning Techniques. *J. Comput. Sci. Technol. Stud*. 2020;2(2), 01–11 [Online]. Available: <https://al-kindipublisher.com/index.php/jcsts/article/view/531>
 161. Samsir S, Sitorus JHP, Zulkifli Z, Ritonga FA, Nasution RW. Comparison of machine learning algorithms for chest X-ray image COVID-19 classification. *J Phys Conf Ser*. 2021;1933(1):012040. <https://doi.org/10.1088/1742-6596/1933/1/012040>.
 162. Mortani Barbosa EJ, Georgescu B, Chaganti S, Aleman GB, Cabrero JB, Chabin G, Flohr T, Grenier P, Grbic S, Gupta N, Mellot F, Nicolaou S, Re T, Sanelli P, Sauter AW, Yoo Y, Ziebandt V, Comanicu D. Machine learning automatically detects COVID-19 using chest CTs in a large multicenter cohort. *Eur. Radiol.*, 2021, doi: <https://doi.org/10.1007/s00330-021-07937-3>.
 163. Feng Z, Shen H, Gao K, Su J, Yao S, Liu Q, Yan Z, Duan J, Yi D, Zhao H, Li H, Yu Q, Zhou W, Mao X, Ouyang X, Mei J, Zeng Q, Williams L, Ma X, Rong P, Hu D, Wang W. Machine learning based on clinical characteristics and chest CT quantitative measurements for prediction of adverse clinical outcomes in hospitalized patients with COVID-19. *Eur Radiol*. 2021. <https://doi.org/10.1007/s00330-021-07957-z>.
 164. Hosseinzadeh S, Hosseinzadeh P, Wesolowski MJ. Automatic detection of coronavirus disease (COVID-19) in X-ray and CT images: A machine learning based approach. (January), (2020).
 165. Muhammad Y, Alshehri MD, Alenazy WM, Vinh Hoang T, Alturki R. Identification of Pneumonia Disease Applying an Intelligent Computational Framework Based on Deep Learning and Machine Learning Techniques. *Mob. Inf. Syst.*, 2021, 2021, doi: <https://doi.org/10.1155/2021/9989237>.
 166. Simonyan K, Zisserman A. Very deep convolutional networks for large-scale image recognition. 3rd Int. Conf. Learn. Represent. ICLR 2015 - Conf. Track Proc. 2015;1–14.
 167. Howard AG, Zhu M, Chen B, Kalenichenko D, Wang W, Weyand T, Andreetto M, Adam H. MobileNets: Efficient Convolutional Neural Networks for Mobile Vision Applications. 2017, [Online]. Available: <http://arxiv.org/abs/1704.04861>
 168. He K, Zhang X, Ren S, Sun J. Deep residual learning for image recognition. *Proc. IEEE Comput. Soc. Conf. Comput. Vis. Pattern Recognit.*, 2016–December, 2016; 770–778 doi: <https://doi.org/10.1109/CVPR.2016.90>.
 169. Szegedy C, Vanhoucke V, Ioffe S, Shlens J, Wojna Z. Rethinking the Inception Architecture for Computer Vision. *Proc. IEEE Comput. Soc. Conf. Comput. Vis. Pattern Recognit.*, 2016;2016–December, 2818–2826 doi: <https://doi.org/10.1109/CVPR.2016.308>.
 170. Mukherjee H, Ghosh S, Dhar A, Obaidullah SM, Santosh KC, Roy K. Deep neural network to detect COVID-19: one architecture for both CT Scans and Chest X-rays. *Appl Intell*. 2020. <https://doi.org/10.1007/s10489-020-01943-6>.
 171. Lasker A, Ghosh M, Sk MO, Chakraborty C, Roy K. “Deep learning framework for Covid-19 identification from chest X-ray”, in *Advancement of Deep Learning and its Applications in Object Detection and Recognition*. Denmark: Rivers Publication; 2021.
 172. Hwang EJ, Kim KB, Kim JY, Lim JK, Nam JG, Choi H, Kim H, Yoon SH, Goo JM, Park CM. COVID-19 pneumonia on chest X-rays: Performance of a deep learning-based computer-aided detection system. *PLoS One* 2021;16(6 June), 1–16. doi: <https://doi.org/10.1371/journal.pone.0252440>.
 173. Chen J, Wu L, Zhang J, Zhang L, Gong D, Zhao Y, Chen Q, Huang S, Yang M, Yang X, Hu S, Wang Y, Hu X, Zheng B, Zhang K, Wu H, Dong Z, Xu Y, Zhu Y, Chen X, Zhang M, Yu L, Cheng F, Yu H. Deep learning-based model for detecting 2019 novel coronavirus pneumonia on high-resolution computed tomography. *Sci Rep*. 2020;10(1):1–11. <https://doi.org/10.1038/s41598-020-76282-0>.
 174. Pan F, Li L, Liu B, Ye T, Li L, Liu D, Ding Z, Chen G, Liang B, Yang L, Zheng C. A novel deep learning-based quantification of serial chest computed tomography in Coronavirus Disease 2019 (COVID-19). *Sci Rep*. 2021;11(1):1–11. <https://doi.org/10.1038/s41598-020-80261-w>.
 175. Javor D, Kaplan H, Kaplan A, Puchner SB, Krestan C, Baltzer P. Deep learning analysis provides accurate COVID-19 diagnosis on chest computed tomography. *Eur. J. Radiol.*, 2020;133(January) doi: <https://doi.org/10.1016/j.ejrad.2020.109402>.
 176. Dutta S, Manideep BCS, Rai S, Vijayarajan V. A comparative study of deep learning models for medical image classification. *IOP Conf. Ser. Mater. Sci. Eng.*, 2017;263(4). doi: <https://doi.org/10.1088/1757-899X/263/4/042097>.
 177. Alsaade FW, Aldhyani THH, Al-Adhaileh MH. Developing a Recognition System for Classifying COVID-19 using a convolutional neural network algorithm. *Comput Mater Contin*. 2021;68(1):805–19. <https://doi.org/10.32604/cmc.2021.016264>.
 178. Qi X, Brown LG, Foran DJ, Noshier J, Hachihaliloglu I. Chest X-ray image phase features for improved diagnosis of COVID-19 using convolutional neural network. *Int J Comput Assist Radiol Surg*. 2021;16(2):197–206. <https://doi.org/10.1007/s11548-020-02305-w>.
 179. El-Kenawy ESM, Mirjalili S, Ibrahim A, Alrahmawy M, El-Said M, Zaki RM, Eid MM. Advanced meta-heuristics, convolutional neural networks, and feature selectors for efficient COVID-19 X-ray chest image classification. *IEEE Access*. 2021;9:36019–37. <https://doi.org/10.1109/ACCESS.2021.3061058>.
 180. Jain G, Mittal D, Thakur D, Mittal MK. A deep learning approach to detect Covid-19 coronavirus with X-Ray images. *Biocybern Biomed Eng*. 2020;40(4):1391–405. <https://doi.org/10.1016/j.bbe.2020.08.008>.
 181. Srivastava A, Chanda S, Jha D, Riegler MA, Halvorsen P, Johansen D, Pal U. PAANet: Progressive Alternating Attention for Automatic Medical Image Segmentation. 2021, [Online]. Available: <http://arxiv.org/abs/2111.10618>
 182. Srivastava A, Jha D, Chanda S, Pal U, Johansen HD, Johansen D, Riegler MA, Ali S, Halvorsen P. MSRF-Net: A Multi-Scale Residual Fusion Network for Biomedical Image Segmentation. pp. 1–10, 2021, doi: <https://doi.org/10.1109/JBHI.2021.3138024>.

183. Abdar M, Salari S, Qahremani S, Lam HK. UncertaintyFuse-Net: Robust Uncertainty-aware Hierarchical Feature Fusion with Ensemble Monte Carlo Dropout for COVID-19 Detection. *arXiv Prepr. arXiv ...*, pp. 1–16, 2021, [Online]. Available: <https://arxiv.org/abs/2105.08590>
184. Meyer P, Müller D, Soto-Rey I, Kramer F. COVID-19 Image Segmentation Based on Deep Learning and Ensemble Learning. *Stud Health Technol Inform.* 2021;281:518–9. <https://doi.org/10.3233/SHTI210223>.
185. Gifani P, Shalhaf A, Vafaezadeh M. Automated detection of COVID-19 using ensemble of transfer learning with deep convolutional neural network based on CT scans. *Int J Comput Assist Radiol Surg.* 2021;16(1):115–23. <https://doi.org/10.1007/s11548-020-02286-w>.
186. Li X, Tan W, Liu P, Zhou Q, Yang J. Classification of COVID-19 Chest CT Images Based on Ensemble Deep Learning. *J. Healthc. Eng.* 2021; 2021, doi: <https://doi.org/10.1155/2021/5528441>.
187. Upadhyay K, Agrawal M, Deepak D. Ensemble learning-based COVID-19 detection by feature boosting in chest X-ray images. *IET Image Process.* 2020;14(16):1–8. <https://doi.org/10.1049/iet-ipr.2020.1127>.
188. Singh M, Bansal S, Ahuja S, Dubey RK, Panigrahi BK, Dey N. Transfer learning-based ensemble support vector machine model for automated COVID-19 detection using lung computerized tomography scan data. *Med Biol Eng Comput.* 2021;59(4):825–39. <https://doi.org/10.1007/s11517-020-02299-2>.
189. Annarapu CSR. Deep learning-based improved snapshot ensemble technique for COVID-19 chest X-ray classification. *Appl Intell.* 2021;51(5):3104–20. <https://doi.org/10.1007/s10489-021-02199-4>.
190. Mahmud T, Rahman MA, Fattah SA. CovXNet: A multi-dilation convolutional neural network for automatic COVID-19 and other pneumonia detection from chest X-ray images with transferable multi-receptive feature optimization. *Comput Biol Med.* 2020;122(May):103869. <https://doi.org/10.1016/j.combiomed.2020.103869>.
191. Madaan V, Roy A, Gupta C, Agrawal P, Sharma A, Bologna C, Prodan R. XCOVNet: Chest X-ray Image Classification for COVID-19 Early Detection Using Convolutional Neural Networks. *New Gener. Comput.*, 2021;0123456789, doi: <https://doi.org/10.1007/s00354-021-00121-7>.
192. Chowdhury NK, Rahman MM, Kabir MA. PDCOVNet: A parallel-dilated convolutional neural network architecture for detecting COVID-19 from chest X-ray images. *arXiv.* 2020;8(1),1–14, doi: <https://doi.org/10.1007/s13755-020-00119-3>.
193. Ucar F, Korkmaz D. COVIDiagnosis-Net: Deep Bayes-SqueezeNet based diagnosis of the coronavirus disease 2019 (COVID-19) from X-ray images. *Med Hypotheses.* 2020;140(April):109761. <https://doi.org/10.1016/j.mehy.2020.109761>.
194. Ozturk T, Talo M, Yildirim EA, Baloglu UB, Yildirim O, Rajendra Acharya U. Automated detection of COVID-19 cases using deep neural networks with X-ray images. *Comput Biol Med.* 2020;121(April):103792. <https://doi.org/10.1016/j.combiomed.2020.103792>.
195. Ambati A, Dubey SR. AC-CovidNet: Attention Guided Contrastive CNN for Recognition of Covid-19 in Chest X-Ray Images. 2021, [Online]. Available: <http://arxiv.org/abs/2105.10239>
196. Hanafi, A, Pranolo, Mao Y. Cae-covidx: Automatic covid-19 disease detection based on x-ray images using enhanced deep convolutional and autoencoder. *Int. J. Adv. Intell. Informatics.* 2021;7(1), 49–62. doi: <https://doi.org/10.26555/ijain.v7i1.577>.
197. Hussain E, Hasan M, Rahman MA, Lee I, Tamanna T, Parvez MZ. CoroDet: A deep learning based classification for COVID-19 detection using chest X-ray images. *Chaos, Solitons Fractals.* 2021;142:110495. <https://doi.org/10.1016/j.chaos.2020.110495>.
198. Elbishlawi S, Abdelpakey MH, Shehata MS, Mohamed MM. Corona-net: Diagnosing covid-19 from x-ray images using re-initialization and classification networks. *J. Imaging.* 2021; 7(5). doi: <https://doi.org/10.3390/jimaging7050081>.
199. Haghanifar A, Majdabadi MM, Choi Y, Deivalakshmi S, Ko S. COVID-CXNet: Detecting COVID-19 in Frontal Chest X-ray Images using Deep Learning. 2020, [Online]. Available: <http://arxiv.org/abs/2006.13807>
200. Khan MSI, Rahman A, Karim MR, Bithi NI, Band S, Dehzangi A, Alinejad-Rokny H. CovidMulti-Net A Parallel-Dilated Multi Scale Feature Fusion Architecture for the Identification of COVID-19 Cases from Chest X-ray Images. *medRxiv.* 2021;1–16. [Online]. Available: <https://medrxiv.org/cgi/content/short/2021.05.19.21257430>
201. Wang L, Lin ZQ, Wong A. COVID-Net: a tailored deep convolutional neural network design for detection of COVID-19 cases from chest X-ray images. *Sci Rep.* 2020;10(1):1–12. <https://doi.org/10.1038/s41598-020-76550-z>.
202. Singh RK, Pandey R, Babu RN. COVIDScreen: explainable deep learning framework for differential diagnosis of COVID-19 using chest X-rays. *Neural Comput. Appl.* 2021;6, doi: <https://doi.org/10.1007/s00521-020-05636-6>.
203. Das D, Samal C, Ukey D, Chowdhary G, Mohanty SP. Cov-iLearn: A Machine Learning Integrated Smart X-Ray Device in Healthcare Cyber-Physical System for Automatic Initial Screening of COVID-19. pp. 2021;1–16. [Online]. Available: <http://arxiv.org/abs/2106.05861>
204. Umer M, Ashraf I, Ullah S, Mehmood A, Choi GS. COVINet: a convolutional neural network approach for predicting COVID-19 from chest X-ray images. *J. Ambient Intell. Humaniz. Comput.*, 2021;2020. doi: <https://doi.org/10.1007/s12652-021-02917-3>.
205. Hertel R, Benlamri R. COV-SNET: A deep learning model for X-ray-based COVID-19 classification. *Informatics Med Unlocked.* 2021;24(April):100620. <https://doi.org/10.1016/j.imu.2021.100620>.
206. Ouchicha C, Ammor O, Meknassi M. CVDNet: A novel deep learning architecture for detection of coronavirus (Covid-19) from chest x-ray images.,” no. January, 2020.
207. Minaee S, Kafieh R, Sonka M, Yazdani S, Jamalipour Soufi G. Deep-COVID: Predicting COVID-19 from chest X-ray images using deep transfer learning. *Med. Image Anal.*, 2020;65. doi: <https://doi.org/10.1016/j.media.2020.101794>.
208. Quan H, Xu X, Zheng T, Li Z, Zhao M, Cui X. DenseCapsNet: Detection of COVID-19 from X-ray images using a capsule neural network. *Comput. Biol. Med.*, 2021;133(January), doi: <https://doi.org/10.1016/j.combiomed.2021.104399>.
209. Cheng B, Xue R, Yang H, Zhu L, Xiang W. DPN-SENet: A self-attention mechanism neural network for detection and diagnosis of COVID-19 from chest x-ray images. 2021, [Online]. Available: <http://arxiv.org/abs/2105.09683>
210. Chowdhury NK, Kabir MA, Rahman MM, Rezoana N (2021) ECOVNet: a highly effective ensemble based deep learning model for detecting COVID-19. *PeerJ Comput Sci.* 2020;7:e551. <https://doi.org/10.7717/peerj-cs.551>.
211. Tang S, Wang C, Nie J, Kumar N, Zhang Y, Xiong Z, Barnawi A. EDL-COVID: ensemble deep learning for COVID-19 cases detection from chest X-Ray images. *IEEE Trans Ind Informatics.* 2021;17(9):6539–49. <https://doi.org/10.1109/TII.2021.3057683>.
212. Agrawal T, Choudhary P. FocusCovid: automated COVID-19 detection using deep learning with chest X-ray images. *Evol. Syst.* 2021;(Grech 2020). doi: <https://doi.org/10.1007/s12530-021-09385-2>.

213. Monshi MMA, Poon J, Chung V, Monshi FM. CovidXrayNet: Optimizing data augmentation and CNN hyperparameters for improved COVID-19 detection from CXR. *Comput. Biol. Med.* 2021;133(January). doi: <https://doi.org/10.1016/j.combiomed.2021.104375>.
214. Toraman S, Alakus TB, Turkoglu I. Convolutional capsnet: A novel artificial neural network approach to detect COVID-19 disease from X-ray images using capsule networks. *Chaos, Solitons and Fractals*, 140, (2020), doi: <https://doi.org/10.1016/j.chaos.2020.110122>.
215. Hemalatha Munusamy SA, Karthikeyan JM, Shriram G, Thanga Revathi S. FractalCovNet architecture for COVID-19 Chest X-ray image Classification and CT-scan image Segmentation. no. January, 2020.
216. Ghaderzadeh M, Asadi F, Jafari R, Bashash D, Abolghasemi H, Aria M. Deep convolutional neural network-based computer-aided detection system for COVID-19 using multiple lung scans: Design and implementation study. *J Med Internet Res.* 2021;23(4):1–12. <https://doi.org/10.2196/27468>.
217. Ibrahim DM, Elshennawy NM, Sarhan AM. Deep-chest: Multi-classification deep learning model for diagnosing COVID-19, pneumonia, and lung cancer chest diseases. *Comput. Biol. Med.* 2021;132(January). doi: <https://doi.org/10.1016/j.combiomed.2021.104348>.
218. Shah V, Keniya R, Shridharani A, Punjabi M, Shah J, Mehendale N. Diagnosis of COVID-19 using CT scan images and deep learning techniques. *Emerg Radiol.* 2021;28(3):497–505. <https://doi.org/10.1007/s10140-020-01886-y>.
219. Bhansali R, Kumar R, Writer D. CoronaNet: a novel deep learning model for COVID-19 detection in CT scans. *J Student Res.* 2020;9(2):1–9. <https://doi.org/10.47611/jsrhs.v9i2.1246>.
220. Wu X, Chen C, Zhong M, Wang J, Shi J. COVID-AL: The diagnosis of COVID-19 with deep active learning. *Med Image Anal.* 2020;68(December):2021. <https://doi.org/10.1016/j.media.2020.101913>.
221. Javaheri T, Homayounfar M, Amoozgar Z, Reiazi R, Homayounieh F, Abbas E, Laali A, Radmard AR, Gharib MH, Mousavi SAJ, Ghaemi O, Babaei R, Mobin HK, Hosseinzadeh M, Jahانبan-Esfahlan R, Seidi K, Kalra MK, Zhang G, Chitkushvev LT, Haibe-Kains B, Malekzadeh R, Rawassizadeh R. CovidCTNet: an open-source deep learning approach to diagnose covid-19 using small cohort of CT images. *npj Digit. Med.*, 2021;4(1), doi: <https://doi.org/10.1038/s41746-021-00399-3>.
222. Afshar P, Heidarian S, Naderkhani F, Oikonomou A, Plataniotis KN, Mohammadi A. COVID-CAPS: A capsule network-based framework for identification of COVID-19 cases from X-ray images. *Pattern Recognit Lett.* 2020;138:638–43. <https://doi.org/10.1016/j.patrec.2020.09.010>.
223. Xu Y, Lam HK, Jia G. MANet: A two-stage deep learning method for classification of COVID-19 from Chest X-ray images. *Neurocomputing.* 2021;443(January):96–105. <https://doi.org/10.1016/j.neucom.2021.03.034>.
224. Yamac M, Ahishali M, Degerli A, Kiranyaz S, Chowdhury MEH, Gabbouj M. Convolutional Sparse Support Estimator-Based COVID-19 Recognition from X-Ray Images. *IEEE Trans Neural Networks Learn Syst.* 2021;32(5):1810–20. <https://doi.org/10.1109/TNNLS.2021.3070467>.
225. Khattak MI, Al-Hasan M, Jan A, Saleem N, Verdú E, Khursheed N. Automated Detection of COVID-19 using Chest X-Ray Images and CT Scans through Multilayer- Spatial Convolutional Neural Networks. *Int. J. Interact. Multimed. Artif. Intell.*, vol. In Press, no. In Press, p. 1, 2021, doi: <https://doi.org/10.9781/ijimai.2021.04.002>.
226. Carnier M, Albertti R, Gavidia L, Severeyn E, La Cruz A. *ToraxIA: Virtual Assistant for Radiologists Based on Deep Learning from Chest X-Ray*, vol. 1326 AISC. Springer International Publishing, (2021). doi: https://doi.org/10.1007/978-3-030-68080-0_4.
227. Sangidong JC, Purnomo HD, Santoso FY. Application of deep learning for early detection of COVID-19 Using CT-Scan Images. 3rd 2021 East Indones Conf Comput Inf Technol EIC-onCIT. 2021;2021:61–5. <https://doi.org/10.1109/EIConCIT50028.2021.9431887>.
228. Ahmed S, Yap MH, Member S, Tan M, Hasan K, Member S. ReCoNet : Multi-level Preprocessing of Chest X-rays for COVID-19 Detection Using Convolutional Neural Networks. 2020; pp. 1–9.
229. Rohila VS, Gupta N, Kaul A, Sharma DK. Deep learning assisted COVID-19 detection using full CT-scans. *Internet of Things.* 2021;14:100377. <https://doi.org/10.1016/j.iot.2021.100377>.
230. Awedat K, Essa A. COVID-CLNet: COVID-19 Detection with Compressive Deep Learning Approaches. 2020, [Online]. Available: <http://arxiv.org/abs/2012.02234>
231. Ko H, Chung H, Kang WS, Kim KW, Shin Y, Kang SJ, Lee JH, Kim YJ, Kim NY, Jung H, Lee J. COVID-19 pneumonia diagnosis using a simple 2d deep learning framework with a single chest CT image: Model development and validation. *J Med Internet Res.* 2020;22(6):1–13. <https://doi.org/10.2196/19569>.
232. Bougourzi F, Contino R, Distante C, Taleb-ahmed A, Lille C, Iemn UMR, Valenciennes F. CNR-IEMN : A DEEP LEARNING BASED APPROACH TO RECOGNISE COVID-19 FROM CT-SCAN CNR Institute of Applied Sciences and Intelligent Systems , 73100 Lecce , Italy Correspondence : cosimo.distante@cnr.it ; Abdelmalik.Taleb-Ahmed@uphf.fr,” pp. 8568–8572, 2021.
233. Aboutalebi H, Abbasi S, Shafiee MJ, Wong A. COVID-Net CT-S: 3D Convolutional Neural Network Architectures for COVID-19 Severity Assessment using Chest CT Images. no. 2020, pp. 1–6, 2021, [Online]. Available: <http://arxiv.org/abs/2105.01284>
234. Oyelade ON, Ezugwu AE, Chiroma H. CovFrameNet: An enhanced deep learning framework for COVID-19 detection. *IEEE Access.* 2021. <https://doi.org/10.1109/ACCESS.2021.3083516>.
235. Luján-García JE, Villuendas-Rey Y, López-Yáñez I, Camacho-Nieto O, Yáñez-Márquez C. Nanochest-net: A simple convolutional network for radiological studies classification. *Diagnostics.* 2021;11(5). doi: <https://doi.org/10.3390/diagnostics11050775>.
236. Saiz F, Barandiaran I. COVID-19 Detection in Chest X-ray images using a deep learning approach. *Int J Interact Multimed Artif Intell.* 2020;6(2):4. <https://doi.org/10.9781/ijimai.2020.04.003>.
237. Hammoudi K, Benhabiles H, Melkemi M, Dornaika F, Arganda-Carreras I, Collard D, Scherpereel A. Deep Learning on Chest X-ray Images to Detect and Evaluate Pneumonia Cases at the Era of COVID-19. *J. Med. Syst.*, 2021;45(7). doi: <https://doi.org/10.1007/s10916-021-01745-4>.
238. Brunese L, Mercaldo F, Reginelli A, Santone A. Explainable Deep Learning for Pulmonary Disease and Coronavirus COVID-19 Detection from X-rays. *Comput. Methods Programs Biomed.*, 2020;196. doi: <https://doi.org/10.1016/j.cmpb.2020.105608>.
239. Zebin T, Rezvy S. COVID-19 detection and disease progression visualization: deep learning on chest X-rays for classification and coarse localization. *Appl Intell.* 2021;51(2):1010–21. <https://doi.org/10.1007/s10489-020-01867-1>.
240. Ismael AM, Şengür A. Deep learning approaches for COVID-19 detection based on chest X-ray images. *Expert Syst. Appl.*, 2021;164(January). doi: <https://doi.org/10.1016/j.eswa.2020.114054>.
241. Yener FM, Oktay AB. Diagnosis of COVID-19 with a Deep Learning Approach on Chest CT Slices. *TIPTEKNO 2020 - Tip Teknol. Kongresi - 2020 Med. Technol. Congr. TIPTEKNO 2020,*

- 2020; pp. 16–19, doi: <https://doi.org/10.1109/TIPTEKNO50054.2020.9299266>.
242. Sikkandar MY. Deep learning model for image-based diagnosis of covid-19 classification using convolution neural network. *Ann Rom Soc Cell Biol.* 2021;25(1):2160–74.
 243. Pham TD. Classification of COVID-19 chest X-rays with deep learning: new models or fine tuning? *Heal. Inf. Sci. Syst.*, 2021;9(1). doi: <https://doi.org/10.1007/s13755-020-00135-3>.
 244. Shelke A, Inamdar M, Shah V, Tiwari A, Hussain A, Chafekar T, Mehendale N. Chest X-ray classification using Deep learning for automated COVID-19 screening. no. December 2019, 2020, doi: <https://doi.org/10.1101/2020.06.21.20136598>.
 245. Che Azemin MZ, Hassan R, Mohd Tamrin MI, Md Ali MA. COVID-19 Deep Learning Prediction Model Using Publicly Available Radiologist-Adjudicated Chest X-Ray Images as Training Data: Preliminary Findings. *Int. J. Biomed. Imaging*, vol. 2020, 2020, doi: <https://doi.org/10.1155/2020/8828855>.
 246. Serte S, Demirel H. Deep learning for diagnosis of COVID-19 using 3D CT scans. *Comput. Biol. Med.*, 2021;132(January), doi: <https://doi.org/10.1016/j.cmpbiomed.2021.104306>.
 247. Sadoon TAU-M, Ali MH. Coronavirus 2019 (COVID-19) detection based on deep learning. *Al-Nahrain J Eng Sci.* 2020;23(4):408–15. <https://doi.org/10.29194/njes.23040408>.
 248. Mohammadpoor M, Karizaki MS, Karizaki MS. A deep learning algorithm to detect coronavirus (COVID-19) disease using CT images. *PeerJ Comput Sci.* 2021;7:1–12. <https://doi.org/10.7717/PEERJ-CS.345>.
 249. Ahmed F, Bukhari SAC, Keshtkar F. A Deep Learning Approach for COVID-19 8 Viral Pneumonia Screening with X-ray Images. *Digit Gov Res Pract.* 2021;2(2):1–12. <https://doi.org/10.1145/3431804>.
 250. Elgendi M, Nasir MU, Tang Q, Smith D, Grenier JP, Batte C, Spieler B, Leslie WD, Menon C, Fletcher RR, Howard N, Ward R, Parker W, Nicolaou S. The effectiveness of image augmentation in deep learning networks for detecting COVID-19: a geometric transformation perspective. *Front Med.* 2021;8(March):1–12. <https://doi.org/10.3389/fmed.2021.629134>.
 251. Xiong Z, Wang R, Bai HX, Halsey K, Mei J, Li YH, Atalay MK, Jiang XL, Fu FX, Thi LT, Huang RY, Liao WH, Pan I, Choi JW, Zeng QH, Hsieh B, CuiWang D, Sebro R, Hu PF, Chang K, Shi LB, Qi ZY. Artificial Intelligence augmentation of radiologist performance in distinguishing COVID-19 from Pneumonia of other origin at Chest CT. *Radiology.* 2020;296(3):E156–65. <https://doi.org/10.1148/radiol.2020201491>.
 252. Al Al Rahhal MM, Bazi Y, Jomaa RM, Zuair M, Al Ajlan N. Deep Learning Approach for COVID-19 Detection in Computed Tomography Images. *Comput Mater Contin.* 2021;67(2):2093–110. <https://doi.org/10.32604/cmc.2021.014956>.
 253. Sekeroglu B, Ozsahin I. Detection of COVID-19 from Chest X-Ray Images Using Convolutional Neural Networks. *SLAS Technol.* 2020;25(6):553–65. <https://doi.org/10.1177/2472630320958376>.
 254. Turkoglu M. COVID-19 Detection System Using Chest CT Images and Multiple Kernels-Extreme Learning Machine Based on Deep Neural Network. *Irbm.* 2021;1:1–8. <https://doi.org/10.1016/j.irbm.2021.01.004>.
 255. Asif S, Wenhui Y, Jin H, Jinhai S. Classification of COVID-19 from Chest X-ray images using deep convolutional neural network. 2020 IEEE 6th Int Conf Comput Commun ICCCC. 2020;2020:426–33. <https://doi.org/10.1109/ICCC51575.2020.9344870>.
 256. Das D, Santosh KC, Pal U. Truncated inception net: COVID-19 outbreak screening using chest X-rays. *Phys Eng Sci Med.* 2020;43(3):915–25. <https://doi.org/10.1007/s13246-020-00888-x>.
 257. Wang Z, Xiao Y, Li Y, Zhang J, Lu F, Hou M, Liu X. Automatically discriminating and localizing COVID-19 from community-acquired pneumonia on chest X-rays. *Pattern Recognit.*, 2021;110. doi: <https://doi.org/10.1016/j.patcog.2020.107613>.
 258. Shiri I, Akhavanallaf A, Sanaat A, Salimi Y, Askari D, Mansouri Z, Shayesteh SP, Hasanian M, Rezaei-Kalantari K, Salahshour A, Sandoughdaran S, Abdollahi H, Arabi H, Zaidi H. Ultra-low-dose chest CT imaging of COVID-19 patients using a deep residual neural network. *Eur Radiol.* 2021;31(3):1420–31. <https://doi.org/10.1007/s00330-020-07225-6>.
 259. Wang J, Bao Y, Wen Y, Lu H, Luo H, Xiang Y, Li X, Liu C, Qian D. Prior-attention residual learning for more discriminative COVID-19 screening in CT Images. *IEEE Trans Med Imaging.* 2020;39(8):2572–83. <https://doi.org/10.1109/TMI.2020.2994908>.
 260. Qiu D, Cheng Y, Wang X, Zhang X. Multi-window back-projection residual networks for reconstructing COVID-19 CT super-resolution images. *Comput. Methods Programs Biomed.*, 2021;200(January). doi: <https://doi.org/10.1016/j.cmpb.2021.105934>.
 261. Karthik R, Menaka R, Hariharan M. Learning distinctive filters for COVID-19 detection from chest X-ray using shuffled residual CNN. *Appl. Soft Comput. J.*, 2020;(xxxx), 106744. doi: <https://doi.org/10.1016/j.asoc.2020.106744>.
 262. Ibrahim RW, Al-shamasneh AR. Classification of Covid-19 Coronavirus, Pneumonia and Healthy Lungs in CT Scans Using Q-Deformed Entropy and Deep Learning Features*.
 263. Mostafiz R, Uddin MS, Alam NA, Mahfuz Reza M, Rahman MM. Covid-19 detection in chest X-ray through random forest classifier using a hybridization of deep CNN and DWT optimized features. *J. King Saud Univ. - Comput. Inf. Sci.*, 2021;(xxxx), doi: <https://doi.org/10.1016/j.jksuci.2020.12.010>.
 264. Ahsan MM, Alam TE, Trafalis T, Huebner P. Deep MLP-CNN Model Using Mixed-Data to Distinguish between COVID-19 and Non-COVID-19 Patients. *Symmetry (Basel)*, 2020;12(9). doi: <https://doi.org/10.3390/sym12091526>.
 265. Hamadneh NN, Khan WA, Ashraf W, Atawneh SH, Khan I, Hamadneh BN. Artificial neural networks for prediction of covid-19 in Saudi Arabia. *Comput Mater Contin.* 2021;66(3):2787–96. <https://doi.org/10.32604/cmc.2021.013228>.
 266. Elzeki OM, Elfattah MA, Salem H, Hassanien AE, Shams M. A novel perceptual two layer image fusion using deep learning for imbalanced COVID-19 dataset. *PeerJ Comput Sci.* 2021;7:1–35. <https://doi.org/10.7717/PEERJ-CS.364>.
 267. Wang SH, Govindaraj VV, Górriz JM, Zhang X, Zhang YD. Covid-19 classification by FGCNet with deep feature fusion from graph convolutional network and convolutional neural network. *Inf Fusion.* 2021;67:208–29. <https://doi.org/10.1016/j.inffus.2020.10.004>.
 268. Zhang YD, Satapathy SC, Liu S, Li GR. A five-layer deep convolutional neural network with stochastic pooling for chest CT-based COVID-19 diagnosis. *Mach. Vis. Appl.*, 2021;32(1). doi: <https://doi.org/10.1007/s00138-020-01128-8>.
 269. Hajjij M, Zamzmi G, Batayneh F. TDA-Net: fusion of persistent homology and deep learning features for COVID-19 Detection in chest X-Ray images. pp. 1–12, 2021, [Online]. Available: <http://arxiv.org/abs/2101.08398>
 270. Wu X, Hui H, Niu M, Li L, Wang L, He B, Yang X, Li L, Li H, Tian J, Zha Y. Deep learning-based multi-view fusion model for screening 2019 novel coronavirus pneumonia: a multicentre study. *Eur J Radiol.* 2020;128(April):1–9. <https://doi.org/10.1016/j.ejrad.2020.109041>.
 271. Xu M, Ouyang L, Han L, Sun K, Yu T, Li Q, Tian H, Safarnejad L, Zhang H, Gao Y, Bao FS, Chen Y, Robinson P, Ge Y, Zhu B, Liu J, Chen S. Accurately differentiating between patients with COVID-19, patients with other viral infections, and healthy

- individuals: Multimodal late fusion learning approach. *J Med Internet Res.* 2021;23(1):1–17. <https://doi.org/10.2196/25535>.
272. Abbasian A, Rajabzadeh A, Acharya UR. Application of deep learning technique to manage COVID-19 in routine clinical practice using CT images: Results of 10 convolutional neural networks. (January), 2020.
 273. Mishra AK, Das SK, Roy P, Bandyopadhyay S. Identifying COVID19 from Chest CT Images: A Deep Convolutional Neural Networks Based Approach. *J. Healthc. Eng.*, 2020;2020. doi: <https://doi.org/10.1155/2020/8843664>.
 274. Rehman A, Saba T, Tariq U, Ayesha N. Deep learning-based COVID-19 detection using CT and X-Ray images: current analytics and comparisons. 2021;63–68.
 275. Nayak SR, Nayak DR, Sinha U, Arora V, Pachori RB. Application of deep learning techniques for detection of COVID-19 cases using chest X-ray images: A comprehensive study. *Biomed Signal Process Control.* 2021;64:102365. <https://doi.org/10.1016/j.bspc.2020.102365>.
 276. Mohsin Ahmed H, Wael Abdullah B. Overview of deep learning models for identification Covid-19. *Mater. Today Proc.*, 2021;(xxxx) doi: <https://doi.org/10.1016/j.matpr.2021.05.553>.
 277. Rahaman MM, Li C, Yao Y, Kulwa F, Rahman MA, Wang Q, Qi S, Kong F, Zhu X, Zhao X. Identification of COVID-19 samples from chest X-Ray images using deep learning: A comparison of transfer learning approaches. *J Xray Sci Technol.* 2020;28(5):821–39. <https://doi.org/10.3233/XST-200715>.
 278. Paluru N, Dayal A, Jenssen HB, Sakinis T, Cenkeramaddi LR, Prakash J, Yalavarthy PK. Anam-Net: Anamorphic Depth Embedding-Based Lightweight CNN for Segmentation of Anomalies in COVID-19 Chest CT Images. *IEEE Trans Neural Networks Learn Syst.* 2021;32(3):932–46. <https://doi.org/10.1109/TNNLS.2021.3054746>.
 279. Priya C, Sithi Shameem Fathima SMH, Kirubanandasarathy N, Valanarasid A, Safana Begam MH, Aiswarya N. Automatic optimized CNN based COVID-19 lung infection segmentation from CT image. *Mater Today Proc.* 2021;14(4):337–9. <https://doi.org/10.1016/j.matpr.2021.01.820>.
 280. Gerard SE, Herrmann J, Xin Y, Martin KT, Rezoagli E, Ippolito D, Bellani G, Cereda M, Guo J, Hoffman EA, Kaczka DW, Reinhardt JM. CT image segmentation for inflamed and fibrotic lungs using a multi-resolution convolutional neural network. *Sci Rep.* 2021;11(1):1–12. <https://doi.org/10.1038/s41598-020-80936-4>.
 281. Wang G, Liu X, Li C, Xu Z, Ruan J, Zhu H, Meng T, Li K, Huang N, Zhang S. A Noise-Robust Framework for Automatic Segmentation of COVID-19 Pneumonia Lesions from CT Images. *IEEE Trans Med Imaging.* 2020;39(8):2653–63. <https://doi.org/10.1109/TMI.2020.3000314>.
 282. Zhao X, Zhang P, Song F, Fan G, Sun Y, Wang Y, Tian Z, Zhang L, Zhang G. D2A U-Net: Automatic segmentation of COVID-19 lesions from CT slices with dilated convolution and dual attention mechanism. pp. 0–2, 2021, [Online]. Available: <http://arxiv.org/abs/2102.05210>
 283. Ter-Sarkisov A. Lightweight model for the prediction of COVID-19 through the detection and segmentation of lesions in chest CT scans. *Sci Inf Technol Lett.* 2020;1(2):92–9. <https://doi.org/10.31763/sitech.v1i2.202>.
 284. Karakanis S, Leontidis G. Lightweight deep learning models for detecting COVID-19 from chest X-ray images. *Comput Biol Med.* 2021;130:104181. <https://doi.org/10.1016/j.combiomed.2020.104181>.
 285. Ciano G, Andreini P, Mazzierli T, Bianchini M, Scarselli F. A multi-stage GAN for multi-organ chest X-ray image generation and segmentation. pp. 1–15, 2021, [Online]. Available: <http://arxiv.org/abs/2106.05132>
 286. Mahapatra D, Singh A. CT image synthesis using weakly supervised segmentation and geometric inter-label relations for COVID image analysis. pp. 1–13, 2021, [Online]. Available: <http://arxiv.org/abs/2106.10230>
 287. Karbhari Y, Basu A, Geem Z, Han G. Generation of Synthetic Chest X-ray Images and Detection of COVID-19 : a deep learning based approach. 2021; 1–19.
 288. Mukherjee H, Ghosh S, Dhar A, Obaidullah SM, Santosh KC, Roy K. Shallow convolutional neural network for COVID-19 outbreak screening using chest X-rays. *Cognit Comput.* 2021. <https://doi.org/10.1007/s12559-020-09775-9>.
 289. Fan DP, Zhou T, Ji GP, Zhou Y, Chen G, Fu H, Shen J, Shao L. Inf-Net: automatic COVID-19 lung infection segmentation from CT Images. *IEEE Trans Med Imaging.* 2020;39(8):2626–37. <https://doi.org/10.1109/TMI.2020.2996645>.
 290. Wang G, Liu X, Shen J, Wang C, Li Z, Ye L, Wu X, Chen T, Wang K, Zhang X, Zhou Z, Yang J, Sang Y, Deng R, Liang W, Yu T, Gao M, Wang J, Yang Z, Cai H, Lu G. A deep-learning pipeline for the diagnosis and discrimination of viral, non-viral and COVID-19 pneumonia from chest X-ray images. *Nat Biomed Eng.* 2021;5(6):509–21. <https://doi.org/10.1038/s41551-021-00704-1>.
 291. Yasar H, Ceylan M. A new deep learning pipeline to detect Covid-19 on chest X-ray images using local binary pattern, dual tree complex wavelet transform and convolutional neural networks. *Appl Intell.* 2021;51(5):2740–63. <https://doi.org/10.1007/s10489-020-02019-1>.
 292. Naudé W. Artificial intelligence vs COVID-19: limitations, constraints and pitfalls. *AI Soc.* 2020;35(3):761–5. <https://doi.org/10.1007/s00146-020-00978-0>.
 293. Khanday NY, Sofi SA. Deep insight: Convolutional neural network and its applications for COVID-19 prognosis. 2020.
 294. Chandrasekaran B, Fernandes S. TLCoV- An automated Covid-19 screening model using transfer learning from chest X-ray images. *Diabetes Metab Syndr.* 2020;14(4):337–9.
 295. Arshad Q, Khan WZ, Azam F, Khan MK. deep learning based COVID-19 detection : challenges and future directions. 2021;0–18 doi: <https://doi.org/10.36227/techrxiv.14625885>.
 296. Watson J, Whiting PF, Brush JE. Interpreting a covid-19 test result. *BMJ.* 2020;369:1–7. <https://doi.org/10.1136/bmj.m1808>.
 297. Blain M, Kassin MT, Varble N, Wang X, Xu Z, Xu D, Carrafiello G, Vespro V, Stellato E, Ierardi AM, Di Meglio L, Suh RD, Walker SA, Xu S, Sanford TH, Turkbey EB, Harmon S, Turkbey B, Wood BJ. Determination of disease severity in COVID-19 patients using deep learning in chest X-ray images. *Diagnostic Interv. Radiol.*, 2020, doi: <https://doi.org/10.5152/dir.2020.20205>.
 298. Hall LO, Paul R, Goldgof DB, Goldgof GM. Finding COVID-19 from Chest X-rays using Deep Learning on a Small Dataset. *arXiv*, 2020; 1–8.
 299. Samuel OO. Low dose radiation therapy for Covid-19 Pneumonia: the pros and cons. pp. 1–5, 2020, doi: <https://doi.org/10.36648/2574-285X.5.3.11>.
 300. Gilanie G, Bajwa UI, Waraich MM, Asghar M, Kousar R, Kashif A, Aslam RS, Qasim MM, Rafique H. Coronavirus (COVID-19) detection from chest radiology images using convolutional neural networks. *Biomed Signal Process Control.* 2021;66:102490. <https://doi.org/10.1016/j.bspc.2021.102490>.
 301. Helwan A, Ma'Aitah MKS, Hamdan H, Ozsahin DU, Tuncyurek O. Radiologists versus Deep Convolutional Neural Networks: A Comparative Study for Diagnosing COVID-19. *Comput. Math. Methods Med.*, 2021; 2021, doi: <https://doi.org/10.1155/2021/5527271>.
 302. Wang SH, Nayak DR, Guttery DS, Zhang X, Zhang YD. COVID-19 classification by CSHNet with deep fusion using transfer learning and discriminant correlation analysis. *Inf Fusion.* 2021;68:131–48. <https://doi.org/10.1016/j.inffus.2020.11.005>.

303. Kikkiseti S, Zhu J, Shen B, Li H, Duong TQ. Deep-learning convolutional neural networks with transfer learning accurately classify COVID-19 lung infection on portable chest radiographs. *PeerJ*. 2020;8:1–13. <https://doi.org/10.7717/peerj.10309>.
304. Gianchandani N, Jaiswal A, Singh D, Kumar V, Kaur M. Rapid COVID-19 diagnosis using ensemble deep transfer learning models from chest radiographic images. *J. Ambient Intell. Humaniz. Comput.*, 2020;0123456789 doi: <https://doi.org/10.1007/s12652-020-02669-6>.
305. Ezzat D, Hassanien AE, Ella HA. An optimized deep learning architecture for the diagnosis of COVID-19 disease based on gravitational search optimization. *Appl. Soft Comput. J.*, 2020;(xxxx), 106742. doi: <https://doi.org/10.1016/j.asoc.2020.106742>.
306. Huang S, Yang J, Fong S, Zhao Q. Artificial intelligence in the diagnosis of covid-19: Challenges and perspectives. *Int J Biol Sci.* 2021;17(6):1581–7. <https://doi.org/10.7150/ijbs.58855>.
307. Rajaraman S, Siegelman J, Alderson PO, Folio LS, Folio LR, Antani SK. Iteratively pruned deep learning ensembles for COVID-19 detection in chest X-Rays. *IEEE Access.* 2020;8:115041–50. <https://doi.org/10.1109/ACCESS.2020.3003810>.
308. Selvaraju RR, Cogswell M, Das A, Vedantam R, Parikh D, Batra D. Grad-CAM: Visual Explanations from Deep Networks via Gradient-Based Localization. *Int J Comput Vis.* 2020;128(2):336–59. <https://doi.org/10.1007/s11263-019-01228-7>.

Publisher's Note Springer Nature remains neutral with regard to jurisdictional claims in published maps and institutional affiliations.

Springer Nature or its licensor (e.g. a society or other partner) holds exclusive rights to this article under a publishing agreement with the author(s) or other rightsholder(s); author self-archiving of the accepted manuscript version of this article is solely governed by the terms of such publishing agreement and applicable law.