

# Computer Image-Guided Precise Acromioplasty for Reducing the Critical Shoulder Angle



Yi Long, M.D., Jing-Yi Hou, M.D., Jian-Fa Chen, M.D., Wei Xiang, M.D., Qi-Sheng Lin, M.D., Xiao-Bing Xiang, M.D., and Rui Yang, M.D., Ph.D.

**Abstract:** The shoulders with critical shoulder angle (CSA) of greater than 33-35° are associated with rotator cuff tears, whereas a CSA of less than 30° is likely to be osteoarthritic. However, anterior acromioplasty or lateral acromioplasty could not reduce high CSAs to the desired range (30-33°), with satisfactory accuracy and efficacy. Thus, we introduce a computer image-guided precise acromioplasty (CIG-PAP) technique, an individualized treatment based on three-dimensional planning. We believe that the introduction of this technique will provide an alternative approach to reduce a large CSA to the desired range (30-33°).

## Introduction

The critical shoulder angle (CSA) describes the lateral extension of the acromion in relation to the inclination of the glenoid and has been demonstrated to be an effective predictor for the development of shoulder pathology.<sup>1-4</sup> Numerous studies have documented that shoulders with a CSA of less than 30° were likely to be osteoarthritic, whereas a CSA of greater than 33-35° was associated with rotator cuff tears (RCTs).<sup>5-10</sup> Gerber et al. demonstrated that patients with a CSA reduced to 33° or less had superior abduction strength and lower retear rate after arthroscopic rotator cuff repair (RCR).<sup>11</sup>

Therefore, accurately reducing the large CSA to the desired range (30-33°) seems to become one of the important goals in the clinical treatment of RCTs.

Several studies have shown that anterior acromioplasty reduced the CSA by a mean of 1-3.2°. <sup>12-15</sup> In comparison, lateral acromioplasty could significantly decrease the CSA by a mean of 3.6-6.5°. <sup>11,16,17</sup> However, whether anterior or lateral, 20-52% of patients still had postoperative CSA > 35° after acromioplasty, while CSA were over-reduced to below 30° in some cases. <sup>11-14,16-19</sup> Currently, avoiding insufficient or over-reduction of the CSA is still a challenging problem.

In this article, we present a computer image-guided precise acromioplasty (CIG-PAP) technique, which is an individualized treatment based on three-dimensional (3-D) planning to reduce a large CSA to the desired range (30-33°). CIG-PAP is especially indicated for patients with RCTs combined with preoperative CSA greater than 35°. We hope that using this technique concomitant to arthroscopic RCR would provide clinical benefits to patients. Conversely, contraindication for CIG-PAP would include the following: irreparable RCTs, inflammatory arthritis, and concomitant fracture or dislocation of the shoulder.

*From the Department of Orthopaedic Surgery, Sun Yat-sen Memorial Hospital, Sun Yat-sen University, Guangzhou, China (Y.L., J-Y.H., R.Y.); Department of Orthopaedic Surgery, The First Affiliated Hospital, Guangzhou University of Traditional Chinese Medicine, Guangzhou, China (J-F.C., X-B.X.); and Department of Orthopaedic Surgery, The Eighth Affiliated Hospital, Sun Yat-Sen University, Shenzhen, China (W.X., Q-S.L.)*

*This study was supported by the Fundamental Research Funds for the Central Universities, Sun Yat-sen University (no. 2020004). Full ICMJE author disclosure forms are available for this article online, as [supplementary material](#).*

*Received April 18, 2022; accepted June 27, 2022.*

*Address correspondence to Rui Yang, M.D., Ph.D., Department of Orthopedics, Sun Yat-sen Memorial Hospital, Sun Yat-sen University, 107 Yan Jiang Road West, Guangzhou, Guangdong 510120, China. E-mail: [yangr@mail.sysu.edu.cn](mailto:yangr@mail.sysu.edu.cn)*

*© 2022 THE AUTHORS. Published by Elsevier Inc. on behalf of the Arthroscopy Association of North America. This is an open access article under the CC BY-NC-ND license (<http://creativecommons.org/licenses/by-nc-nd/4.0/>).*

*2212-6287/22530*

*<https://doi.org/10.1016/j.eats.2022.06.026>*

## Surgical Technique (With Video Illustration)

### 3-D Reconstruction and Coordinate System Establishment

Digital Imaging and Communications in Medicine (DICOM) data of shoulder are obtained. Three-dimensional reconstruction is made using Mimics 20.0 (Materialise, Leuven, Belgium). Subsequently, 3-D

shoulder model is imported into Blender 2.81 (Amsterdam, Netherlands) to establish a Cartesian coordinate system for position alignment, according to previous studies.<sup>20,21</sup>

### Preoperative Planning and Measurement

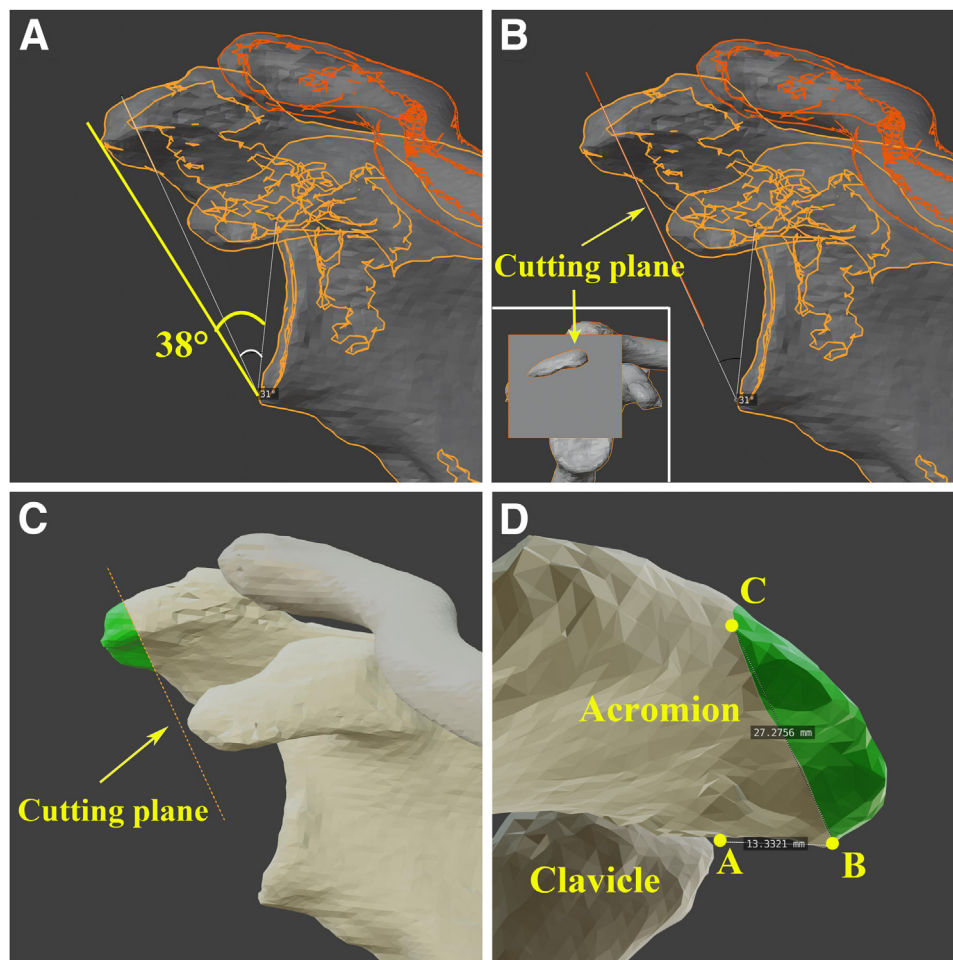
Preoperative planning is performed on 3-D shoulder model using Blender 2.81. First, preoperative CSA is measured on the standard anterior view to confirm the value of CSA greater than  $35^\circ$  ( $38^\circ$  in this article). The CSA is measured between a line connecting the superior and inferior borders of the glenoid and another line from the inferior borders of the glenoid to the most inferolateral point of the acromion.<sup>1</sup> And then, the postoperative target CSA is set at  $31^\circ$ , which is in the middle of the desired range of  $30\text{--}33^\circ$  (Fig 1A). Next, a cutting plane is established and positioned at the measuring line of  $31^\circ$  (Fig 1B). Hence, the external

acromion of the cutting plane (green region) is the part of the bone to be removed (Fig 1C). Lastly, the resected bone borders are identified and measured on the computer, including the anterior acromial edge of acromioclavicular joint (Point A), anteromedial resection margin (Point B), posterolateral resection margin (Point C), and the distance of AB (approximately 13 mm) and BC (approximately 27 mm) (Fig 1D).

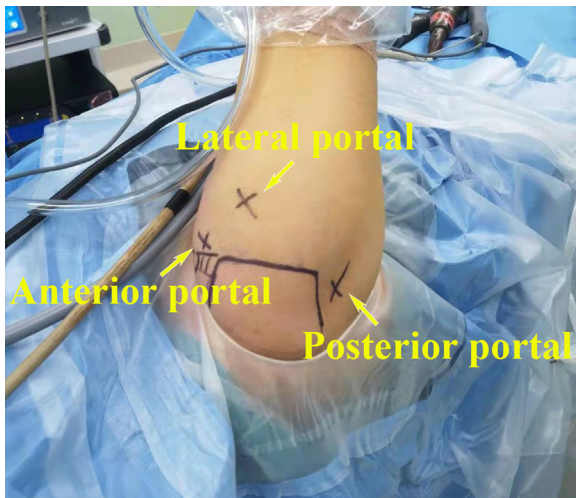
### Arthroscopic CIG-PAP

After general anesthesia combined with brachial plexus block, the patient is placed in the lateral decubitus position with the arm in  $30^\circ$  abduction and with 10 pounds of traction. The bony landmarks are identified and marked, together with anterior, posterior, and lateral portals (Fig 2).

After the posterior and anterior portals are created, a routine diagnostic arthroscopy is performed in the



**Fig 1.** Demonstration of preoperative planning and measurement (right shoulder). (A) Preoperative CSA (yellow line,  $38^\circ$ ) is measured on the standard anterior view of 3-D shoulder. And the postoperative target CSA is set at  $31^\circ$  (white line). (B) The cutting plane is created and positioned at the measuring line of  $31^\circ$ . (C) The green region outside the cutting plane is the part of the acromion to be resected. (D) The measurement of resected bone borders, including the distance of AB (approximately 13 mm) and BC (approximately 27 mm). “A” denotes anterior acromial edge of acromioclavicular joint, “B” denotes anteromedial resection margin, and “C” denotes posterolateral resection margin; CSA, critical shoulder angle.



**Fig 2.** The patient is placed in the lateral decubitus position with continuous extremity traction (right shoulder). The bony landmarks are outlined, and the anterior, posterior, and lateral portals are marked.

articular cavity. Any intra-articular pathology is assessed and addressed appropriately if necessary, including articular cartilage, glenoid labrum, glenohumeral ligament, biceps, and subscapularis.

The 30° arthroscope is then inserted into the sub-acromial space, and a lateral portal is established to assess the reparability of the RCT based on tear location, size, degree of retraction, tension, tissue quality, and other variables. Once the RCT is determined to be repairable, the following procedures will be performed.

First, all soft tissue undersurface of the acromion and acromioclavicular joint is cleaned using radiofrequency electrocautery (Arthrex, Naples, FL). After fully revealing the acromioclavicular joint, anterior and

lateral borders of the acromion, the anterior acromial edge of acromioclavicular joint (point A) is identified and marked with a spinal needle (Fig 3; Video 1).

Second, the posterior portal is used as the viewing portal, and the lateral portal is used as the working portal for measurement. According to the preoperative planning, the anteromedial resection margin (point B) is identified by measuring the distance of AB (approximately 13 mm in this article), and marked with a spinal needle (Fig 4; Video 1).

Third, the lateral portal is used as the viewing portal, and the anterior portal is used as the working portal for measurement. The posterolateral resection margin (point C) is identified by measuring the distance of BC (approximately 27 mm in this article), and also marked with a spinal needle (Fig 5; Video 1).

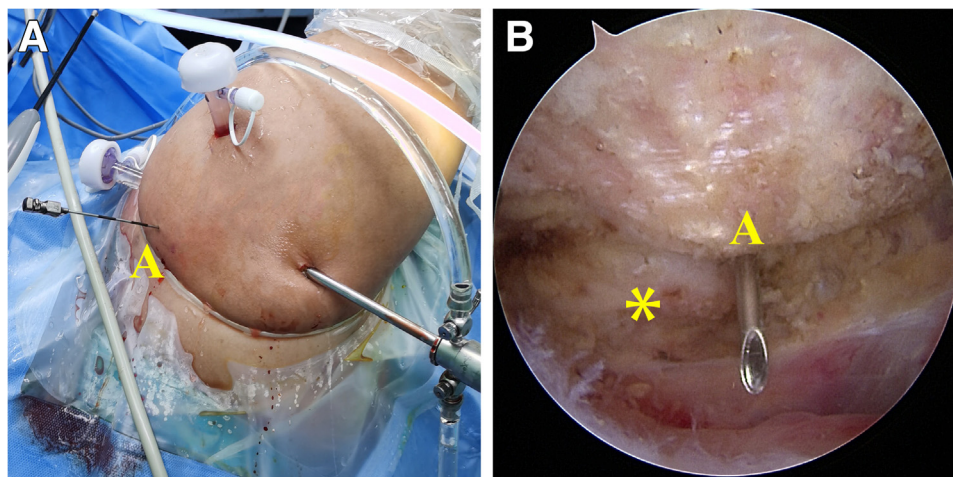
Then, a 0# PDS® (polydioxanone) suture (Ethicon, Somerville, NJ) is introduced under arthroscopy from point B to C through the inner core of the straight needles, and the blue resection line (BC) is made (Video 1).

Next, the region of the acromion outside the blue resection line is gradually resected by a 5.5-mm shaver burr (Arthrex) via the lateral portal (Fig 6; Video 1). Finally, the cutting surface of the acromion is deactivated using radiofrequency electrocautery (Arthrex).

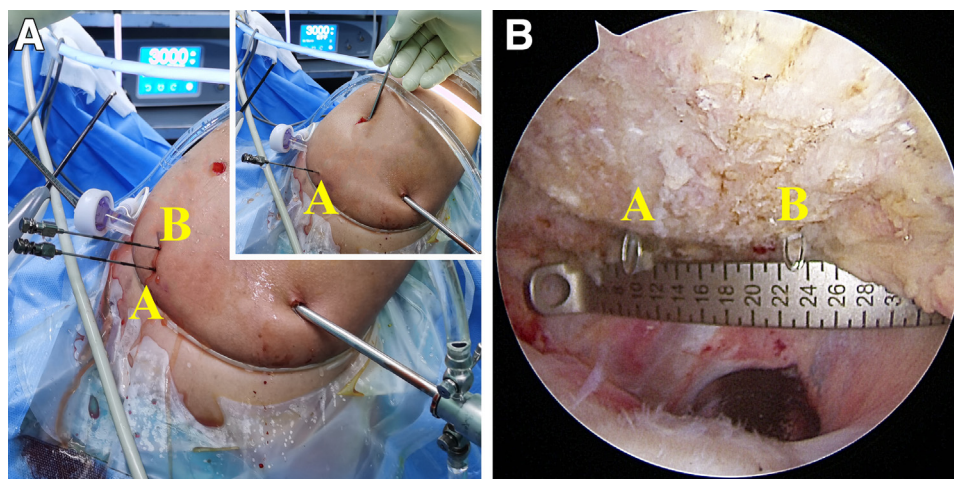
Arthroscopic RCR is then performed depending on the tear location and size. Standard anteroposterior (AP) radiograph (type A1 or C1 according to the Suter-Henninger classification<sup>20</sup>) (Fig 7) or CT scans of the shoulder is taken 3-5 days postoperation to assess the post-operative CSA.

### Postoperative Management

As the CIG-PAP is concomitant with arthroscopic RCR, the patient should follow the rehabilitation protocol of



**Fig 3.** Identifying and marking the point A with a spinal needle (right shoulder in lateral decubitus position). (A) Gross view after inserting the spinal needle. (B) Arthroscopic view using 30° arthroscope from the posterior portal. A denotes anterior acromial edge of acromioclavicular joint. The asterisk (\*) denotes the clavicle.



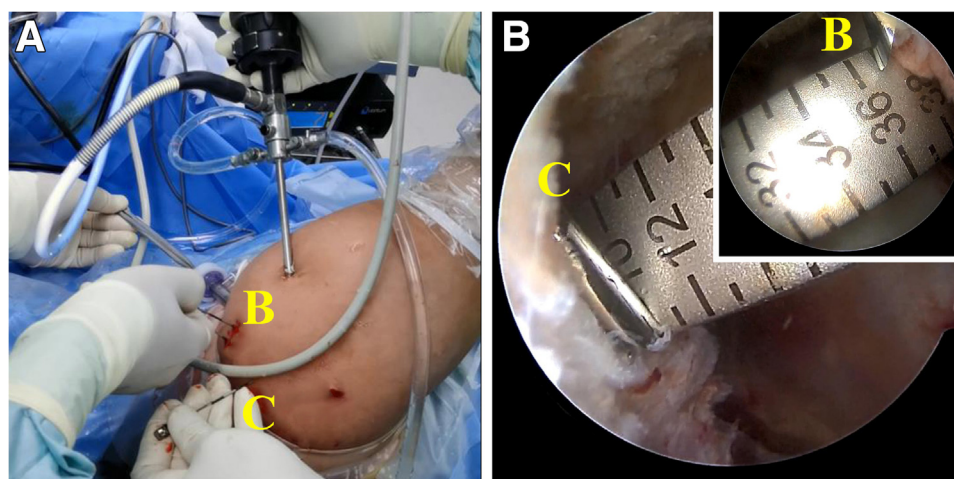
**Fig 4.** Marking the point B with a spinal needle by measuring the distance of AB on the undersurface of the acromion (right shoulder in lateral decubitus position). (A) Gross view of the measurement and marking. (B) Arthroscopic view using 30° arthroscope from the posterior portal, and measuring the distance of AB from the lateral portal (scale from 10 mm to 23 mm, ~13 mm). A denotes the anterior acromial edge of acromioclavicular joint; B denotes the anteromedial resection margin.

RCR. The upper limb is placed into a shoulder and elbow brace for immobilization immediately after the operation. Active activity of the elbow and wrist should be started on the second day postoperatively. Passive or active-assisted shoulder range-of-motion exercises should begin 1-2 weeks after the operation. Active shoulder motion should be started after 8 weeks and gradually strengthened and reintegrated into normal activities at 12 weeks postoperatively.

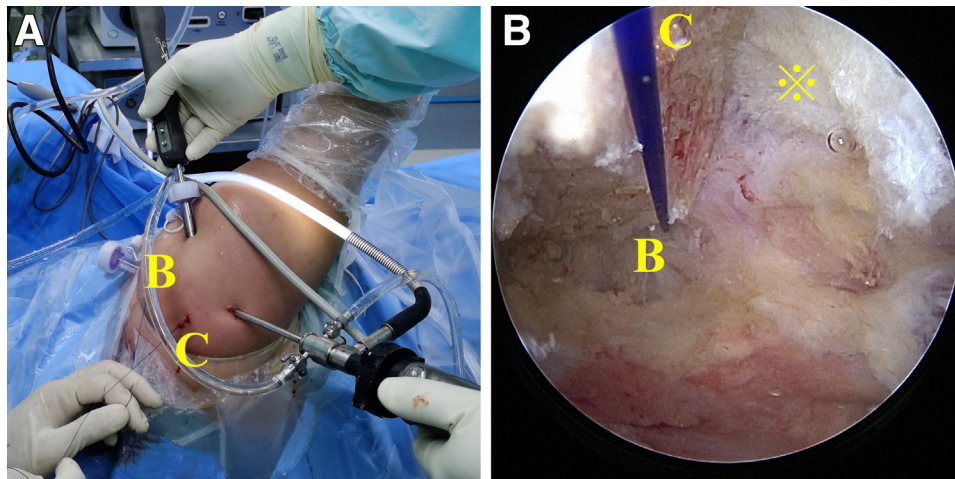
### Discussion

Since the reduction of CSA is difficult to predict intraoperatively, the favorable range of postoperative CSA is

not always achieved after acromioplasty. Olmos et al. suggested using the approximation of “1 degree of CSA reduction for each 1 mm of resection” to quantify the amount of acromion to be resected by lateral acromioplasty; however, they found that 46.3% of patients still had a postoperative CSA > 35°. <sup>17</sup> Similarly, to calculate the amount of acromion resection for reducing the CSA, Franceschetti et al. developed a formula by measuring the parameters on the AP radiographs. <sup>22</sup> Although they reported using the complex formula could reduce the large CSAs to the range of 30-35°, how to accurately apply the preoperative planning to arthroscopic acromioplasty needs to be further clarified. <sup>22</sup>



**Fig 5.** Marking the point C with a spinal needle by measuring the distance of BC on the undersurface of the acromion (right shoulder in lateral decubitus position). (A) Gross view of the measurement and marking. (B) Arthroscopic view using 30° arthroscope from the lateral portal, and measuring the distance of BC from anterior portal (scale from 10 mm to 37 mm, ~27 mm). B denotes the anteromedial resection margin; C denotes the posterolateral resection margin.



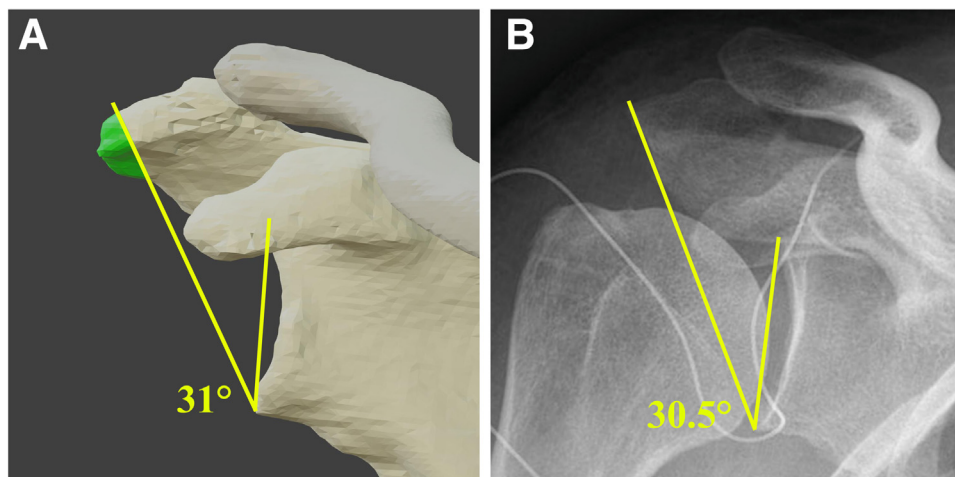
**Fig 6.** Removing the acromial bone outside the resection line BC (right shoulder in lateral decubitus position). (A) Gross view after marking the resection line BC with a 0# PDS® (polydioxanone) suture (Ethicon, Somerville, NJ). (B) Arthroscopic view using 30° arthroscope from the posterior portal, and working from the lateral portal. B denotes the anteromedial resection margin; C denotes the posterolateral resection margin; \* symbol denotes the deltoid fascia.

The CIG-PAP provides a new potential strategy for accurate reduction of CSA without insufficient or over-resection of the acromion (Table 1). This all-arthroscopic personalized acromioplasty is concomitant with arthroscopic RCR. And it is recommended to perform this technique first to increase space for visualization and suture passage during RCR (Table 2). The most difficult manipulation of this technique is how to accurately locate the area of osteotomy during arthroscopy, according to the 3-D planning.

In the early stage, we measured the resected bone borders on the patient's skin after the bony

landmarks were marked.<sup>23</sup> This method was satisfactory for some thin patients. However, it was inaccurate for the patients with unclear bony landmarks. Moreover, the body surface marker points would shift after the shoulder was filled with water during the operation.

This article modified the procedure to locate the area of osteotomy with greater accuracy. We selected the anterior edge of the acromioclavicular joint (point A) as an initial marker point, because it was relatively stable and easy to identify under arthroscopy. And we directly measured and marked the resected bone border under the arthroscopy instead of marking it



**Fig 7.** The pre-operative three-dimensional planning and postoperative measurement for CSA (right shoulder). (A) Target CSA of preoperative planning is set at 31°. (B) Postoperative CSA measured on the standard anteroposterior radiograph is 30.5°. CSA, critical shoulder angle.

**Table 1.** Advantages and Disadvantages

Advantages	Disadvantages
<ul style="list-style-type: none"> <li>• All-arthroscopic visual operation technique</li> <li>• No extra incisions and specialty instruments</li> <li>• Individualized acromioplasty</li> <li>• Avoiding insufficient or over-reduction of the CSA</li> <li>• Greater reduction of the CSA with the lower volume of resected bone.</li> </ul>	<ul style="list-style-type: none"> <li>• New learning curves for operators</li> <li>• Preoperative CT scans of the shoulder and 3-D planning are needed.</li> <li>• Lack of clinical follow-up data</li> </ul>

CSA, critical shoulder angle; CT, computed tomography; 3-D, three dimensional.

on the body skin. We hope these improvements would reduce the CSA with greater consistency between preoperative 3-D planning and intraoperative osteotomy. Our preliminary cohort results are promising.

The main disadvantage of this technique is that preoperative 3-D planning is necessary. Therefore, there are inevitable learning curves for the 3-D planning tools described in this article. However, any other similar application software can be chosen depending on the operator's proficiency and preference. In fact, many other 3-D planning tools described in the literature can also realize the process.<sup>24-26</sup> Maybe an automatic 3-D planning program will simplify the procedure in the future.

In general, the CIG-PAP provides a new individualized treatment for accurate correction of CSA. Further research and clinical trials need to be carried out to evaluate the clinical benefits.

**Table 2.** Tips and Tricks

<ul style="list-style-type: none"> <li>• Clean all soft tissue undersurface of the acromion and acromioclavicular joint to get a better operation field.</li> <li>• To increase space for visualization and suture passage during RCR, it is recommended to perform the CIG-PAP first.</li> <li>• The acromion should be gradually resected from the undersurface to the upper until the deltoid fascia is exposed.</li> <li>• The spinal needles should be vertically inserted close to the acromial edge as far as possible.</li> <li>• After inserting the spinal needles, the assistant should keep the needle tails from swinging greatly.</li> <li>• The cutting surface of acromion should be deactivated using radiofrequency electrocautery.</li> </ul>
--

CIG-PAP, computer image-guided precise acromioplasty; RCR, rotator cuff repair.

## References

1. Moor BK, Bouaicha S, Rothenfluh DA, Sukthankar A, Gerber C. Is there an association between the individual anatomy of the scapula and the development of rotator cuff tears or osteoarthritis of the glenohumeral joint?: A radiological study of the critical shoulder angle. *Bone Joint J* 2013;935-941. 95-B.
2. Incesoy MA, Yildiz KI, Turk OI, et al. The critical shoulder angle, the acromial index, the glenoid version angle and the acromial angulation are associated with rotator cuff tears. *Knee Surg Sports Traumatol Arthrosc* 2020;29:2257-2263.
3. Cunningham G, Cocor C, Smith MM, Young AA, Cass B, Moor BK. Implication of bone morphology in degenerative rotator cuff lesions: A prospective comparative study between greater tuberosity angle and critical shoulder angle. *Orthop Traumatol Surg Res* 2022;108:103046.
4. Lin CL, Chen YW, Lin LF, Chen CP, Liou TH, Huang SW. Accuracy of the critical shoulder angle for predicting rotator cuff tears in patients with nontraumatic shoulder pain. *Orthop J Sports Med* 2020;8. 2325967120918995.
5. Tang Y, Hou J, Li Q, et al. The Effectiveness of using the critical shoulder angle and acromion index for predicting rotator cuff tears: Accurate diagnosis based on standard and nonstandard anteroposterior radiographs. *Arthroscopy* 2019;35:2553-2561.
6. Smith GCS, Liu V. High Critical shoulder angle values are associated with full-thickness posterosuperior cuff tears and low values with primary glenohumeral osteoarthritis. *Arthroscopy* 2022;38:709-715. e701.
7. Mantell MT, Nelson R, Lowe JT, Endrizzi DP, Jawa A. Critical shoulder angle is associated with full-thickness rotator cuff tears in patients with glenohumeral osteoarthritis. *J Shoulder Elbow Surg* 2017;26:e376-e381.
8. Razmjou H, Palinkas V, Christakis M, Roberts S, Kennedy D. Reduced acromiohumeral distance and increased critical shoulder angle: implications for primary care clinicians. *Phys Sportsmed* 2020;48:312-319.
9. Hohmann E, Shea K, Scheiderer B, Millett P, Imhoff A. Indications for arthroscopic subacromial decompression. A level V evidence clinical guideline. *Arthroscopy* 2020;36:913-922.
10. Tunali O, Ersen A, Kizilkurt T, Bayram S, Sivacioglu S, Atalar AC. Are critical shoulder angle and acromion index correlated to the size of a rotator cuff tear. *Orthop Traumatol Surg Res* 2022;108:103122.
11. Gerber C, Catanzaro S, Betz M, Ernstbrunner L. Arthroscopic correction of the critical shoulder angle through lateral acromioplasty: A safe adjunct to rotator cuff repair. *Arthroscopy* 2018;34:771-780.
12. Katthagen JC, Marchetti DC, Tahal DS, Turnbull TL, Millett PJ. The effects of arthroscopic lateral acromioplasty on the critical shoulder angle and the anterolateral deltoid origin: An anatomic cadaveric study. *Arthroscopy* 2016;32:569-575.

13. Billaud A, Cruz-Ferreira E, Pesquer L, Abadie P, Carlier Y, Flurin PH. Does the critical shoulder angle decrease after anterior acromioplasty? *Arch Orthop Trauma Surg* 2019;139:1125-1132.
14. Girard M, Colombi R, Azoulay V, et al. Does anterior acromioplasty reduce critical shoulder angle? *Orthop Traumatol Surg Res* 2020;106:1101-1106.
15. MacLean IS, Gowd AK, Waterman BR, et al. The effect of acromioplasty on the critical shoulder angle and acromial index. *Arthroscopy* 2020;2:e623-e628.
16. Altintas B, Kääb M, Greiner S. Arthroscopic lateral acromion resection (ALAR) optimizes rotator cuff tear relevant scapula parameters. *Arch Orthop Trauma Surg* 2016;136:799-804.
17. Olmos MI, Boutsiadis A, Swan J, et al. Lateral acromioplasty cannot sufficiently reduce the critical shoulder angle if preoperatively measured over 40 degrees. *Knee Surg Sports Traumatol Arthrosc* 2021;29:240-249.
18. Gurpinar T, Polat B, Carkci E, Eren M, Polat AE, Ozturkmen Y. The effect of critical shoulder angle on clinical scores and retear risk after rotator cuff tendon repair at short-term follow up. *Sci Rep* 2019;9:12315.
19. Hardy V, Rony L, Bachler J, Favard L, Hubert L. Does anterior arthroscopic acromioplasty modify critical shoulder angle? *Orthop Traumatol Surg Res* 2021;107:102936.
20. Suter T, Gerber Popp A, et al. The influence of radiographic viewing perspective and demographics on the critical shoulder angle. *J Shoulder Elbow Surg* 2015;24:e149-158.
21. Suter T, Henninger HB, Zhang Y, Wylie JD, Tashjian RZ. Comparison of measurements of the glenopolar angle in 3D CT reconstructions of the scapula and 2D plain radiographic views. *Bone Joint J* 2016:1510-1516. 98-B.
22. Franceschetti E, Giovannetti de Sanctis E, Palumbo A, et al. Lateral acromioplasty has a positive impact on rotator cuff repair in patients with a critical shoulder angle greater than 35 degrees. *J Clin Med* 2020;9:3950.
23. Long Y, Hou J, Tang Y, et al. Effect of arthroscopic acromioplasty on reducing critical shoulder angle: A protocol for a prospective randomized clinical trial. *BMC Musculoskelet Disord* 2020;21:819.
24. Ghafurian S, Galdi B, Bastian S, Tan V, Li K. Computerized 3D morphological analysis of glenoid orientation. *J Orthop Res* 2016;34:692-698.
25. Beeler S, Hasler A, Gotschi T, Meyer DC, Gerber C. Different acromial roof morphology in concentric and eccentric osteoarthritis of the shoulder: A multiplane reconstruction analysis of 105 shoulder computed tomography scans. *J Shoulder Elbow Surg* 2018;27:e357-e366.
26. Billaud A, Lacroix PM, Carlier Y, Pesquer L. How much acromial bone should be removed to decrease the critical shoulder angle? A 3D CT acromioplasty planning study. *Arch Orthop Trauma Surg* 2022. <https://doi.org/10.1007/s00402-021-04292-2>.