

Failures in emergency management of pediatric airway foreign bodies by rigid bronchoscopy: we have yet to complete our learning

Mohammad Ashkan Moslehi 

To cite: Moslehi MA. Failures in emergency management of pediatric airway foreign bodies by rigid bronchoscopy: we have yet to complete our learning. *World Jnl Ped Surgery* 2022;5:e000321. doi:10.1136/wjps-2021-000321

Received 4 June 2021

Accepted 3 January 2022

ABSTRACT

Background Several children are affected by airway foreign body aspiration (FBA) resulting from life-threatening conditions. Choking has been considered the major symptom and is defined as airway blockage by a foreign body (FB), leading to marked morbidity or mortality. This retrospective study indicates the possibility of misdiagnosis or rigid bronchoscope (RB) failure, which is the standard gold method for extracting FB in the airway.

Methods Six children with airway FBA who failed treatment using RB between 2018 and 2019 were retrospectively studied. The inclusion criterion was a history of failure to extract FB using RB followed by flexible fiberoptic bronchoscopy (FFB).

Results In the present study, among 63 patients who had undergone rigid bronchoscopy, airway FBs were successfully removed in 57 (90.48%). Rigid bronchoscopy failed in 6 (9.52%) patients. The age of cases at the time of bronchoscopy ranged from 11 months to 13 years. FFB was performed to extract missing or remaining FBs and was done successfully in all patients. The patients made an uneventful recovery following FB extraction using the FFB method.

Conclusions It is not easy to diagnose and treat airway FB in children. Rigid bronchoscopy has been approved as a method to manage airway FB, but a negative bronchoscopy result must usually be interpreted carefully. FFB is applicable as a proper and relatively safe diagnostic and therapeutic tool in managing airway FBs among the pediatric population, especially in cases where rigid bronchoscopy was performed but missed or failed to extract the FB.

INTRODUCTION

Although young children up to 4 years of age are highly at risk of foreign body aspiration (FBA), this condition can be seen in all age groups. Emergency management such as bronchoscopy is highly suggested due to the probability of severe unwanted consequences after aspiration. Accordingly, prompt and timely diagnosis of FBA can prevent such unwanted and even irreversible complications. Furthermore, proper diagnosis is only possible if the treating physician has strong

Key messages

What is already known about this subject?

- ▶ Foreign body aspiration remains a leading cause of morbidity and mortality in children.
- ▶ Young children are particularly at risk of foreign body aspiration.
- ▶ Foreign body aspiration typically presents with choking episodes with varying amounts of obstruction to the airway.
- ▶ Rigid bronchoscopy is the method of choice for diagnosis and management of foreign body aspiration.

What are the new findings?

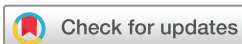- ▶ Although rigid bronchoscopy is still considered the standard gold method for foreign body extraction among children, in practice several types of therapeutic failure can be encountered during this procedure which every bronchoscopist should be aware of and should be able to manage appropriately.

How might it impact clinical practice in the foreseeable future?

- ▶ Awareness of the different types of failure in the management of airway foreign bodies by rigid bronchoscope, which can be managed using fiberoptic bronchoscope, should be considered.
- ▶ The current study shows that, in addition to rigid bronchoscopes, a variety of flexible fiberoptic bronchoscopes and compatible instruments should be accessible at every center when needed.

clinical suspicion, especially in cases with no evidence of aspiration. Rigid bronchoscopy (RB) has long been used as the gold standard to remove airway foreign bodies (FBs). However, like other medical procedures, RB may be associated with diagnostic and even therapeutic failures.

On the other hand, flexible fiberoptic bronchoscopes (FFBs) have recently gained remarkable popularity as these types of bronchoscopes have made significant progress in image quality and different appropriate sizes, along with the availability of various supplementary instruments, such as forceps



© Author(s) (or their employer(s)) 2022. Re-use permitted under CC BY-NC. No commercial re-use. See rights and permissions. Published by BMJ.

Pediatric Interventional Pulmonology Division, Medical School, Shiraz University of Medical Sciences, Shiraz, Iran

Correspondence to

Professor Mohammad Ashkan Moslehi; ashkanmoslehi@gmail.com

and baskets. Compared with RB, FFB has good flexibility in reaching the proper position to catch foreign objects, especially those stuck in peripheral airways. More importantly, FFB can be done outside the operating room (OR) by light sedation. Several studies have been published in recent years on the safety and efficiency of using FFB among children.^{1,2} The use of novel methods to remove airway FBs in children, such as cryoextraction, has increased the confidence of replacing such bronchoscopes with conventional ones.³⁻⁶ Deciding when to use flexible or rigid bronchoscopes will depend entirely on the bronchoscopist's experience and on the type of FB, the location, and the facilities needed to perform. Most published studies have examined only one method in terms of effectiveness and side effects. Few studies have compared flexible and rigid methods with each other.⁷⁻⁹ On the other hand, the errors or the reasons RB fails to remove obstruction in children's lungs have not been thoroughly investigated. The current study examined the spectrum of restrictions of RB as well as the uncommon cases that lead to use of FFB as an alternative to manage airway FBs in children.

METHODS

In this study, 63 medical records of patients with a diagnosis of FBA who underwent RB at Shiraz University Pediatric Interventional Pulmonology Division from 2018 to 2019 were reviewed retrospectively. Six children with airway FBs, in whom RB failed to extract the FB, were then selected.

RESULTS

RB was the primary method of FB removal in all 63 patients studied, resulting in a successful treatment in 90.48% of patients. FB extraction by RB was unsuccessful in 6 of 63 (9.52%) patients aged 11 months to 5 years who were referred to our division and underwent FFB. Four (66.4%) of these patients were boys. The male to female ratio was 2:1. All cases had a positive history of aspiration with an eyewitness. Choking (83%), coughing (50%), and noisy breathing (50%) were the most common clinical presentations. Unilateral hyperinflation was the most common imaging finding, which was reported in half of the patients. Only one patient (16.6%) had a normal chest X-ray (table 1).

Case 1

A 2-year-old girl visited our hospital due to severe respiratory distress and cyanotic spells that lasted 7 days, along with a history of choking after aspiration of nuts in the preceding 12 days before her referral. Her chest X-ray showed right lung hyperinflation. The surgeon could not remove the friable object and RB failed. FFB was therefore considered, where two small nut particles were seen in the right lower lobe bronchus. They were embedded in granulation tissue (GT). The particles were effectively

Table 1 FB Variables

Variable	N	%
Initial diagnosis		
FBA	3	50
PD	1	16.6
FBA and PD	2	33.3
Period of evaluation		
Less than 24 hours	0	0
More than 24 hours	6	100
Radiologic finding		
Unilateral hyperinflation	3	50
Atelectasis	1	16.6
Consolidation	1	16.6
Radiopaque FB	0	0
Normal	1	16.6
Location		
Trachea	0	0
Right side	4	66.6
Left side	1	16.6
Both sides	1	16.6
FB nature		
Organic	6	100
Inorganic	0	0

FB, foreign body; FBA, foreign body aspiration; PD, pulmonary disease.

removed by Dormia basket and the patient was discharged with good health condition on the same day (figure 1A).

Case 2

A 15-month-old boy was referred for a productive cough and noisy breathing intermittently lasting for 3 weeks. One week earlier, he visited a local hospital for these symptoms. He was subjected to RB due to choking while eating soup. Primary chest radiography revealed right-sided hyperinflation. The surgeon extracted a small chicken bone and his temporary symptoms improved. Nevertheless, a week later, similar symptoms developed and he was referred to our center. Chest auscultation indicated mild decrease in breath sounds and monophasic wheeze in the left lower lung. The patient was subjected to FFB, where near-total occlusion and left lower bronchus distortion with GT were found. Following suctioning and mechanical debulking of the formed GT using alligator forceps, another cartilage particle embedded in GT which was missed during the first procedure was detected (figure 1B). Two days later, he was discharged with normal health condition.

Case 3

A previously healthy boy aged 5 years was referred due to teeth aspiration and a choking episode. He had no symptoms on the first 2 days; however, severe cough spells

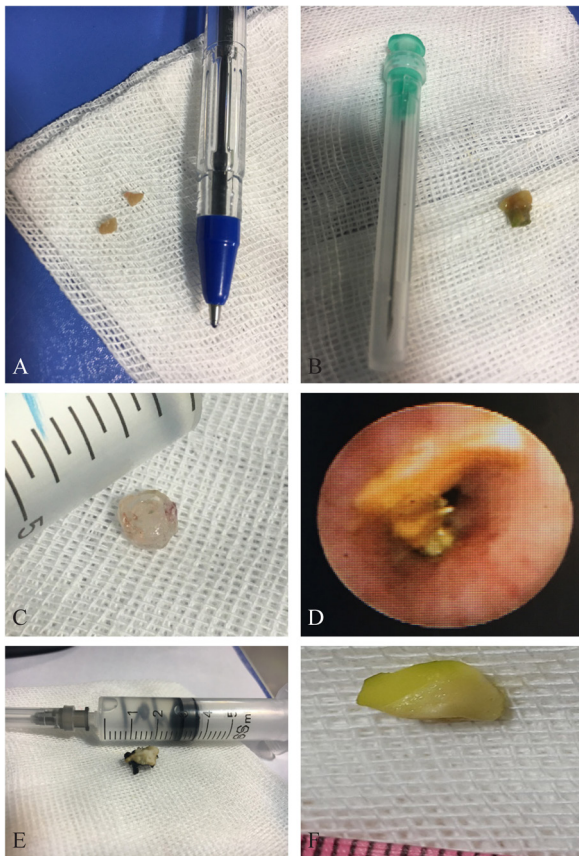


Figure 1 Extracted foreign bodies: (A) extracted two nut particles; (B) missed cartilage particle embedded in granulation tissue; (C) extracted teeth from the right lower lobe bronchus; (D) carrot particles; (E) extracted walnut from the right upper lobe; and (F) extracted pistachio from the right lower lobe subsegmental bronchus.

developed. Chest radiography showed right-sided hyperinflation. RB was performed in the OR under general anesthesia. Due to the firm nature of the object, RB failed to extract the FB and was pushed down to the lowest part of the right lower bronchus, which was far away from the usually accessible field of RB. FFB was performed, and by placing a Fogarty balloon catheter alongside the trapped FB and inflating the balloon behind the FB, the object was first pulled up to the right main bronchus and then removed using a Dormia basket (figure 1C).

Case 4

Following an episode of projectile vomiting, a 2-year-old boy with cerebral palsy and a history of stridor, hoarseness, and dyspnea for a week visited our hospital with complaints of fever, severe respiratory failure, cyanotic spells, and chest retraction. Intubation was done quickly and he was promptly transferred to the OR where RB was done. Carrot particles in the subglottis, trachea, and main bronchus were found. It was not easy to fully extract the particles. Thus, he was intubated again and transferred to the pediatric intensive care unit, but his ventilation remained poor. Chest CT scan showed bilateral infiltration and left bronchus stenosis. Accordingly,

FFB was scheduled and showed a considerable amount of mucosal secretion. After adequate suctioning, different friable raw vegetables were seen and were removed by cryoprobe (Erbe, Germany) under direct bronchoscopic vision (figure 1D).

Case 5

A 15-month-old boy with a previously healthy status was referred to our center with a history of episodic cough and cyanotic spells which started when his brother put a piece of walnut to his mouth 1 week before his admission. At the time of admission, he was febrile and tachypneic. His chest radiography showed right upper lung atelectasis. He was transferred to the OR and underwent RB, by which only copious thick secretion in his right main bronchus was detected. Although no FB was seen, the surgeon doubted as he could not investigate the whole length of the entire bronchus, which was out of range of the rigid bronchoscope. The patient's condition became unstable. The next day, FFB was done using a thin bronchoscope (External Diameter (ED) 2.8mm, Olympus Company, Japan) and showed FB in the right upper lobe bronchus, which was a piece of walnut. The FB was effectively removed by small forceps (1mm) (figure 1E).

Case 6

An 11-month-old girl with a previously healthy status was admitted to our hospital with complaints of cyanosis, dyspnea, and stridor for 1 month. Her parents gave a positive history of accidental choking after aspiration of a pistachio. Her chest X-ray was normal. According to the patient's history and symptoms, she was immediately taken to the OR where an emergency RB was done, which failed to demonstrate an FB. She was discharged and prescribed with medications including oral antibiotics and a bronchodilator with a metered-dose inhaler (salbutamol). Although her status became slightly better, she was admitted again after 2 weeks following recurrence and worsening of her primary symptoms. She was transferred to our center, where FFB was performed. FFB investigation showed a small FB (crunched pistachio) lodged in her right lower lobe subsegmental bronchus and significant GT formation. After FB extraction (figure 1F), the patient's symptoms significantly improved and she was discharged from the hospital on the same day.

DISCUSSION

FBA is a common condition in toddlers younger than 3 years and may be associated with severe complications.¹⁰ The diagnosis is challenging in most cases due to several factors, such as absence of specific signs, misdiagnosis, inadequate medical attention, wrong medical decisions, and reliance on imaging results.¹¹ FB removal using rigid bronchoscope under general anesthesia, developed by Gustav Killian, has been used as the gold standard to remove FBs.¹² Rigid bronchoscope has a large working

channel through which the airway can be effectively controlled. Rigid bronchoscope is also compatible with bigger and stronger forceps, which allow a better grip and debulking of GT formed over the FB. Moreover, rigid bronchoscope offers better hemostasis.

Zavala and Rhodes¹³ indicated the application of FFB for removing FB in artificial lungs and animal models. After this, FFB has been widely used for airway FB extraction and is now regarded as the first line in this field, especially in challenging patients.^{14–16} This type of bronchoscope can be used effectively in patients where FBs are impacted too distally, in patients with cervical trauma or instability, in patients with congenital oral or airway malformations, and in mechanically ventilated cases. While RB needs to be done under general anesthesia in the OR and is risky in some cases, FFB can be done under local anesthesia and intravenous sedation in the bronchoscopy suite,¹⁷ although rare cases may still need more invasive surgical interventions, such as thoracotomy and bronchotomy.^{18–20} Using bronchoscopy, FB visualization and extraction can be achieved simultaneously; however, FBs can be missed even with RB as the gold standard approach. These cases demonstrate that FFB can be used to remove FBs in the airways when RB fails. Considering cases 1, 5, and 6, the experience of the bronchoscopy physician and the correct use of equipment are essential for effective detection and retrieval of FBs. Compared with FFB, RB requires deep general anesthesia and sedation levels, which can quickly worsen the patient's condition and thus increase the operating time, making it difficult for the bronchoscopist to perform a successful operation. In case 2, the patient's unstable condition and the copious and thick secretions, mucosal edema and inflammations, bronchial narrowing, and bleeding from the surrounding GT formation alongside and around the aspirated FB may have contributed to FB being missed and increased the procedure's failure rate. Moreover, after retrieving the FB, it is highly recommended to conduct a secondary investigation for any remaining small particles.

The FB in case 2 was missed due to failure to consider a secondary investigation. Cases 1, 4, 5, and 6 had aspirated organic objects with friable texture, which are difficult to catch with ordinary forceps. The friable texture of the FB seems to be the leading cause of failure in performing RB on index cases. During RB, migration of the FB to distal locations is another cause of the failures observed in cases 3 and 6. As a standard method, the surgeon first inserts the RB barrel and connects the multifunction head. After connecting the anesthesia circulation, the optic lens and the light source are inserted. These steps may cause migration of the FB to the lowest part of the entire bronchus, where FB cannot be accessed by rigid bronchoscope. FFB is effective in patients whose FBs are impacted too distally to reach using rigid bronchoscope. The inability to bend the rigid bronchoscope is challenging due to the increased failure rate during FB removal, especially from the upper lobes and middle lobes.

In case 5, the FB had been missed due to this inability to investigate the right upper lobe. Also, inadequate hospital facilities and the lack of necessary instruments, including various sizes of rigid bronchoscopes, different types of optical forceps, Dormia baskets, Fogarty balloons, cryoprobes, electrocautery knives, and argon plasma coagulation, can lead to poor outcomes and RB failure.

In conclusion, advancements and acquisition of novel bronchoscope methods, such as high-definition optical systems, various types of optical forceps, and video bronchoscopes, can decrease the risk of missed FBs using bronchoscopy. However, the lack of advanced instrumentation in most centers can be considered a concern. The current research indicated that FFB is highly effective in preventing missed tracheobronchial FBs. The study also emphasized the importance of medical history in diagnosing airway FBs, even when normal RB is reported. FFB is a crucial and relatively safe diagnostic and therapeutic tool that needs to be done considering its advantages and disadvantages based on the patient's conditions. The choice of methods depends on the bronchoscopist's training, experience, and preferences, which should be considered according to specific circumstances of each case.

Contributors MAM contributed to conceptualization; writing - original draft; data curation; and writing - review and editing the manuscript. MAM acts as guarantor and accepts full responsibility for the work.

Funding The authors have not declared a specific grant for this research from any funding agency in the public, commercial or not-for-profit sectors.

Competing interests None declared.

Patient consent for publication Consent obtained directly from patient(s).

Ethics approval This retrospective pilot chart review study involves human participants and was performed in accordance with the Declaration of Helsinki. Written informed consent was obtained from all parents before the procedure under the authority of Namazi Hospital Institutional Board. Participants gave informed consent to participate in the study before taking part.

Provenance and peer review Not commissioned; externally peer reviewed.

Data availability statement Data sharing not applicable as no datasets generated and/or analyzed for this study. No data are available.

Open access This is an open access article distributed in accordance with the Creative Commons Attribution Non Commercial (CC BY-NC 4.0) license, which permits others to distribute, remix, adapt, build upon this work non-commercially, and license their derivative works on different terms, provided the original work is properly cited, appropriate credit is given, any changes made indicated, and the use is non-commercial. See: <http://creativecommons.org/licenses/by-nc/4.0/>.

ORCID iD

Mohammad Ashkan Moslehi <http://orcid.org/0000-0002-0019-586X>

REFERENCES

- Swanson KL, Prakash UBS, Midthun DE, *et al.* Flexible bronchoscopic management of airway foreign bodies in children. *Chest* 2002;121:1695–700.
- Golan-Tripto I, Mezan DW, Tsaregorodtsev S, *et al.* From rigid to flexible bronchoscopy: a tertiary center experience in removal of inhaled foreign bodies in children. *Eur J Pediatr* 2021;180:1443–50.
- Goussard P, Pohunek P, Eber E, *et al.* Pediatric bronchoscopy: recent advances and clinical challenges. *Expert Rev Respir Med* 2021;15:453–75.
- Moslehi MA. Foreign body retrieval by using flexible Cryoprobe in children. *J Bronchology Interv Pulmonol* 2021;28:103–6.
- Zhang L, Yin Y, Zhang J, *et al.* Removal of foreign bodies in children's airways using flexible bronchoscopic CO2 cryotherapy. *Pediatr Pulmonol* 2016;51:943–9.

- 6 Moslehi MA. Three-Centimeter chicken bone aspiration: the rare missed case. *J Indian Assoc Pediatr Surg* 2020;25:333–4.
- 7 Martinot A, Closset M, Marquette CH, *et al.* Indications for flexible versus rigid bronchoscopy in children with suspected foreign-body aspiration. *Am J Respir Crit Care Med* 1997;155:1676–9.
- 8 Prakash UB, Midthun DE, Edell ES. Indications for flexible versus rigid bronchoscopy in children with suspected foreign-body aspiration. *Am J Respir Crit Care Med* 1997;156:1017–9.
- 9 Simpson GT. Rigid vs. flexible bronchoscopy for foreign-body aspiration. *N Engl J Med* 1984;310:1190–1.
- 10 He S, Zuo Z-L. Different anatomical sites of the foreign body injury with 2999 children during 2012-2016. *Chin J Traumatol* 2018;21:333–7.
- 11 Huang Z, Liu D, Zhong J, *et al.* Delayed diagnosis and treatment of foreign body aspiration in China: the roles played by physician inexperience and lack of bronchoscopy facilities at local treatment centers. *Int J Pediatr Otorhinolaryngol* 2013;77:2019–22.
- 12 Killian G. Meeting of the Society of physicians of Freiburg. *Freiburg Munchen Med Wschr* 1897;45:378.
- 13 Zavala DC, Rhodes ML. Foreign body removal: a new role for the fiberoptic bronchoscope. *Ann Otol Rhinol Laryngol* 1975;84:650–6.
- 14 Kim K, Lee HJ, Yang EA, *et al.* Foreign body removal by flexible bronchoscopy using retrieval basket in children. *Ann Thorac Med* 2018;13:82–5.
- 15 Paradis T, Wollenberg M, Tieu B. Extraction of a large central airway foreign body using flexible bronchoscopy combined with an endobronchial blocker. *Case Rep Surg* 2016;2016:1–4.
- 16 Moslehi MA. A rare case of massive foreign body aspiration mimic asthma. *Respir Med Case Rep* 2019;28:100963.
- 17 Lan RS, Lee CH, Chiang YC, *et al.* Use of fiberoptic bronchoscopy to retrieve bronchial foreign bodies in adults. *Am Rev Respir Dis* 1989;140:1734–7.
- 18 Kiran S, Ahluwalia C, Chopra V, *et al.* Bronchotomy for removal of foreign body bronchus in an infant. *Indian J Anaesth* 2014;58:772–3.
- 19 Marks SC, Marsh BR, Dudgeon DL. Indications for open surgical removal of airway foreign bodies. *Ann Otol Rhinol Laryngol* 1993;102:690–4.
- 20 Chaudhry IUH, Eid HA, Cheema A, *et al.* Innovative surgical technique for removal of light emitting diode from segmental bronchus in a child: after the failure of endoscopic retrieval. *Int J Surg Case Rep* 2020;73:365–8.