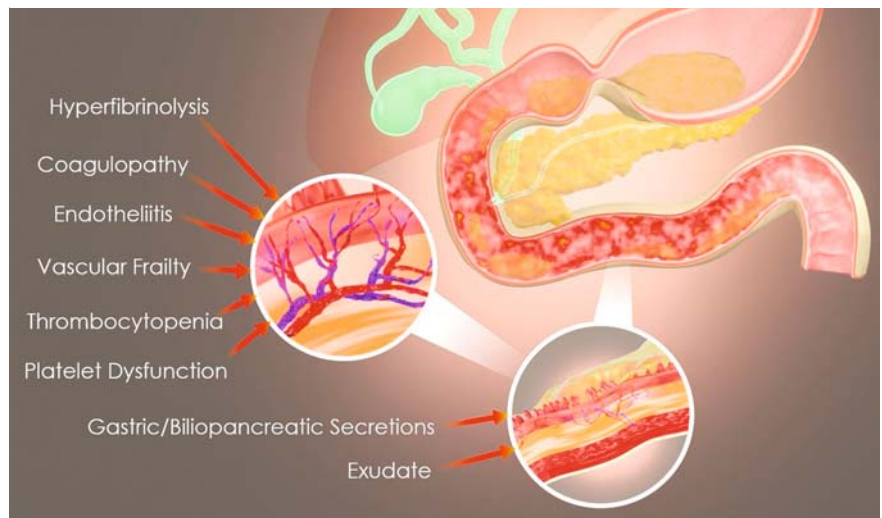


## Modified endoscopic vacuum therapy for duodenal hemorrhage in patients with severe acute respiratory syndrome coronavirus 2

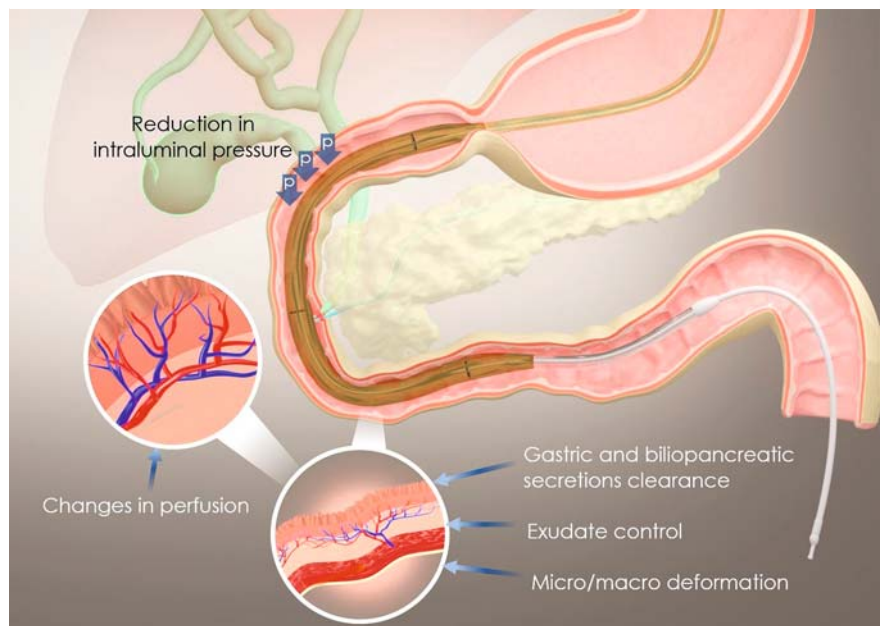
OPEN  
ACCESS

The use of extracorporeal membrane oxygenation is eventually needed in patients with severe acute respiratory syndrome coronavirus 2 (SARS-CoV-2) [1]. Hemorrhage is a frequent complication in these patients, including gastrointestinal bleeding, mainly caused by increased inflammatory state, hyperfibrinolysis, coagulopathy, platelet dysfunction, endotheliitis, anticoagulant use, thrombocytopenia, and the extracorporeal membrane oxygenation non-pulsatile blood flow [2,3]. The duodenum is the most affected organ, probably due to the higher exposure to biliopancreatic secretion associated with reduction in gastrointestinal motility and perfusion (► Fig. 1). In most cases, there is diffuse bleeding usually refractory to conventional endoscopic hemostatic therapies. Therefore, we present the first reports of a novel mechanism-based therapy for these critically ill patients. Such therapy is based on the use of endoscopic vacuum therapy that promotes deformation at the cytoskeletal level, exudate control, increased angiogenesis, and reduces aggressive mucosal factors such as gastric and biliopancreatic secretions [4,5]. Thus, it treats vascular fragility associated with endotheliitis that is associated with gastrointestinal bleeding in these patients (► Fig. 2). A modified endoscopic vacuum therapy using a triple-lumen tube to allow for nutrition and drainage with a single tube through the nares is used, as previously described (► Fig. 3, ► Fig. 4) [5].

Initial esophagogastroduodenoscopy (EGD) typically demonstrated duodenal villous atrophy associated with diffuse bleeding, including active ulcers and visible vessels, which were refractory to conventional endoscopic hemostatic therapies, including hemostatic powder. After endoscopic vacuum therapy placement, all patients were hemodynamically stable within 4–7 days, with no signs of gastrointestinal bleeding. Follow-up EGD



► Fig. 1 Pathophysiology of diffuse duodenal bleeding in patients with SARS-CoV-2 on extracorporeal membrane oxygenation support.

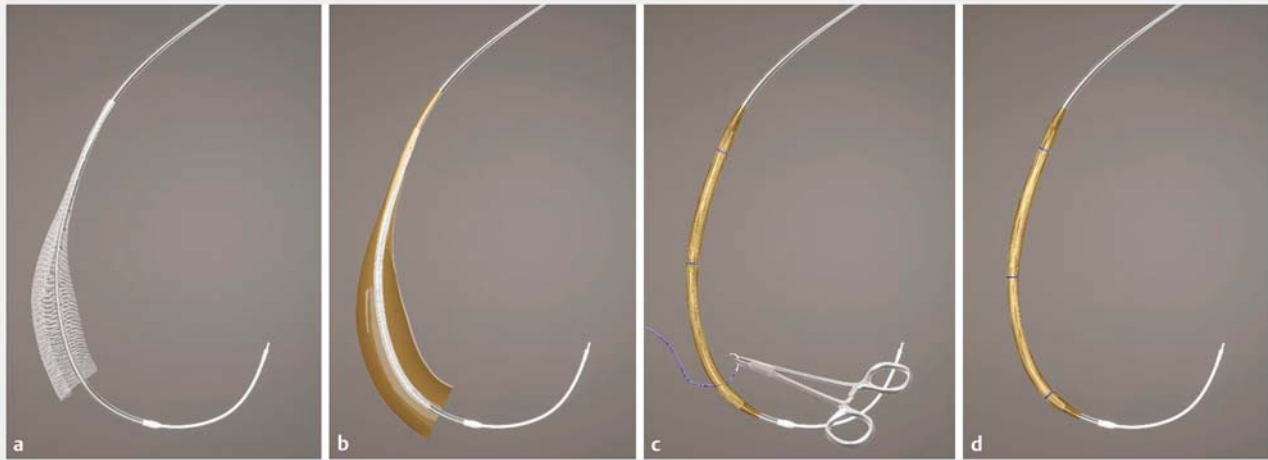


► Fig. 2 Mechanism of action of the modified endoscopic vacuum therapy for the treatment of diffuse gastrointestinal bleeding.

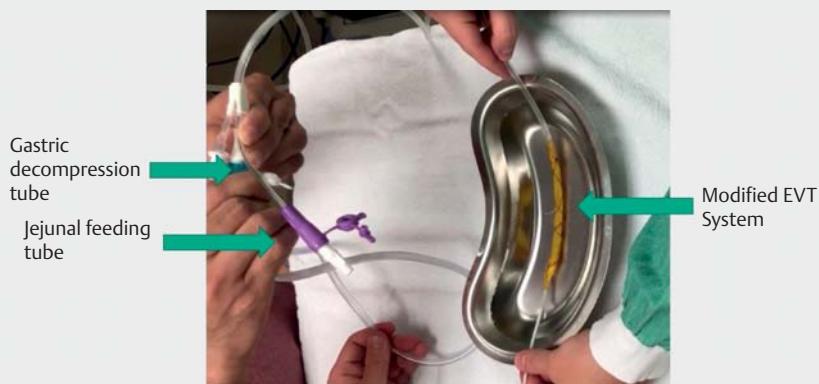demonstrated a completely healed mucosa with no signs of villous atrophy or bleeding (► Video 1).

In our experience, this technique is associated with high technical and clinical

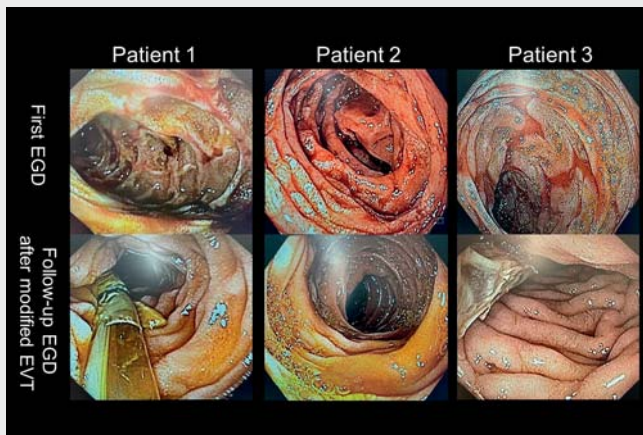
success rates, allowing early enteral nutrition, with no adverse events and a low rate of rebleeding after endoscopic vacuum therapy removal. After the successful use of this approach in refractory



► **Fig. 3** Modified endoscopic vacuum therapy: step-by-step process of manufacture. **a** Using ½-width gauze, wrap the fenestrated portion of the gastric decompression tube. **b** Use the antimicrobial incise drape to wrap the gauze around the gastric decompression tube. **c** Fix the modified sponge with sutures. **d** Use the 18G needle to make several holes in the antimicrobial incise drape – final appearance.



► **Fig. 4** Modified endoscopic vacuum therapy using a triple-lumen tube to allow for nutrition and drainage with a single device.



► **Video 1** Modified endoscopic vacuum therapy for the treatment of duodenal hemorrhage in critically ill patients: a simple approach for a complex condition.



cases, we no longer offer conventional endoscopic hemostatic therapies for patients with diffuse gastrointestinal bleeding associated with SARS-CoV-2 on extracorporeal membrane oxygenation, reducing the need for multiple endoscopic procedures and transfusions.

Endoscopy\_UCTN\_Code\_CPL\_1AH\_2AC

### Acknowledgments

We would like to thank all the multidisciplinary team at the Vila Nova Star Hospital, as well as the patients and their families who trusted in our proposed technique.

### Competing interests

The authors declare that they have no conflict of interest.

### The authors

**Diogo Turiani Hourneaux de Moura**<sup>1,2</sup>   
**Eduardo Guimarães Hourneaux de Moura**<sup>1,2</sup>   
**Bruno Salomão Hirsch**<sup>2</sup> **Gustavo L. Rodela Silva**<sup>1</sup>, **Stéphanie I. Rizk**<sup>1,3</sup>, **Paulo M. Hoff**<sup>1,4</sup>, **Ludhmila A. Hajjar**<sup>1,3</sup>

1 Instituto D'Or de Pesquisa e Ensino (IDOR), São Paulo, Brazil and Hospital Vila Nova Star, São Paulo, Brazil

2 Gastroenterology Department, Hospital das Clínicas da Faculdade de Medicina da Universidade de São Paulo, São Paulo, Brazil

- 3 Department of Cardiopneumology, Instituto do Coração, Hospital das Clínicas da Faculdade de Medicina da Universidade de São Paulo, São Paulo, Brazil
- 4 Oncology Department, Instituto do Câncer do Estado de São Paulo, Faculdade de Medicina da Universidade de São Paulo, São Paulo, Brazil

### Corresponding author

**Diogo T. H. de Moura, MD**

Hospital Vila Nova Star, Rua Dr. Alceu de Campos Rodrigues, 126, Vila Nova Conceição, 04544-000 São Paulo, SP, Brazil  
Fax: +55 11 2661-6467  
diogo.moura@vilanovastar.com.br

### References

- [1] Ramanathan K, Antognini D, Combes A et al. Planning and provision of ECMO services for severe ARDS during the COVID-19 pandemic and other outbreaks of emerging infectious diseases. *Lancet Respir Med* 2020; 8: 518–526
- [2] Yamada S, Ogawa H, Asakura H. Etiology and management of bleeding during ECMO in a COVID-19 patient. *J Atheroscler Thromb* 2021; 28: 402–403
- [3] Asakura H, Ogawa H. Overcoming bleeding events related to extracorporeal membrane oxygenation in COVID-19. *Lancet Respir Med* 2020; 8: e87–e88
- [4] Loske G, Schorsch T, Müller C. Intraluminal and intracavitary vacuum therapy for esophageal leakage: a new endoscopic minimally invasive approach. *Endoscopy* 2011; 43: 540–544
- [5] de Moura DTH, Hirsch BS, Boghossian MB et al. Low-cost modified endoscopic vacuum therapy using a triple-lumen tube allows nutrition and drainage for treatment of an early post-bariatric surgery leak. *Endoscopy* 2021. doi:10.1055/a-1540-5870 [Epub ahead of print]

### Bibliography

*Endoscopy* 2022; 54: E837–E839

DOI 10.1055/a-1803-4445

ISSN 0013-726X

published online 13.5.2022

© 2022. The Author(s).

This is an open access article published by Thieme under the terms of the Creative Commons Attribution-NonDerivative-NonCommercial License, permitting copying and reproduction so long as the original work is given appropriate credit. Contents may not be used for commercial purposes, or adapted, remixed, transformed or built upon. (<https://creativecommons.org/licenses/by-nc-nd/4.0/>)

Georg Thieme Verlag KG, Rüdigerstraße 14, 70469 Stuttgart, Germany



### ENDOSCOPY E-VIDEOS

<https://eref.thieme.de/e-videos>



*Endoscopy E-Videos* is an open access online section, reporting on interesting cases and new techniques in gastroenterological endoscopy. All papers include a high quality video and all contributions are freely accessible online. Processing charges apply (currently EUR 375), discounts and waivers acc. to HINARI are available.

This section has its own submission website at

<https://mc.manuscriptcentral.com/e-videos>