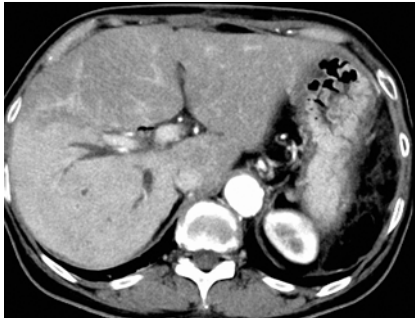


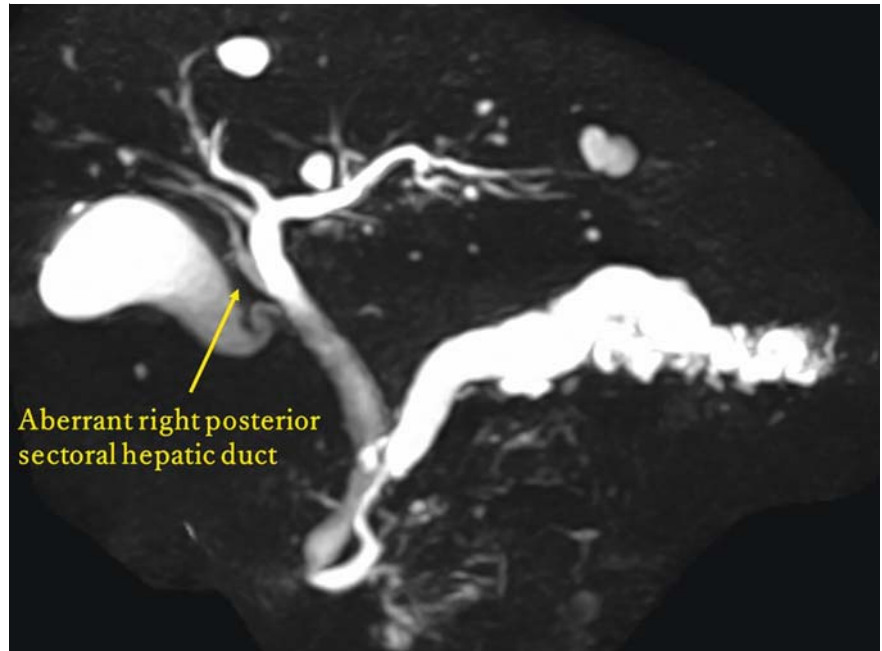
Endoscopic ultrasound-guided hepaticojejunostomy using forward-viewing echoendoscope for transected aberrant right posterior hepatic duct in Roux-en-Y hepaticojejunostomy



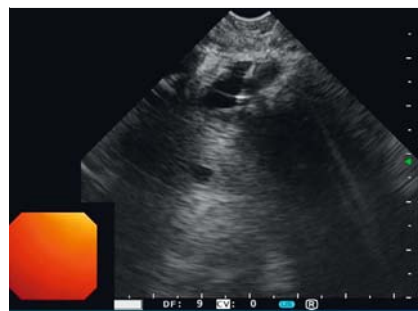► **Fig. 1** Computed tomography image shows the dilated right posterior sectoral hepatic duct and small abscesses in the area.

An aberrant right posterior hepatic duct is one of the most common risk factors for bile duct injury during surgical procedures. Complete transection of the bile duct necessitates surgical repair. Recently, endoscopic ultrasound (EUS)-guided hepaticojejunostomy using a forward-viewing echoendoscope to manage complete biliary obstruction in patients with surgically altered anatomy has been reported [1–4]. Although most of the reports described complete stenosis of hepaticojejunostomy anastomoses with pancreaticoduodenectomy and modified Child reconstruction, none has documented repairing a completely transected bile duct with Roux-en-Y hepaticojejunostomy.

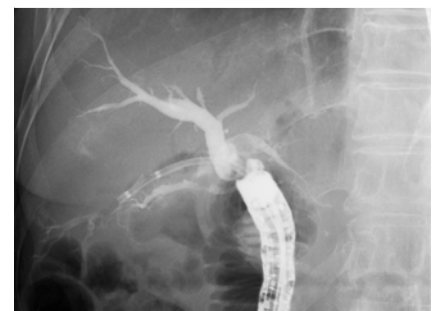A 72-year-old woman who underwent total pancreatectomy with Roux-en-Y hepaticojejunostomy for intraductal papillary mucinous carcinoma 2 months prior presented with abdominal pain. Abdominal computed tomography showed dilatation of the right posterior hepatic duct and small abscesses (► **Fig. 1**). A retrospective imaging review of the patient's preoperative magnetic resonance images revealed an aberrant right posterior hepatic duct (► **Fig. 2**). Complete transection and ligation of the aberrant duct during the previous operation were



► **Fig. 2** Preoperative magnetic resonance cholangiopancreatography showed an aberrant right posterior hepatic duct.



► **Fig. 3** Endoscopic ultrasound image: The completely transected right posterior hepatic duct was punctured using a forward-viewing echoendoscope.

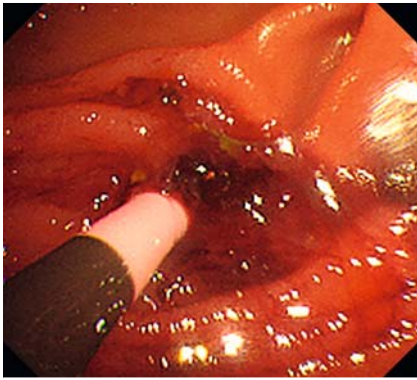


► **Fig. 4** Fluoroscopic image shows plastic stent placement into the completely transected right posterior hepatic duct using a forward-viewing echoendoscope.

suspected (Strasberg classification type B) [5].

We considered performing an EUS-guided hepaticojejunostomy using the forward-viewing echoendoscope (TGF-UC260J; Olympus Medical Systems, Tokyo, Japan). However, we assumed

that insertion into the bilioenteric limb around the anastomosis would be challenging owing to the Roux-en-Y reconstruction; thus, we initially performed balloon enteroscopy (SIF-290H; Olympus Medical Systems, Tokyo, Japan) to confirm the direction of the anastomosis.



► **Fig. 5** Endoscopic image shows plastic stent placement into the completely transected right posterior hepatic duct using a forward-viewing echoendoscope.




Upon reaching the anastomosis, a nasobiliary drainage tube was placed into the bilioenteric limb. The forward-viewing echoendoscope was then successfully advanced into the hepaticojejunostomy anastomosis with tube guidance. Subsequently, the dilated right posterior hepatic duct was punctured with a 19-gauge needle, and a 0.025 guidewire was introduced into the bile duct. The puncture site was dilated with a mechanical dilator (ES dilator; Zeon Medical, Tokyo, Japan) and a plastic stent was placed (SUZAKU; Kaneka Medix, Osaka, Japan) (► **Fig. 3**, ► **Fig. 4**, ► **Fig. 5**, ► **Video 1**). The patient immediately recovered and was promptly discharged 4 days after the procedure.

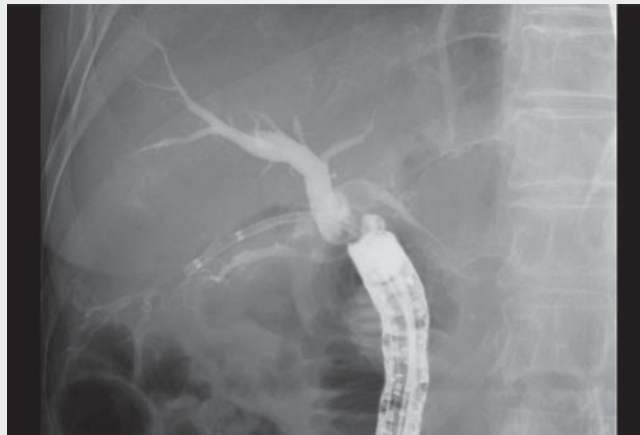Endoscopy_UCTN_Code_CPL_1AL_2AD

Competing interests

The authors declare that they have no conflict of interest.

The authors

Kazuya Koizumi  **Sakue Masuda**  **Kento Shionoya**  **Makomo Makazu**
Gastroenterology Medicine Center, Shonan Kamakura General Hospital, Kamakura, Kanagawa, Japan



► **Video 1** Endoscopic ultrasound-guided hepaticojejunostomy for completely transected aberrant right posterior sectoral duct in a patient with total pancreatectomy and Roux-en-Y hepaticojejunostomy successfully performed using a forward-viewing echoendoscope.

Corresponding author

Kazuya Koizumi, MD
Gastroenterology Medicine Center, Shonan Kamakura General Hospital, 1370-1 Okamoto, Kamakura, Kanagawa 247-8533, Japan
Fax: +81-467-45-0190
kizm2010@gmail.com

References

- [1] Kida M, Yamauchi H, Okuwaki K et al. Endoscopic ultrasound-guided cholechojejunostomy with a forward-viewing echoendoscope for severe benign bilioenteric stricture in a patient with Child's resection. *Endoscopy* 2015; 47: E303–E304
- [2] Iwai T, Kida M, Yamauchi H et al. EUS-guided transanastomotic drainage for severe bilio-pancreatic anastomotic stricture using a forward-viewing echoendoscope in patients with surgically altered anatomy. *Endosc Ultrasound* 2021; 10: 33–38
- [3] Ishiwatari H, Sato J, Kaneko J. Hepaticojejunostomy for the right hepatic bile duct using a forward-viewing echoendoscope in a patient after pancreatoduodenectomy. *Dig Endosc* 2019; 31: e82–e83
- [4] Okamoto T, Nakamura K, Yabuta M et al. Retrograde endosonography-guided hepaticojejunostomy after failed rendezvous in a patient with Child's resection. *Endoscopy* 2022; 54: E131–E132
- [5] Strasberg SM, Hertl M, Soper NJ. An analysis of the problem of biliary injury during laparoscopic cholecystectomy. *J Am Coll Surg* 1995; 180: 101–125

Bibliography

Endoscopy 2022; 54: E933–E934
DOI 10.1055/a-1881-4068
ISSN 0013-726X
published online 14.7.2022
© 2022. The Author(s).

This is an open access article published by Thieme under the terms of the Creative Commons Attribution-NonDerivative-NonCommercial License, permitting copying and reproduction so long as the original work is given appropriate credit. Contents may not be used for commercial purposes, or adapted, remixed, transformed or built upon. (<https://creativecommons.org/licenses/by-nc-nd/4.0/>)

Georg Thieme Verlag KG, Rüdigerstraße 14, 70469 Stuttgart, Germany



ENDOSCOPY E-VIDEOS
<https://eref.thieme.de/e-videos>



Endoscopy E-Videos is an open access online section, reporting on interesting cases

and new techniques in gastroenterological endoscopy. All papers include a high quality video and all contributions are freely accessible online. Processing charges apply (currently EUR 375), discounts and waivers acc. to HINARI are available.

This section has its own submission website at

<https://mc.manuscriptcentral.com/e-videos>