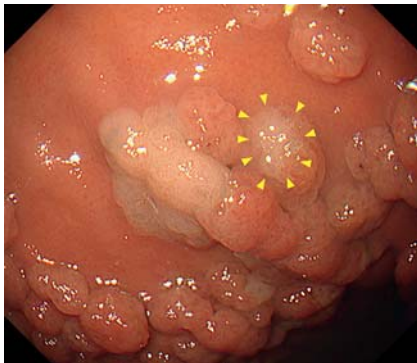


Gel immersion endoscopic mucosal resection for a gastric neoplasm with a background of fundic gland polyposis

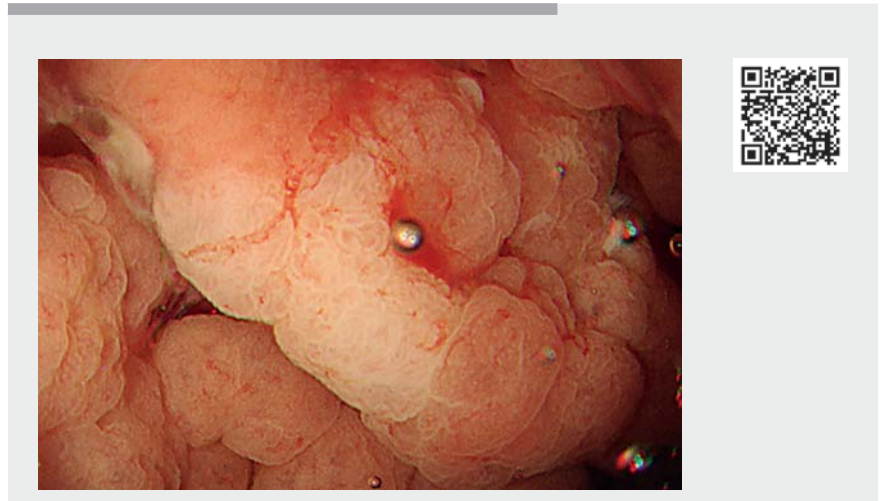
OPEN
ACCESS



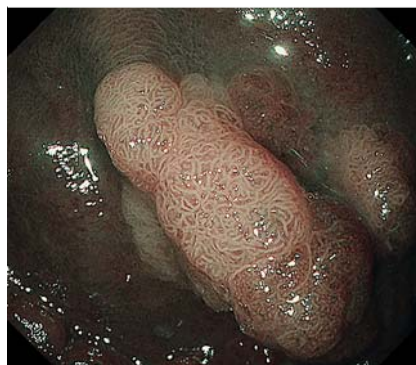► **Fig. 1** Esophagogastroduodenoscopy shows a 15-mm whitish flat elevated lesion located at the greater curvature of the upper gastric body with fundic gland polyposis. Near the lesion, a 5-mm whitish lesion was also seen (arrowhead).

Endoscopic submucosal dissection for a gastric neoplasm at the greater curvature of the upper gastric body with polyposis is challenging because of the ease of submersion in water, difficult mucosal incision due to background polyposis, and frequent bleeding during incision. Alternatively, conventional endoscopic mucosal resection (EMR) is a simple and convenient resection method. However, frequent piecemeal resection is concerning [1]. Here, we demonstrate gel immersion EMR for the aforementioned lesion.

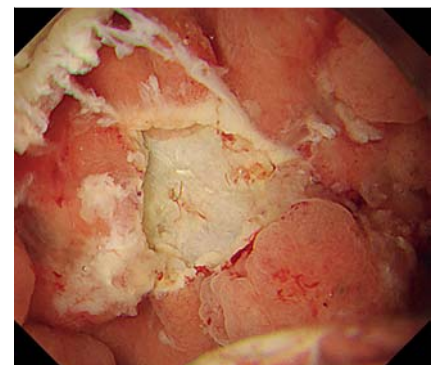
A 42-year-old woman with Gardner syndrome underwent esophagogastroduodenoscopy, showing 15-mm and 5-mm whitish flat elevated lesions at the greater curvature of the upper gastric body with fundic gland polyposis (► **Fig. 1**). Endoscopy with narrow-band imaging showed a regular surface pattern, suggesting gastric adenoma (► **Fig. 2**), which was confirmed by biopsies. As these were non-invasive neoplasms, it was not necessary to dissect just above the muscle layer. We decided to perform EMR using not water but Viscoclear (Otsuka Pharmaceutical Factory, Tokushima, Japan), to promptly deal with in-



► **Video 1** Esophagogastroduodenoscopy shows a whitish flat elevated lesion at the greater curvature of the upper gastric body with fundic gland polyposis. This was successfully removed by gel immersion endoscopic mucosal resection.



► **Fig. 2** Endoscopy with narrow-band imaging shows a regular surface pattern, which suggested gastric adenoma.

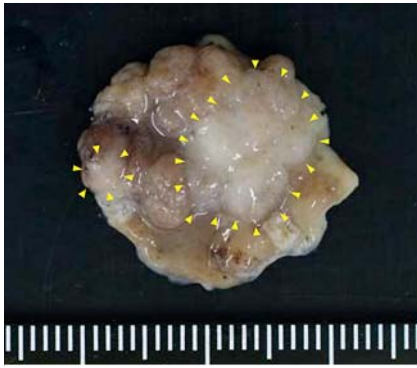


► **Fig. 3** En bloc resection was achieved.

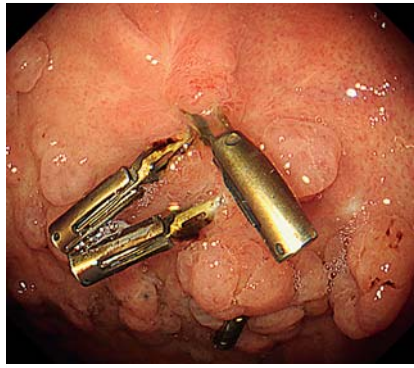
traprocedural bleeding (► **Video 1**). After marking around the lesion, the gel was injected into the stomach. While maintaining the snare tip in the gastric wall, we captured the lesion and achieved en bloc resection (cut mode) without complications (► **Fig. 3**, ► **Fig. 4**). Pathological examination revealed gastric adenomas. The esophagogastroduodenoscopy performed 3 months later showed no residual tumor at the post-EMR ulcer scar

(► **Fig. 5**), which was confirmed by biopsies.

The efficacy of gel immersion EMR has been reported mainly in the duodenum and colon [2–4]. This method has also been used for gastric cancer near the pyloric ring, where it is difficult to submerge in water and the workspace is narrow [5]. Additionally, gel immersion EMR may also be useful for a gastric neoplasm at the greater curvature of the upper gastric body with polyposis.



► **Fig. 4** Resected specimen. Both lesions were seen (arrowhead).



► **Fig. 5** No residual tumor at post-endoscopic mucosal resection ulcer scar in follow-up endoscopy 3 months later.

Endoscopy_UCTN_Code_CCL_1AB_2AD_3AB

Competing interests

The authors declare that they have no conflict of interest.

The authors

Hidegori Kimura¹, **Masayuki Oi²**, **Yukihiro Morita²**, **Shigeki Bamba¹**, **Osamu Inatomi²**, **Akira Andoh²**

- 1 Division of Digestive Endoscopy, Department of Medicine, Shiga University of Medical Science, Shiga, Japan
- 2 Division of Gastroenterology, Department of Medicine, Shiga University of Medical Science, Shiga, Japan

Corresponding author

Hidegori Kimura, MD

Division of Digestive Endoscopy,
Department of Medicine, Shiga University
of Medical Science, Seta Tsukinowa, Otsu,
520-2192, Japan
Fax: +81-77-548-2219
hidenori.kim.6416@gmail.com

References

- [1] Oda I, Saito D, Tada M et al. A multicenter retrospective study of endoscopic resection for early gastric cancer. *Gastric Cancer* 2006; 9: 262–270
- [2] Yachida T, Kobara H, Tada N et al. Endoscopic mucosal resection under gel immersion for superficial nonampullary duodenal epithelial neoplasms. *Endoscopy* 2021. doi:10.1055/a-1544-7810
- [3] Kuwabara H, Chiba H, Tachikawa J et al. Efficacy of under-gel endoscopic mucosal resection method for colonic lesion extending into the diverticulum. *Endoscopy* 2022; 54: E292–E293
- [4] Takada K, Hotta K, Imai K. Gel immersion endoscopic mucosal resection with acetic acid spray for sessile serrated lesion extending close to the appendiceal orifice. *Digestive Endoscopy* 2022; 34: e115–e116. doi:10.1111/den.14343
- [5] Miura K, Sudo G, Saito M et al. Gel immersion endoscopic mucosal resection for early gastric cancer near the pyloric ring. *Endoscopy* 2022. doi:10.1055/a-1730-4674

Bibliography

Endoscopy 2022; 54: E1011–E1012

DOI 10.1055/a-1903-1528

ISSN 0013-726X

published online 24.8.2022

© 2022. The Author(s).

This is an open access article published by Thieme under the terms of the Creative Commons Attribution-NonDerivative-NonCommercial License, permitting copying and reproduction so long as the original work is given appropriate credit. Contents may not be used for commercial purposes, or adapted, remixed, transformed or built upon. (<https://creativecommons.org/licenses/by-nc-nd/4.0/>)

Georg Thieme Verlag KG, Rüdigerstraße 14,
70469 Stuttgart, Germany



ENDOSCOPY E-VIDEOS

<https://eref.thieme.de/e-videos>



Endoscopy E-Videos is an open access online section, reporting on interesting cases

and new techniques in gastroenterological endoscopy. All papers include a high quality video and all contributions are freely accessible online. Processing charges apply (currently EUR 375), discounts and waivers acc. to HINARI are available.

This section has its own submission website at

<https://mc.manuscriptcentral.com/e-videos>