

Endoscopic submucosal dissection in the colon using a novel adjustable traction device: A-TRACT-2

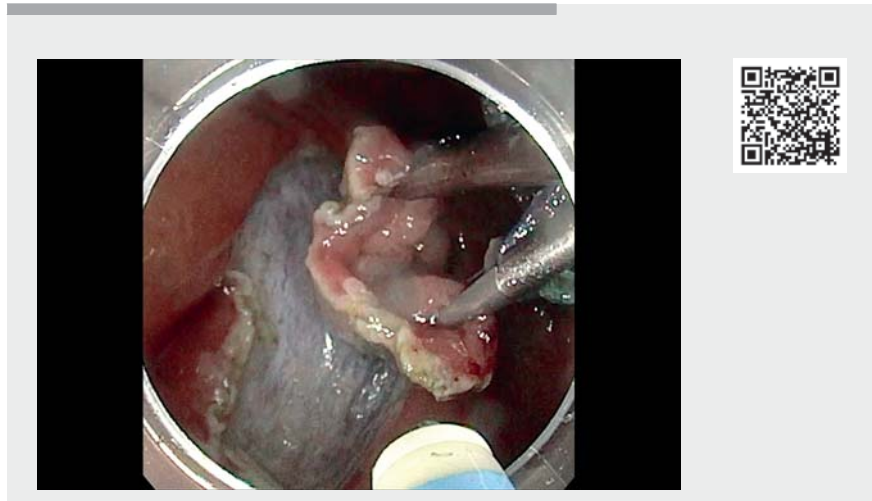


A major barrier to expansion of endoscopic submucosal dissection (ESD) remains the technical difficulty of the procedure. Thus, several devices and techniques have been described to ease this procedure [1], but all have their limitations, the main one being that they provide only a fixed amount of traction that tends to decline as the dissection advances [2]. However, we think that the ideal traction would be soft at the beginning of the procedure so as not to rip the clips of the lesion, intermediate as the dissection advances, and hard at the end to facilitate the cutting of the last fibers, often the trickiest part of the procedure.

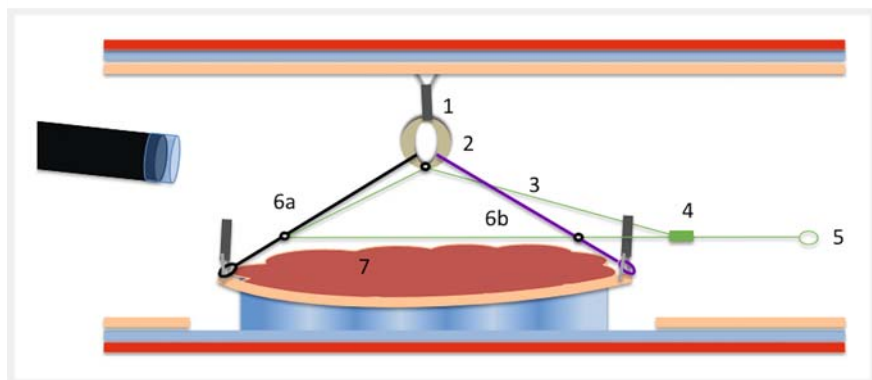
We describe the use of a new traction device (A-TRACT-2) that is both easy to use and adjustable, providing growing traction and continuous easy access to the submucosa during ESD (► **Video 1**).

We report here the case of a 69-year-old patient with a 3-cm laterally spreading granular tumor of the cecum. The first step of the procedure was making a peripheral incision. We then fixed the device with clips to the upper and lower edges of the lesion. Afterward, we used another clip to attach the rubber band to the opposite wall (► **Fig. 1**). Initial traction was obtained, and dissection started. After 1/4 of the lesion was cut, traction began to decline (► **Fig. 2**), and we tightened the device to bring both the anchoring points of the device closer to the traction point between them and to the rubber band in order to reestablish optimal traction (► **Fig. 3**). The submucosal exposure was ideal through the end of the procedure (► **Fig. 4**). This technique allowed a curative R0 resection of the lesion.

To our knowledge, this is the first time that an adjustable traction system has been used in humans. This technique seems attractive, especially in difficult locations. Further studies are needed to confirm its effectiveness.



► **Video 1** Dissection in the cecum using the new A-TRACT-2 traction device.



► **Fig. 1** Initial traction. **1** Endoscopic clip. **2** Rubber band. **3** Tightening wire. **4** One-way slip knot. **5** Tightening loop. **6a** Anterior traction wire. **6b** Posterior traction wire. **7** Laterally spreading tumor.

Endoscopy_UCTN_Code_TTT_1AQ_2AD

Competing interests

The authors declare that they have no conflict of interest.

The authors

Louis-Jean Masgnaux¹, Jean Grimaldi¹, Romain Legros², Jérôme Rivory¹, Timothée Wallenhorst³, Jérémie Jacques², Mathieu Pioche¹

- 1 Gastroenterology and Endoscopy Unit, Edouard Herriot Hospital, Hospices Civils de Lyon, Lyon, France
- 2 Gastroenterology and Endoscopy Unit, Dupuytren University Hospital, Limoges, France

Corresponding author

Mathieu Pioche, MD

Endoscopy Unit, Department of Digestive
Diseases, Pavillon L – Edouard Herriot
Hospital, 69437 Lyon Cedex, France
mathieu.pioche@chu-lyon.fr

References

- [1] Lafeuille P, Rivory J, Jacques J et al. Diagnostic endoscopic submucosal dissection for invasive cancer with the four cardinal points traction strategy. *Endoscopy* 2022; 54: E281–E282. doi:10.1055/a-1516-3680
- [2] Bordillon P, Pioche M, Wallenhorst T et al. Double-clip traction for colonic endoscopic submucosal dissection: a multicenter study of 599 consecutive cases (with video). *Gastrointest Endosc* 2021; 94: 333–343. doi:10.1016/j.gie.2021.01.036

Bibliography

Endoscopy 2022; 54: E988–E989

DOI 10.1055/a-1888-3963

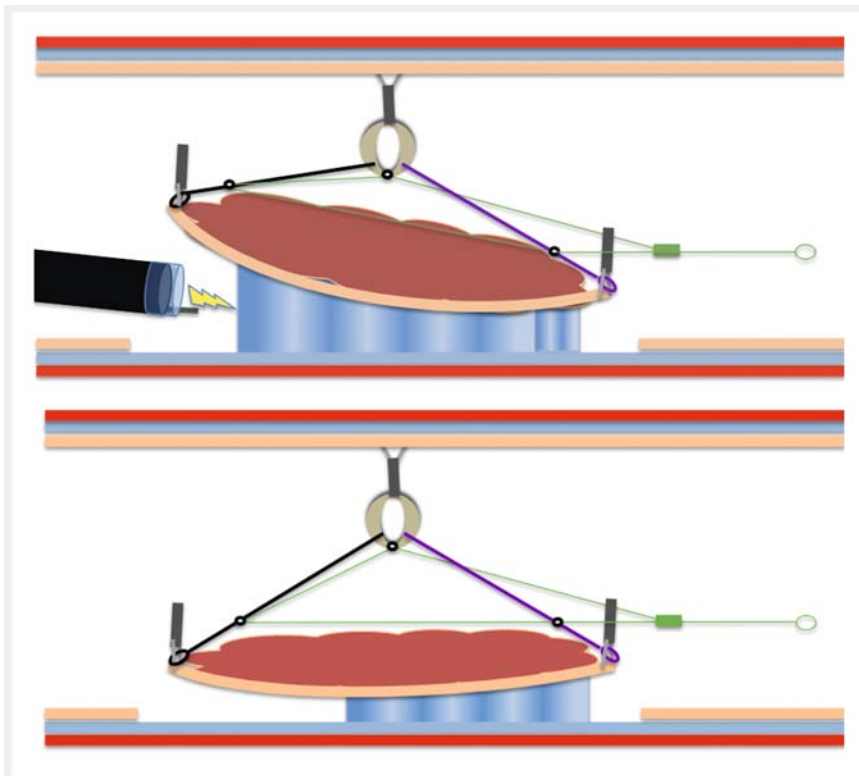
ISSN 0013-726X

published online 4.8.2022

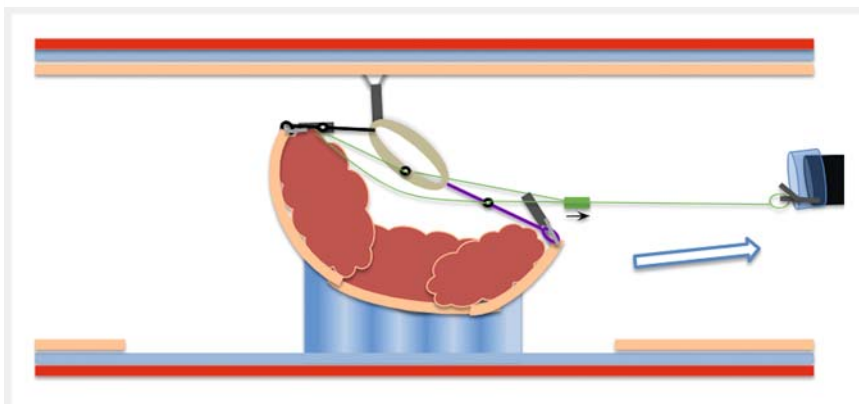
© 2022. The Author(s).

This is an open access article published by Thieme under the terms of the Creative Commons Attribution-NonDerivative-NonCommercial License, permitting copying and reproduction so long as the original work is given appropriate credit. Contents may not be used for commercial purposes, or adapted, remixed, transformed or built upon. (<https://creativecommons.org/licenses/by-nc-nd/4.0/>)

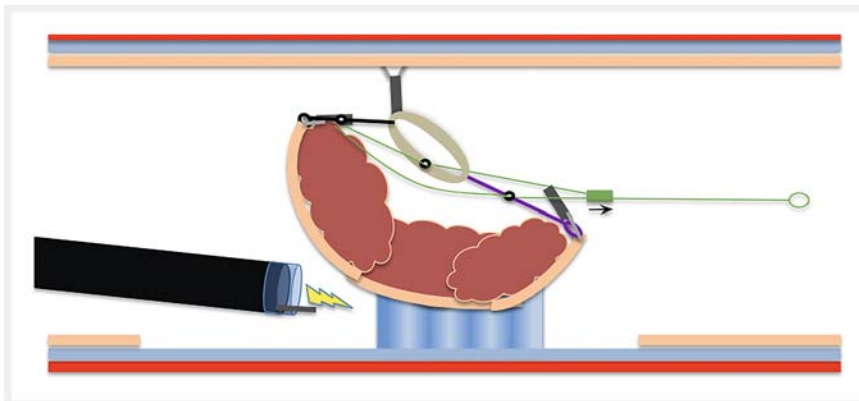
Georg Thieme Verlag KG, Rüdigerstraße 14,
70469 Stuttgart, Germany



► **Fig. 2** Dissection starts, and traction begins to decline.



► **Fig. 3** Tightening of the device in order to reestablish optimal traction.



► **Fig. 4** Ideal traction is obtained through the end of procedure.