









Vulvar Reconstruction Using Keystone Flaps Based on the Perforators of Three Arteries

Yunjae Lee, MD¹  Sanghun Lee, MD¹  Dongkyu Lee, MD¹  Hyeonjung Yeo, MD¹ 
Hannara Park, MD¹  Hyochun Park, MD, PhD¹ 

¹Department of Plastic and Reconstructive Surgery, Daegu Fatima Hospital, Daegu, Republic of Korea

Arch Plast Surg 2022;49:724–728.

Address for correspondence Hyochun Park, MD, PhD, Department of Plastic and Reconstructive Surgery, Daegu Fatima Hospital, 99 Ayang-ro, Dong-gu, Daegu 41199, Republic of Korea (e-mail: phc3900@hanmail.net).

Abstract

Various flaps are used to reconstruct skin and soft tissue defects of the vulva following resection of malignancies. Whenever possible, reconstruction using local flaps is the standard treatment. Here, we describe vulvar defect reconstruction using keystone flaps. Standard keystone flaps are based on randomly located vascular perforators. However, we designed a keystone flap that includes perforators of three named arteries (the anterior labial artery of the external pudendal artery, cutaneous branches of the obturator artery, and posterior labial artery of the internal pudendal artery) and the pudendal nerve, which accompanies the internal pudendal artery. Four patients with squamous cell carcinoma and extramammary Paget's disease of the vulva underwent radical vulvectomy and keystone flaps including perforators of three arteries. Depending on the morphology of the defects, keystone flaps were used with different designs. For elliptical and unilateral vulvar defects, a standard keystone flap was designed, and for defects on both sides of the vulva, a double opposing keystone flap was used. For oval defects, the omega variant keystone flap was designed, and when the morphology of the defect needed rotation of the flap, a rotational keystone flap was designed. All the patients showed good function and sensation, with an acceptable cosmetic appearance.

Keywords

- ▶ surgical procedures
- ▶ local flap
- ▶ artery
- ▶ perineum
- ▶ vulva

Introduction

Vulvar reconstruction after radical vulvectomy is challenging. To achieve the best outcome, functions such as intercourse, micturition, and defecation should remain normal and a good cosmetic appearance needs to be maintained. Various flap surgeries are used for vulvar reconstruction, including the gracilis, gluteal fold, medial thigh, vertical rectus abdominis myocutaneous, and pudendal thigh flaps.^{1–3} Among the flaps presented above, flaps based on the internal pudendal artery, such as the pudendal thigh flap

and the gluteal fold V-Y advancement flap, have the advantage of becoming a sensate flap because the pudendal nerve accompanies the internal pudendal artery.^{2,3}

Several musculocutaneous flaps have been introduced for vulvar reconstruction; however, these flaps are usually very bulky and do not provide the best result after standard vulvectomy. Since local flaps are thin and pliable, standard treatments should include local flaps after radical vulvectomy, if possible.⁴

Flaps that can be used are limited depending on the location and size of the vulvar defect. However, the keystone

received
November 23, 2021
accepted after revision
January 21, 2022

DOI <https://doi.org/10.1055/s-0042-1756294>.
eISSN 2234-6171.

© 2022. The Korean Society of Plastic and Reconstructive Surgeons. All rights reserved.

This is an open access article published by Thieme under the terms of the Creative Commons Attribution-NonDerivative-NonCommercial-License, permitting copying and reproduction so long as the original work is given appropriate credit. Contents may not be used for commercial purposes, or adapted, remixed, transformed or built upon. (<https://creativecommons.org/licenses/by-nc-nd/4.0/>)

Thieme Medical Publishers, Inc., 333 Seventh Avenue, 18th Floor, New York, NY 10001, USA

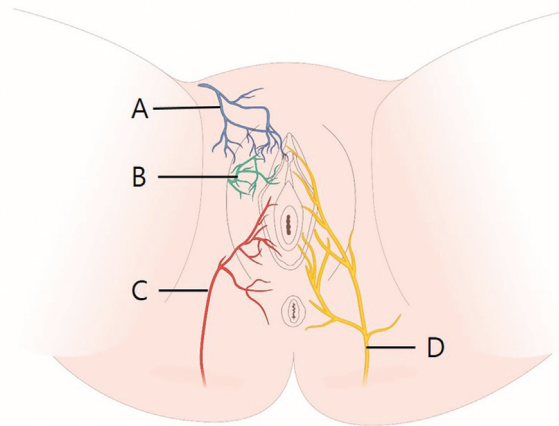


Fig. 1 Distribution of the arteries and pudendal nerves around the vulva and perineum. (A) Anterior labial artery of the external pudendal artery. (B) Cutaneous branches of the obturator artery. (C) Posterior labial artery of the internal pudendal artery. (D) Pudendal nerve.

flap introduced by Behan in 2003 has no limitation in terms of designing flaps for any location and size of defects.⁵ Moreover, the success rate of this technique is not strongly impacted by the skill of the surgeon, and this technique rarely leads to major complications, such as total or partial flap loss.⁶ While the standard keystone flap was designed to reconstruct elliptical defects, there are various modifications in its use depending on the size and morphology of the defect.⁷

The conventional keystone flap introduced by Behan is based on randomly located vascular perforators, whereas the techniques described in our study used Doppler ultrasonography to include named perforators (the anterior labial artery of the external pudendal artery, the cutaneous branches of the obturator artery, and the posterior labial artery of the internal pudendal artery) in the flap to create a reliable flap (► Fig. 1).⁵ Moreover, we made a flap wider than the standard keystone flap, resulting in a more reliable and redundant flap. This enabled us to achieve a better morphology of the labium major with extra skin. Here, we report four successful reconstruction cases of vulvar cancer after radical vulvectomy in terms of functional and cosmetic aspects.

Case

An 83-year-old female patient was diagnosed with bilateral squamous cell carcinoma of the vulva. After bilateral inguino-femoral lymphadenectomy of the vulva, a radical wide excision on the right side and partial wide excision on the left side were performed in the gynecology department. The combined defect measured 4.5×10.0 cm. A 5.0-cm wide standard keystone flap and one-arm keystone flap were designed for both the right and left sides of the vulva, respectively. However, the defect was fully covered by the standard keystone flap on the right side alone. The patient was discharged at 27 days after surgery without complications; the patient was satisfied with the esthetic and functional outcomes of the vulvar reconstruction at 6 months postoperatively.

A 64-year-old female patient had bilateral squamous cell carcinoma of the vulva and several lymph adenopathies on both the inguinal areas. Under general anesthesia, the patient was placed on the operative table in a lithotomy position.

After lymphadenectomy of both inguino-femoral lymph nodes in the department of surgery, an excision margin was designed. Perforators of the anterior labial artery of the external pudendal artery, two cutaneous branches of the obturator artery, and the posterior labial artery of the internal pudendal artery on both sides of the vulva (► Fig. 1) were located and marked using Doppler ultrasonography. The standard keystone flap was then designed on both sides of the vulva.

After radical wide excision of vulvar cancer, a 5.5×8.5 -cm defect was noted. Keystone flaps were designed for both sides of the vulva and were 5.5 cm in width, which was the same as the width of the defect (► Fig. 2).

After an incision, the deep fascia was carefully divided and the border of the flap was undermined 1 cm upward from the deep fascia. This was followed by blunt dissection of the tissue and preservation of the neurovascular structures.

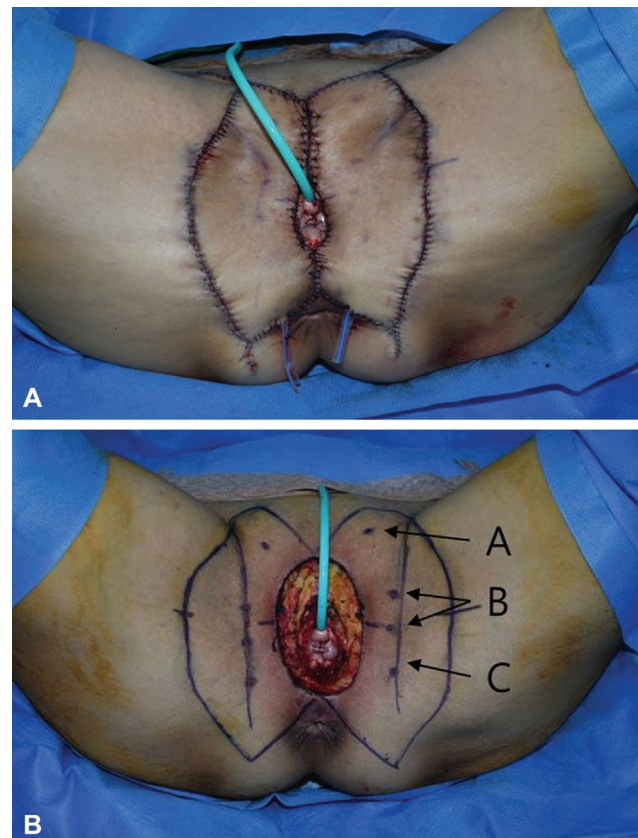


Fig. 2 Case 2: Double opposing keystone flap. (A) After radical wide excision of squamous cell carcinoma. The resultant defect measured 5.5×8.5 cm. Perforators identified using Doppler ultrasonography, and perforator of three arteries based on double opposing keystone flaps was designed. The flap width was 5.5 cm, equal to the defect size, and was designed on both sides. (A, anterior labial artery of the external pudendal artery, B, cutaneous branches of the obturator artery, C, posterior labial artery of the internal pudendal artery). (B) Immediate postoperative photograph.

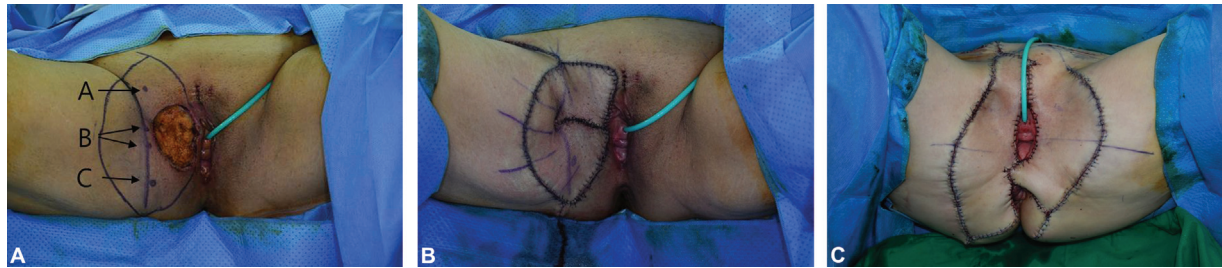

Fig. 3 Case 3: Omega variant keystone flap. (A) After radical wide excision of extramammary Paget's disease. The resultant defect measured 4.7×7.0 cm. An omega variant keystone flap was designed. The flap width was 6.7 cm (A, anterior labial artery of the external pudendal artery, B, cutaneous branches of the obturator artery, and C, posterior labial artery of the internal pudendal artery). (B) Immediate postoperative photography. (C) Recovery without complications at 994 days after keystone flap reconstruction.

After securing enough redundancy to make the labium major, the flap was sutured layer by layer (►Fig. 2). At 26 months postoperatively, the patient had no problems in functions, such as micturition, defecation, walking, and sitting and had a good cosmetic appearance of the vulva.

A 74-year-old female patient was diagnosed with extramammary Paget's disease of the right vulva. After radical wide excision of the right vulva in the gynecology department, there was a defect measuring 4.7×7.0 cm. Since the defect was oval in shape, an omega- Ω -variant type B keystone flap was designed. The designed flap was 6.7 cm in width. The upper and lower arms of the flap were elevated off the deep fascia and transposed to cover the defect (►Fig. 3).

A 70-year-old female patient was diagnosed with bilateral extramammary Paget's disease of the vulva. She underwent inguofemoral lymph node dissection on both sides under general anesthesia, followed by radical wide excision. The resultant defect measured 4.5×18.0 cm on the right side and 4.0×14.0 cm on the left. Standard keystone flaps for both vulva were designed and were 6.5 cm in width for each. After a 2.0-cm dissection under the deep fascia, a standard keystone flap was applied to the right side, whereas a rotational keystone flap was applied to the left side, as a rotation of the flap was required below the defect (►Fig. 4). At 200 days after the surgery, there were no other complaints of functional discomforts related to micturition, defecation, walking, or sitting, and the patient was satisfied with the esthetic result.

Discussion

The keystone flap, introduced by Behan in 2003, can be simply designed, allowing it to be used for any location and size of defect, and undermines only the periphery of the flap; thus, no fine perforator dissection is needed and flap survival is relatively reliable.⁵

The standard keystone flap was designed for the reconstruction of elliptical defects; however, there are various modifications that can be used depending on the size and morphology of the defect.⁷ The demographic characteristics of the patients are summarized in ►Table 1. This was the case for the four case presentations mentioned in this paper where different modifications were used depending on the size and morphology of the defect. The schematic diagram of patients with reconstruction is presented in ►Table 2.

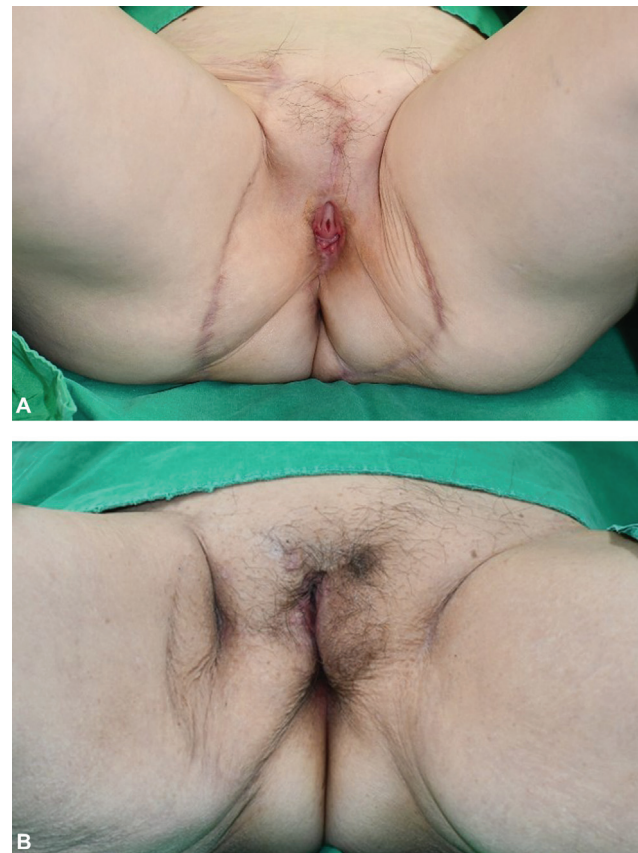

Fig. 4 Case 4: Standard keystone on the right side and rotational keystone flap on the left side. (A) Immediate postoperative photography, and (B) at 350 days postsurgery photography.




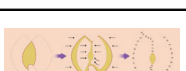
As previously mentioned, a standard keystone flap is a fasciocutaneous advancement flap based on randomly located vascular perforators without the use of Doppler ultrasonography to locate perforators. In this study, named perforators (anterior labial artery of the external pudendal artery, cutaneous branches of the obturator artery, and posterior labial artery of the internal pudendal artery) were located in the flap using Doppler ultrasonography, resulting in a flap more reliable than the standard keystone flap. A wider flap than the standard keystone flap enabled a more reliable and redundant flap, which makes it possible to suture without tension, resulting in a good outcome of the labium major morphology.

Table 1 Demographic characteristics of the patients

Patient	Age (y)	Underlying disease	Vulvar neoplasm	Defect side	Defect size (cm)	Lymph node dissection	Surgical procedure	Keystone width (cm)
1	83	HTN, spinal stenosis	Squamous cell carcinoma	Both	4.5 × 10.0	+	Standard keystone flap	5.0
2	64	HTN, varicose vein	Squamous cell carcinoma	Both	5.5 × 8.5	+	Double opposing keystone flap	5.5
3	74	–	Extramammary Paget’s disease	Right	4.7 × 7.0	–	Omega variant keystone flap	6.7
4	70	HL	Extramammary Paget’s disease	Both	4.5 × 18.0 (right) 4.0 × 14.0 (left)	+	Standard keystone flap (right) Rotational keystone flap (left)	6.5 (right) 6.5 (left)

Abbreviations: HTN, hypertension; HL, hyperlipidemia.

Table 2 Schematic diagram of vulva reconstruction using keystone flaps

Technique	Diagram
Standard keystone flap	
Double opposing keystone flap	
Omega variant keystone flap	
Rotational keystone flap (standard keystone flap [right], rotational keystone flap [left])	

All of the three arteries described in the manuscript were used in the four cases. Although multiple perforators flap can limit the arc of rotation of the flap, no significant degree of rotation was required in vulvar reconstruction. In addition, with a slight dissection of the deep fascia, the keystone flap was approximated to the vulvar area to secure sufficient redundancy for covering the defect.

When performing the omega-variant type B keystone flap of case 3, as described in the manuscript, the rotation of the upper and lower arms was required; therefore, the upper and lower arms of the flap were elevated off the wider area of the deep fascia compared with the other cases. To reduce tension as much as possible, deep fascia dissection is required to the lateral margin, and subcutaneous dissection can be added to the medial margin of the flap.

For functionally and aesthetically successful vulvar reconstruction, flaps should be thin enough. The inguinal and para suprapubic areas are commonly used for vulvar reconstruction because they are thin.⁸ However, our cases, since inguinofemoral lymph node dissection was performed in three out of four patients and the blood supply may not be sufficient, so inguinal skin flap was not performed.

Flaps based on the internal pudendal artery have also been used for vulvar reconstruction.^{1,2} Flaps based on the internal pudendal artery had difficulties in reconstructing the upper vulva, and there is a risk of necrosis of the flap tip if the flap is lengthened. However, the keystone flap in this study used the internal pudendal artery as the main perforator and included two additional perforators on the upper part at the same time. So, it could be effectively used for reconstruction on the upper part of the vulva.

In conclusion, the keystone flap based on perforators of three arteries has many advantages. It is easy to design and elevate, and the survival of the flap is highly reliable, showing low morbidity and complication rates. It seems to be more advantageous for advanced-stage vulva cancer. The procedure is also effective in reconstructing large defects and gives good functional results and acceptable cosmetic appearances. The flap and scars did not seem to affect the patients during walking or sitting. The scars were also quite well hidden. Therefore, we consider this method as our primary choice for vulvar reconstruction.

Authors’ Contributions

Y.L. was responsible for data curation, methodology, writing—original draft, and writing—review and editing; S.L. was responsible for data curation, visualization, writing—review and editing; D.L. was responsible for data curation, visualization, writing—review and editing; H.Y. was responsible for formal analysis, writing—review and editing; H.P. was responsible for formal analysis, writing—review and editing; H. P. was responsible for conceptualization, data curation, formal analysis, methodology, project administration, writing—original draft, and writing—review and editing.

Note

This article was presented as a poster at the 10th Research and Reconstruction (R&R) Forum on July 24–25, 2020, Korea.

Ethical Approval

This study was approved by the Institutional Review Board of Daegu Fatima Hospital (IRB No. DFE21ORIO106)

and performed in accordance with the principles of the Declaration of Helsinki.

Patient Consent

The patients provided written informed consent for the publication and the use of their images.

Conflict of Interest

None declared.

References

- 1 Tan BK, Kang GC-W, Tay EH, Por YC. Subunit principle of vulvar reconstruction: algorithm and outcomes. *Arch Plast Surg* 2014;41(04):379–386
- 2 Tham NL, Pan WR, Rozen WM, et al. The pudendal thigh flap for vaginal reconstruction: optimising flap survival. *J Plast Reconstr Aesthet Surg* 2010;63(05):826–831
- 3 Lee PK, Choi MS, Ahn ST, Oh DY, Rhie JW, Han KT. Gluteal fold V-Y advancement flap for vulvar and vaginal reconstruction: a new flap. *Plast Reconstr Surg* 2006;118(02):401–406
- 4 John HE, Jessop ZM, Di Candia M, Simcock J, Durrani AJ, Malata CM. An algorithmic approach to perineal reconstruction after cancer resection—experience from two international centers. *Ann Plast Surg* 2013;71(01):96–102
- 5 Behan FC. The keystone design perforator island flap in reconstructive surgery. *ANZ J Surg* 2003;73(03):112–120
- 6 Rini IS, Gunardi AJ, Marsaulina RP, Aryandono T, Dachlan I, Dwiprahasto I. A systematic review of the keystone design perforator island flap in the reconstruction of trunk defects. *Arch Plast Surg* 2020;47(06):535–541
- 7 Behan FC, Rozen WM, Lo CH, Findlay M. The omega - Ω - variant designs (types A and B) of the keystone perforator island flap. *ANZ J Surg* 2011;81(09):650–652
- 8 Kim SH, Seo BC, Oh DY, et al. A new flap for 3-dimensional vulvar and vaginal reconstruction: the “butterfly flap”. *J Korean Soc Plast Reconstr Surg*. 2010;37:847–849