



Since January 2020 Elsevier has created a COVID-19 resource centre with free information in English and Mandarin on the novel coronavirus COVID-19. The COVID-19 resource centre is hosted on Elsevier Connect, the company's public news and information website.

Elsevier hereby grants permission to make all its COVID-19-related research that is available on the COVID-19 resource centre - including this research content - immediately available in PubMed Central and other publicly funded repositories, such as the WHO COVID database with rights for unrestricted research re-use and analyses in any form or by any means with acknowledgement of the original source. These permissions are granted for free by Elsevier for as long as the COVID-19 resource centre remains active.



Contents lists available at ScienceDirect

## The Egyptian Rheumatologist

journal homepage: [www.elsevier.com/locate/ejr](http://www.elsevier.com/locate/ejr)

# Systemic flare and cutaneous ulceration following cytomegalovirus infection in a patient with anti-melanoma differentiation-associated protein 5 (MDA5) associated myositis: Diagnostic challenge during the time of coronavirus disease (COVID-19) pandemic

Prakash Gupta<sup>a</sup>, Rajat Kharbanda<sup>b</sup>, Able Lawrence<sup>b</sup>, Latika Gupta<sup>b,\*</sup><sup>a</sup>Saint Louis University Hospital of the Sacred Heart-Baguio City, Virgen Milagrosa University Foundation-College of Medicine, San Carlos City, Pangasinan, Philippines<sup>b</sup>Department of Clinical Immunology and Rheumatology, Sanjay Gandhi Postgraduate Institute of Medical Sciences, Lucknow, India

## ARTICLE INFO

## Article history:

Received 26 March 2021

Accepted 5 June 2021

Available online 09 June 2021

## Keywords:

Myositis

Dermatomyositis

Cytomegalovirus

Teleconsultation

Immunodeficiency

## ABSTRACT

**Background:** Anti-melanoma differentiation-associated protein 5 (MDA5) associated idiopathic inflammatory myopathy (IIM) often manifests with minimal muscle weakness and rapidly progressive interstitial lung disease (RP-ILD) with a poor prognosis. The clinical presentation may be varied in different ethnic groups. The ongoing coronavirus disease (COVID-19) pandemic has made management even more challenging as certain manifestations may be difficult to diagnose remotely.

**Aim of the work:** To throw light on the rare association of CMV infection in established anti-MDA5 myositis with severe consequences. Similar cases were presented and compared.

**Case report:** A 42-year-old lady presented with heliotrope rash, periorbital edema, ulcerated Gottron's papules, proximal muscle weakness and intermittent fever of six-month duration. Anti-MDA5 antibodies were positive. Active disease, including myocarditis and RP-ILD, were challenging to diagnose on teleconsultation. Upon initiating tofacitinib, cytomegalovirus (CMV) polymerized chain reaction (PCR) came positive. Ganciclovir was started with the possibility of viral activation being the potential driving force for interferon pathway activation and dermatomyositis (DM) flare, but the patient succumbed to the illness.

**Conclusion:** Viral triggers are known to induce autoimmune disease in the genetically predisposed. However, CMV infection in established anti-MDA5 myositis is uncommon and further association with myocarditis is a rare occurrence. Ulcerated Gottron's and periorbital oedema may carry a sinister connotation in Indians with anti-MDA5 DM, with worse manifestations such as myocarditis— which albeit rare, can be fatal.

© 2021 Egyptian Society of Rheumatic Diseases. Publishing services provided by Elsevier B.V. This is an open access article under the CC BY-NC-ND license (<http://creativecommons.org/licenses/by-nc-nd/4.0/>).

## 1. Introduction:

Dermatomyositis (DM) presents with florid muscle weakness and varied cutaneous manifestations and comprises skin features as heliotrope rash, gottron's papules, macular erythema, and occasionally palmar papules and skin ulceration [1,2]. In contrast, anti-melanoma differentiation-associated protein 5 (MDA5) positive DM is a rare subset which oftentimes manifest with minimal muscle weakness and rapidly progressive interstitial lung disease (RP-ILD) with a poor prognosis unless diagnosed by testing for specific Myositis-specific antibodies (MSAs) [3,4]. Classic cutaneous mani-

festations vary in different ethnic groups and may be important pointers towards diagnosis [5,6]. Cutaneous ulceration is reported in 50% of anti-MDA5 associated idiopathic inflammatory myopathies (IIM), most frequently over the elbows, knuckles, knees, lateral nail folds and also seen over sun exposed areas as chest or back [1,3].

Interstitial lung disease (ILD) among Asians is generally rapidly progressive compared to Westerners and frequently culminates in fatal outcomes with up to 70% mortality in patients with anti-MDA5 IIM [4,5]. It is crucial to initiate prompt intensive treatment for RP-ILD with anti-MDA5 antibody due to its poor prognosis. The measurement of titer of anti-MDA5 antibodies takes several days and this can delay the necessary intervention. Consequently, identifying key clinical signs in suspects can offer important guidance for initiating early aggressive therapy. The ongoing coronavirus

Peer review under responsibility of Egyptian Society of Rheumatic Diseases.

\* Corresponding author.

E-mail address: [drlatikagupta@gmail.com](mailto:drlatikagupta@gmail.com) (L. Gupta).<https://doi.org/10.1016/j.ejr.2021.06.001>

1110-1164/© 2021 Egyptian Society of Rheumatic Diseases. Publishing services provided by Elsevier B.V.

This is an open access article under the CC BY-NC-ND license (<http://creativecommons.org/licenses/by-nc-nd/4.0/>).

disease (COVID-19) pandemic has made management challenging as certain manifestations may be difficult to diagnose remotely.

As we are in the midst of an unprecedented pandemic, we can only speculate the long-term effects and implications of COVID-19 [6]. A negative impact of the pandemic on the QoL of RA patients has been described [7]. Among persons with COVID-19, the development of fibromyalgia syndrome was anticipated as a consequence to pandemic-associated stressors [6]. A causal relationship between vasculitis and viral infections has been postulated. Vasculitis is potentially one of COVID-19's presenting symptoms and prompt diagnosis and treatment is crucial in improving outcome of patients [8]. Viral triggers are known to induce autoimmune disease in the genetically predisposed. However, the hypothesis that viral infections can drive autoimmunity in established anti-MDA5 myositis is proposed but poorly studied. Myocarditis is another cause of mortality in IIM though not typically described in anti MDA5 IIM.

A case is presented with anti MDA5 positive IIM with CMV infection associated flare of dermatomyositis (DM), who succumbed to RP-ILD and myocarditis. Albeit rare, myocarditis should be actively looked out for in patient with MDA5 positive IIM.

## 2. Methods

A search was conducted using the terms (“Cytomegalovirus and myositis”) published on MEDLINE any time. Of fifty-eight articles obtained, 38 case reports were identified. After excluding articles in languages other than English and those without available full-text, six reports were used for further analysis. Written consent was obtained from the patient described (Fig. 1).

## 3. Case presentation

A 42-year-old lady presented with heliotrope rash and periorbital edema, ulcerated Gottron’s papules, proximal muscle weakness, and intermittent fever of six-month duration. Computerized

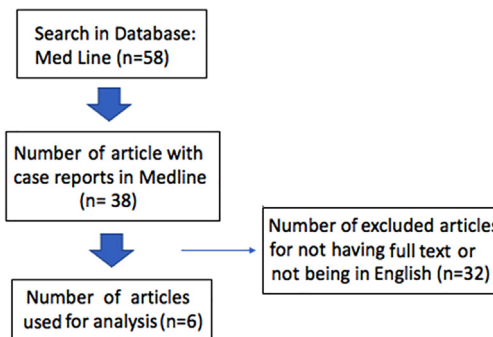


Fig. 1. Flow chart for the search strategy of the terms (“Cytomegalovirus and myositis”) published on MEDLINE any time.

Tomography (CT) of the chest suggested early ILD. Myositis specific autoantibodies were sent, and azathioprine (AZA) initiated for DM. The patient developed cytopenia with AZA which improved on discontinuing the drug though the patient’s condition rapidly deteriorated during the imposed lockdown period. She returned with symptoms of easy fatiguability, dyspnea, and vasculitis ulcers over the Gottron’s rashes, elbow, and feet (Fig. 2a–d) requiring in-patient admission nine months after initial presentation and 15 months into the illness. Anti- MDA5 antibodies tested positive. 2D-Echocardiography confirmed systolic dysfunction and CT revealed rapid progression of interstitial lung disease (RP-ILD), both of which were missed on teleconsultations (Fig. 2e, f).

As she continued to worsen despite pulse methylprednisolone and cyclophosphamide, tofacitinib was initiated. However, it had to be discontinued after CMV polymerized chain reaction (PCR) turned positive. She was treated with ganciclovir with the possibility of viral activation being the potential driving force for interferon pathway activation and flare of DM. Despite continuing high dose glucocorticoids and antivirals, CRP (18 mg/dl) and high ferritin (>1500 ng/ml) remained high, and patient succumbed to her illness over a fortnight of in-patient management.

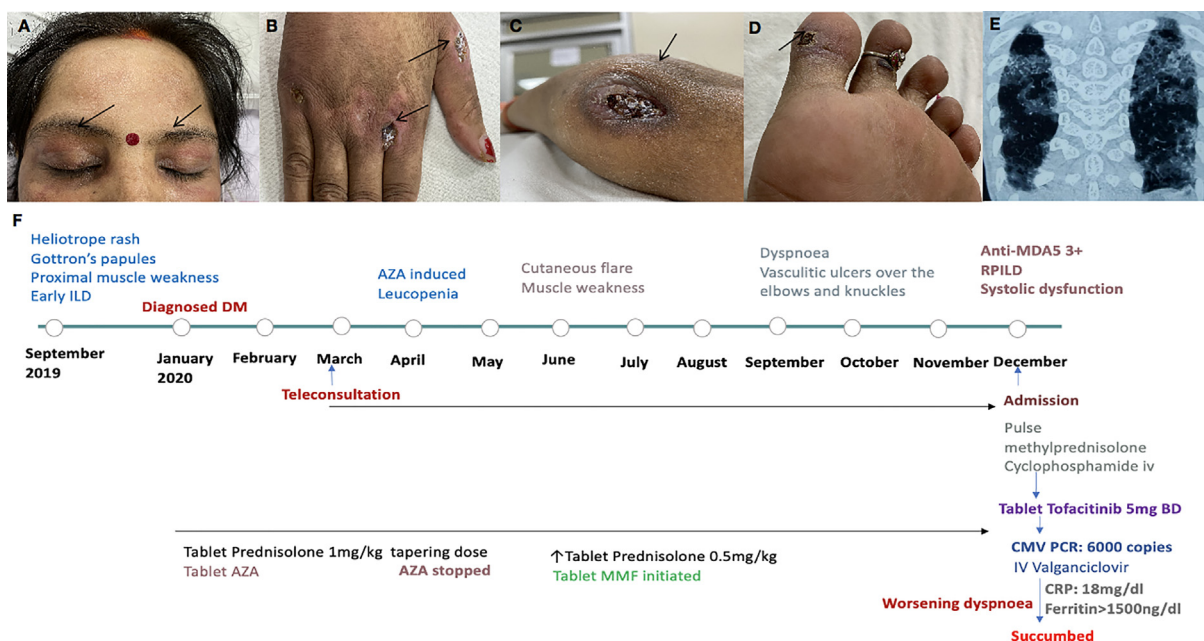


Fig. 2. A: Heliotrope rash with periorbital puffiness; B: Vasculitis ulcer over knuckles; C: Vasculitis ulcer involving elbow; D: Vasculitis ulcer involving feet; E: Both the lung fields having patchy consolidations with ground glass opacities suggestive of an organizing pneumonia pattern; F: Timeline of the patient’s clinical manifestations along with treatment.

**Table 1**  
Association of cytomegalovirus (CMV) infection with myositis case reports.

Case Report	Country/ year	Caseage/sex	Risk factors	With CMV	MSA	Other organs involved	Treatment	Outcome
Gupta et al	India/ 2021	42/F	DM	Yes	MDA5	Myocarditis, ILD	AZA, MP, CYC, tofacitinib, GCV	Death
Sakthivadivel et al [14]	India/ 2020	29/M	GBS	Yes	None	Oral ulcer, Myonecrosis	P, valganciclovir, plasmapheresis	Improved with plasmapheresis.
Zhang et al [15]	China/ 2020	61/M	DM	Yes	None	Pneumonia, Bronchitis	MP, moxifloxacin, TZP, oseltamivir, voriconazole, GCV.	Resolved after 4 days
Lange et al [16]	USA/ 2018	Middle aged/F	MAS	Yes	anti-RNP anti-Ro	Endocarditis, DPI, GNB, UTI	Valganciclovir, DX, anakinra etoposide	Death
Hozumi et al [17]	Japan/ 2012	62/F	PM	Yes	None	Ulcerating bronchitis	IV GCV	Improved after 3 wks
Hashimoto et al [18]	Japan/ 2006	67/F	DM	Yes	None	ILD	CYC, P, GCV	Death
Naylor et al [19]	UK/1987	65/F	–	Yes	None	None	P, GCV	Improved after 3 mo
		69/F	–	No	None	ARF subclinical HT	Peritoneal dialysis Corticosteroids	Ms. strength recovery 4 mo after discharge

DM: Dermatomyositis, GBS: Guillain-Barre syndrome, MAS: macrophage activation syndrome, CMV: cytomegalovirus, MSA: myositis-specific autoantibodies, PM: Polymyositis, MTX: methotrexate, anti-RNP: anti-ribonucleoprotein, UTI: urinary tract infection, ILD: Interstitial Lung disease, DPI: Diffuse pulmonary infiltrates, GNB: gram-negative bacteremia, ARF: acute renal failure, HT: Hashimoto's thyroiditis, AZA: azathioprine, MP: methylprednisolone, TZP: Piperacillin/Tazobactam, GCV: Ganciclovir, DX: dexamethasone, CYC: cyclophosphamide, P: Prednisolone, TMP-SMX: Trimethoprim-sulfamethoxazole, Ms: muscle.

#### 4. Discussion

Ulcerated Gottron's and periorbital edema can be important clues to underlying anti-MDA5 DM and viral activation could be the underlying driver of autoimmunity [9]. Six other cases were identified in literature reporting the intersection of CMV with IIM (Table 1). A few cases were successfully managed with ganciclovir though many succumbed despite treatment. High mortality of anti-MDA5 positive DM and association with CMV infections and seasonality of the former opens the case to explore underlying inborn immune pathway defects which may predispose these individuals to viral infections [10]. Recently identified similarity between COVID-19 and anti-MDA5 positive IIM further highlights an important role of viruses in triggering and sustaining autoimmunity. MDA5 being the cytoplasmic sensor for viral RNA could potentially predispose to infections when defective or lead to autoimmunity from hyperfunctioning gain-of-function mutations. Autoimmunity and primary immunodeficiency are now known to be along a continuum, with the recent recognition of heritable digenic and polygenic defects in several autoimmune disorders with widespread availability of whole exome sequencing [11]. Therefore, it seems plausible that greater insight into the area may potentially classify anti-MDA5 DM as an adult-onset primary immunodeficiency with autoimmunity with important therapeutic implications [12]. Milder disease course in another subset of anti-MDA5 IIM suggests the disease may be bi-phenotypic with two distinct variants in the Indian population [9].

Teleconsultation has assumed the center stage in management of chronic diseases during the COVID-19 pandemic [13]. Although the preferred means of communication in these unusual times, there is felt need to develop means of better clinical examination and identify key aspects of poor health like cardiac or muscle disease through audiovisual consultations [11]. The rare occurrence of myocarditis in anti-MDA5 DM may be fatal as in this case, and greater attention to cardiac function may be considered in management.

#### Funding

This research did not receive any specific grant from funding agencies in the public, commercial, or not-for-profit sectors.

#### Declaration of Competing Interest

The authors declare that they have no known competing financial interests or personal relationships that could have appeared to influence the work reported in this paper.

#### Acknowledgments

We are thankful to the Connecting Researchers and Dr Malke Asaad for their help with this work.

#### References:

- [1] Narang NS, Casciola-Rosen L, Li S, Chung L, Fiorentino DF. Cutaneous ulceration in dermatomyositis: Association with anti-melanoma differentiation-associated gene 5 antibodies and interstitial lung disease. *Arthritis Care Res* 2015;67(5):667–72.
- [2] Li L, Wang Q, Yang F, Wu C, Chen S, Wen X, et al. Anti-MDA5 antibody as a potential diagnostic and prognostic biomarker in patients with dermatomyositis. *Oncotarget* 2017;8(16):26552–64.
- [3] Tansley SL, Betteridge ZE, Gunawardena H, Jacques TS, Owens CM, Pilkington C, et al. Anti-MDA5 autoantibodies in juvenile dermatomyositis identify a distinct clinical phenotype: a prospective cohort study. *Arthritis Res Ther* 2014;16(4):R138.
- [4] Kawasumi H, Gono T, Kawaguchi Y, Yamanaka H. Recent treatment of interstitial lung disease with idiopathic inflammatory myopathies. *Clin Med Insights Circ Respir Pulm Med* 2015;9:9–17.
- [5] Chino H, Sekine A, Baba T, Kitamura H, Iwasawa T, Okudela K, et al. Interstitial lung disease with anti-melanoma differentiation-associated protein 5 antibody: rapidly progressive peribular opacity. *Intern Med* 2019;58(18):2605–13.
- [6] Gheita TA, Fathi HM, ElAde SS, Eesa NN, Hammam NH. Coronavirus disease 2019 (COVID-19) an emerging trigger for primary fibromyalgia syndrome: A tale of three cases post-COVID-19. *Int J Clin Rheumatol* 2021;16(4):129–35.
- [7] Zomlheto Z, Assogba C, Dossou-yovo H. Impact of the severe acute respiratory syndrome coronavirus 2 (SARS-CoV2) infection and disease-2019 (COVID-19) on the quality of life of rheumatoid arthritis patients in Benin. *Egyptan Rheumatol* 2021;43(1):23–7.
- [8] Assar S, Pournazari M, Soufivand P, Mohamadzadeh D, Sanaee S. Microscopic polyangiitis associated with coronavirus disease-2019 (COVID-19) infection in an elderly male. *Egypt Rheumatol* 2021;43(3):225–8.
- [9] Gupta L, Naveen R, Gaur P, Agarwal V, Aggarwal R. Myositis-specific and myositis-associated autoantibodies in a large Indian cohort of inflammatory myositis. *Semin Arthritis Rheum* 2021;51(1):113–20.
- [10] Mehta P, Agarwal V, Gupta L. High early mortality in idiopathic inflammatory myopathies: Results from the inception cohort at a tertiary care center in northern India. *Rheumatology (Oxford)* 2021;keab001.
- [11] Gupta L, Chinoy H. Monitoring disease activity and damage in adult and juvenile idiopathic inflammatory myopathy. *Curr Opin Rheumatol* 2020;32(6):553–61.
- [12] Rathore U, Haldule S, Gupta L. Psoriasisiform rashes as the first manifestation of anti-MDA5 associated myositis. *Rheumatology (Oxford)* 2020;keaa821.

- [13] Gupta L, Lilleker JB, Agarwal V, Chinoy H, Aggarwal R. COVID-19 and myositis - unique challenges for patients. *Rheumatology (Oxford)* 2021;60(2):907–10.
- [14] Sakthivadivel V, Naveenraj P, Kachhwaha A, Kumar D, Anne PB, Elhence P, et al. Concurrent acute myositis and Guillain-Barre syndrome in cytomegalovirus infection – a rare case report. *BMC Infect Dis* 2020;20(1). doi: <https://doi.org/10.1186/s12879-020-05506-5>.
- [15] Zhang K, Yu C, Li Y, Wang Y. Next-generation sequencing technology for detecting pulmonary fungal infection in bronchoalveolar lavage fluid of a patient with dermatomyositis: a case report and literature review. *BMC Infect Dis* 2020;20.
- [16] Lange AV, Kazi S, Chen W, Barnes A. Fatal case of macrophage activation syndrome (MAS) in a patient with dermatomyositis and cytomegalovirus viraemia. *BMJ Case Rep*.2018. 2018:bcr2018225231.
- [17] Hozumi H, Fujisawa T, Kuroishi S, Inui N, Nakamura Y, Suda T, et al. Ulcerating bronchitis caused by cytomegalovirus in a patient with polymyositis. *Intern Med* 2012;51(20):2933–6.
- [18] Hashimoto A, Okuyama R, Watanabe H, Tagami H, Aiba S. Cytomegalovirus infection complicating immunosuppressive therapy for dermatomyositis. *Acta Derm Venereol* 2006;86(6):535–7.
- [19] Naylor CD, Jevnikar AM, Witt NJ. Sporadic viral myositis in two adults. *CMAJ* 1987;137:819–21.