



Efficacy and safety of pyrotinib and radiotherapy vs. pyrotinib-based therapy in patients with HER2⁺ breast cancer with brain metastasis: a retrospective cohort study

Jiixin Chen¹, Huiqiang Zhang², Jinmei Zhou², Zisheng Wu¹, Xuexue Wu², Shaohua Zhang², Zefei Jiang², Tao Wang^{1,3,4}

¹Department of Oncology, The Fifth Medical Center, Chinese PLA General Hospital and Medical School, Beijing, China; ²Department of Oncology, The Fifth Medical Center, Chinese PLA General Hospital, Beijing, China; ³Anhui Medical University, Hefei, China; ⁴Southern Medical University, Guangzhou, China

Contributions: (I) Conception and design: T Wang, J Chen; (II) Administrative support: Z Jiang, S Zhang; (III) Provision of study materials or patients: H Zhang, J Zhou; (IV) Collection and assembly of data: Z Wu; (V) Data analysis and interpretation: J Chen, X Wu; (VI) Manuscript writing: All authors; (VII) Final approval of manuscript: All authors.

Correspondence to: Tao Wang. The Fifth Medical Center, Chinese PLA General Hospital and Medical School, No. 8 East Street, Fengtai District, Beijing, China. Email: wangtao733073@163.com.

Background: At present, local therapy, such as surgery and radiotherapy, is the mainstay treatment for brain metastasis and anti-human epidermal growth factor receptor type 2 (HER2)-targeted therapy has been shown to be efficacious for HER2⁺ breast cancer (BC) patients with brain metastasis. However, Clinical studies comparing the combined effects of the two treatments are lacking. This study sought to investigate the efficacy and safety of pyrotinib and radiotherapy versus pyrotinib-based therapy in treating HER2⁺ BC patients with brain metastasis.

Methods: This retrospective, observational study collected data from 79 HER2⁺ BC patients with brain metastasis who received pyrotinib-based therapy from May 2018 to December 2021. Among these patients, 35 received pyrotinib-based therapy concurrently with, or within 3 months before or after, brain radiotherapy (Group A), and 44 received pyrotinib-based therapy as the primary regimen (with no restriction as to whether they had received brain radiotherapy previously or not, the interval between receiving radiotherapy and receiving pyrotinib was >3 months) (Group B). Patient information was collected by the Electronic Medical Records System. The primary endpoints were progression-free survival (PFS) and overall survival (OS). The secondary endpoints were the objective response rate (ORR), the clinical benefit rate (CBR), and safety. The assessment of adverse effects was based on CTCAE5.0.

Results: The intracranial ORRs were 48.6% in Group A and 20.5% (9/44) in Group B (P=0.015). The intracranial CBRs were 80.0% in Group A and 65.9% in Group B. The median intracranial PFS times (IC-PFS) were 15.0 months and 9.0 months in Group A and Group B, respectively (P=0.385). There was no statistically significant difference in OS between the 2 groups (95.0 vs. 98.0 months, P=0.872). The subgroup analysis showed that patients with active brain metastasis who received pyrotinib and radiotherapy had a longer IC-PFS time than those who received pyrotinib-based therapy (P=0.056). No serious adverse reactions (e.g., acute brain edema, cognitive dysfunction, or treatment-related death events) were observed.

Conclusions: Pyrotinib combined with radiotherapy is recommended for HER2⁺ breast cancer active brain metastasis patients who can tolerate radiotherapy and pyrotinib. Pyrotinib-based therapy may be considered for patients who cannot tolerate radiotherapy and pyrotinib.

Keywords: Breast cancer (BC); brain metastasis; human epidermal growth factor receptor type 2 (HER2); pyrotinib; radiotherapy

Submitted Sep 19, 2022. Accepted for publication Nov 17, 2022.

doi: 10.21037/atm-22-5352

View this article at: <https://dx.doi.org/10.21037/atm-22-5352>

Introduction

In 2020, breast cancer became the most prevalent malignant tumor worldwide. Human epidermal growth factor receptor type 2 (HER2)-positive breast cancer (HER2⁺ BC) is a highly aggressive subtype of breast cancer, and accounts for 20–30% of all Breast cancer patients. With the development and clinical use of HER2-targeted therapy, the survival of HER2⁺ BC patients has improved significantly (1). However, with the prolongation of patient survival and good control of extracranial lesions, central nervous system (CNS) metastasis is increasing. Up to 50% of all patients with advanced HER2⁺ BC will eventually develop brain metastasis (2,3). Further, the poor therapeutic effect of treatments for brain metastasis is becoming the main life-threatening reason for HER2⁺ breast cancer (4,5).

At present, local therapy, such as surgery and radiotherapy, is the mainstay treatment for brain metastasis (6). One randomized controlled study showed that in the SRS group, the actuarial 1-year brain salvage-free survival rate was 50% and the 1-year survival rate was 57% with good quality of life maintained (7). However, many issues arise in relation to radiotherapy, such as recurrence after radiotherapy, the selection and designation of re-radiotherapy, possible radioactive brain necrosis, and cognitive impairment after multiple courses of routine radiotherapy.

HER2-targeted therapy has been shown to be efficacious for HER2⁺ BC patients with brain metastasis. At present, the available HER2-targeted therapies can be categorized into small-molecule tyrosine kinase inhibitors (TKIs), and monoclonal antibodies and antibody-drug conjugates (ADCs). Compared to monoclonal antibodies and ADCs,

TKIs have more advantages in the penetration of the blood-brain barrier (8-11). To date, 4 epidermal growth factor receptor (EGFR)-TKIs have been approved (i.e., lapatinib, pyrotinib, neratinib, and tucatinib), all of which have been shown to have good efficacy in treating BC patients with brain metastasis (12-16).

Pyrotinib, a small-molecule TKI independently developed in China, is an irreversible and potent TKI that targets HER1, HER2, and HER4. In the PHENIX trial, about 10% of patients presented with asymptomatic brain metastasis, and the progression-free survival (PFS) time of those in the pyrotinib and capecitabine group reached 6.9 months (17), indicating that brain metastasis patients could benefit from treatment with pyrotinib. In a real-world study, pyrotinib was found to significantly improve the prognosis of patients with brain metastasis, and patients with brain metastasis treated pyrotinib had a PFS time of 8.8 months. PERMEATE, a single-arm, prospective, phase-II study, showed that patients with brain metastasis that progressed after radiotherapy who were treated with pyrotinib combined with capecitabine had a CNS-objective response rate (ORR) of 42.1% and a PFS time of 5.6 months, and patients with brain metastasis who did not received radiotherapy had a CNS-ORR of 74.6% and a PFS time of 11.3 months (18,19). However, relatively few studies have focused on pyrotinib treatment, and even fewer have analyzed whether pyrotinib affects the overall survival (OS) of patients with brain metastasis based on real-world data (20,21).

All of the above-mentioned studies examined the effect of drugs in the treatment of brain metastasis. In clinical practice, radiotherapy is still the mainstay treatment for brain metastasis, the combination of drugs with radiotherapy, and how, is not known. This real-world study sought to compare the efficacy and safety of pyrotinib and radiotherapy to pyrotinib therapy alone in the treatment of HER2⁺ BC patients with brain metastasis, and to determine the best treatment model for these patients. We present the following article in accordance with the STROBE reporting checklist (available at <https://atm.amegroups.com/article/view/10.21037/atm-22-5352/rc>).

Methods

Inclusion criteria

To be eligible for inclusion in this study, patients had to meet the following inclusion criteria: (I) have a histopathologically confirmed diagnosis of HER2⁺ BC with

Highlight box

Key findings

- Pyrotinib combined with radiotherapy is recommended for HER2⁺ breast cancer active brain metastasis patients.

What is known and what is new?

- Radiotherapy is still the mainstay treatment for brain metastasis, the combination of drugs with radiotherapy, and how, is not known.
- This study sought to investigate the efficacy and safety of pyrotinib and radiotherapy versus pyrotinib-based therapy.

What is the implication, and what should change now?

- The large prospective randomized controlled trials need to be conducted.

brain metastasis; (II) have been treated with pyrotinib-based therapy after being diagnosed with brain metastasis, (III) be aged 18–80 years; (IV) have presented with at least 1 intracranial measurable lesion according to the Response Evaluation Criteria in Solid Tumors (RECIST v1.1); and (V) have normally functionally major organs, and no treatment contraindications.

Clinical data

We collected the data of 79 HER2⁺ BC patients with brain metastasis who were diagnosed with breast cancer brain metastases in the Department of Oncology, the Fifth Medical Center of Chinese PLA General Hospital and received pyrotinib-based therapy from May 2018 to December 2021. Among these patients, 35 received pyrotinib-based therapy concurrently with, or within 3 months before or after, brain radiotherapy (Group A), and 44 received pyrotinib-based therapy as the primary regimen (with no restriction as to whether they had received brain radiotherapy previously or not, and with and with an interval between receiving radiotherapy and receiving pyrotinib was >3 months) (Group B). The study was conducted in accordance with the Declaration of Helsinki (as revised in 2013). This study was reviewed and approved by the Ethics Committee of the Fifth Medical Center of Chinese PLA General Hospital (No. 2012L01067). All patients had given written informed consent.

The assessment of baseline clinical characteristics

The patient information, such as age, disease-free survival (DFS), hormone receptor type, TNM staging, metastasis at diagnosis, meningeal metastasis, any symptom after diagnosis, extracranial metastasis, brain radiotherapy before treatment, HER2-targeted therapy lines, previously received treatment, treatment regimen through a system of medical records, etc., was collected from the Electronic Medical Records System.

HER2 overexpression was defined as an immunohistochemical membrane staining with a score of 3+, and HER2-negative expression was divided into HER 2+ and 0-point score, and fluorescence in situ hybridization (FISH) was performed when the HER2 immunohistochemistry (IHC) score was ambiguous (2+). According to the American Society of Clinical Oncology/College of American Pathologists (ASCO/CAP) guideline recommendations for HER2 testing, it was judged as HER2 positive if the ratio

of HER2/CEP17 was greater than or equal to 2.0 or the copy number of HER2 gene was greater than or equal to 6. Estrogen receptor (ER) and progesterone receptor status was detected by IHC. The IHC results of ER/PR $\geq 1\%$ were treated as positive. Hormone receptor (HR) positive was defined as ER/PR positive, and HR negative was defined as ER negative and PR negative.

Efficacy assessment

A baseline examination was performed for all the measurable lesions before the treatment, followed by regular imaging examinations and measurements. According to RECIST v1.1, a complete response (CR) was defined as the disappearance of all target lesions, a partial response (PR) was defined as a reduction of $\geq 30\%$ in the total long diameters of baseline lesions, progressive disease (PD) was defined as an increase of >20% in the total long diameters of baseline lesions, an increase of 5 mm in the minimum absolute value, or the appearance of new lesions, and stable disease (SD) was defined the sum of the long diameters of the baseline lesions decreased but did not reach PR or increased but did not reach PD.

The objective response rate (ORR) was defined as CR + PR. The clinical benefit rate (CBR) was defined as CR + PR + SD ≥ 6 months. OS was defined as the time from diagnosis of BC to death. Intracranial progression-free survival (IC-PFS) was defined as the time from the start of treatment to the first occurrence of PD in the intracranial lesions. The assessment of adverse effects was based on CTCAE5.0.

Follow-up

As of April 2022, there were 35 patients in Group A, and at the end of the pyrotinib-based therapy, 22 of these 35 patients achieved IC-PFS, and 14 died due to PD or other causes. As of April 2022, there were 44 patients in Group B, and at the end of the pyrotinib-based therapy, 28 of these 44 patients achieved IC-PFS, and 20 patients died due to PD or other causes.

Statistical analysis

The continuous variables with a normal distribution are presented as the mean \pm standard deviation, while those with a non-normal distribution are presented as the median (interquartile range). An independent sample *t*-test was used to compare the differences between the 2 groups. The

rates were compared using a Chi-square, Fisher test or independent sample *t*-test. The Kaplan-Meier method was used to estimate the PFS and confidence intervals for the survival analysis. SPSS 22.0 was used to complete all the statistical tests, which were 2-sided tests with a significance level of 0.05.

Results

A total of 79 HER2⁺ BC patients with brain metastasis who received pyrotinib-based therapy as the primary treatment for from May 2018 to December 2021 were included in this study. Active brain metastasis was defined as new brain metastasis or PD after the local treatment of previous brain lesions, while stable brain metastasis was defined as stable brain metastasis after previous treatment. There were 29 (82.9%) patients with active brain metastasis in Group A, and 22 (50%) patients in Group B. In the clinical treatment

of patients with active brain metastasis, radiotherapy is adopted for early local treatment. In this study, a total of 5 patients in the group A cohort and 24 patients in the group B cohort had received brain radiotherapy before the initiation of treatment, a statistically significant difference ($P=0.001$). The pyrotinib-based therapy for the 2 groups included pyrotinib alone, pyrotinib and chemotherapy, and pyrotinib and endocrine therapy. In Group A, 12 patients received pyrotinib alone, 18 patients received chemotherapy and pyrotinib, and 5 received pyrotinib and endocrine therapy. In Group B, 12 patients received pyrotinib alone, 25 received pyrotinib and chemotherapy, 7 received pyrotinib and endocrine therapy. There were no significant differences in terms of the median age, hormone receptor type, tumor node metastasis (TNM) staging, number of brain metastasis at diagnosis, meningeal metastasis, symptoms after diagnosis of brain metastasis, extracranial metastasis, and previous HER2-targeted therapy between

Table 1 Baseline characteristics

Variables	Pyrotinib + radiotherapy (N=35)	Pyrotinib (N=44)	P value
Age, years	45 [30–58]	46 [24–69]	0.39
DFS, months	14.5 [0–120]	17.0 [0–108]	
Hormone receptor type			0.12
HR positive	14 (40.0)	26 (59.1)	
HR negative	21 (60.0)	18 (40.9)	
TNM staging			0.92
I	3 (8.6)	3 (6.8)	
II	12 (34.3)	17 (38.6)	
III	14 (40.0)	15 (34.1)	
IV	6 (17.1)	9 (20.5)	
Metastasis at diagnosis			0.23
Single	8 (22.9)	16 (36.4)	
Multiple	27 (77.1)	28 (63.6)	
Meningeal metastasis			0.50
Yes	5 (14.3)	4 (9.1)	
No	30 (85.7)	40 (90.9)	
Any symptom after diagnosis			0.80
Yes	10 (28.6)	11 (25.0)	
No	25 (71.4)	33 (75.0)	

Table 1 (continued)

Table 1 (continued)

Variables	Pyrotinib + radiotherapy (N=35)	Pyrotinib (N=44)	P value
Extracranial metastasis			
Lymph node metastasis	26 (74.3)	27 (61.4)	0.05
Bone metastasis	18 (51.4)	26 (59.1)	0.65
Hepatic metastasis	19 (54.3)	21 (47.7)	0.65
Lung metastasis	13 (37.1)	23 (52.3)	0.26
Active brain metastasis	29 (82.9)	22 (50.0)	0.004
Stable brain metastasis	6 (17.1)	22 (50.0)	
Brain radiotherapy before treatment			
Yes	5 (14.3)	24 (54.5)	0.001
No	30 (85.7)	20 (45.5)	
HER2-targeted therapy lines			
<2	19 (54.3)	14 (31.8)	0.07
≥2	16 (45.7)	30 (68.2)	
Previously received treatment			
Trastuzumab	31 (88.6)	38 (86.4)	0.52
Pertuzumab	2 (5.7)	8 (18.2)	0.07
Lapatinib	13 (37.1)	28 (63.6)	0.45
Pyrotinib	4 (11.4)	3 (6.8)	0.69
T-DM1	1 (2.9)	2 (4.5)	0.59
Treatment regimen			
Pyrotinib alone	12 (34.3)	12 (27.3)	0.501
Pyrotinib + chemotherapy	18 (51.4)	25 (56.8)	0.476
Pyrotinib + endocrine therapy	5 (14.3)	7 (15.9)	0.842

Data are shown as median [interquartile range] or number (percentage). DFS, disease-free survival; HR, hormone receptor; HER2, human epidermal growth factor receptor type 2; T-DM1, trastuzumab emtansine.

Table 2 Comparison of the efficacy for the 2 groups

Intracranial outcome	Pyrotinib + radiotherapy (N=35)	Pyrotinib (N=44)	P value
CR	2 (5.7%)	0	
PR	15 (42.9%)	9 (20.5%)	
SD	12 (34.3%)	25 (56.8%)	
SD ≥6 months	11 (31.4%)	22 (50.0%)	
PD	6 (17.1%)	10 (22.7%)	
ORR	48.6% (17/35)	20.5% (9/44)	0.015
CBR	80.0% (28/35)	70.5% (31/44)	0.308

CR, complete response; PR, partial response; SD, stable disease; PD, progressive disease; ORR, objective response rate; CBR, clinical benefit rate.

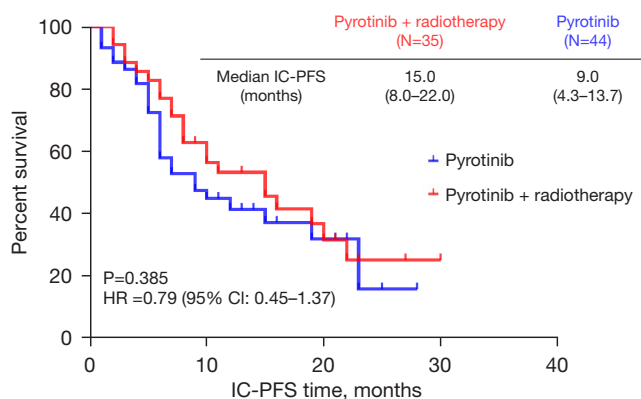


Figure 1 Median IC-PFS times of pyrotinib + radiotherapy vs. pyrotinib-based therapy in the 2 groups. IC-PFS, intracranial progression-free survival; HR, hazard ratio; CI, confidence interval.

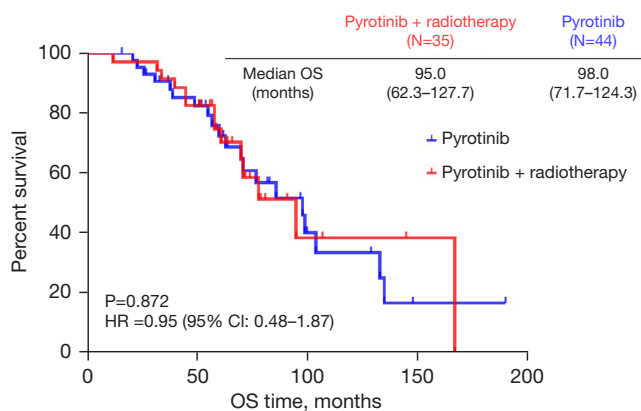


Figure 2 Median OS times of pyrotinib and radiotherapy vs. pyrotinib-based therapy in the 2 groups. OS, overall survival; HR, hazard ratio; CI, confidence interval.

Groups A and B. The baseline characteristics of the patients are shown in *Table 1*.

In Group A, the patients had an ORR of 48.6% (17/35), and 2 patients achieved CR, and 15 patients achieved PR. In Group B, the patients had an ORR of 20.5% (9/44), and no patients achieved CR, and 9 patients achieved PR. The intracranial response rate of Group A was significantly higher than that of Group B. In Group A, the patients had a CBR of 80.0% (28/35) after treatment, and 12 reached SD, of whom 11 had a SD duration of ≥ 6 months. In Group B, the patients had a CBR of 70.5% (31/44) after treatment, and 25 reached SD, of whom 22 had a SD duration of

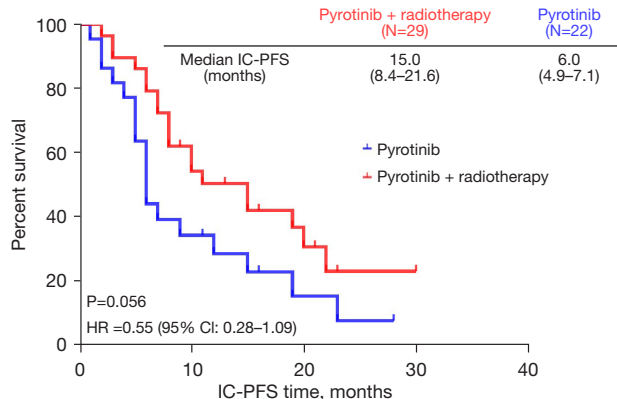


Figure 3 Median IC-PFS times of pyrotinib and radiotherapy vs. pyrotinib-based therapy for patients with active brain metastasis in the 2 groups. IC-PFS, intracranial progression-free survival; HR, hazard ratio; CI, confidence interval.

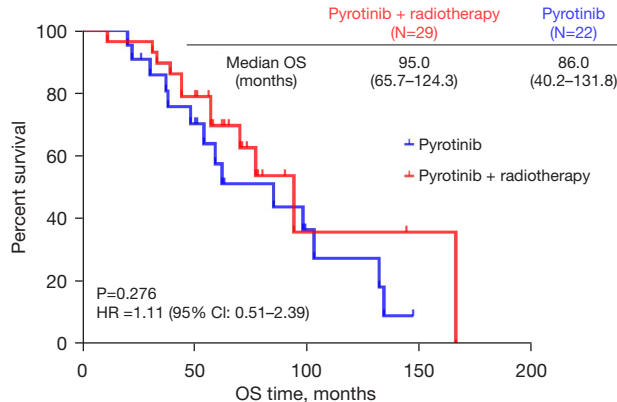


Figure 4 Median OS time of pyrotinib and radiotherapy vs. pyrotinib-based therapy for patients with active brain metastasis in the 2 groups. OS, overall survival; HR, hazard ratio; CI, confidence interval.

≥ 6 months. The CBR was similar between the 2 groups. See *Table 2* for further details.

The patients were followed-up until April 2022, and had a median follow-up period of 24.3 months. The median IC-PFS times were 15.0 months and 9.0 months in Group A and Group B, respectively (see *Figure 1*) ($P=0.385$). There was no statistically significant difference in OS between the 2 groups (see *Figure 2*) (95.0 vs. 98.0 months, $P=0.872$). The subgroup analysis demonstrated that for patients with active brain metastasis, the IC-PFS time of Group A was significantly longer than that of Group B (15.0 vs. 6.0 months, $P=0.056$) (see *Figure 3*). Among the patients

Table 3 Treatment-related adverse reactions in the 2 groups

Adverse reactions	Pyrotinib + radiotherapy, n (%)		Pyrotinib, n (%)	
	All grades	≥3	All grades	≥3
Acute brain edema	0	0	0	0
Cognitive dysfunction	0	0	0	0
Diarrhea	28 (80.0)	8 (22.9)	35 (79.5)	5 (11.4)
Nausea	18 (51.4)	0	20 (45.5)	3 (6.8)
Anemia	15 (42.9)	0	18 (40.9)	0
Hand-foot syndrome	10 (28.6)	1 (2.9)	15 (34.1)	2 (4.5)
Vomiting	17 (48.6)	2 (5.7)	22 (50.0)	3 (6.8)
Transaminases increased	12 (34.3)	1 (2.9)	13 (29.5)	0
Bilirubin increased	10 (28.6)	0	12 (27.3)	0
Neutrophils decreased	10 (28.6)	2 (5.7)	11 (25.0)	1 (2.3)
Platelet decreased	7 (20.0)	0	6 (13.6)	0
Fatigue	9 (25.7)	0	7 (15.9)	0

with active brain metastasis, patients in Group A had a longer OS time than those in Group B (95.0 *vs.* 86.0 months, $P=0.276$) (see *Figure 4*).

No serious adverse reactions, such as acute brain edema or cognitive dysfunction, were observed. The most common adverse reaction in Groups A and B was diarrhea (80% *vs.* 79.5%). A total of 40.0% (14/35) of patients in Group A and 31.8% (14/44) of patients in Group B had grade ≥ 3 adverse reactions. No treatment-related deaths occurred in Groups A or B, and the specific safety data are set out in *Table 3*.

Discussion

Breast cancer brain metastasis is currently the main factor threatening the life of BC patients. However, as most patients with BC brain metastasis are excluded from clinical trials for new drugs, relatively few studies on the treatment of BC with brain metastasis have been conducted (22). Thus, clinical research needs to be conducted to determine how to prolong the survival of BC patients with brain metastasis. This real-world study mainly comprised HER2⁺ BC patients with brain metastasis who had been treated with pyrotinib. It sought to determine the best treatment mode of drug therapy and brain radiotherapy, provide more treatment options for patients with brain metastasis, and improve the survival of HER2⁺ BC patients with brain

metastasis.

In this study, the CBR for intracranial lesions of Group A (80.0%) was significantly higher than that of Group B (70.5%), but the difference between the 2 groups was not statistically significant. In the PERMEATE trial (18), the CNS-ORR of pyrotinib combined with capecitabine in the treatment of BC patients with brain metastasis ranged from 42.1–74.6%. In the present study, Group A had an ORR of 48.6% and Group B had an ORR 20.5%, which are both lower than those previously reported. The difference in the results may be related to the fact that this was a retrospective, real-world study that included patients who had previously received brain radiotherapy and lapatinib. Alternately, the difference could also be related to the pyrotinib-based therapies administered in this study, which included pyrotinib alone, pyrotinib combined with endocrine therapy, and pyrotinib combined with chemotherapy (including capecitabine, paclitaxel, and etoposide). Our findings also indicate that pyrotinib combined with radiotherapy can be used to improve the local efficacy of intracranial lesions in patients with generally acceptable conditions.

In the PHENIX trial (17), the median PFS time of BC patients with brain metastasis treated with pyrotinib combined with capecitabine was 6.9 months. In the PERMEATE trial, the median PFS time of patients with

brain metastasis who was treated with pyrotinib combined with capecitabine was 5.6–11.3 months. In the present study, the median IC-PFS time of patients in Group B was 9.0 months, which is consistent with the existing research data. In this study, patients with brain metastasis treated with pyrotinib and radiotherapy concurrently were included in Group A. The median IC-PFS time of patients in Group A was 15.0 months, which was higher than that reported in previous studies (17,23).

To date, no previous studies have been conducted on patients who have been treated with pyrotinib combined with brain radiotherapy. However, previous studies have shown that radiotherapy has the effect of opening the blood-brain barrier and increasing the effectiveness of drugs (24,25). Research has yet to confirm whether radiotherapy increases the concentration of pyrotinib in the cerebrospinal fluid. In this study, there was no statistically significant difference in the IC-PFS time between Groups A and B ($P=0.79$). Pyrotinib combined with radiation therapy did not improve the local efficacy with breast cancer brain metastases of patients compared to pyrotinib. However, this was a retrospective study with a small sample size, and large prospective randomized controlled trials need to be conducted in the future to better understand the efficacy of pyrotinib combined with radiotherapy.

In the subgroup analysis of this study, the combination of pyrotinib and radiotherapy led to a significant improvement in IC-PFS time compared to pyrotinib-based therapy (15.0 *vs.* 6.0 months, $P=0.056$). The HERCLIMB trial on tucatinib (13) examined 291 patients with brain metastasis, of whom 174 had active brain metastasis. In the HERCLIMB trial, the median IC-PFS time of patients with active brain metastasis was 9.5 months, which was lower than that of patients in Group A in this study. The data of the 2 studies are not comparable, as different experimental drugs were used, but these findings could guide future research, as for patients with active brain metastasis, HER2-targeted therapy combined with radiotherapy appeared to have better local efficacy than the single drug treatment. More large-sample size studies need to be conducted to confirm these findings.

This is the first real-world study with OS data on the efficacy of pyrotinib and radiotherapy versus pyrotinib-based therapy. There was no significant difference in the OS between the 2 groups, indicating that pyrotinib combined with brain radiotherapy did not lead to any OS benefits. The subgroup analysis suggested that for patients with active brain metastasis, the OS of Group A was better than that of Group B (95.0 *vs.* 86.0 months), which indicates

that pyrotinib combined with radiotherapy might be more suitable for these patients. Conversely, for patients with stable brain metastasis, pyrotinib-based therapy did not affect the efficacy of the treatment, and at the same time can be better for reducing the burden of patients. More studies need to be conducted to identify the most suitable population for pyrotinib combined with radiotherapy and promote a precise diagnosis and treatment process.

Consistent with previously published data (23,26), in the safety analysis of this study, the most common adverse reaction was diarrhea. This retrospective real-world study explored the effects of targeted therapy combined with a radiotherapy. This study mainly focused on the intracranial-related adverse reactions of patients with brain metastasis. No acute brain edema, cognitive dysfunction, or other serious adverse reactions were observed in the 2 groups, indicating that the overall safety tolerance of pyrotinib in the treatment of BC with brain metastasis is acceptable, and the safety of HER2-targeted therapy combined radiotherapy is controllable.

The main strength of this study is that it is the first real-world study to explore the efficacy and safety of pyrotinib plus radiotherapy versus pyrotinib-based therapy. However, as this was a retrospective study with a small sample size, there are some biases and confounding factors in the results (e.g., this study did not control the mode and dose of radiotherapy to the brain and did not unify the pyrotinib-based therapy). These confounding factors may affect the survival of patients. In the future, the larger randomized controlled trials should be conducted to determine the best treatment mode for BC patients with brain metastasis to provide more treatment options for such patients.

Conclusions

Based on the results, pyrotinib combined with radiotherapy is recommended for HER2⁺ breast cancer active brain metastasis patients who can tolerate radiotherapy and pyrotinib. Pyrotinib-based therapy may be considered for patients who cannot tolerate radiotherapy and pyrotinib.

Acknowledgments

Funding: None.

Footnote

Reporting Checklist: The authors have completed the

STROBE reporting checklist. Available at <https://atm.amegroups.com/article/view/10.21037/atm-22-5352/rc>

Data Sharing Statement: Available at <https://atm.amegroups.com/article/view/10.21037/atm-22-5352/dss>

Conflicts of Interest: All authors have completed the ICMJE uniform disclosure form (available at <https://atm.amegroups.com/article/view/10.21037/atm-22-5352/coif>). The authors have no conflicts of interest to declare.

Ethical Statement: The authors are accountable for all aspects of the work in ensuring that questions related to the accuracy or integrity of any part of the work are appropriately investigated and resolved. The study was conducted in accordance with the Declaration of Helsinki (as revised in 2013). This study was reviewed and approved by the Ethics Committee of the Fifth Medical Center of Chinese PLA General Hospital (No. 2012L01067). All patients had given written informed consent.

Open Access Statement: This is an Open Access article distributed in accordance with the Creative Commons Attribution-NonCommercial-NoDerivs 4.0 International License (CC BY-NC-ND 4.0), which permits the non-commercial replication and distribution of the article with the strict proviso that no changes or edits are made and the original work is properly cited (including links to both the formal publication through the relevant DOI and the license). See: <https://creativecommons.org/licenses/by-nc-nd/4.0/>.

References

1. Choong GM, Cullen GD, O'Sullivan CC. Evolving standards of care and new challenges in the management of HER2-positive breast cancer. *CA Cancer J Clin* 2020;70:355-74.
2. Gabos Z, Sinha R, Hanson J, et al. Prognostic significance of human epidermal growth factor receptor positivity for the development of brain metastasis after newly diagnosed breast cancer. *J Clin Oncol* 2006;24:5658-63.
3. Martin AM, Cagney DN, Catalano PJ, et al. Brain Metastases in Newly Diagnosed Breast Cancer: A Population-Based Study. *JAMA Oncol* 2017;3:1069-77.
4. Costa R, Carneiro BA, Wainwright DA, et al. Developmental therapeutics for patients with breast cancer and central nervous system metastasis: current landscape and future perspectives. *Ann Oncol* 2017;28:44-56.
5. Brufsky AM, Mayer M, Rugo HS, et al. Central nervous system metastases in patients with HER2-positive metastatic breast cancer: incidence, treatment, and survival in patients from registHER. *Clin Cancer Res* 2011;17:4834-43.
6. Vogelbaum MA, Brown PD, Messersmith H, et al. Treatment for Brain Metastases: ASCO-SNO-ASTRO Guideline. *J Clin Oncol* 2022;40:492-516.
7. Hartgerink D, Bruynzeel A, Eekers D, et al. A Dutch phase III randomized multicenter trial: whole brain radiotherapy versus stereotactic radiotherapy for 4-10 brain metastases. *Neurooncol Adv* 2021;3:vdab021.
8. Slamon DJ, Leyland-Jones B, Shak S, et al. Use of chemotherapy plus a monoclonal antibody against HER2 for metastatic breast cancer that overexpresses HER2. *N Engl J Med* 2001;344:783-92.
9. Geyer CE, Forster J, Lindquist D, et al. Lapatinib plus capecitabine for HER2-positive advanced breast cancer. *N Engl J Med* 2006;355:2733-43.
10. Swain SM, Baselga J, Kim SB, et al. Pertuzumab, trastuzumab, and docetaxel in HER2-positive metastatic breast cancer. *N Engl J Med* 2015;372:724-34.
11. Verma S, Miles D, Gianni L, et al. Trastuzumab emtansine for HER2-positive advanced breast cancer. *N Engl J Med* 2012;367:1783-91.
12. Bachelot T, Romieu G, Campone M, et al. Lapatinib plus capecitabine in patients with previously untreated brain metastases from HER2-positive metastatic breast cancer (LANDSCAPE): a single-group phase 2 study. *Lancet Oncol* 2013;14:64-71.
13. Lin NU, Borges V, Anders C, et al. Intracranial Efficacy and Survival With Tucatinib Plus Trastuzumab and Capecitabine for Previously Treated HER2-Positive Breast Cancer With Brain Metastases in the HER2CLIMB Trial. *J Clin Oncol* 2020;38:2610-9.
14. Krop IE, Kim SB, Martin AG, et al. Trastuzumab emtansine versus treatment of physician's choice in patients with previously treated HER2-positive metastatic breast cancer (TH3RESA): final overall survival results from a randomised open-label phase 3 trial. *Lancet Oncol* 2017;18:743-54.
15. Mills MN, Walker C, Thawani C, et al. Trastuzumab Emtansine (T-DM1) and stereotactic radiation in the management of HER2+ breast cancer brain metastases. *BMC Cancer* 2021;21:223.
16. Saura C, Oliveira M, Feng YH, et al. Neratinib Plus Capecitabine Versus Lapatinib Plus Capecitabine in HER2-Positive Metastatic Breast Cancer Previously

- Treated With ≥ 2 HER2-Directed Regimens: Phase III NALA Trial. *J Clin Oncol* 2020;38:3138-49.
17. Yan M, Bian L, Hu X, et al. Pyrotinib plus capecitabine for human epidermal factor receptor 2-positive metastatic breast cancer after trastuzumab and taxanes (PHENIX): a randomized, double-blind, placebo-controlled phase 3 study. *Transl Breast Cancer Res* 2020;1:13.
 18. Yan M, Ouyang Q, Sun T, et al. Pyrotinib plus capecitabine for patients with human epidermal growth factor receptor 2-positive breast cancer and brain metastases (PERMEATE): a multicentre, single-arm, two-cohort, phase 2 trial. *Lancet Oncol* 2022;23:353-61.
 19. Xu B, Yan M, Ma F, et al. Pyrotinib plus capecitabine versus lapatinib plus capecitabine for the treatment of HER2-positive metastatic breast cancer (PHOEBE): a multicentre, open-label, randomised, controlled, phase 3 trial. *Lancet Oncol* 2021;22:351-60.
 20. Gao M, Fu C, Li S, et al. The efficacy and safety of pyrotinib in treating HER2-positive breast cancer patients with brain metastasis: A multicenter study. *Cancer Med* 2022;11:735-42.
 21. Lin Y, Lin M, Zhang J, et al. Real-World Data of Pyrotinib-Based Therapy in Metastatic HER2-Positive Breast Cancer: Promising Efficacy in Lapatinib-Treated Patients and in Brain Metastasis. *Cancer Res Treat* 2020;52:1059-66.
 22. Bailleux C, Eberst L, Bachelot T. Treatment strategies for breast cancer brain metastases. *Br J Cancer* 2021;124:142-55.
 23. Ma F, Ouyang Q, Li W, et al. Pyrotinib or Lapatinib Combined With Capecitabine in HER2-Positive Metastatic Breast Cancer With Prior Taxanes, Anthracyclines, and/or Trastuzumab: A Randomized, Phase II Study. *J Clin Oncol* 2019;37:2610-9.
 24. Fauquette W, Amourette C, Dehouck MP, et al. Radiation-induced blood-brain barrier damages: an in vitro study. *Brain Res* 2012;1433:114-26.
 25. Stemmler H-J, Schmitt M, Willems A, et al. Ratio of trastuzumab levels in serum and cerebrospinal fluid is altered in HER2-positive breast cancer patients with brain metastases and impairment of blood-brain barrier. *Anticancer Drugs* 2007;18:23-8.
 26. Ma F, Li Q, Chen S, et al. Phase I Study and Biomarker Analysis of Pyrotinib, a Novel Irreversible Pan-ErbB Receptor Tyrosine Kinase Inhibitor, in Patients With Human Epidermal Growth Factor Receptor 2-Positive Metastatic Breast Cancer. *J Clin Oncol* 2017;35:3105-12.
- (English Language Editor: L. Huleatt)

Cite this article as: Chen J, Zhang H, Zhou J, Wu Z, Wu X, Zhang S, Jiang Z, Wang T. Efficacy and safety of pyrotinib and radiotherapy *vs.* pyrotinib-based therapy in patients with HER2⁺ breast cancer with brain metastasis: a retrospective cohort study. *Ann Transl Med* 2022;10(22):1228. doi: 10.21037/atm-22-5352