

Morphological changes in Parkinson's disease based on magnetic resonance imaging: A mini-review of subcortical structures segmentation and shape analysis

Jin-Huan Deng, Han-Wen Zhang, Xiao-Lei Liu, Hua-Zhen Deng, Fan Lin

Specialty type: Radiology, nuclear medicine and medical imaging

Provenance and peer review:

Unsolicited article; Externally peer reviewed.

Peer-review model: Single blind

Peer-review report's scientific quality classification

Grade A (Excellent): 0
Grade B (Very good): B
Grade C (Good): C
Grade D (Fair): 0
Grade E (Poor): 0

P-Reviewer: Aydin S, Turkey;
Gokce E, Turkey

Received: August 23, 2022

Peer-review started: August 23, 2022

First decision: October 21, 2022

Revised: November 2, 2022

Accepted: November 21, 2022

Article in press: November 21, 2022

Published online: December 19, 2022



Jin-Huan Deng, Han-Wen Zhang, Xiao-Lei Liu, Hua-Zhen Deng, Fan Lin, Department of Radiology, The First Affiliated Hospital of Shenzhen University, Health Science Center, Shenzhen Second People's Hospital, Shenzhen 518035, Guangdong Province, China

Corresponding author: Fan Lin, MD, Professor, Department of Radiology, The First Affiliated Hospital of Shenzhen University, Health Science Center, Shenzhen Second People's Hospital, No. 3002 Sungangxi Road, Shenzhen 518035, Guangdong Province, China.

foxetfoxet@gmail.com

Abstract

Parkinson's disease (PD) is a neurodegenerative disorder caused by the loss of dopaminergic neurons in the substantia nigra, resulting in clinical symptoms, including bradykinesia, resting tremor, rigidity, and postural instability. The pathophysiological changes in PD are inextricably linked to the subcortical structures. Shape analysis is a method for quantifying the volume or surface morphology of structures using magnetic resonance imaging. In this review, we discuss the recent advances in morphological analysis techniques for studying the subcortical structures in PD *in vivo*. This approach includes available pipelines for volume and shape analysis, focusing on the morphological features of volume and surface area.

Key Words: Parkinson's disease; Dopaminergic neurons; Magnetic resonance imaging; Substantia nigra; Morphological

©The Author(s) 2022. Published by Baishideng Publishing Group Inc. All rights reserved.

Core Tip: Parkinson's disease (PD) is a neurodegenerative disorder caused by the loss of dopaminergic neurons in the substantia nigra, resulting in clinical symptoms, including bradykinesia, resting tremor, rigidity, and postural instability. The pathophysiological changes in PD are inextricably linked to the subcortical structures. Shape analysis is a method for quantifying the volume or surface morphology of structures using magnetic resonance imaging. In this review, we discuss the recent advances in morphological analysis techniques for studying the subcortical structures in PD *in vivo*. This approach includes available pipelines for volume and shape analysis, focusing on the morphological features of volume and surface area.

Citation: Deng JH, Zhang HW, Liu XL, Deng HZ, Lin F. Morphological changes in Parkinson's disease based on magnetic resonance imaging: A mini-review of subcortical structures segmentation and shape analysis. *World J Psychiatry* 2022; 12(12): 1356-1366

URL: <https://www.wjgnet.com/2220-3206/full/v12/i12/1356.htm>

DOI: <https://dx.doi.org/10.5498/wjp.v12.i12.1356>

INTRODUCTION

Parkinson's disease (PD) is the second most common neurodegenerative disorder after Alzheimer's disease. It is primarily caused by the loss of dopaminergic neurons in the substantia nigra. The classical clinical symptoms of PD include movement symptoms such as bradykinesia, resting tremor, rigidity, and postural instability. Recent studies have shown that symptoms of PD extend beyond motricity and include cognitive and neuropsychiatric symptoms. Non-motor symptoms can be identified at all stages, even before the appearance of motor symptoms[1]. In addition to clinical markers, PD biomarkers include neuroimaging, genetic, and biochemical markers[2]. This review focuses primarily on the use of neuroimaging in PD.

The main pathological features of PD are the degeneration of dopaminergic neurons in the substantia nigra and deposition of Lewy bodies, leading to pathophysiological changes in the downstream basal ganglia circuits. The basal ganglia system includes the striatum, globus pallidus, and structures with functional connections to the striatum, including the subthalamic nucleus, substantia nigra, and red nucleus.

Magnetic resonance imaging (MRI) is one of the most useful noninvasive techniques for examining intracranial structures, showing macroscopic alterations of the subcortical structures, and can visualize their volume and surface morphology. Therefore, MRI-based morphological analysis of the subcortical structures has the potential to be a prominent diagnostic neuroimaging marker for PD. This review focuses on the shape analysis of the striatum, thalamus, and hippocampus, which has been mostly discussed in previous studies.

METHODS

A literature search was conducted for relevant studies using four databases: PubMed, Web of Science, Google Scholar, and Scopus. The key search terms in the different combinations were "Parkinson's disease, shape analysis, subcortical structures, striatum, thalamus, and hippocampus." The final search was conducted on October 25, 2022.

The inclusion criteria were the studies that included: (1) A background or introduction on PD; (2) the clinical criteria of PD; (3) an introduction to methods of the subcortical structure segmentation; (4) shape analysis of the subcortical or cortical structures; and (5) data utilization of structural MRI sequences.

We excluded studies based on the following exclusion criteria: (1) Articles published in languages other than English; (2) animal model or theoretical articles; (3) studies with a sample size of < 10 patients; (4) studies whose methodology did not involve volumetric or shape analysis; and (5) review or meta-analysis articles of shape analysis.

RESULTS

Figure 1 shows a flowchart of the study selection. This review included 69 references, of which 2 provided a background/introduction on PD, 5 referred to the segmentation methods, and 62 to the morphology of the subcortical or cortical structures in PD. Subcortical structures mainly included the striatum, thalamus, and hippocampus. Further information on the structures and morphological changes is provided in Table 1.

Table 1 Morphological studies in Parkinson's disease

Subcortical structures	Ref.	Segmentation methods	Analysis type	Results
Striatum	Geng <i>et al</i> [12], 2006; Pitcher <i>et al</i> [10], 2012; Owens-Walton <i>et al</i> [11], 2018	Manual	Volume	Reduced volume of bilateral caudate and putamen nuclei
	Sterling <i>et al</i> [13], 2013	Semi-automatic	Volume	Reduced volume of bilateral caudate and putamen nuclei
	Geevarghese <i>et al</i> [15], 2015; Vasconcellos <i>et al</i> [17], 2018; Tanner <i>et al</i> [16], 2017; Melzer <i>et al</i> [30], 2012	Automatic	Volume	Reduced volume of bilateral caudate nuclei
	Oltra <i>et al</i> [35], 2022	Automatic	Volume	Reduced volume of bilateral caudate nuclei (with RBD)
	Lee <i>et al</i> [14], 2014; Garg <i>et al</i> [20], 2015	Automatic	Volume	Reduced volume of bilateral putamen nuclei
	Garg <i>et al</i> [20], 2015	Automatic	Volume	Reduced volume of right putamen nuclei
	Kamps <i>et al</i> [33], 2019	Automatic	Volume	Reduced volume of right putamen nuclei (with RBD severity)
	Kluger <i>et al</i> [34], 2019	Automatic	Volume	Reduced volume of dorsal striatum (with fatigue)
	Messina <i>et al</i> [18], 2011; Menke <i>et al</i> [19], 2014; Nemmi <i>et al</i> [21], 2015; Khan <i>et al</i> [22], 2019; Gong <i>et al</i> [32], 2019	Automatic	Volume	No significant difference in bilateral striatum
	Chung <i>et al</i> [31], 2017	Automatic	Volume	Locally reduction of right caudate nuclei
	Devignes <i>et al</i> [28], 2021	Automatic	Shape	Locally reduction of left caudate nuclei (with cognition)
	Garg <i>et al</i> [20], 2015	Automatic	Shape	Locally reduction of right putamen nuclei
	Gong <i>et al</i> [32], 2019	Automatic	Shape	Locally reduction of bilateral caudate and right putamen nuclei (with RBD)
	Tanner <i>et al</i> [16], 2017	Automatic	Shape	Locally reduction of the lateral and medial caudate nuclei
	Sterling <i>et al</i> [13], 2013	Semi-Automatic	Shape	Locally reduction of the head and dorsal body of caudate nuclei
	Nemmi <i>et al</i> [21], 2015	Automatic	Shape	Locally reduction of the medial surface of left caudate nuclei (with the right UPDRS)
	Tanner <i>et al</i> [16], 2017	Automatic	Shape	Locally reduction of the medial surface of putamen nuclei
	Sterling <i>et al</i> [13], 2013	Semi- Automatic	Shape	Locally reduction of the caudal and ventrolateral putamen nuclei
	Sigirli <i>et al</i> [23], 2021	Automatic	Shape	Locally reduction of the middle-posterior of right putamen nuclei
	Lee <i>et al</i> [14], 2014	Automatic	Shape	Locally reduction of the posterolateral and ventromedial putamen nuclei
Nemmi <i>et al</i> [21], 2015	Automatic	Shape	Locally reduction of the lateral and medial posterior putamen nuclei (with UPDRS)	
Khan <i>et al</i> [22], 2019	Automatic	Shape	Locally reduction of the caudal-motor and rostral-motor sub-regions	
Thalamus	McKeown <i>et al</i> [43], 2008	Manual	Volume	No significant difference
	Garg <i>et al</i> [20], 2015	Automatic	Volume	Significant difference
	Vasconcellos <i>et al</i> [17], 2018; Mak <i>et al</i> [26], 2014; Sivaranjini <i>et al</i> [27], 2021; Foo <i>et al</i> [45], 2017	Automatic	Volume	Reduced volume of bilateral thalamus
	Nicolini <i>et al</i> [46], 2019	Automatic	Volume	Reduced volume of bilateral thalamus (with non-motor symptom)

	Kamps <i>et al</i> [33], 2019	Automatic	Volume	Reduced volume of left thalamus (with RBD)
	Chen <i>et al</i> [44], 2020	Automatic	Volume	Increased volume (20) of right subnuclei
	Chen <i>et al</i> [44], 2020	Automatic	Volume	Increased volume (21), reduced volume (2) of left subnuclei
	Kaya <i>et al</i> [40], 2019	Manual	Shape	Locally reduction of the dorsolateral of bilateral STN
	Devignes <i>et al</i> [28], 2021	Automatic	Shape	Locally reduction of right thalamus (with cognition)
	Chung <i>et al</i> [31], 2017	Automatic	Shape	Locally reduction of bilateral thalamus (with cognition)
	McKeown <i>et al</i> [43], 2008	Automatic	Shape	Locally reduction of the dorsal surface of bilateral thalamus
	Garg <i>et al</i> [20], 2015	Automatic	Shape	Net-inward and outward deformation of left thalamus
Hippocampus				
	Wang <i>et al</i> [55], 2018	Automatic	Volume	Reduced volume of right hippocampus
	Chen <i>et al</i> [56], 2016	Automatic	Density	Reduced density of left hippocampus
	Geevarghese <i>et al</i> [15], 2015	Automatic	Volume	Reduced volume of left hippocampus (with cognition)
	Lee <i>et al</i> [14], 2014; Tanner <i>et al</i> [16], 2017; Radziunas <i>et al</i> [53], 2018; Melzer <i>et al</i> [30], 2012	Automatic	Volume	Reduced volume of bilateral hippocampus
	Vasconcellos <i>et al</i> [17], 2018	Automatic	Volume	Reduced volume of bilateral hippocampus (with disease duration)
	Camlidag <i>et al</i> [68], 2014; Xu <i>et al</i> [59], 2020	Automatic	Volume	Reduced volume of bilateral hippocampus (with cognition)
	van Mierlo <i>et al</i> [64], 2015	Automatic	Volume	Reduced volume of bilateral hippocampus (with depression)
	Rahayel[63], 2019	Automatic	Volume	Reduced volume of bilateral hippocampus (with REM-RBD)
	Wilson <i>et al</i> [54], 2019	Automatic	Volume	Reduced volume of bilateral hippocampus (with cognition, motor and disease duration)
	Luo <i>et al</i> [60], 2021	Automatic	Volume	Reduced volume of subfields (with cognition)
	Uribe <i>et al</i> [61], 2018	Automatic	Volume	Reduced volume of subfields, especially CA1
	Becker <i>et al</i> [62], 2021	Automatic	Volume	Reduced volume of CA1 (with cognition)
	Xu <i>et al</i> [59], 2020	Automatic	Volume	Reduced volume of subiculum, CA2/3, CA4, ML and right GC-DG
	Park <i>et al</i> [57], 2019	Automatic	Volume	Volume asymmetry, especially in CA4-DG and CA2-3
	Tanner <i>et al</i> [16], 2017	Automatic	Shape	Locally reduction in the head and CA1 bilaterally
	Devignes <i>et al</i> [28], 2021	Automatic	Shape	Locally reduction of right hippocampus (with cognition)

REM: Rapid eye movement; RBD: Sleep behavior disorder; STN: Subthalamic nucleus; CA: Cornu ammonis (subfields of hippocampus); ML: Molecular layer subfields; GC-DG: Granule cell layer of the dentate gyrus.

Parkinson's disease

The Movement Disorders Society (MDS) has proposed the main diagnostic criteria for PD in clinical settings[3]. The recent version of the MDS diagnostic criteria considers three stages in the progression of PD: Preclinical, prodromal, and clinical. Clinical PD can be diagnosed when typical motor symptoms occur. Neurodegeneration may occur in patients with PD before they reach the clinical stage[3]. Previous studies have been mostly conducted based on clinical diagnosis; therefore, this review focuses

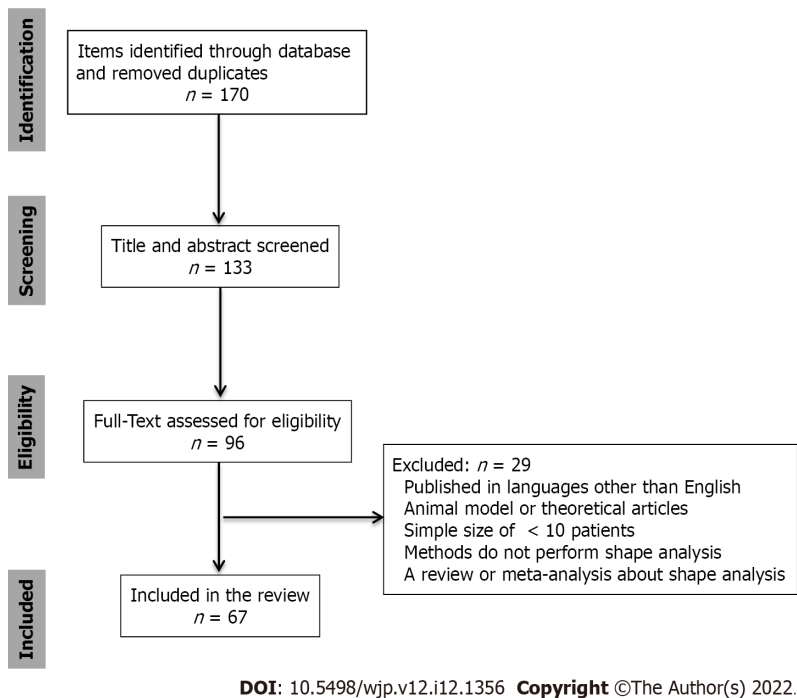


Figure 1 A flowchart of the study selection.

on PD in the clinical stage. The striatum is one of the most affected structures in the nigrostriatal pathway because of the degeneration of dopaminergic neurons. In addition to the striatum, neurons in the substantia nigra project to other basal nuclei, such as the pallidum, substantia nigra, and thalamic nucleus basalis. A decrease in dopamine levels may cause the structural and morphological changes observed in PD.

MRI allows noninvasive observation of morphological changes in the subcortical structures in patients with PD to find changes in neuroimaging characteristics. Hence, it may help in clinical intervention, especially in the preclinical or prodromal stages of the disease. However, the naked eye cannot identify subtle changes in structures; hence, quantitative analysis using a computer may help determine the presence or absence of morphological changes in these structures. Segmentation of subcortical structures based on the images is the prerequisite to performing an accurate analysis. The following sections describe the common segmentation methods and the results of morphological analyses of the subcortical structures obtained from previous studies.

Methods of segmentation

Both manual and automatic segmentation have been used in recent studies. Manual segmentation, usually the gold-standard approach for automatic segmentation, is a tedious and time-consuming task that depends on the subjectivity of the physician. Therefore, many investigators have used publicly available automated segmentation software for efficiency and objectivity. Automatic segmentation methods include voxel-based morphometry (VBM) and surface-based morphometry (SBM). The tools used for segmentation in most studies include FSL and FreeSurfer, among others. The FIRST software, distributed with the FSL package, is a tool that employs manually labeled image data to offer anatomical training information for 15 different subcortical regions using 336 manually labeled T1-weighted MRI images[4]. FreeSurfer is a suite of tools for extensive automated analysis of key features in the human brain that can be used in most MRI sequences and provides an accurate geometric surface model[5]. By minimizing the difference between the original image and the converted target image, large deformation diffeomorphic metric mapping (LDDMM) creates a differential homogenous transformation that has its own inherent smoothness and simulated displacement size. It is often applied in the object-matching segment of medical imaging data processing[6]. This review focuses on the morphological analysis of subcortical structures in PD using the techniques mentioned above in recent years.

Several scholars have compared the effects of manual and automatic segmentation. For the hippocampus and amygdala, segmentation using VBM and FreeSurfer is performed at a level comparable to manual segmentation[7]. In another study, automated segmentation revealed different degrees of variability in the subcortical structures compared to manual segmentation, with particularly pronounced differences found in the FreeSurfer and FSL pipelines for the pallidum and thalamus[8]. From these studies, it can be seen that the efficiency of automatic segmentation is comparable to that of manual segmentation. Automatic methods save more time and display better segmentation results,

which could be used in the shape analysis of the subcortical structures in patients with PD.

Shape analysis of the striatum

The striatum is a critical component of the brain that controls the motor, reward, and executive functions, and dopamine serves as an important mediator[9]. Decreased dopamine levels have the greatest impact on striatal structures in patients with PD. Several studies have segmented the striatum by manual segmentation of T1-weighted MRI images for its morphology, showing that the volume of the caudate nucleus or putamen was smaller in patients than in normal controls[10,11]. In addition, studies using automatic segmentation showed the same results as those using manual segmentation of the volume of the caudate nucleus and putamen[12-17]. However, some studies have found no significant difference in striatum volume between patients with PD and normal controls[18-21]. Studies that performed further surface morphometric analyses under automated shape analyses showed: (1) A regional contraction of the posterolateral and ventromedial putamen bilaterally in patients with PD[14]; (2) areas of local atrophy in the lateral and medial posterior parts of the bilateral putamen; (3) atrophy locally on the medial surface of the left caudate nucleus[21]; and (4) a reduction in the volume and an inward displacement of the surface of the caudal motor striatum[22]. Studies using other machine learning methods have also found local atrophy in the caudate and putamen nuclei, including the caudal portion of the putamen or the middle-posterior putamen and the head of the caudate[13,23]. A study attempted to distinguish different stages of PD based solely on the shape analysis of the bilateral caudate nucleus and putamen through an automated process, with balanced accuracies in the range of 59%-85%[24].

Dysfunction of the basal ganglia plays a key role in developing motor and non-motor symptoms in PD[25]. When exploring the relationship between volume and symptoms, several studies have shown that greater atrophy of the caudate and putamen in PD is usually associated with more severe motor symptoms and cognitive impairment[11,17,26-28]. Additionally, some correlation analyses did not find a significant correlation between striatal volume and cognitive or motor symptoms[10].

Local morphological analyses provided more details; local atrophy in the left putamen and thalamus correlated with the right Unified Parkinson Disease Rating Scale (UPDRS) motor scale score, which is the most widely used scale for the clinical studies of PD[21,29]. A previous study identified PD with mild cognitive impairment (PD-MCI) with limited atrophy of the right putamen[30]. When PD-MCI converted to dementia, smaller local shape volumes were found in the right caudate nucleus of the patients compared to that of patients with PD-MCI who did not convert[31]. In addition, logistic regression analysis indicated that the local shape volumes in the right caudate nucleus were significant independent predictors of conversion to dementia in patients with PD-MCI. Distinct structural changes in the caudate and/or putamen are associated with performance in the attention or working memory domain, fatigue, the severity of rapid eye movement (REM) sleep behavior disorder (RBD), and excessive daytime sleepiness[26,32-35].

Specifically, volume atrophy of the left caudate nucleus or right putamen was found to be more pronounced in the patient cohort[11,23], which may be due to disease lateralization. Previous studies have shown that the decrease in dopamine capacity in the striatum is more pronounced in the contralateral hemisphere on the side with more severe clinical symptoms of PD[36]. It has been suggested that the onset of motor symptoms may always occur in one limb, and morphological analysis has revealed a greater degree of striatal atrophy on the contralateral side of the limb where motor symptoms occur[16]. Local deformation of the posterior side of the putamen has been reported in several articles. According to the literature, the posterior putamen is directly related to the sensorimotor cortex and is preferentially affected; dopamine depletion is mainly located in this region of the basal ganglia[10,23,37,38]. Therefore, we can also infer that the morphological changes in PD can be detected using MRI. Furthermore, we may be able to assess the severity of some symptoms, such as cognitive function in patients with PD, and provide timely interventions for clinical treatment.

Shape analysis of the thalamus

The thalamus is composed of several nuclei that regulate various motor and sensory functions and is usually divided into seven nuclei: The anterior, lateral, ventral, intralaminar, medial, and posterior nuclear groups and the reticular nucleus. Among the nuclei of the thalamus, the ventral thalamus, also known as the subthalamic nucleus (STN), plays an important role in extrinsic inputs reaching the basal ganglia circuitry[39]. A study calculated the morphological changes in the STN and found statistically significant differences in the shape of bilateral STN between the PD and control groups, with the largest deformation site located in the dorsolateral parts of bilateral STNs[40]. Patriat *et al*[41] showed that the volume of STN was smaller in PD patients compared to healthy controls, which was further validated in the field of 7T MRI. Although thalamic degeneration may represent a site of dopaminergic degeneration in PD, the thalamus is also influenced by hyperactivity in glutamatergic signaling, which may be caused by the loss of dopaminergic neurons in the substantia nigra and striatum[42]. Thus, various morphological changes occur in the thalamus of patients with PD. Furthermore, several studies on structural and functional imaging have identified morphological or functional changes in the thalamus in patients with PD. Using manual segmentation, scholars found no significant difference in the thalamus volume between patients with PD and healthy controls[43]. They used spherical harmonic-based representation

methods and detected significant differences in shape[43]. A previous study subdivided the left and right thalamus into 25 subnuclei using automatic methods. It was detected that 21 of the left and 20 of the right thalamic subnuclei had increased volume, accompanied by atrophy in two left subnuclei[44].

More studies have been conducted to correlate thalamic shape changes with clinical symptoms. Nemmi *et al*[21] found a significant correlation between local atrophy of the right thalamus and the UPDRS using FSL scripts. However, one study found that surface morphological changes in the thalamus were not associated with disease severity in UPDRS using FreeSurfer segmentation with LDDMM alignment[20]. This may be due to differences in segmentation methods and cohort sizes, and the influence of glutamatergic neurons on thalamic morphology requires further investigation.

Moreover, most studies have concluded that altered thalamic morphology is associated with non-motor symptoms. Several studies have found a relationship between reduced thalamic volume and poor cognitive function in patients with PD[17,26-28,45]. A more detailed correlation analysis showed that the local shape volume of the bilateral thalamus was a significant independent predictor of the conversion of MCI to dementia. However, the local shape volume of the thalamus was associated with semantic fluency and attentional composite scores[31]. In addition, some scholars have found that the severity of other non-motor symptoms in patients with PD is associated with more pronounced thalamic atrophy. Furthermore, they found that such non-motor symptoms include sleep, fatigue, gastrointestinal dysfunction, and REM-RBD[32,46].

The thalamus, one of the output nuclei of the basal ganglia, is markedly affected by dopaminergic and glutamatergic neuronal degeneration. For living subjects, imaging is potentially one of the most practical tools to detect changes in the thalamus. Precise shape analysis shows that the thalamus in PD undergoes major or minor changes. Compared to manual measurements, accurate automated measurements reflect more pronounced variation and more detailed results. Because of the varying progression of neuronal degeneration, thalamus shape analysis in patients with PD presents differently. Hence, future studies using the same methods and similar cohort sizes may show better consistency. Moreover, several studies have demonstrated the relevance of shape alterations and symptoms, especially non-motor symptoms, probably because the thalamic subnuclei play an important role in the transmission of dopaminergic neuronal pathways. However, the sequence in which the onset of symptoms and the changes within the thalamus occur is still unclear. In addition, abnormal STN activity may be associated with motor dysfunction in PD; however, further studies are needed to confirm the relationship between STN shape changes and motor symptoms.

Shape analysis of the hippocampus

As a subcortical structure, the hippocampus is an important brain region that carries the body's cognitive functions and is closely related to learning ability, memory, and emotion regulation. Cognitive impairment is frequently seen in PD; thus, the hippocampus may be an imaging marker of cognitive impairment[47]. Scholars have found a reduction in hippocampal gray matter density or thickness through automatic methods in the elderly or patients with cognitive impairment, especially in the CA1, which is one of the four hippocampal subfields called the cornu ammonis[48-52]. Several studies on hippocampal morphology have been conducted in patients with PD and normal controls. Using automatic shape analysis, some studies have shown smaller hippocampal volumes in patients with PD than in controls[16,17,30,53-55]. There were also reduced local volumes of the hippocampus in patients with cognitive impairment compared with those without cognitive impairment, including the subfields CA1-4[28,30,31,54-62]. Studies have shown that the development of REM-RBD and depression may be associated with a smaller hippocampal volume[33,63,64]. This suggests a close relationship between hippocampal atrophy and cognitive function, in which the CA1 may be one of the most notable subfields.

The hippocampus is the main source of cholinergic input to the cerebral cortex, and most studies have shown that the hippocampal volume shrinks in patients with PD. Hippocampal shape analysis has focused on non-motor symptoms in PD, primarily the cognitive function, which matches the function of the hippocampus. The relationship between hippocampal atrophy and cognitive decline has been confirmed in patients with PD in the majority of studies. However, recent studies mostly showed volume results; thus, the surface morphological analysis may be able to link hippocampal subregions to specific symptoms of cognitive impairment further. The relationship between morphological changes and other symptoms, such as REM-RBD and depression, warrants further investigation.

Furthermore, a large number of studies are also using these automated pipelines to analyze cortical structures in PD. Cerebral cortices are key to human activity and may be altered as a result of unusual activity in PD, such as thinning. Most studies have found atrophy in various parts of the cortex in patients with cognitive impairment. In a longitudinal study, Garcia-Diaz *et al*[65] confirmed the thinning of cortical thickness in PD patients with cognitive impairment *vs* those without. Among some symptoms related to the cerebral cortex, Vignando *et al*[66] reported a general reduction in occipital, parietal, temporal, frontal, and limbic cortical thickness in patients experiencing hallucinations. Changes in visuospatial and visual supraprereceptual impairment also correlated with cortical thinning in occipital, parietal, and temporal regions in the study by Garcia-Diaz *et al*[65]. As for motor symptoms, through the calculation of surface area in a study of PD gait disorders, Wei *et al*[67] found that the larger the surface areas of the left lateral temporal cortex and right inferior parietal cortex, the worse the gait

performance.

This review focuses on the results of patients on 3T instruments, and participants were scanned using a 1.5T MRI instrument and used manual planar measurements, revealing that the normalized STN and red nuclei volumes were larger in patients with PD than in controls[68]. Similarly, 7TMRI imaging revealed atrophy of the overall prefrontal cortex and hippocampus, as well as a reduction in STN volume, for patients with PD[41,69]. Although current studies on 7TMRI have focused only on volumetric rather than morphological changes, higher resolution instruments can help us to detect finer structural changes and conduct more structural studies.

CONCLUSION

Methods for the shape analysis of subcortical structures based on MRI data are becoming increasingly diverse and refined, allowing even minor changes to be detected. This study has reviewed previous research on the application of these techniques in PD. In contrast to manual measurements, most studies employ computational methods to maintain objectivity. Volume atrophy can be found in most structures, including the subcortical and cortical areas. Surface-based morphometry detects structural changes that can be associated with clinical symptoms. We found that pathophysiological changes in PD are closely associated with changes in the subcortical structures and that different sub-structural alterations are consistent with specific clinical phenotypes. Therefore, the shape analysis of the subcortical structures can be used as an imaging biological indicator of PD, helping to explain associated clinical symptoms.

FOOTNOTES

Author contributions: Authors' contributions: Lin F contributed to the conception of the study; Zhang HW, Liu XL, and Deng HZ contributed significantly to analysis and manuscript preparation; Deng JH and Zhang HW performed the data analyses and wrote the manuscript; Zhang HW and Deng JH contributed equally to this study.

Supported by the Guangdong Basic and Applied Basic Research Foundation, No. 2021A1515220131; Youth Exploration Fund of Shenzhen Health Economics Society, No. 202211; and Clinical Research Project of Shenzhen Second People's Hospital, No. 223375022.

Conflict-of-interest statement: The authors declare that they have no conflicts of interest.

Open-Access: This article is an open-access article that was selected by an in-house editor and fully peer-reviewed by external reviewers. It is distributed in accordance with the Creative Commons Attribution NonCommercial (CC BY-NC 4.0) license, which permits others to distribute, remix, adapt, build upon this work non-commercially, and license their derivative works on different terms, provided the original work is properly cited and the use is non-commercial. See: <https://creativecommons.org/licenses/by-nc/4.0/>

Country/Territory of origin: China

ORCID number: Han-Wen Zhang 0000-0001-5731-7429; Fan Lin 0000-0003-1595-2736.

S-Editor: Chen YL

L-Editor: A

P-Editor: Chen YL

REFERENCES

- 1 **Pfeiffer RF.** Non-motor symptoms in Parkinson's disease. *Parkinsonism Relat Disord* 2016; **22** Suppl 1: S119-S122 [PMID: 26372623 DOI: 10.1016/j.parkreldis.2015.09.004]
- 2 **Delenclos M,** Jones DR, McLean PJ, Uitti RJ. Biomarkers in Parkinson's disease: Advances and strategies. *Parkinsonism Relat Disord* 2016; **22** Suppl 1: S106-S110 [PMID: 26439946 DOI: 10.1016/j.parkreldis.2015.09.048]
- 3 **Berg D,** Postuma RB, Adler CH, Bloem BR, Chan P, Dubois B, Gasser T, Goetz CG, Halliday G, Joseph L, Lang AE, Liepelt-Scarfone I, Litvan I, Marek K, Obeso J, Oertel W, Olanow CW, Poewe W, Stern M, Deuschl G. MDS research criteria for prodromal Parkinson's disease. *Mov Disord* 2015; **30**: 1600-1611 [PMID: 26474317 DOI: 10.1002/mds.26431]
- 4 **Patenaude B,** Smith SM, Kennedy DN, Jenkinson M. A Bayesian model of shape and appearance for subcortical brain segmentation. *Neuroimage* 2011; **56**: 907-922 [PMID: 21352927 DOI: 10.1016/j.neuroimage.2011.02.046]
- 5 **Fischl B.** FreeSurfer. *Neuroimage* 2012; **62**: 774-781 [PMID: 22248573 DOI: 10.1016/j.neuroimage.2012.01.021]
- 6 **Beg MF,** Miller MI, Trounev A, Younes L. Computing large deformation metric mappings via geodesic flows of diffeomorphisms. *Int J Comput Vis* 2005; **61**: 139-57 [DOI: 10.1023/B:VISI.0000043755.93987.aa]

- 7 **Grimm O**, Pohlack S, Cacciaglia R, Winkelmann T, Plichta MM, Demirakca T, Flor H. Amygdalar and hippocampal volume: A comparison between manual segmentation, Freesurfer and VBM. *J Neurosci Methods* 2015; **253**: 254-261 [PMID: 26057114 DOI: 10.1016/j.jneumeth.2015.05.024]
- 8 **Makowski C**, Béland S, Kostopoulos P, Bhagwat N, Devenyi GA, Malla AK, Joobar R, Lepage M, Chakravarty MM. Evaluating accuracy of striatal, pallidal, and thalamic segmentation methods: Comparing automated approaches to manual delineation. *Neuroimage* 2018; **170**: 182-198 [PMID: 28259781 DOI: 10.1016/j.neuroimage.2017.02.069]
- 9 **Grillner S**, Robertson B, Stephenson-Jones M. The evolutionary origin of the vertebrate basal ganglia and its role in action selection. *J Physiol* 2013; **591**: 5425-5431 [PMID: 23318875 DOI: 10.1113/jphysiol.2012.246660]
- 10 **Pitcher TL**, Melzer TR, Macaskill MR, Graham CF, Livingston L, Keenan RJ, Watts R, Dalrymple-Alford JC, Anderson TJ. Reduced striatal volumes in Parkinson's disease: a magnetic resonance imaging study. *Transl Neurodegener* 2012; **1**: 17 [PMID: 23210661 DOI: 10.1186/2047-9158-1-17]
- 11 **Owens-Walton C**, Jakabek D, Li X, Wilkes FA, Walterfang M, Velakoulis D, van Westen D, Looi JCL, Hansson O. Striatal changes in Parkinson disease: An investigation of morphology, functional connectivity and their relationship to clinical symptoms. *Psychiatry Res Neuroimaging* 2018; **275**: 5-13 [PMID: 29555381 DOI: 10.1016/j.psychres.2018.03.004]
- 12 **Geng DY**, Li YX, Zee CS. Magnetic resonance imaging-based volumetric analysis of basal ganglia nuclei and substantia nigra in patients with Parkinson's disease. *Neurosurgery* 2006; **58**: 256-62; discussion 256 [PMID: 16462479 DOI: 10.1227/01.NEU.0000194845.19462.7B]
- 13 **Sterling NW**, Du G, Lewis MM, Dimaio C, Kong L, Eslinger PJ, Styner M, Huang X. Striatal shape in Parkinson's disease. *Neurobiol Aging* 2013; **34**: 2510-2516 [PMID: 23820588 DOI: 10.1016/j.neurobiolaging.2013.05.017]
- 14 **Lee HM**, Kwon KY, Kim MJ, Jang JW, Suh SI, Koh SB, Kim JH. Subcortical grey matter changes in untreated, early stage Parkinson's disease without dementia. *Parkinsonism Relat Disord* 2014; **20**: 622-626 [PMID: 24703894 DOI: 10.1016/j.parkreldis.2014.03.009]
- 15 **Geevarghese R**, Lumsden DE, Hulse N, Samuel M, Ashkan K. Subcortical structure volumes and correlation to clinical variables in Parkinson's disease. *J Neuroimaging* 2015; **25**: 275-280 [PMID: 24593221 DOI: 10.1111/jon.12095]
- 16 **Tanner JJ**, McFarland NR, Price CC. Striatal and Hippocampal Atrophy in Idiopathic Parkinson's Disease Patients without Dementia: A Morphometric Analysis. *Front Neurol* 2017; **8**: 139 [PMID: 28450849 DOI: 10.3389/fneur.2017.00139]
- 17 **Vasconcellos LF**, Pereira JS, Adachi M, Greca D, Cruz M, Malak AL, Charchat-Fichman H. Volumetric brain analysis as a predictor of a worse cognitive outcome in Parkinson's disease. *J Psychiatr Res* 2018; **102**: 254-260 [PMID: 29729620 DOI: 10.1016/j.jpsyires.2018.04.016]
- 18 **Messina D**, Cerasa A, Condino F, Arabia G, Novellino F, Nicoletti G, Salsone M, Morelli M, Lanza PL, Quattrone A. Patterns of brain atrophy in Parkinson's disease, progressive supranuclear palsy and multiple system atrophy. *Parkinsonism Relat Disord* 2011; **17**: 172-176 [PMID: 21236720 DOI: 10.1016/j.parkreldis.2010.12.010]
- 19 **Menke RA**, Szewczyk-Krolikowski K, Jbabdi S, Jenkinson M, Talbot K, Mackay CE, Hu M. Comprehensive morphometry of subcortical grey matter structures in early-stage Parkinson's disease. *Hum Brain Mapp* 2014; **35**: 1681-1690 [PMID: 23861334 DOI: 10.1002/hbm.22282]
- 20 **Garg A**, Appel-Cresswell S, Popuri K, McKeown MJ, Beg MF. Morphological alterations in the caudate, putamen, pallidum, and thalamus in Parkinson's disease. *Front Neurosci* 2015; **9**: 101 [PMID: 25873854 DOI: 10.3389/fnins.2015.00101]
- 21 **Nemmi F**, Sabatini U, Rascol O, Péran P. Parkinson's disease and local atrophy in subcortical nuclei: insight from shape analysis. *Neurobiol Aging* 2015; **36**: 424-433 [PMID: 25174648 DOI: 10.1016/j.neurobiolaging.2014.07.010]
- 22 **Khan AR**, Hiebert NM, Vo A, Wang BT, Owen AM, Seergobin KN, MacDonald PA. Biomarkers of Parkinson's disease: Striatal sub-regional structural morphometry and diffusion MRI. *Neuroimage Clin* 2019; **21**: 101597 [PMID: 30472168 DOI: 10.1016/j.nicl.2018.11.007]
- 23 **Sigirli D**, Ozdemir ST, Erer S, Sahin I, Ercan I, Ozpar R, Orun MO, Hakyemez B. Statistical shape analysis of putamen in early-onset Parkinson's disease. *Clin Neurol Neurosurg* 2021; **209**: 106936 [PMID: 34530266 DOI: 10.1016/j.clineuro.2021.106936]
- 24 **Peralta M**, Baxter JSH, Khan AR, Haegelen C, Jannin P. Striatal shape alteration as a staging biomarker for Parkinson's Disease. *Neuroimage Clin* 2020; **27**: 102272 [PMID: 32473544 DOI: 10.1016/j.nicl.2020.102272]
- 25 **Wu T**, Wang J, Wang C, Hallett M, Zang Y, Wu X, Chan P. Basal ganglia circuits changes in Parkinson's disease patients. *Neurosci Lett* 2012; **524**: 55-59 [PMID: 22813979 DOI: 10.1016/j.neulet.2012.07.012]
- 26 **Mak E**, Bergsland N, Dwyer MG, Zivadinov R, Kandiah N. Subcortical atrophy is associated with cognitive impairment in mild Parkinson disease: a combined investigation of volumetric changes, cortical thickness, and vertex-based shape analysis. *AJNR Am J Neuroradiol* 2014; **35**: 2257-2264 [PMID: 25082821 DOI: 10.3174/ajnr.A4055]
- 27 **Sivaranjini S**, Sujatha CM. Morphological analysis of subcortical structures for assessment of cognitive dysfunction in Parkinson's disease using multi-atlas based segmentation. *Cogn Neurodyn* 2021; **15**: 835-845 [PMID: 34603545 DOI: 10.1007/s11571-021-09671-4]
- 28 **Devignes Q**, Viard R, Betrouni N, Carey G, Kuchcinski G, Defebvre L, Leentjens AFG, Lopes R, Dujardin K. Posterior Cortical Cognitive Deficits Are Associated With Structural Brain Alterations in Mild Cognitive Impairment in Parkinson's Disease. *Front Aging Neurosci* 2021; **13**: 668559 [PMID: 34054507 DOI: 10.3389/fnagi.2021.668559]
- 29 **Postuma RB**, Berg D, Stern M, Poewe W, Olanow CW, Oertel W, Obeso J, Marek K, Litvan I, Lang AE, Halliday G, Goetz CG, Gasser T, Dubois B, Chan P, Bloem BR, Adler CH, Deuschl G. MDS clinical diagnostic criteria for Parkinson's disease. *Mov Disord* 2015; **30**: 1591-1601 [PMID: 26474316 DOI: 10.1002/mds.26424]
- 30 **Melzer TR**, Watts R, MacAskill MR, Pitcher TL, Livingston L, Keenan RJ, Dalrymple-Alford JC, Anderson TJ. Grey matter atrophy in cognitively impaired Parkinson's disease. *J Neurol Neurosurg Psychiatry* 2012; **83**: 188-194 [PMID: 21890574 DOI: 10.1136/jnnp-2011-300828]
- 31 **Chung SJ**, Shin JH, Cho KH, Lee Y, Sohn YH, Seong JK, Lee PH. Subcortical shape analysis of progressive mild cognitive impairment in Parkinson's disease. *Mov Disord* 2017; **32**: 1447-1456 [PMID: 28737237 DOI: 10.1002/mds.27106]

- 32 **Gong L**, Li H, Yang D, Peng Y, Liu D, Zhong M, Zhang B, Xu R, Kang J. Striatum Shape Hypertrophy in Early Stage Parkinson's Disease With Excessive Daytime Sleepiness. *Front Neurosci* 2019; **13**: 1353 [PMID: 31992965 DOI: 10.3389/fnins.2019.01353]
- 33 **Kamps S**, van den Heuvel OA, van der Werf YD, Berendse HW, Weintraub D, Vriend C. Smaller subcortical volume in Parkinson patients with rapid eye movement sleep behavior disorder. *Brain Imaging Behav* 2019; **13**: 1352-1360 [PMID: 30155787 DOI: 10.1007/s11682-018-9939-4]
- 34 **Kluger BM**, Zhao Q, Tanner JJ, Schwab NA, Levy SA, Burke SE, Huang H, Ding M, Price C. Structural brain correlates of fatigue in older adults with and without Parkinson's disease. *Neuroimage Clin* 2019; **22**: 101730 [PMID: 30818269 DOI: 10.1016/j.nicl.2019.101730]
- 35 **Oltra J**, Segura B, Uribe C, Monté-Rubio GC, Campabadal A, Inguanzo A, Pardo J, Marti MJ, Compta Y, Valldeoriola F, Iranzo A, Junque C. Sex differences in brain atrophy and cognitive impairment in Parkinson's disease patients with and without probable rapid eye movement sleep behavior disorder. *J Neurol* 2022; **269**: 1591-1599 [PMID: 34345972 DOI: 10.1007/s00415-021-10728-x]
- 36 **Haaxma CA**, Helmich RC, Borm GF, Kappelle AC, Horstink MW, Bloem BR. Side of symptom onset affects motor dysfunction in Parkinson's disease. *Neuroscience* 2010; **170**: 1282-1285 [PMID: 20723583 DOI: 10.1016/j.neuroscience.2010.07.030]
- 37 **Kish SJ**, Shannak K, Hornykiewicz O. Uneven pattern of dopamine loss in the striatum of patients with idiopathic Parkinson's disease. Pathophysiologic and clinical implications. *N Engl J Med* 1988; **318**: 876-880 [PMID: 3352672 DOI: 10.1056/NEJM198804073181402]
- 38 **O'Neill J**, Schuff N, Marks WJ Jr, Feiwel R, Aminoff MJ, Weiner MW. Quantitative 1H magnetic resonance spectroscopy and MRI of Parkinson's disease. *Mov Disord* 2002; **17**: 917-927 [PMID: 12360540 DOI: 10.1002/mds.10214]
- 39 **Jahanshahi M**, Obeso I, Baunez C, Alegre M, Krack P. Parkinson's disease, the subthalamic nucleus, inhibition, and impulsivity. *Mov Disord* 2015; **30**: 128-140 [PMID: 25297382 DOI: 10.1002/mds.26049]
- 40 **Kaya MO**, Ozturk S, Ercan I, Gonen M, Serhat Erol F, Kocabicak E. Statistical Shape Analysis of Subthalamic Nucleus in Patients with Parkinson Disease. *World Neurosurg* 2019; **126**: e835-e841 [PMID: 30862597 DOI: 10.1016/j.wneu.2019.02.180]
- 41 **Patriat R**, Niederer J, Kaplan J, Amundsen Huffmaster S, Petrucci M, Eberly L, Harel N, MacKinnon C. Morphological changes in the subthalamic nucleus of people with mild-to-moderate Parkinson's disease: a 7T MRI study. *Sci Rep* 2020; **10**: 8785 [PMID: 32472044 DOI: 10.1038/s41598-020-65752-0]
- 42 **Calon F**, Rajput AH, Hornykiewicz O, Bédard PJ, Di Paolo T. Levodopa-induced motor complications are associated with alterations of glutamate receptors in Parkinson's disease. *Neurobiol Dis* 2003; **14**: 404-416 [PMID: 14678757 DOI: 10.1016/j.nbd.2003.07.003]
- 43 **McKeown MJ**, Uthama A, Abugharbieh R, Palmer S, Lewis M, Huang X. Shape (but not volume) changes in the thalamus in Parkinson disease. *BMC Neurol* 2008; **8**: 8 [PMID: 18412976 DOI: 10.1186/1471-2377-8-8]
- 44 **Chen Y**, Zhu G, Liu D, Liu Y, Yuan T, Zhang X, Jiang Y, Du T, Zhang J. The morphology of thalamic subnuclei in Parkinson's disease and the effects of machine learning on disease diagnosis and clinical evaluation. *J Neurol Sci* 2020; **411**: 116721 [PMID: 32058183 DOI: 10.1016/j.jns.2020.116721]
- 45 **Foo H**, Mak E, Yong TT, Wen MC, Chander RJ, Au WL, Sitoh YY, Tan LC, Kandiah N. Progression of subcortical atrophy in mild Parkinson's disease and its impact on cognition. *Eur J Neurol* 2017; **24**: 341-348 [PMID: 27943468 DOI: 10.1111/ene.13205]
- 46 **Nicolini F**, Wilson H, Giordano B, Diamantopoulos K, Pagano G, Chaudhuri KR, Politis M. Sleep disturbances and gastrointestinal dysfunction are associated with thalamic atrophy in Parkinson's disease. *BMC Neurosci* 2019; **20**: 55 [PMID: 31640554 DOI: 10.1186/s12868-019-0537-1]
- 47 **Li H**, Jia X, Qi Z, Fan X, Ma T, Pang R, Ni H, Li CR, Lu J, Li K. Disrupted Functional Connectivity of Cornu Ammonis Subregions in Amnesic Mild Cognitive Impairment: A Longitudinal Resting-State fMRI Study. *Front Hum Neurosci* 2018; **12**: 413 [PMID: 30420801 DOI: 10.3389/fnhum.2018.00413]
- 48 **Schmidt-Wilcke T**, Poljansky S, Hierlmeier S, Hausner J, Ibach B. Memory performance correlates with gray matter density in the ento-/perirhinal cortex and posterior hippocampus in patients with mild cognitive impairment and healthy controls—a voxel based morphometry study. *Neuroimage* 2009; **47**: 1914-1920 [PMID: 19442751 DOI: 10.1016/j.neuroimage.2009.04.092]
- 49 **Lee P**, Ryooh H, Park J, Jeong Y; Alzheimer's Disease Neuroimaging Initiative. Morphological and Microstructural Changes of the Hippocampus in Early MCI: A Study Utilizing the Alzheimer's Disease Neuroimaging Initiative Database. *J Clin Neurol* 2017; **13**: 144-154 [PMID: 28176504 DOI: 10.3988/jcn.2017.13.2.144]
- 50 **McIntosh EC**, Jacobson A, Kemmotsu N, Pongpipat E, Green E, Haase L, Murphy C. Does medial temporal lobe thickness mediate the association between risk factor burden and memory performance in middle-aged or older adults with metabolic syndrome? *Neurosci Lett* 2017; **636**: 225-232 [PMID: 27717834 DOI: 10.1016/j.neulet.2016.10.010]
- 51 **Shim G**, Choi KY, Kim D, Suh SI, Lee S, Jeong HG, Jeong B. Predicting neurocognitive function with hippocampal volumes and DTI metrics in patients with Alzheimer's dementia and mild cognitive impairment. *Brain Behav* 2017; **7**: e00766 [PMID: 28948070 DOI: 10.1002/brb3.766]
- 52 **Fogwe LA**, Reddy V, Mesfin FB. Neuroanatomy, hippocampus. StatPearls Treasure Island (FL): StatPearls Publishing, 2022. Available from: <http://www.ncbi.nlm.nih.gov/books/NBK482171/>
- 53 **Radziunas A**, Deltuva VP, Tamasauskas A, Gleizniene R, Pranckeviciene A, Petrikonis K, Bunevicius A. Brain MRI morphometric analysis in Parkinson's disease patients with sleep disturbances. *BMC Neurol* 2018; **18**: 88 [PMID: 29925331 DOI: 10.1186/s12883-018-1092-6]
- 54 **Wilson H**, Nicolini F, Pellicano C, Politis M. Cortical thinning across Parkinson's disease stages and clinical correlates. *J Neurol Sci* 2019; **398**: 31-38 [PMID: 30682518 DOI: 10.1016/j.jns.2019.01.020]
- 55 **Wang L**, Nie K, Zhao X, Feng S, Xie S, He X, Ma G, Wang L, Huang Z, Huang B, Zhang Y. Characteristics of gray matter morphological change in Parkinson's disease patients with semantic abstract reasoning deficits. *Neurosci Lett* 2018; **673**: 85-91 [PMID: 29275185 DOI: 10.1016/j.neulet.2017.12.047]

- 56 **Chen FX**, Kang DZ, Chen FY, Liu Y, Wu G, Li X, Yu LH, Lin YX, Lin ZY. Gray matter atrophy associated with mild cognitive impairment in Parkinson's disease. *Neurosci Lett* 2016; **617**: 160-165 [PMID: 26742642 DOI: 10.1016/j.neulet.2015.12.055]
- 57 **Park JW**, Lee CN, Sim Y, Ham HK, Tae WS, Kim BJ. Automated Subfield Volumetric Analysis of Hippocampus in Patients with Drug-Naïve Nondementia Parkinson's Disease. *Parkinsons Dis* 2019; **2019**: 8254263 [PMID: 30854188 DOI: 10.1155/2019/8254263]
- 58 **Filippi M**, Canu E, Donzuso G, Stojkovic T, Basaia S, Stankovic I, Tomic A, Markovic V, Petrovic I, Stefanova E, Kostic VS, Agosta F. Tracking Cortical Changes Throughout Cognitive Decline in Parkinson's Disease. *Mov Disord* 2020; **35**: 1987-1998 [PMID: 32886420 DOI: 10.1002/mds.28228]
- 59 **Xu R**, Hu X, Jiang X, Zhang Y, Wang J, Zeng X. Longitudinal volume changes of hippocampal subfields and cognitive decline in Parkinson's disease. *Quant Imaging Med Surg* 2020; **10**: 220-232 [PMID: 31956544 DOI: 10.21037/qims.2019.10.17]
- 60 **Luo C**, Gao Y, Hu N, Wei X, Xiao Y, Wang W, Lui S, Gong Q. Distinct hippocampal subfield atrophy in Parkinson's disease regarding motor subtypes. *Parkinsonism Relat Disord* 2021; **93**: 66-70 [PMID: 34808520 DOI: 10.1016/j.parkreldis.2021.11.011]
- 61 **Uribe C**, Segura B, Baggio HC, Campabadal A, Abos A, Compta Y, Marti MJ, Valldeoriola F, Bargallo N, Junque C. Differential Progression of Regional Hippocampal Atrophy in Aging and Parkinson's Disease. *Front Aging Neurosci* 2018; **10**: 325 [PMID: 30364338 DOI: 10.3389/fnagi.2018.00325]
- 62 **Becker S**, Granert O, Timmers M, Pilotto A, Van Nueten L, Roeben B, Salvatore G, Galpern WR, Streffer J, Scheffler K, Maetzler W, Berg D, Liepelt-Scarfone I. Association of Hippocampal Subfields, CSF Biomarkers, and Cognition in Patients With Parkinson Disease Without Dementia. *Neurology* 2021; **96**: e904-e915 [PMID: 33219138 DOI: 10.1212/WNL.00000000000011224]
- 63 **Rahayel S**, Gaubert M, Postuma RB, Montplaisir J, Carrier J, Monchi O, Rémillard-Pelchat D, Bourgouin PA, Panisset M, Chouinard S, Joubert S, Gagnon JF. Brain atrophy in Parkinson's disease with polysomnography-confirmed REM sleep behavior disorder. *Sleep* 2019; **42** [PMID: 30854555 DOI: 10.1093/sleep/zsz062]
- 64 **van Mierlo TJ**, Chung C, Foncke EM, Berendse HW, van den Heuvel OA. Depressive symptoms in Parkinson's disease are related to decreased hippocampus and amygdala volume. *Mov Disord* 2015; **30**: 245-252 [PMID: 25600157 DOI: 10.1002/mds.26112]
- 65 **Garcia-Diaz AI**, Segura B, Baggio HC, Uribe C, Campabadal A, Abos A, Marti MJ, Valldeoriola F, Compta Y, Bargallo N, Junque C. Cortical thinning correlates of changes in visuospatial and visuoperceptual performance in Parkinson's disease: A 4-year follow-up. *Parkinsonism Relat Disord* 2018; **46**: 62-68 [PMID: 29132765 DOI: 10.1016/j.parkreldis.2017.11.003]
- 66 **Vignando M**, Ffytche D, Lewis SJG, Lee PH, Chung SJ, Weil RS, Hu MT, Mackay CE, Griffanti L, Pins D, Dujardin K, Jardri R, Taylor JP, Firbank M, McAlonan G, Mak HKF, Ho SL, Mehta MA. Mapping brain structural differences and neuroreceptor correlates in Parkinson's disease visual hallucinations. *Nat Commun* 2022; **13**: 519 [PMID: 35082285 DOI: 10.1038/s41467-022-28087-0]
- 67 **Wei X**, Wang Z, Zhang M, Li M, Chen YC, Lv H, Tuo H, Yang Z, Ba F. Brain Surface Area Alterations Correlate With Gait Impairments in Parkinson's Disease. *Front Aging Neurosci* 2022; **14**: 806026 [PMID: 35153730 DOI: 10.3389/fnagi.2022.806026]
- 68 **Camlidag I**, Kocabicak E, Sahin B, Jahanshahi A, Incesu L, Aygun D, Yildiz O, Temel Y, Belet U. Volumetric analysis of the subthalamic and red nuclei based on magnetic resonance imaging in patients with Parkinson's disease. *Int J Neurosci* 2014; **124**: 291-295 [PMID: 24020352 DOI: 10.3109/00207454.2013.843091]
- 69 **Oh BH**, Moon HC, Kim A, Kim HJ, Cheong CJ, Park YS. Prefrontal and hippocampal atrophy using 7-tesla magnetic resonance imaging in patients with Parkinson's disease. *Acta Radiol Open* 2021; **10**: 2058460120988097 [PMID: 33786201 DOI: 10.1177/2058460120988097]



Published by **Baishideng Publishing Group Inc**
7041 Koll Center Parkway, Suite 160, Pleasanton, CA 94566, USA

Telephone: +1-925-3991568

E-mail: bpgoffice@wjgnet.com

Help Desk: <https://www.f6publishing.com/helpdesk>

<https://www.wjgnet.com>

