

In the article by Uojima et al. entitled “Skeletal Muscle Mass Influences Tolerability and Prognosis in Hepatocellular Carcinoma Patients Treated with Lenvatinib” [Liver Cancer. 2020; 9:193–206, DOI: 10.1159/000504604], the authors found that “SMI = subcutaneous fat area (cm²) / height² (m²)” was used erroneously instead of “SMI = skeletal mass area (cm²) / height² (m²)” in the labelling of Figure 2. Figure 2 with the correct labelling is shown here.

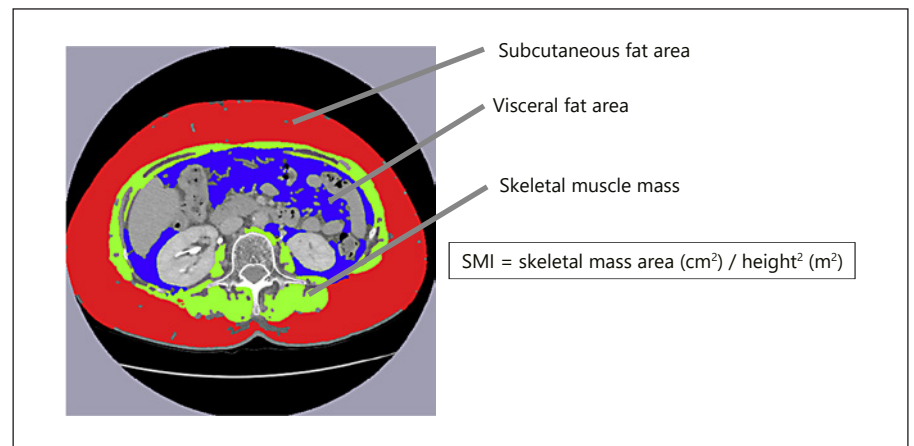


Fig. 2. Cross-sectional areas of skeletal muscle at the third lumbar level were measured by manual tracing on the CT images, and their sum was calculated. The green area indicates skeletal muscle at the third lumbar level. SMI, skeletal muscle index.