


CASE REPORT

Sacral abnormalities including caudal appendage, skeletal dysplasia, and prenatal cardiomyopathy associated with a pathogenic *TAB2* variant in a 3-generation family

Saskia Koene¹  | Floortje Klerx-Melis² | Arno Anne Willem Roest³ |
Maarten Cornelis Kleijwegt⁴ | Marianne Bootsma⁵ | Monique C. Haak⁶ |
Meike Heleen van Haeringen¹ | Claudia Antoinette Laetitia Ruivenkamp¹ |
Esther Anne Rieky Nibbeling¹ | Arie van Haeringen¹

¹Department of Clinical Genetics, Leiden University Medical Centre, Leiden, The Netherlands

²Department of Radiology, Haga Teaching Hospital, The Hague, The Netherlands

³Department of Pediatrics, Leiden University Medical Centre, Leiden, The Netherlands

⁴Department of Ear Nose and Throat - Head and Neck Cancer, Leiden University Medical Centre, Leiden, The Netherlands

⁵Department of Cardiology, Leiden University Medical Centre, Leiden, The Netherlands

⁶Department of Prenatal Diagnosis and Therapy, Leiden University Medical Centre, Leiden, The Netherlands

Correspondence

Saskia Koene, Department of Clinical Genetics, Leiden University Medical Centre, Albinusdreef 2, 2333 ZA Leiden, The Netherlands.
Email: s.koene@lumc.nl

Abstract

Haplo-insufficiency of the TGF β -activated kinase 1 binding protein 2 (*TAB2*) gene is associated with short stature, facial dysmorphisms, connective tissue abnormalities, hearing loss, and cardiac disease. Skeletal dysplasia and sacral dimples are also found in a minority of patients. Here, we describe a 3-generation family with caudal appendage, other sacral anomalies, and skeletal abnormalities including hypoplasia of the iliac wings and scapulae, fusion of the carpal bones and stenosis of the spinal canal, as well as a remarkable course of prenatally-detected cardiomyopathy with characteristics changing over time. Genetic analysis showed a heterozygous non-sense variant in the *TAB2* gene.

KEYWORDS

cardiomyopathy, carpal fusion, caudal appendage, skeletal dysplasia, *TAB2*

1 | INTRODUCTION

Haplo-insufficiency of the TGF β -activated kinase 1 binding protein 2 (*TAB2*) gene was first associated with congenital heart defects (Thienpont et al., 2010) and cardiomyopathy (Cheng et al., 2021). Gradually, the phenotype broadened in some cases to include short stature, facial dysmorphisms, connective tissue abnormalities, and developmental delay (Cheng et al., 2021; Engwerda et al., 2021; Ritelli et al., 2018). A recent study summarizing 70 individuals with *TAB2* haplo-insufficiency showed that cardiac disease, short stature, and

hypermobility are the primary characteristics (Engwerda et al., 2021). The study also reported facial features overlapping with Noonan syndrome.

Although deep sacral dimples have been previously described in patients with *TAB2* gene deletions (Engwerda et al., 2021; Ritelli et al., 2018; Wade et al., 2016), caudal appendage has not been reported in any *TAB2*-deficient patient to date. Human tail or caudal appendage is a rare congenital malformation, and a rare genetic cause is autosomal recessive 3MC syndrome caused by bi-allelic pathogenic variants in *MASP1* and *COLEC11*. 3MC syndrome, previously reported

This is an open access article under the terms of the [Creative Commons Attribution-NonCommercial-NoDerivs](https://creativecommons.org/licenses/by-nc-nd/4.0/) License, which permits use and distribution in any medium, provided the original work is properly cited, the use is non-commercial and no modifications or adaptations are made.

© 2022 The Authors. *American Journal of Medical Genetics Part A* published by Wiley Periodicals LLC.

as four separate syndromes (Carnevale et al., 1989; Malpuech et al., 1983; Michels et al., 1978; Mingarelli et al., 1996), is associated with caudal appendage in combination with cleft lip and palate, hyper-telorism, highly-arched eyebrows, growth deficiency, and genitourinary tract anomalies.

Here, we report a 3-generation family with caudal appendage, other skeletal abnormalities, and prenatal-onset cardiomyopathy associated with a heterozygous pathogenic variant in the *TAB2* gene.

2 | CLINICAL REPORT

In this article, we describe an adult female, her father, and her offspring from a multiple-generational Caucasian Dutch family with *TAB2* haplo-insufficiency (Figure 1).

The proband (II-1) was first seen by a clinical geneticist (A.H.) at the age of 2 years due to the suspicion of a syndromic cause for her atrial septal defect (ASD) and mitral and tricuspid insufficiency, given the caudal appendage and dysmorphic features in both her and her father (I-1).

Pregnancy and initial motor development were unremarkable. Later motor development was complicated by hypotonia and hypermobility. At physical examination, normal growth, hypermobility of the joints, decreased muscle strength, kyphosis, and abnormal sacral anatomy (Figure 2) were noted. Dysmorphic features included a long face, short palpebral fissures, and epicanthal folds. Based on the skeletal abnormalities (fusion of carpal bones, steep iliac wings, and small scapulae; Table 1; Figure 3), a clinical diagnosis of scapuloiliac dysostosis was made at the time (Blane et al., 1984).

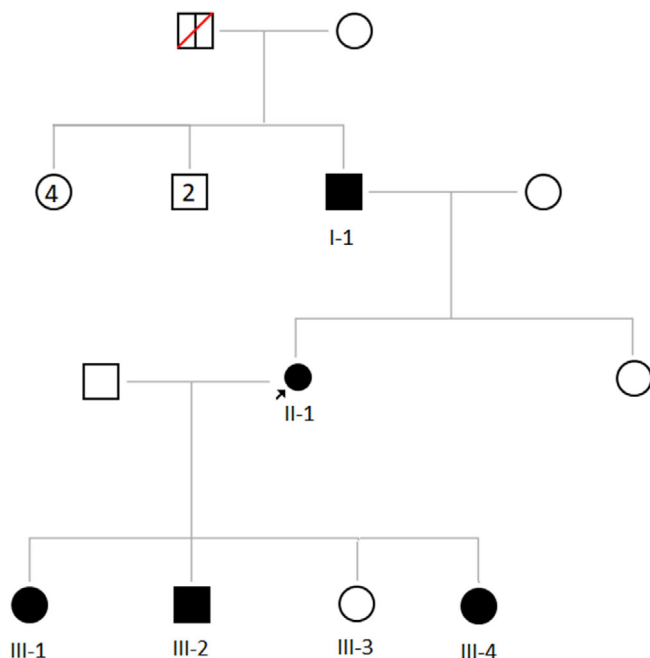


FIGURE 1 Three-generation pedigree

At the age of 22 years, she was of normal height (170 cm; -0.1 SDS) but with short limbs (arm span <-2 SDS; sit height $+2$ SDS). She needed frequent tympanostomy tubes due to otitis media with effusion (OME) and required surgery to widen her ear canal (M-meatoplasty). After her last pregnancy, incarceration of the intestines occurred, most probably due to diastasis recti that was diagnosed after the age of 8 years. Her major complaints are the result of hypermobility and tissue weakness.

The father (I-1) shows caudal appendage and facial features similar to those of his daughter. Now 74 years old, he has a history of lumbar canal stenosis and cervical myelopathy that required multiple surgeries, gonarthrosis, dilating cardiomyopathy, and inguinal hernia. His caudal appendage was removed as a result of an infectious focus under the appendage. He currently has a nonspecific interstitial pneumonia, which is probably unrelated to *TAB2* haplo-insufficiency. His major complaints concern back pain.

The first child of II-1 (III-1) shows dilating cardiomyopathy and hypermobility. As a fetus, she exhibited an enlarged heart at routine obstetric scanning at 27 weeks gestational age. Fetal echocardiography revealed a normal left ventricle (LV) and a dilated right ventricle (RV), with moderately reduced contractility. The RV increased in size during pregnancy, showing decreasing contractility, while LV function remained normal. At 39 weeks, multiple short runs of tachycardia were present. Labor was induced and a girl weighting 3425 grams was born. Postnatally, the tachycardia was found to be caused by frequent premature atrial contractions due to an enlarged RV with depressed function, in combination with mildly elevated pulmonary pressure. After observation on a neonatal ward, she was discharged but readmitted with LV dilatation and severely depressed cardiac function 1 month later. Following initiation of heart failure therapy based on ACE inhibition and B-blockade, LV dilatation and function improved and the therapy could be discontinued at 1 year. Cardiac MRI at the age of 12 years revealed a mildly dilated LV (LV-EDV/BSA: 104 [reference values: 57–101 ml/m²]) with an ejection fraction of 47.6% (reference values 50%–76%), without any signs of myocardial fibrosis on late gadolinium enhancement imaging.

As an infant, she had hyperlaxity and feeding problems due to hypotonia, which were addressed by tube feeding. She now shows normal cognitive development, with few limitations in daily life, with the exception of unilateral conductive hearing loss due to tympanic membrane perforation and she appears to incur injury during sport more frequently than her peers.

Her brother (III-2) has a gross motor developmental delay, congenital hip dysplasia and frequent OME requiring tympanostomy tubes. Prenatal ultrasound revealed mild dilatation of the RV. Postnatal echocardiography showed an ASD and a perimembranous ventricular septal defect that closed spontaneously during follow-up. The RV dilatation also resolved spontaneously after birth. His major complaints are related to hypermobility and muscle weakness, for example, in learning to ride a bicycle.

The youngest daughter (III-4) has hypermobility and hypotonia. Prenatal echocardiography showed mild tricuspid regurgitation at

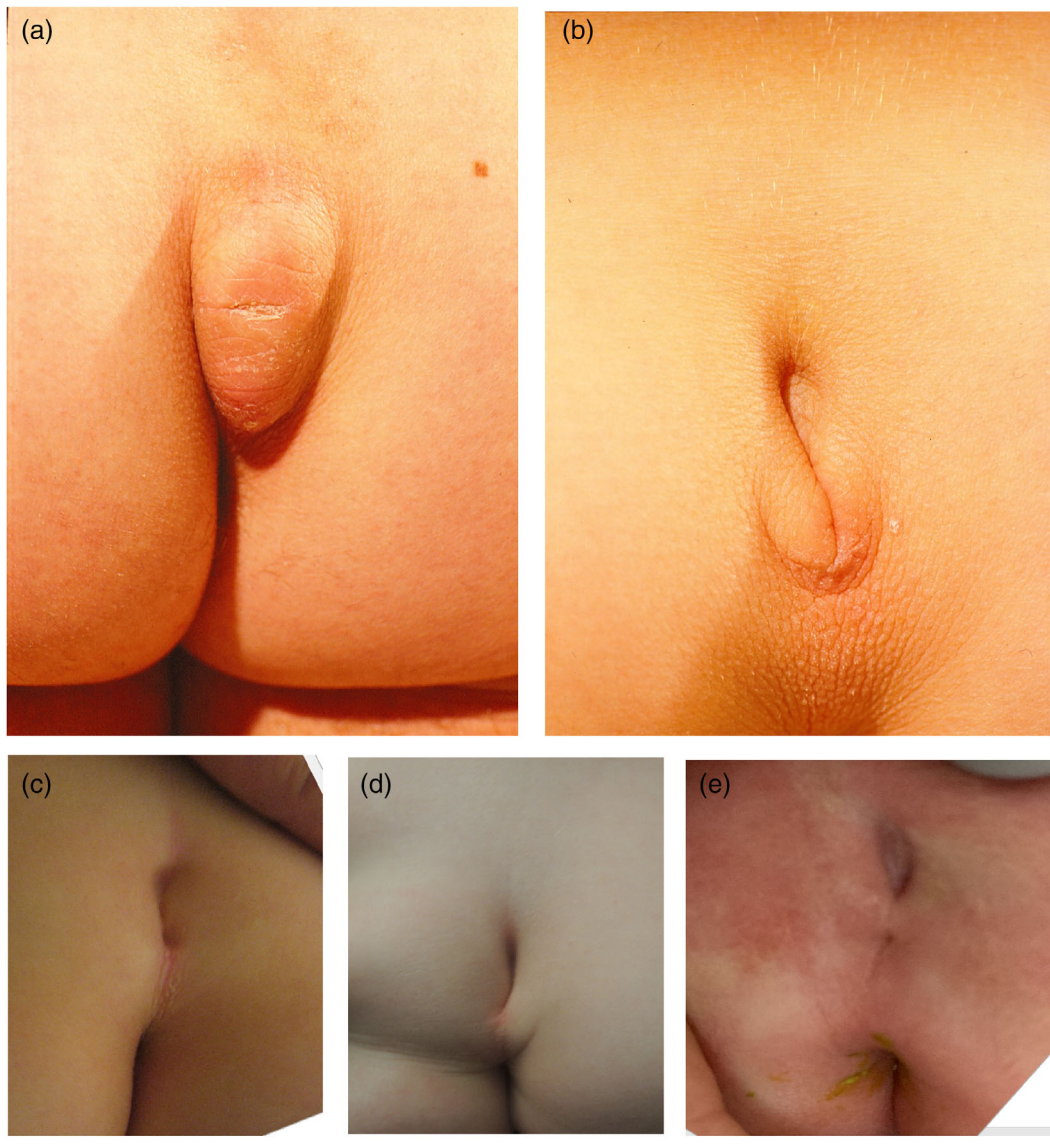

FIGURE 2 Sacral region. The caudal appendage in I-1 (a) and the deep sacral dimple in II-1 (b), III-1 (c), III-2 (d), and III-4 (e)

20 weeks GA, without enlargement of the RV. Follow-up scans remained stable, showing a mildly enlarged heart that developed into mild asymmetry (RV > LV). Postnatal echocardiography revealed decreased RV function with a tricuspid annular plane systolic excursion (TAPSE) of 5.6 mm and mildly elevated pulmonary pressure. Furthermore, a thickened tricuspid valve with mild regurgitation and a thickened mitral valve with no stenosis or regurgitation were detected. In the weeks after birth, RV function improved to a TAPSE of 14 mm (Z-score +0.6), LV function became normal after birth and tricuspid valve regurgitation resolved.

On X-rays of the here described affected family members, hypoplastic iliac wings (2/4 family members), hypoplastic scapulae (2/4), lumbar stenosis (2/4), abnormal development of the acetabular roof (2/4), thoracic kyphosis (1/4), and fusion of carpal bones (1/4) were seen (Table 1; Figure 3).

Table 1 summarizes all features associated with TAB2 haplo-insufficiency in this family and provides an overview of similar features in a cohort previously described by Engwerda et al. (2021) encompassing TAB2 haplo-insufficiency due to both single nucleotide variants and gene-deletions.

3 | GENETIC ANALYSIS

Genetic analysis was based on whole exome sequencing using previously reported methods, in combination with Moon software (Diploid; Version 2.3.2) analysis, and detected a heterozygous, paternal TAB2 variant (Chr6(GRCh37):g.149700172dup:NM_015093.4:c.1121dup p.(Asn375Lysfs*4)) in patient II-1. This variant is present in all affected individuals (I-1; III-1; III-2; III-4) but has not been observed in control

TABLE 1 Phenotype details of the subjects from our 3-generation family with TAB2 deficiency compared to the cohort of Engwerda et al. (2021)

Patient	I-1	II-1	III-1	III-2	III-4	Previously reported in patients with TAB2 deletions (Engwerda et al; cohort n = 36)	Previously reported in patients with TAB2 variants (Engwerda et al; cohort n = 36)
Variant	c.1121dup p.(Asn375Lysfs*4)						
Age last follow up (years)	74	40	14	4	11 months		
Gender (F/M)	M	F	F	M	F		
Heart							
Dilated cardiomyopathy	+	+	+	-	-	11	12
Connective tissue/skeletal							
Caudal appendage	+	-	-	-	-	0	0
Sacral dimple	-	+	+	+	+	0	10
Hypoplastic sacrum	-	U	-	-	U	1	0
Iliac hypoplasia	+	+	-	-	U	0	0
Lumbar stenosis	+	+	-	U	-	3	0
Thoracic and cervical stenosis	+	-	-	U	-	0	1
Hypoplastic scapulae	-	+	+	-	U	2	0
Fusion of the carpal bones	U	+	-	-	U	4	1
Increased skin folds	+	+	+	+	+	2	0
Diastasis recti	-	+	-	-	-	0	0

Abbreviation: U, unknown.

populations (i.e., gnomAD database). No other genetic explanation for cardiomyopathy was found in III-1 despite NGS of 60 cardiomyopathy-associated genes.

4 | DISCUSSION

Here, we described a 3-generation family with caudal appendage and other sacral anomalies, as well as skeletal abnormalities including hypoplasia of iliac wings and scapulae, fusion of the carpal bones, and stenosis of the spinal canal. Genetic analysis detected a heterozygous nonsense variant in the *TAB2* gene.

The occurrence of caudal appendage in the father is unusual, as previously described causes have all been autosomal recessive (Urquhart et al., 2016). Strikingly, a deep sacral dimple was described in 10 patients with a *TAB2* gene deletion, and hypoplasia of the sacrum was previously reported in one patient (Ritelli et al., 2018). Spinal canal stenosis, present in both I-1 and II-1, has also been reported in a minority of patients with stenosis of the lumbar vertebral canal (Ritelli et al., 2018), suggesting that spinal canal stenosis is a component of the *TAB2*-related phenotype.

Skeletal abnormalities such as pectus excavatum, short hands, scoliosis, hip dysplasia, and disproportionate short stature have been described in only a minority of reported patients with *TAB2* haplo-insufficiency (Engwerda et al., 2021). Syndromic causes of carpal fusion and hypoplasia of the scapulae, iliac wings, and sacrum include skeletal dysplasias such as *SOX9*-related campomelic dysplasia, which

is also associated with cardiac defects. Interestingly, *SOX9* appears to be a transcriptional activator of *TAB2* (Huang et al., 2017). Because skeletal features such as pectus excavatum, fusion of the carpal bones, and brachydactyly were present in multiple patients (Engwerda et al., 2021; Ritelli et al., 2018), we suggest that these features are indeed associated with *TAB2* haplo-insufficiency.

Hearing loss has previously been found in approximately 1 in 4 patients with *TAB2* haplo-insufficiency (Engwerda et al., 2021). In the present family, both unilateral and bilateral conductive hearing loss were seen, in association with frequent tympanic membrane perforations and OME.

Finally, a novel pattern of cardiac abnormalities in early life was seen in this family, in addition to the commonly described cardiac abnormalities associated with *TAB2* haplo-insufficiency. Cardiac imaging revealed cardiac (dys)function and cardiomyopathy in the prenatal and direct postnatal period with involvement of the RV, with dilatation and dysfunction. In agreement with literature, significant LV dysfunction was present after the neonatal period, especially in the first child, with function improving during long-term follow-up. Depressed RV function pre- and early postnatally may be explained by increased afterload due to elevated pulmonary pressure, a problem that resolved with the postnatal physiological decrease in pulmonary pressure.

In conclusion, we suggest that sacral, neural tube, and other skeletal abnormalities are all phenotypic features of *TAB2* haplo-insufficiency. This report also expands the cardiac phenotype associated with pathogenic *TAB2* variants to include early onset cardiomyopathy, with characteristic changes over time.

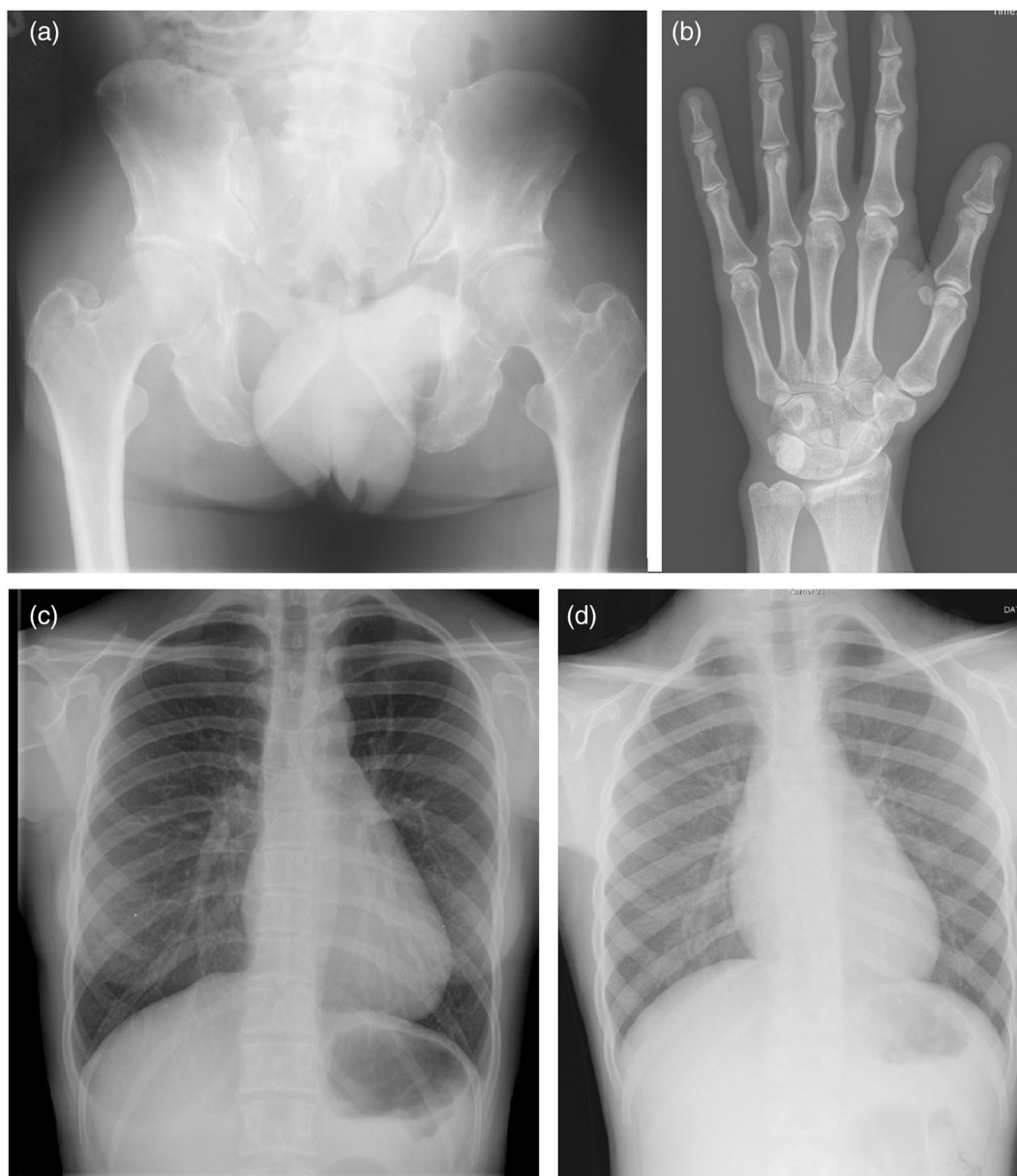

FIGURE 3 X-ray of the pelvis, hand, and thorax. X-rays of the (a) pelvis (II-1), showing hypoplasia of the iliac wings; (b) hand (II-1), showing fusion of the carpal bones and thorax (II-1 [c], and III-1 at 8 years of age [d]) showing hypoplasia of the scapulae.

AUTHOR CONTRIBUTIONS

Saskia Koene: Writing manuscript; Floortje Klerx-Melis: Collecting radiological data, correction of manuscript; Arno Anne Willem Roest: Correction of manuscript; Maarten Cornelis Kleijwegt: Correction of manuscript; Marianne Bootsma: Correction of manuscript; Monique Cecile Haak: Correction of manuscript; Meike Heleen van Haeringen: Collection of family data, correction of manuscript; Claudia Antoinette Laetitia Ruivenkamp: Genetic analysis; correction of manuscript; Esther Anne Rieky Nibbeling: Genetic analysis, correction of manuscript; Arie van Haeringen: Supervision and correction of manuscript.

CONFLICT OF INTEREST

The authors declare no potential conflict of interests.

DATA AVAILABILITY STATEMENT

Data sharing is not applicable to this article as no new data were created or analyzed in this study.

ORCID

Saskia Koene  <https://orcid.org/0000-0002-9876-744X>

REFERENCES

- Blane, C. E., Holt, J. F., & Vine, A. K. (1984). Scapuloiliac dysostosis. *British Journal of Radiology*, 57(678), 526–528.
- Carnevale, F., Krajewska, G., Fischetto, R., Greco, M. G., & Bonvino, A. (1989). Ptosis of eyelids, strabismus, diastasis recti, hip defect, cryptorchidism, and developmental delay in 2 sibs. *American Journal of Medical Genetics*, 33(2), 186–189.

- Cheng, G., Xiong, Y., Zhou, H., He, Y., Zhang, K., Cao, S., & Wang, K. (2021). First-principles calculation of atomic structure, stability and electronic structure of TaB₂/SiC interface. *Modelling and Simulation in Materials Science and Engineering*, 29(4), 045005.
- Engwerda, A., Leenders, E. K. S. M., Frentz, B., Terhal, P. A., Löhner, K., de Vries, B. B. A., Dijkhuizen, T., Vos, Y. J., Rinne, T., van den Berg, M. P., Roofthoof, M. T. R., Deelen, P., van Ravenswaaij-Arts, C. M. A., & Kerstjens-Frederikse, W. S. (2021). TAB2 deletions and variants cause a highly recognisable syndrome with mitral valve disease, cardiomyopathy, short stature and hypermobility. *European Journal of Human Genetics*, 29, 1669–1676.
- Huang, C. Z., Xu, J. H., Zhong, W., Xia, Z. S., Wang, S. Y., Cheng, D., Li, J. Y., Wu, T. F., Chen, Q. K., & Yu, T. (2017). Sox9 transcriptionally regulates Wnt signaling in intestinal epithelial stem cells in hypomethylated crypts in the diabetic state. *Stem Cell Research & Therapy*, 8, 60.
- Malpuech, G., Demeocq, F., Palcoux, J. B., Vanlieferinghen, P., & Opitz, J. M. (1983). A previously undescribed autosomal recessive multiple congenital-anomalies mental-retardation (Mca Mr) syndrome with growth failure, lip palate cleft(S), and urogenital anomalies. *American Journal of Medical Genetics*, 16(4), 475–480.
- Michels, V. V., Hittner, H. M., & Beaudet, A. L. (1978). Clefting syndrome with ocular anterior-chamber defect and lid anomalies. *Journal of Pediatrics*, 93(3), 444–446.
- Mingarelli, R., Scanderbeg, A. C., & Dallapiccola, B. (1996). Two sisters with a syndrome of ocular, skeletal, and abdominal abnormalities (OSA syndrome). *Journal of Medical Genetics*, 33(10), 884–886.
- Ritelli, M., Morlino, S., Giacomuzzi, E., Bernardini, L., Torres, B., Santoro, G., Ravasio, V., Chiarelli, N., D'Angelantonio, D., Novelli, A., Grammatico, P., Colombi, M., & Castori, M. (2018). A recognizable systemic connective tissue disorder with polyvalvular heart dystrophy and dysmorphism associated with TAB2 mutations. *Clinical Genetics*, 93(1), 126–133.
- Thienpont, B., Zhang, L., Postma, A. V., Breckpot, J., Tranchevent, L. C., van Loo, P., Møllgård, K., Tommerup, N., Bache, I., Tümer, Z., van Engelen, K., Menten, B., Mortier, G., Waggoner, D., Gewillig, M., Moreau, Y., Devriendt, K., & Larsen, L. A. (2010). Haploinsufficiency of TAB2 causes congenital heart defects in humans. *American Journal of Human Genetics*, 86(6), 839–849.
- Urquhart, J., Roberts, R., de Silva, D., Shalev, S., Chervinsky, E., Nampoothiri, S., Sznajder, Y., Revencu, N., Gunasekera, R., Suri, M., Ellingford, J., Williams, S., Bhaskar, S., & Clayton-Smith, J. (2016). Exploring the genetic basis of 3MC syndrome: Findings in 12 further families. *American Journal of Medical Genetics Part A*, 170(5), 1216–1224.
- Wade, E. M., Daniel, P. B., Jenkins, Z. A., McInerney-Leo, A., Leo, P., Morgan, T., Addor, M. C., Adès, L. C., Bertola, D., Bohring, A., Carter, E., Cho, T. J., Duba, H. C., Fletcher, E., Kim, C. A., Krakow, D., Morava, E., Neuhann, T., Superti-Furga, A., ... Robertson, S. P. (2016). Mutations in MAP3K7 that alter the activity of the TAK1 signaling complex cause frontometaphyseal dysplasia. *American Journal of Human Genetics*, 99(2), 392–406.

How to cite this article: Koene, S., Klerx-Melis, F., Roest, A. A. W., Kleijwegt, M. C., Bootsma, M., Haak, M. C., van Haeringen, M. H., Ruivenkamp, C. A. L., Nibbeling, E. A. R., & van Haeringen, A. (2022). Sacral abnormalities including caudal appendage, skeletal dysplasia, and prenatal cardiomyopathy associated with a pathogenic TAB2 variant in a 3-generation family. *American Journal of Medical Genetics Part A*, 188A: 3510–3515. <https://doi.org/10.1002/ajmg.a.62929>