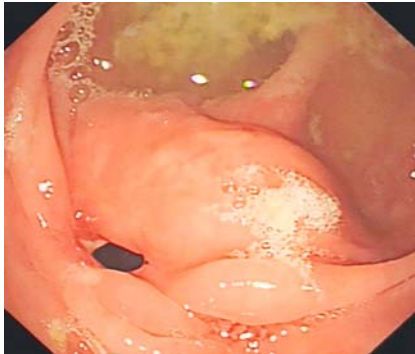
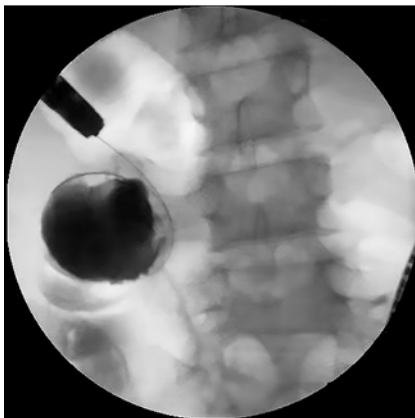


Endoscopic treatment of a postoperative anastomotic stricture in a patient with refractory Crohn's disease

OPEN
ACCESS

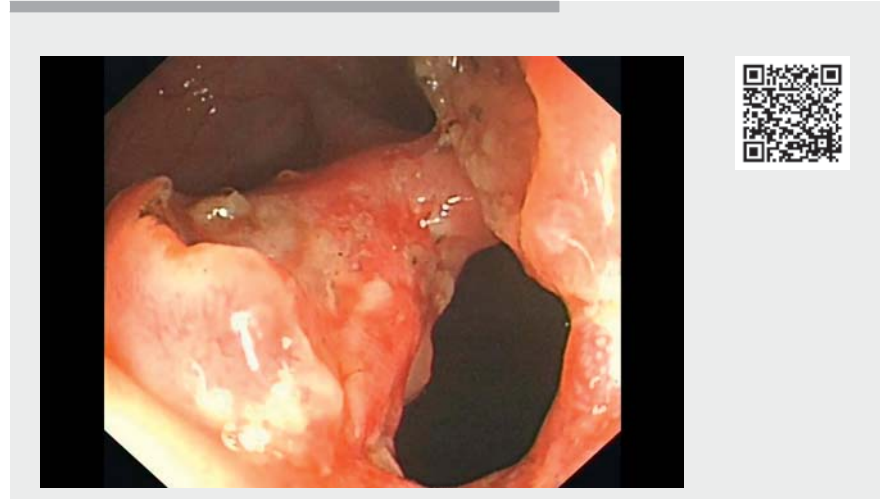

► **Fig. 1** Endoscopic view of the anastomotic stricture with ulceration.



► **Fig. 2** Radiographic image showing the contrast agent entering the intestinal lumen.

A 17-year-old man with recurrent abdominal pain for 8 years was diagnosed with Crohn's disease (CD) with perforation. After surgery, the patient's abdominal pain persisted despite treatment with azathioprine, adalimumab, and infliximab. Laboratory testing revealed a positive fecal occult blood test, markedly elevated fecal calprotectin (698 $\mu\text{g/g}$) and slightly elevated plasma C-reactive protein (CRP) level (8.5 mg/L). Colonoscopy showed an anastomotic ulcer and stricture. The patient was treated with an intravenous infusion of cyclophosphamide and oral thalidomide. After 6



► **Video 1** Endoscopic stricturotomy was performed to treat an anastomotic stricture in a patient with Crohn's disease.

months, his abdominal pain had disappeared and the inflammatory markers had returned to normal. Colonoscopy showed the anastomotic ulcer had disappeared but the stricture had worsened. Thalidomide therapy was maintained; however, after another 6 months, the patient again experienced abdominal pain and his inflammatory markers were significantly elevated (CRP 14 mg/L, fecal calprotectin 1376 $\mu\text{g/g}$). Computed tomographic enterography (CTE) showed the anastomotic stricture and thickened bowel wall without a fistula.

On colonoscopy, the scope could not be passed through the anastomosis and ulcers were visible again (► **Fig. 1**). After injecting contrast agent to delineate the proximal lumen (► **Fig. 2**), we performed endoscopic stricturotomy (► **Video 1**) as the stricture was short and straight and accompanied by ulceration (► **Fig. 3 a,b**). We initially cut the mucosa on the opposite side from the ulcer, assumed to be the thicker part of the bowel wall, to avoid perforation. After the incision had been made, the colonoscope could be passed

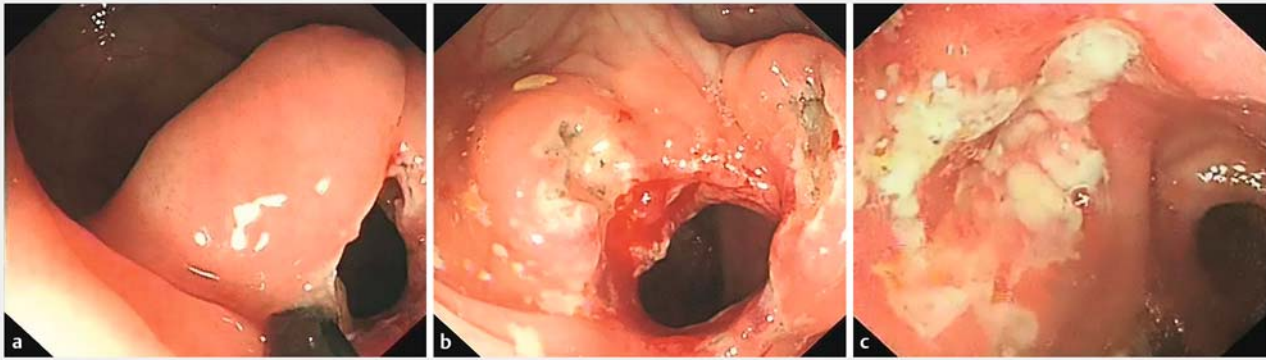
through the stricture into the small bowel, where an active ulcer was found (► **Fig. 3 c**).

The patient was subsequently treated with hormone therapy combined with methotrexate. Repeat colonoscopy after 6 months showed that the anastomotic stoma was significantly wider so the colonoscope could be passed through, and the ulcer on the oral side was well healed. In conclusion, anastomotic strictures without fistulas could be effectively treated by endoscopic stricturotomy in CD patients. Where strictures are accompanied by ulcers, stricturotomy may be safer than endoscopic balloon dilation [1–4].

Endoscopy_UCTN_Code_TTT_1AQ_2AF

Funding

Capital's Funds for Health Improvement and Research
Grant No.2018-1-5091



► **Fig. 3** Endoscopic images showing: **a** incision of the anastomotic stricture; **b** the appearance of the anastomotic stoma after endoscopic stricturotomy; **c** ulceration on the oral side of anastomosis.


Clinical trial

Trial Registration: Chinese Clinical Trial Registry | Registration number (trial ID): ChiCTR-1900022728 | Type of study: Observational study

Competing interests

The authors declare that they have no conflict of interest.

The authors

Yan Jia^{1*}, **Xianzong Ma**^{1,2*}, **Yurong Tao**¹, **Limin Zhang**¹, **Jianqiu Sheng**^{1,2}, **Bing Wu**³, **Peng Jin**^{1,4} 

- 1 Department of Gastroenterology, Seventh Medical Center of Chinese PLA General Hospital, Beijing, China
- 2 Medical School of Chinese PLA, Beijing, China
- 3 Diagnostic Radiology Division, Seventh Medical Center of Chinese PLA General Hospital, Beijing, China
- 4 Senior Department of Gastroenterology, First Medical Center of Chinese PLA General Hospital, Beijing, China

Corresponding author

Peng Jin, MD

Department of Gastroenterology, Seventh Medical Center of Chinese PLA General Hospital, Nanmenchang 5#, Dongcheng District, Beijing 100700, China
dr_pengjin@qq.com

References

- [1] Ueno F, Matsui T, Matsumoto T et al. Evidence-based clinical practice guidelines for Crohn's disease, integrated with formal consensus of experts in Japan. *J Gastroenterol* 2013; 48: 31–72
- [2] Lan N, Shen B. Endoscopic stricturotomy versus balloon dilation in the treatment of anastomotic strictures in Crohn's disease. *Inflamm Bowel Dis* 2018; 24: 897–907
- [3] Mayberry JF, Lobo A, Ford AC et al. NICE clinical guideline (CG152): the management of Crohn's disease in adults, children and young people. *Aliment Pharmacol Ther* 2013; 37: 195–203
- [4] Bharadwaj S, Fleshner P, Shen B. Therapeutic armamentarium for stricturing Crohn's disease: medical versus endoscopic versus surgical approaches. *Inflamm Bowel Dis* 2015; 21: 2194–2213

Bibliography

Endoscopy 2023; 55: E135–E136

DOI 10.1055/a-1941-8409

ISSN 0013-726X

published online 28.10.2022

© 2022. The Author(s).

This is an open access article published by Thieme under the terms of the Creative Commons Attribution-NonDerivative-NonCommercial License, permitting copying and reproduction so long as the original work is given appropriate credit. Contents may not be used for commercial purposes, or adapted, remixed, transformed or built upon. (<https://creativecommons.org/licenses/by-nc-nd/4.0/>)

Georg Thieme Verlag KG, Rüdigerstraße 14, 70469 Stuttgart, Germany



ENDOSCOPY E-VIDEOS

<https://eref.thieme.de/e-videos>



Endoscopy E-Videos is an open access online section, reporting on interesting cases

and new techniques in gastroenterological endoscopy. All papers include a high quality video and all contributions are freely accessible online. Processing charges apply (currently EUR 375), discounts and waivers acc. to HINARI are available.

This section has its own submission website at <https://mc.manuscriptcentral.com/e-videos>

* Co-first authors