

Review

Video-based surgical curriculum for open-globe injury repair, III: surgical repair

Aliya Siddiqui, MS,^a Marguerite C. Weinert, MD,^{b,c} Catherine M. Marando, MD,^{b,c} in collaboration with curriculum editors Tedi Begaj, MD,^{b,c} Yifan Lu, MD,^{c,d} and Grayson W. Armstrong, MD, MPH^{b,c}

Author affiliations: ^aCarle Illinois College of Medicine, University of Illinois Urbana-Champaign, Champaign, Illinois;

^bDepartment of Ophthalmology, Harvard Medical School, Boston, Massachusetts;

^cMassachusetts Eye and Ear, Boston, Massachusetts;

^dCambridge Health Alliance, Harvard Medical School, Cambridge, Massachusetts

As one of the most severe forms of ocular trauma, open-globe injury (OGI) causes significant vision loss. Timely and meticulous repair of these injuries can improve patient outcomes. This video-based educational curriculum is intended to serve as an efficient yet comprehensive reference for OGI repair. We hope that these video-based articles help surgeons and trainees from around the world find answers to specific surgical questions in OGI management. The curriculum has been divided into six separate review articles, each authored by a different set of authors, to facilitate a systematic and practical approach to the subject of wound types and repair techniques. This third article highlights the use of antibiotics before, during, and after surgery; suture selection; surgical knots, and “ship-to-shore” suturing.

Curriculum Editors

Preoperative, Intraoperative, and Postoperative Antibiotics

Surgical repair of an open-globe injury (OGI) is critical to improving function, preserving vision, and reducing risk of infection after traumatic eye injury. Antibiotic therapy also plays a critical role in achieving good outcomes. In the absence of prophylactic antibiotic use, post-traumatic endophthalmitis occurs in approximately 10% of cases, whereas use of antibiotics may reduce the rate of endophthalmitis to as low as 0.9%.^{1,2} The most common infectious agents are Gram positive cocci (eg,

streptococcus, coagulase-negative staphylococcus), bacillus species, and fungi.³ Additionally, risk factors for endophthalmitis include delay of closure beyond 24 hours, wound contamination, retained intraocular foreign body (IOFB), involvement of the lens capsule, and trauma occurring in a rural setting.⁴

Preoperative Antibiotics

Empiric antibiotic therapy should be initiated as early as possible from the onset of initial injury to reduce the risk of possible infection. Two common, broad-spectrum agents employed at Massachusetts Eye and Ear are intravenous vancomycin (15 mg/kg for children or ~1 g twice daily for a total of 4 doses) and a third-generation cephalosporin (ceftazidime 50 mg/kg for children or ~1g three times daily for a total of 6 doses), for a total treatment duration of 48 hours.^{5,6} This standardized treatment regimen covers the majority of bacterial etiologies. In patients with penicillin allergies, fluoroquinolones may be used instead. Tabatabaei and colleagues⁷ found no difference between oral and intravenous antibiotic administration in occurrence of endophthalmitis or visual acuity at 1 year’s follow-up. Thus, in circumstances without capacity for intravenous medications, and when transfer to an outside hospital might require several hours, initiation of an oral regimen may be appropriate.

Antifungal prophylaxis is not routinely administered unless there is a high risk, as, for example, in cases of intraocular foreign organic material. Clinical trials have shown similar efficacy of oral fluoroquinolones as well as intravitreal vancomycin and ceftazidime or intravi-

Published December 27, 2022.

Copyright ©2022. All rights reserved. Reproduction in whole or in part in any form or medium without expressed written permission of the Digital Journal of Ophthalmology is prohibited.

doi:10.5693/djo.01.2022.08.002

Correspondence: Grayson W. Armstrong, MD, MPH, Department of Ophthalmology, Harvard Medical School, Massachusetts Eye and Ear, Boston, MA (email: grayson_armstrong@meei.harvard.edu).

treating clindamycin and gentamicin.⁶ However, unless there is an IOFB or suspicion for endophthalmitis, the potential benefits of intravitreally injected medications in the context of limited proven benefit do not outweigh the risks, offering no compelling rationale for routine administration.

The possibility of a *Clostridium tetani* infection may occur in patients with complicated perforating wounds; thus, tetanus post-exposure prophylaxis is recommended.^{8,9}

Intraoperative Antibiotics

During surgical repair of zone I injuries, where the anterior segment can be safely manipulated, intracameral moxifloxacin may be used. Moxifloxacin has been found to be effective against other similar microorganisms that are encountered in routine anterior segment surgery.¹⁰ At the conclusion of repair, a subconjunctival injection of cefazolin (100 mg/0.5 mL) and dexamethasone (400 mcg/0.1 mL) is commonly used, administered away from the site of injury.

Postoperative Antibiotics

In tandem with cycloplegic agents and corticosteroid topical therapy, a topical antibiotic is routinely used. The common agents are the fluoroquinolones (eg, moxifloxacin, ofloxacin), applied at a frequency per physician or institutional protocol in the injured eye. If necessary and as an alternative, combination drops or ointment (ie, antibiotic and corticosteroid) may also be used.

In the postoperative phase, broad-spectrum intravenous antibiotic therapy should be continued for a total of 48 hours.

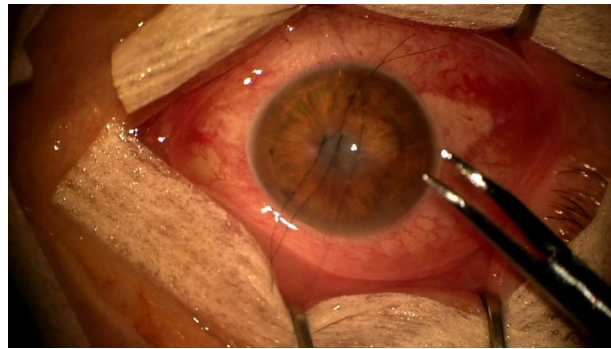
Discharge Antibiotics

Beginning on postoperative day 1, as mentioned above, topical antibiotic therapy is initiated postoperatively. We continue this for a total of 1 week.⁶

(NS, GWA)

Suture Selection

OIGs can involve any structure of the eye, and proper surgical repair requires choosing the appropriate suture (including material, size, and needle) for a given wound type. Nylon monofilament suture is a nonabsorbable, minimally reactive suture producing little scarring; loss of tensile strength because of hydrolysis occurs very gradually.¹¹ Nylon is the preferred suture for primary wound closure in OGI, because it is nonabsorbable and can remain permanently in scleral wounds and be



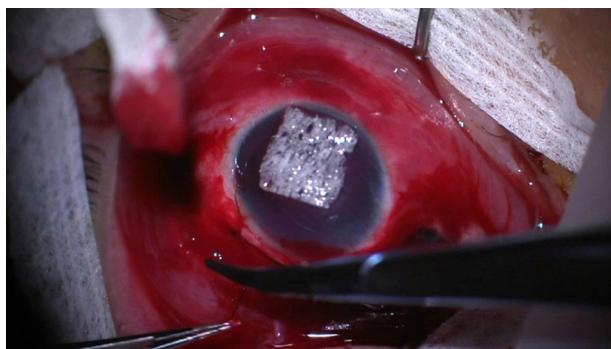
Video 1. Examples of the various sutures.

removed gradually from corneal wounds. For corneal wounds, 10-0 nylon sutures are used to achieve the best optical outcome¹²; 9-0 nylon is used for limbal lacerations and 8-0 nylon is used for scleral lacerations. No matter the size of the suture, a spatulated needle is recommended in OGI repair: the flat tip on the upper and lower surfaces allows precise depth control through the sclera and cornea.¹³ It is important to be aware that the lateral edges are the sharp “cutting edges,” and care should be taken not to inadvertently widen a tunnel while passing the suture.

Silk is a nonabsorbable braided suture with easy maneuverability, but it has increased risk of bacterial infectivity. Thus, it should not be used for primary wound closure; however, it can be useful for manipulating the eye during surgery. A 4-0 silk suture on a reverse cutting needle may be used for limbal fixation in order to manipulate the globe for more posterior repairs, and 4-0 silk on a tapered needle can be useful for retracting lids when the injury impedes the use of a conventional eyelid retractor, as could be the case after severe eyelid trauma. Finally, 2-0 silk can be threaded through a Gass hook and used to isolate extraocular muscles for further globe control and exposure.

Polyglactin 910 is a braided absorbable suture that offers wound support for 7–10 days and fully dissolves after 60–90 days. Muscle disinsertion and reattachment may be necessary in complex zone III lacerations; commonly a 6-0 polyglactin 901 double-armed suture on a spatulated needle is used to secure the muscle. For conjunctival repair, an 8-0 polyglactin 910 suture is useful, given its rapid dissolvability. Some surgeons argue that the absorbable and pro-inflammatory properties of polyglactin sutures preclude its use for primary open-globe injury repair.

Choosing the appropriate suture gives a surgeon the best opportunity to successfully close the globe. Video 1 pro-



Video 2. Surgeon's knot.

vides examples of the various sutures discussed above (see also Appendix 1).

(MCW, CMM)

Surgical Knots

Proper suturing and knot tying technique is necessary to ensure proper wound closure, maintain suture tension during healing, and prevent wound leak. It is important to ensure wounds are water tight as wound leaks are associated with higher rates of microbial keratitis and endophthalmitis.¹⁴ Note, all techniques below are described for a right-handed surgeon.

Surgeon's Knot

The surgeon's knot is a variation on the simple square knot that prevents loss of tension prior to the second throw.¹⁵ Surgeon's knots are described according to the number of loops in each throw, most commonly 2-1-1. Nylon suture, because of the low friction, will often require a 3-1-1.¹¹ Video 2 illustrates the surgeon's knot (see also Appendix 2).

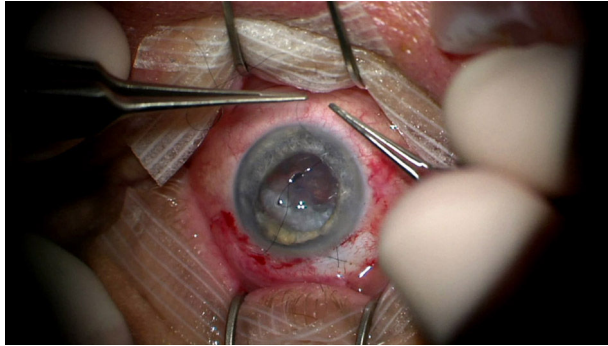
- First, the needle is passed right-to-left through both sides of the wound, the needle is released, and the forceps (in the left hand) are used to grasp the longer suture end (ie, with the needle still attached). The forceps should grasp the suture at an acute angle, such that the suture is an extension of the forceps. A second set of forceps or the needle driver, in the right hand, is then placed in the center or "valley" of the knot, with the jaws closed and parallel to the wound. The forceps are used to wrap the long end of the suture inward toward the center of the knot (clockwise in this example) around the jaws of the needle driver at least twice (the number varies based on suture type and wound

tension). While maintaining the loops around the needle driver, the second forceps or needle driver's jaws are opened and used to grasp the short tail end of the suture. The tail is then pulled toward the surgeon while the long end is pulled away from the surgeon. Enough tension should be applied such that the walls of the wounds approximate.

- The short and long ends should now be on opposite sides from where they started. The needle driver is placed in the center of the wound, jaws closed, parallel to the wound. The forceps are used to wrap the suture once, inward, toward the center of the knot (counterclockwise in this example) around the jaws of the needle driver. The jaws of the needle driver are then opened and used to grasp the tail of the suture while maintaining the single loop over the jaws, and this is pulled tight. With nylon suture, it can be useful to pull at a 90° angle to the direction of the suture embedded in the tissue.
- Further single throws can be added for additional knot security. The long end will always be wrapped around the needle driver, such that it is rotated inward toward the center of the knot (in this example the next loop would be clockwise and the following loop would be counterclockwise, and so on). Typically, one more single throw is placed to complete the 2-1-1 or 3-1-1 knots that are used in globe closure.

Slip Knot

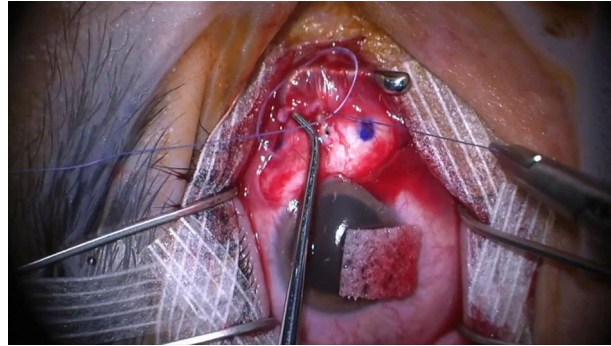
A slip knot uses a 1-1-1 knot and is useful in corneal wounds since the knot tension can be adjusted at any time, particularly if the final tension is to be determined at the end of the closure. When a corneal laceration is large or complex, requiring multiple sutures, it can be difficult to gauge the appropriate tension when starting the closure. All sutures are left adjustable until the final tensions are appropriate across the length of the wound, at which time they are locked down. Sutures that are too tight can cause astigmatism, whereas sutures that are too loose may allow wound leakage. Additionally, the 1-1-1 knot results in a much smaller knot that is easier to rotate and bury in the corneal stroma. The knot is constructed with three single overhand knots; however, the first two knots are tied in the same direction. As the name implies, the knot can be "slipped" along the suture to tighten or loosen the tension prior to placing the third



Video 3. Slip knot.

and final throw. Video 3 illustrates the slip knot (see also Appendix 3).

- First, the needle is passed right-to-left through both sides of the wound, the needle is released and the forceps (in the left hand) are used to grasp the longer suture end (ie, with the needle still attached). The forceps should grasp the suture at an acute angle such that the suture is an extension of the forceps. The needle driver, in the right hand, is then placed in the center of the wound, between the two suture ends, with the jaws closed and parallel to the wound. The forceps are then used to wrap the long end of the suture inwards towards the center of the knot (clockwise in this example) around the jaws of the needle driver one time. While maintaining the loops around the needle driver, the needle driver's jaws are opened and used to grasp the tail end of the suture. The tail is then pulled toward the surgeon while the long end (in the forceps) is pulled away from the surgeon.
- The directionality of this second suture is essential to creating the slip knot. The short and long ends should now be on opposite sides from where they started. The needle driver is placed "outside" the knot or "outside" the valley, meaning it is placed on the side of the long suture that is not adjacent to the short end. In this example, that would be on the right side of the long suture. The forceps in the left hand then wrap the suture around the needle driver away from the wound (clockwise in this example). The needle driver is then rotated to the right to grab the short end and pull it through. The long and short side of the suture material must be laid down in the same orientation as before the second throw.



Video 4. Securing an extraocular muscle.

- The result is that there are two knots thrown in the same direction.
- This slip knot can be adjusted to the desired suture tension. If multiple sutures are being placed, the needle can be cut at this time, leaving the tails long enough to place the final throw that ultimately locks the knot.
- Multiple sutures can be placed in this manner. Once the desired tension is achieved along the entire wound, a single throw should be placed to lock each knot. This is done in the conventional fashion, with the needle driver placed in the center of the knot, and the long end is wrapped around once in an "inward" direction. In this case, it would be wrapped counterclockwise. The short tail is then pulled through and the knot is locked.
- The tension of each suture must be checked prior to tying a knot, because tension changes in one suture will affect the tension of adjacent sutures.

Extraocular Muscle Secure Suture

Proper technique to secure an extraocular muscle to the globe is important for disinsertion and reinsertion of muscles during OGI repair. This suture prevents the surgeon from losing the muscle behind the globe during the case and allows for precise reinsertion to minimize post-operative motility abnormalities. Video 4 details the proper way to secure an extraocular muscle (see also Appendix 4).

- The muscle is isolated and marked, a double-armed 6-0 polyglactin 910 suture on a spatulated needle is passed full-thickness through the middle third of the muscle, approximately 1 mm behind the tendon insertion. The suture is

pulled, allowing for equal length tails, and a 3-1-1 surgeon's knot is tied. When cinching this suture, two needle drivers are used to hold the suture tails close to the knot and pull evenly and parallel to the ground to lay the knot flat.

- One of the needles is loaded and passed partial thickness through the muscle belly, starting just posterior the central knot and exiting at the lateral muscle edge. If the suture is appropriately weaved partial thickness, the needle will remain stationary in the tissue without tilting after it is released from the needle driver. Then, starting from the muscle edge where the suture just exited, a full-thickness locking suture is passed from posterior to anterior through approximately one-fourth to one-third of the muscle width. Care is taken to not accidentally cut the previously placed sutures with the spatulated needle. To lock the suture, the needle is passed through the resulting loop before tightening. The knot is then rotated posteriorly by gently pulling on the anterior exiting portion of the suture.
- The same step is repeated on the other side of the muscle using the second arm of the suture.
- The muscle is now secure to be disinserted. Care is taken to not cut suture material when disinserting the muscle from the globe. The needles should not be cut off as they will be used to reinsert the muscle at the desired origin once globe repair is complete.¹¹

Locking Knot

A locking knot is a temporary secure hold in the suture material to maintain tension on a wound during repair. This is usually done after the first throw, which allows the surgeon to maintain the tension required to hold the wound edges together while reloading the needle. The tension can then be maintained while making the remaining throws to complete the knot. This knot requires that the first throw has multiple loops (typically two or three). This is most commonly used with corneal nylon sutures.

- The first throw of the knot uses two or more loops (see surgeon's knot, above).
- After tightening the suture, both ends of the suture are pulled evenly toward one side of the wound. Typically, one hand is kept stationary while the other moves the suture end to the first hand's side, pulling them together. This "locks"

the first throw under tension. Care is taken to ensure even pulling; otherwise, the knot may become loose.

- The second throw is carefully done so as to not disrupt the tension on the locked knot. Note, a third throw is still needed to stabilize and secure the knot.⁸

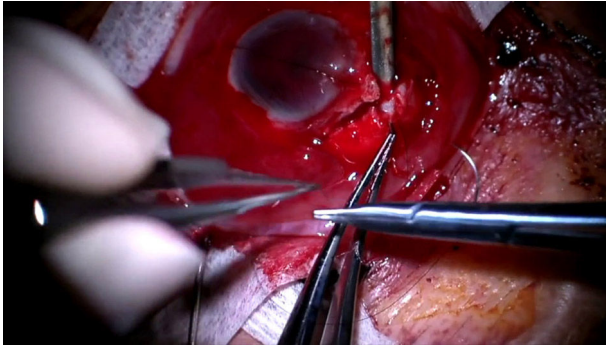
(CMM, MCW)

Ship-to-Shore Suturing

Although ship-to-shore suturing is a concept commonly discussed in penetrating keratoplasty, moving from the graft to the host tissue, this technique is highly relevant to OGI. Specifically, ship-to-shore suturing is an approach in trauma surgery to repair jagged wounds often with small flaps and wounds with sharp, angled edges.

Jagged wounds present two major challenges: alignment and wound stability. Ship-to-shore suturing assists with both. The concept is to place a suture at the location of a turn or corner in the wound, moving from the side with a more acute angle (ie, the smaller side), like a mobile flap, to the side with more tissue.⁸ When tightened, this pulls the tissue together, as a ship pulled to shore. By moving from the less stable flap ("ship" side) of the wound to the more robust ("shore") side the surgeon has more control over the needle and suture placement. Furthermore, by joining the jagged corners of the zig-zag wound, this aligns anatomical landmarks and eases repair of the remainder of the wound. For this reason, ship-to-shore suturing should be performed early in jagged wound repair. Notably, unlike in penetrating keratoplasty, where the anatomic relationship of the "ship" and "shore" are constant, in open globe repair, the "ship" side of the wound can change, even within a single wound. Every corner of a jagged wound should be treated independently, assessing which side has the acute angle or flap as the "ship" and which side has more stable tissue as the "shore" side. Video 5 demonstrates proper ship-to-shore suturing (see also Appendix 5).

- Wound edges should be explored and identified. Turns within a jagged wound must be located and the acute flap ("ship") side as well as the corresponding angle in the more robust ("shore") side identified.
- Start with toothed forceps in the left hand and needle driver with a nylon suture (size dependent on location of wound) on a spatulated needle in the right hand. With the toothed forceps,



Video 5. Ship-to-shore suturing.

the edge of the “ship” edge of the wound is grasped. A partial-thickness pass through the “ship” side is performed using the needle driver, exiting at the wound margin.

- Next, the “shore” edge of the wound is grasped, and another partial-thickness pass at equal depth through the “shore” side of the wound is performed using the needle driver.
- If the sclera is being repaired, a surgeon’s knot using a locking technique is tied in a 3-1-1 fashion. If the cornea is being repaired, a slip knot can be used. If intraocular contents are extruding, a spatula can be helpful in repositioning the uvea so contents do not get caught in the wound closure.

(MCW, CMM)

Key Learning Points

- Post-traumatic endophthalmitis occurs in about 10% of cases and can be lowered to 0.9% in the setting of systematic institution of antibiotic therapy.

- At our institution, intravenous vancomycin in tandem with a third-generation cephalosporin is used for a total of 48 hours to provide coverage against a wide spectrum of possible organisms.
- Postoperatively, topical fluoroquinolones are used for 1 week.
- For sustained wound support, a nonabsorbable suture (eg, nylon) should be used.
- Select suture size based on wound location: corneal repair with 10-0 nylon, limbal repair with 9-0 nylon, and scleral repair with 8-0 nylon.
- Spatulated needles are helpful for partial-thickness passes through cornea, sclera, or muscle, whereas reverse cutting needles are helpful for traction sutures.
- Surgeon’s knots are particularly useful in limbal, scleral, and conjunctival closure because they maintain tension between the first and second throws.
- Slip knots allow the surgeon to adjust the tension prior to completing the knot. The knot is also less bulky, which is useful in corneal wounds.
- Extraocular muscle suturing (securement and disinsertion) may be necessary to expose hidden posterior scleral wounds.
- Locking knots are useful for maintaining tension during wound repair temporally.
- Ship-to-shore suturing improves anatomic alignment and stability in jagged wounds and should be an early step in OGI repair.

Appendix 1. Video 1 Transcript

- 00:07** Today we will be reviewing suture choice during open-globe surgery. We start by reviewing corneal suturing, which uses a 10-0 nylon suture. We do this with a spatulated needle, which is important because the tip is flat on the upper and lower surfaces, allowing precise depth control through the cornea.
- 00:26** This patient suffered a full-thickness corneal laceration. We can see the surgeon has placed two corneal sutures already but has not tied them, to allow adjustment of the tension of the suture, and has now placed a third corneal suture, again using this 10-0 nylon suture. After closing, ultimately they have placed five sutures and rotated the knots for an excellent wound closure.
- 00:49** Next, we move to limbal suturing using the 9-0 nylon suture, again on a spatulated needle. This patient has a full thickness laceration through the sclera limbus and cornea and appropriate limbal alignment is essential for closing this wound. Again, we do so using the slightly larger and more sturdy 9-0 nylon suture on the spatulated needle.
- 01:12** Continuing with our nylon suture, we're now moving to the larger 8-0 nylon for scleral wound closure, again on a spatulated needle. This patient you can see an excellent limbal wound closure but as the wound continued more posteriorly through the sclera and towards the muscle, we now must close this scleral wound. We're doing so with again a slightly larger 8-0 nylon suture in interrupted fashion.
- 01:39** As those wounds move more posteriorly, we often need to isolate the muscle to see the scleral wounds. For this, we like to use a 2-0 silk that is threaded through the tip of a Gass hook. So here, we've hooked the muscle. And now you can see the Gass hook with the silk threaded through the hole. This is then used to go around the muscle and pull the silk suture through to have control over that muscle.
- 02:07** When we need to remove the muscle to further assess scleral injury, we like to imbricate the muscle using a double-armed 6-0 Vicryl suture (made by Ethicon Inc, Somerville, NJ). Vicryl is a good choice here, because it allows us to maintain good tension while having a suture that will dissolve over the course of the following months. The double-armed nature allows us to have the potential to reattach the muscle. Once we detach the muscle, you can see that we have good control over the muscle itself while preventing it from slipping behind the globe.
- 02:38** For conjunctival closure, we also recommend using an 8-0 Vicryl suture on a spatulated needle. This allows once again for good tension on the wound for healing but also a suture that will dissolve and not be too bothersome to the patient. Conjunctiva can be closed in an interrupted fashion and a running fashion, as seen here, or even taking episcleral bites using these needles.

Appendix 2. Video 2 Transcript

- 00:07** This 34-year-old man was punched in the eye and sustained a globe rupture. The curvilinear scleral wound is approximately 12 mm, with prolapsed uvea. A conjunctival peritomy has already been performed.
- 00:23** In this case, 8-0 nylon suture was used to close the entire length of the wound in an interrupted fashion with a simple 3-1-1 surgeon's knot, which we will examine closely here. This surgeon passes the suture partial thickness, near-full depth, to approximate the edges of the wound. The depths are carefully matched on either side of the wound to prevent overriding or buckling of the sclera.
- 00:57** The suture is then pulled through, leaving a short tail that is easy to grasp, but not so short that it pulls through inadvertently.
- 01:06** In her left hand, the surgeon holds the long end of the suture with tying forceps. In her right hand, she places the needle driver in between the two sutures, and her left hand wraps the suture around the needle driver three times.
- 01:28** Notice how she positioned the tip of the needle driver next to the short tail, making it easier to grab the tail and pull the suture through. Doing this makes it less likely for your loops to unravel from the needle driver as you try to grab your short tail. Her instruments then cross and the suture is pulled evenly to lay the knot flat.
- 01:51** Her left hand continues to hold the long end of the suture and the needle driver is again placed between the sutures and overlying the wound. Placing the needle driver in between the sutures ensures that the knot is tied in the correct orientation every time.
- 02:11** The long end is then wrapped around the needle driver only one time and then the short tail is grasped and pulled through the loop.
- 02:24** This is repeated one final time to complete the third square knot. Notice how she did not release the long end of the suture from the tying forceps in between the second and third throws as this reduces unnecessary movements.
- 02:43** She will now repeat this process and place another interrupted surgeon's knot. To improve your suturing skills, try to use the forceps to hold the long end of the suture at an acute angle, such that if you were to draw a line along the length of the forceps, it would continue along the length of the suture and not veer off at a right angle. Doing this makes it easier to wrap the suture around the needle driver and avoid unwanted kinks or resistance to proper loops.
- 03:22** One final knot is being placed at the nasal most aspect of the wound. See here the partial thickness bite being placed to approximate the edges of the sclera. This is then pulled through and the tail is left short. The suture is wrapped three times (two, three) around the needle driver and pulled flat. This is repeated with one single loop for the second square knot and then a final third time and the tails are cut short. The scleral sutures are now complete.

Appendix 3. Video 3 Transcript

- 00:07** This 60-year-old man sustained a penetrating corneal wound from a metallic foreign body that embedded in the lens. You can appreciate the actively leaking central corneal wound. A slip knot is used for corneal wounds to ensure the proper tension.
- 00:26** A 10-0 nylon suture is used for this slip knot.
- 00:31** The suture tip is introduced into the cornea at a 90° angle, and the wrist is supinated to guide the needle partial thickness, near full depth, taking care to have the same depth on either side of the wound. If the depths are not equal, then this may result in a shelved wound, and the refractive outcome may be poor. The suture is pulled through leaving a short tail.
- 00:57** The tying forceps in the left hand grasp the long end of the suture and the forceps in the right hand are placed in between the short and long tails. The left hand then wraps a single loop around the forceps in the right hand and the short end is pulled through. Note the direction of the loop is based on the forceps in the right hand being placed in between the short and long tails. So you can think of the suture as being looped in towards the center of the knot.
- 01:30** For the second single square knot, the left hand continues to hold the long end of the suture. However, the right-hand forceps are placed next to the long end of the suture that is not adjacent to the short tail—or you can think of it being placed outside the knot. When the suture is wrapped once around the forceps, you see it as being looped out and away from the center of the knot. The right hand then moves around to the right to grasp the short tail and pull it through.
- 02:07** The directionality of this second suture is essential to a successful slip knot. Let's watch this one more time. See how the forceps are placed outside of the knot. The loop is rotated outward, then the hand comes around to the right and grabs the short tail and is pulled tight.
- 02:28** At this point we have a slip knot and the tension is carefully adjusted. Once the surgeon is happy with the tension, a final single square knot is placed in the conventional fashion. Here the forceps are placed between the short and long tails and the suture is looped in towards the center of the knot. The tension is no longer adjustable and the tails are cut short. The suture is then rotated.
- 03:01** This second case will demonstrate why the slip knot is especially useful when multiple corneal sutures are placed next to each other in larger or more irregular wounds. Commonly, the first suture or sutures may be placed too loosely or too tightly, which cannot be fully appreciated until the wound is closed and the regular corneal architecture is restored. If nonadjustable knots were used, then the surgeon could not go back and modify the tension and he would need to repass those sutures. This is why the slip knot is particularly useful in these scenarios.
- 03:42** Here the surgeon has placed the first two throws of a slip knot for each of these sutures. The tails were left long enough to be able to go back and throw a final single knot once the tension is optimized. The surgeon is adjusting the tensions carefully to avoid inducing unwanted astigmatism while maintaining a good closure.
- 04:05** Once he is happy with the tension, a single square knot is tied for each suture. The tails are cut short and the knots are buried.

Appendix 4. Video 4 Transcript

- 00:07** This 46-year-old man sustained a penetrating open-globe injury from a nail. The medial rectus was split. In this video we will demonstrate the secure muscle suture that is placed prior to disinserting the muscle from the globe in order to explore and repair the underlying sclera.
- 00:30** A Jameson hook has been used to isolate the muscle, and the edges have been marked. Using a double-armed 6-0 Vicryl suture on a spatulated needle, a full-thickness bite is passed through the central third of the muscle belly. This suture is pulled, allowing for equal-length tails until you see the crease from where the suture was folded in the package. This is then tied with a surgeon's knot in a 3-1-1 fashion.
- 01:09** Here, the first square knot is being placed, and the surgeon is going to grab close to the knot and pull the sutures parallel to the ground with equal tensions, so that it lays flat. The remaining two single square knots are then placed.
- 01:31** One of the needles is then loaded and inserted just posterior to the central knot and passed partial-thickness through the muscle and exiting at the muscle edge. Here, you can tell this suture is partial thickness, because it does not move or tip back when the surgeon releases his grasp. Using that same needle, a full-thickness bite is passed through the outer one-third of the muscle in a locking fashion. Here the surgeon is grabbing the needle that has been passed through the loop that was just created in order to lock the suture. This is then pulled tight and the knot is rotated posteriorly. This side is now complete.
- 02:26** The other needle is then loaded, and the same thing is repeated on the other side of the muscle. First, we have the partial-thickness bite starting centrally and exiting at the muscle edge. And then the surgeon is placing a full thickness bite through the peripheral third of the muscle. At this point our secure suture is complete. The muscle is cut from the globe being careful not to damage the sutures that were just carefully placed. And now the underlying scleral defect is revealed.

Appendix 5. Video 5 Transcript

- 00:06 This video will review ship-to-shore suturing in open-globe surgery. Ship-to-shore suturing is a technique that we use in traumatic open-globe surgery to help to reapproximate jagged wounds. This helps to create an anatomical alignment; the technique also provides stability during the process of repairing these difficult wounds. So, let's review a couple of these cases.
- 00:36 The first case is the zone II-to-III rupture. You can see here the zigzag rupture with two different points that would be amenable to ship-to-shore suturing.
- 00:47 We start with the what we call the "ship" side of the wound. This is the side with the flap and the less stable part of the wound. We want to start here, because it gives us the most control over placement of our suture and will cause the least amount of torquing on the wound as we then move over to the opposite side. We refer to the opposite side as the "shore" side, as it has a larger amount of tissue and higher stability. Here the surgeon is using a spatula to hold back the intraocular contents. And as they tie the knot, the ship side is pulled to the shore side, reapproximate the wound into its normal anatomical position.
- 01:35 Moving to the second jagged portion of this wound, we can clear up around the wound margin, get better visualization of this area, and then once again identify that flap. Note, that for this portion of the wound the "ship" portion is actually on the corneal side, which is opposite from earlier. This highlights that the ship and shore concept is not a fixed anatomical discussion but rather is relative to the wound that you are working with.
- 02:09 Now that the second suture is placed, once again we can use the spatula to hold back the intraocular contents and tighten the suture. After placing these two sutures, we can see that we have excellent anatomic alignment for this wound for the remainder of the closure.
- 02:24 The second case is a paintball injury, with this limbal wound that takes a sharp turn. We can see the flap portion of the wound, or the ship portion, in the left hand of the surgeon here. We will place our suture through this less stable ship portion and then move over to the shore portion of the wound, in this case the limbus, which again is the larger tissue more stable portion of the wound. Once again, we'll use that spatula to push back some those intraocular contents while we suture the wound closed.
- 02:56 Overall, you can see how the ship-to-shore suturing has pulled that corner up into appropriate alignment. Ultimately, the repair is completed and we can see the limbal wound with that left turn.
- 03:10 Our third case is the result of a fall and a similar injury to the previous case. We've isolated the flap as the first portion that we suture, the ship portion. We then move again to the limbus as the shore portion. We tighten that knot to pull that ship into the shore for good anatomic alignment for the corner. Overall, there was an excellent result from this wound closure.

References

1. Zhang Y, Zhang MN, Jiang CH, Yao Y, Zhang K. Endophthalmitis following open globe injury. *Br J Ophthalmol* 2010;94:111-4.
2. Huang JM, Pansick AD, Blomquist PH. Use of intravenous vancomycin and cefepime in preventing endophthalmitis after open globe injury. *J Ocul Pharmacol Ther* 2016;32:437-41.
3. Long C, Liu B, Xu C, Jing Y, Yuan Z, Lin X. Causative organisms of post-traumatic endophthalmitis: a 20-year retrospective study. *BMC Ophthalmol* 2014;14:34.
4. Ahmed Y, Schimel AM, Pathengay A, Colyer MH, Flynn HW Jr. Endophthalmitis following open-globe injuries. *Eye (Lond)* 2012;26:212-17.
5. Andreoli CM, Andreoli MT, Kloek CE, Ahuero AE, Vavvas D, Durand ML. Low rate of endophthalmitis in a large series of open globe injuries. *Am J Ophthalmol* 2009;147:601-8.e2.
6. Andreoli, C.; Teiger, MG.; Kloek, C.; Lorch, AC. Antibiotic prophylaxis for open globe injury: expert opinion controversies in open globe injury management. In: Grob, S.; Kloek, C., editors. *Management of Open Globe Injuries* Cham, Switzerland: Springer; 2018. p. 47-61.
7. Tabatabaei SA, Soleimani M, Behrooz MJ, Sheibani K. Systemic oral antibiotics as a prophylactic measure to prevent endophthalmitis in patients with open globe injuries in comparison with intravenous antibiotics. *Retina* 2016;36:360-5.
8. Liang JL, Tiwari T, Moro P, et al. Prevention of pertussis, tetanus, and diphtheria with vaccines in the United States: recommendations of the Advisory Committee on Immunization Practices (ACIP). *MMWR Recomm Rep* 2018;67:1-44.
9. Iyer MN, Kraniias G, Daun ME. Post-traumatic endophthalmitis involving *Clostridium tetani* and *Bacillus* spp. *Am J Ophthalmol* 2001;132:116-7.
10. Libre PE, Mathews S. Endophthalmitis prophylaxis by intracameral antibiotics: in vitro model comparing vancomycin, cefuroxime, and moxifloxacin. *J Cataract Refract Surg* 2017;43:833-8.
11. Lee, J.; Cater, KD. *Basic Principles of Ophthalmology* 3rd ed ed. San Francisco: American Academy of Ophthalmology; 2015. Suture Materials and Needles; p. 111-8.
12. Tannen, BL.; Hersh, PS.; Sohn, EH. *Surgical repair: ocular injuries Basic Techniques of Ophthalmic Surgery* 2nd ed ed. San Francisco: American Academy of Ophthalmology; 2015. p. 555-67.
13. Sullivan, P. *The Open Globe—Surgical Techniques for the Closure of Ocular Wounds* Eyelearning Ltd; 2013. Surgical principles; p. 13-30.
14. Kong GY, Henderson RH, Sandhu SS, Essex RW, Allen PJ, Campbell WG. Wound-related complications and clinical outcomes following open globe injury repair. *Clin Exp Ophthalmol* 2015;43:508-13.
15. Wladis, EJ.; Langer, PD. *Basic Principles of Ophthalmology* 3rd ed ed. American Academy of Ophthalmology; 2015. Suturing and knot tying; p. 177-86.