



Case report

House advancement flap anoplasty in anal stenosis post hemorrhoids surgery. A case report

Kinyamaniyi Kamabu^{a,b}, Okullo Obong Geoffrey^b, Sonye Magugu Kiyaka^a, Mamadi Owera Francis^{a,b}, Abdikadar Mohamud Arab^{a,b}, Franck Katembo Sikakulya^{a,c,*}

^a Faculty of Clinical Medicine and Dentistry, Department of Surgery, Kampala International University Western Campus, Ishaka-Bushenyi, Uganda

^b Department of Surgery Lira Regional Referral Hospital, Uganda

^c Faculty of Medicine, Université Catholique du Graben, Butembo, Democratic Republic of the Congo

ARTICLE INFO

Keywords:

Hemorrhoidectomy

Anal stenosis

House advancement flap anoplasty

ABSTRACT

Introduction and importance: Anal stenosis following hemorrhoids surgery is rare, and very distressing to the patients. It is graded according to its severity namely mild, moderate or severe. Majority of severe cases require surgery. The treatment is complex shown by the multiplicity of flaps and techniques described in the literature. This case report then reminds surgeons about the complications of hemorrhoidectomy and the complexity of their management. In addition, it challenges the surgeons about their practice on hemorrhoids.

Case presentation: A 30-year-old male who presented with difficulty in passing stool with intermittent low abdominal pain for 4 weeks following a surgery for hemorrhoids. A House Advancement Flap was designed to match the transverse incisions and hence the width of the mucosal defect to be replaced. Any intra- or post-operative complications were noted and the patient was discharged on the second postoperative day from the hospital. Patient had no complaints in the post-discharge period.

Clinical discussion: Overzealous hemorrhoidectomy is one of the primary causes of stenosis of anal canal. Other causes that have been reported include anorectal diseases, other anorectal surgeries and radiotherapy. Physical examination majorly leads to the diagnosis of anal stenosis. Its treatment is conservative in mild cases while in severe anal stenosis a House Advancement Flap is one of the possible surgical management options.

Conclusion: Anal stenosis is a rare condition which requires good evaluation for its better management. Given its simplicity and successful results, a House Advancement Flap anoplasty is a reliable treatment of severe anal stenosis.

1. Introduction

Anal stenosis is an uncommon but serious condition that causes the anal canal to become constricted by fibrous tissue [1]. It is characterized by cicatrices tissue and a decrease in the flexibility of the anal canal, as well as changes in the anal canal's diameter [2]. It may be due to an inflammatory process like in Crohn's disease and ulcerative colitis or it can also be caused by tuberculosis, some venereal diseases, post-radiotherapy, laxative addiction, and other conditions. Nevertheless, research has shown that overzealous hemorrhoidectomy causes 90 % of anal stenosis [1]. Anal stenosis is classified into three grades namely mild, moderate and severe according to anal examination with Hill Ferguson retractor or index-small finger [3]. Patients consistently

complain of changes in the way of passing their feces (small, thin, slender, and elongated), disposal issues, feeling uncomfortable after defecating, and pain while defecating [4,5]. Preventing postsurgical anal stenosis is the best treatment [6]. In Milligan-Morgan hemorrhoidectomy for instance, anal stenosis is avoided by preserving appropriate muco-cutaneous bridges and performing internal sphincterotomy if necessary; but if there is anal stenosis, the course of treatment should depend on the condition's severity, underlying causes, and location [7]. A formal anoplasty should be done to repair the loss of anal canal tissue in cases of more severe anal stenosis. The distribution of the more malleable anoderm into the anal canal to replace the scarred lining at that level is made possible by several types of flaps that have been described for anal stenosis [4].

* Corresponding author at: Faculty of Clinical Medicine and Dentistry, Department of Surgery, Kampala International University Western Campus, PO. Box 70, Ishaka-Bushenyi, Uganda.

E-mail address: francksikakulya@gmail.com (F.K. Sikakulya).

<https://doi.org/10.1016/j.ijscr.2023.107894>

Received 5 November 2022; Received in revised form 4 January 2023; Accepted 10 January 2023

Available online 11 January 2023

2210-2612/© 2023 Published by Elsevier Ltd on behalf of IJS Publishing Group Ltd. This is an open access article under the CC BY-NC-ND license (<http://creativecommons.org/licenses/by-nc-nd/4.0/>).

In this report, we used a House advancement flap anoplasty in a patient who developed a severe anal stenosis after Milligan–Morgan hemorrhoidectomy. This work is reported in line with the SCARE 2020 criteria [8].

2. Case presentation

A 30-year-old male, who presented with painful defecation and intermittent abdominal distention of 4 weeks' duration. The patient reported history of hemorrhoidectomy done 5 weeks ago. After this surgery, he could remain more than 20 min in the toilette passing hard stool facilitated by using a finger to dilate the anal canal, and associated with severe pain. He did not have a history of smoking, diabetes, or any other chronic illness. At examination, the patient appeared sick, his vital signs were stable, and a perineal examination revealed significant anal stenosis with a thick scar around the anus that prevented the tip of the little finger from being inserted (see Fig. 1 below: showing 0.7 cm of anal opened by a dissecting forceps). Investigations done, CBC and abdominal ultrasound scan, were normal. After the diagnosis of severe anal stenosis was made, the patient received preoperative doses of ceftriaxone 1 g and metronidazole 500 mg IV, and was brought to the operation room. The patient was given spinal anesthesia and put in the Jackknife position while being prepped and draped in accordance with standard procedure. The scar tissue was partially removed anteriorly and posteriorly. The flap was carefully constructed so as not to damage the blood supply. The base of the flap was sutured to the rectal mucosa at the dentate line using 2/0 vicryl (see Fig. 3 below). Anoderm and perineal skin were stitched to the flap's sides. The wound was closed from the distal end to the flap's apex (see Fig. 4 below). On the second postoperative day, the patient was discharged from the hospital with oral Ampicillin-Cloxacillin for five days, stool softener regime, and advised to take two warm baths per day on the site of surgery up to wound healing. The patient was then seen on postoperative day 7, with no constipation and a well-healing wound and held completely after 8 weeks.

3. Discussion

Anal stenosis is a constriction of the anal canal that can be caused by either a true anatomic stenosis or a functional hypertonic internal anal sphincter. In functional stenosis, there is a hypertonic internal anal sphincter while in anatomic stenosis (stricture), a normal anoderm is

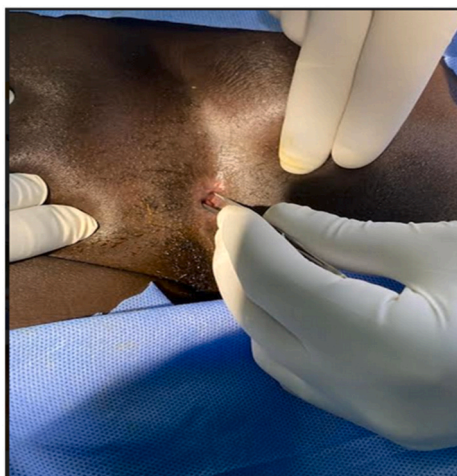

Fig. 1. Anal canal not allowed a small finger but a dissecting forceps.

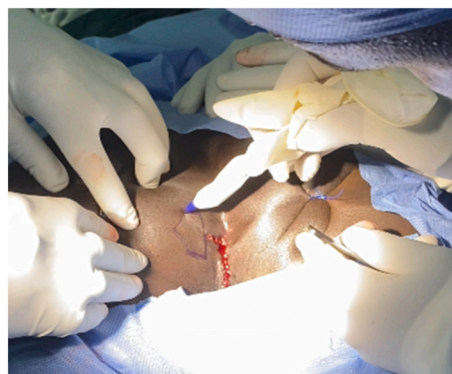

Fig. 2. Flap created perpendicularly to the longitudinal incision.

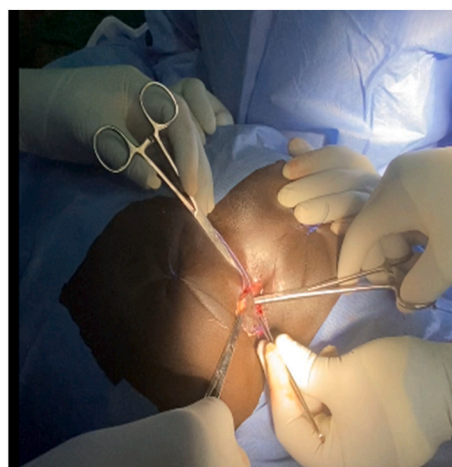


Fig. 3. Flap sutured to the rectal mucosa at the dentate line.

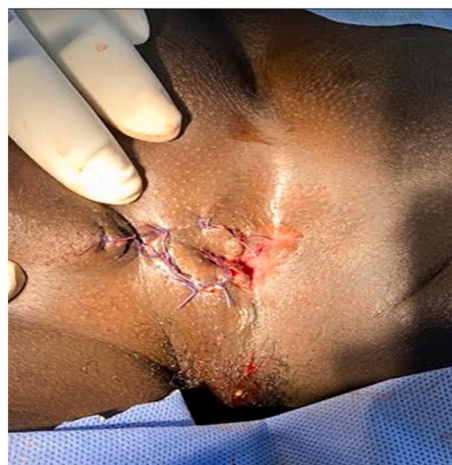

Fig. 4. After anoderm and perineal skin stitched to the flap's sides.

replaced by variable degrees of constricted, non-elastic cicatrized tissue [9]. Both intrinsic and extrinsic pathological mechanisms can result in stenosis. A number of disorders that result in non-cutaneous scarring sores can lead to anal stenosis. The stenotic segment may be situated close to or far from the anal canal, but most frequently, the entire anal canal is recognized to be affected by the abnormalities [5]. Overzealous hemorrhoidectomy is the primary cause of stenosis of anal canal in 90 % with an incidence of 1.5 %–3.8 %. However, in the study done by Njadat, Rumman, Maaita, Almbaidin and Qusus [10], the incidence of anal

stenosis was 7.2 %. Moreover studies have revealed that anal stenosis is rare in Milligan-Morgan and stapled rectal mucosectomy procedures [4], current studies however, have shown the implication of previous surgery among the key role of its etiopathogenesis [11]. Zhang et al. [12] in their study comparing Milligan-Morgan and stapled rectal mucosectomy procedures found that the former is more prone to induce anal stenosis than the later. A number of risk factors have been considered to be related to this condition after Milligan-Morgan procedure, among them the number of piles to remove at one surgery and the history of previous hemorrhoids surgery done [10]. An intriguing hypothesis states that stenosis results from micro-dehiscences of the suture line, which are followed by a submucosa phlogosis and the creation of retractile scar tissue. Undoubtedly, stenosis can be caused by improper suture placement, too low and/or large removal of hemorrhoidal tissue, or asymmetrical, too deep, or more appropriately, at full thickness [13].

In our case, the anal stenosis was caused by complications of surgery using Milligan-Morgan procedure. From our understanding, this complication occurred as a consequence of a deep ligature of pedicles and removal of multiple piles which end up creating a circumferential scar formation which caused a narrowing of rectal mucosa. This severe grade anal stenosis occurred just a month post-operation.

The severity of the stricture and degree of anal canal involvement help to categorize anatomical canal stenosis [3]. As a result of the difficulty of painful digital rectal examination in this case, even with forced dilatation with a little finger, the patient was determined to have severe anal stenosis. Generally, assessment of stenosis severity guides the treatment approaches. Mild stenosis is always treated conservatively using anal dilatation and laxatives, with or mechanical fingers to be done every day. Sphincterotomy is performed mostly for moderate stenosis. Anoplasty however is a procedure performed to overcome the loss of the anal canal function in severe cases [4].

Anoplasty approaches have been found to be universally beneficial, despite certain research showing effective treatments for anal stenosis. Various studies, however, have recommended a number of anoplasty techniques [4]. In our case report, we performed anoplasty using House Advancement Flap method and the patient reported passing stool with less pain after surgery. This technique has been the first one to be reported in our facility. Our decision to use this technique was based on the theory that the anal stenosis was caused by circumferential line stricture due to multiple piles removed following Milligan-Morgan hemorrhoidectomy procedure. Although it is, different studies on this topic have never come out with the diameter or caliber of the anal canal to achieve while performing this advancement flap procedure. However, Gülen, Leventoğlu and menteş [14] using Diamond flap anoplasty found that a caliber of 25 to 26 mm of the anal canal was successful associated with good outcome. In our case, we used small and index finger to “estimate” the opening of the anal canal after House Advancement Flap. It is well known that, House flap anoplasty reduces stress at the suture line and improves blood flow to the flap, especially in cases of severe anal stenosis [15], and compared to rhomboid/diamond and Y–V flap, its complications and recurrence are much lower [11]. Up to now, the patient has not yet reported any post-surgery disturbance.

4. Conclusion

As anal stenosis is a rare condition which still can occur as a complication of hemorrhoids surgery, its best treatment is prevention by using adequate principles. However, when it occurs, it must be evaluated correctly so that a good method of repair is applied. Whenever a severe stenosis is diagnosed, a House Advancement Flap is simple and safe, reliable and curative procedure to use for its treatment.

Consent for publication

Written informed consent was obtained from the patient for

publication of this case report and accompanying images. A copy of the written consent is available for review by the Editor-in-Chief of this journal on request.

Ethical approval

The study is exempt from ethical approval in our institution.

Sources of funding

There was no external funding source for this report.

Author contribution

KK, MOF researched the literature and wrote the manuscript. KK, MOF and AMA operated on the patient and had the idea for this case report. KK and MOF checked the manuscript and made corrections. OOG and FSK provided the overall guidance and support. All authors read and approved the final manuscript.

Guarantor

Kinyamaniyi Kamabu.

Research registration

None.

Declaration of competing interest

The authors declare no conflicts of interest.

References

- [1] M. Chiarelli, A. Guttadauro, M. Maternini, G. Bianco, F. Tagliabue, P. Achilli, F. Gabrielli, The clinical and therapeutic approach to anal stenosis, *Ann. Ital. Chir.* 89 (3) (2018) 237–241.
- [2] M. Tahamtan, L. Ghahramani, H. Khazraei, Y. Tabar, A. Bananzadeh, S. Hosseini, F. Hajihosseini, Surgical management of anal stenosis : anoplasty with or without sphincterotomy, *J. Coloproctol.* 7 (1) (2016) 13–17.
- [3] I. Khubchandani, Anal stenosis, *Surg. Clin. N. Am.* 74 (6) (1994) 1353–1360, [https://doi.org/10.1016/S0039-6109\(16\)46486-8](https://doi.org/10.1016/S0039-6109(16)46486-8).
- [4] G. Brisinda, S. Vanella, F. Cadeddu, G. Marniga, P. Mazzeo, F. Brandara, G. Maria, Surgical treatment of anal stenosis, *World J. Gastroenterol.* 15 (16) (2009) 1921–1928, <https://doi.org/10.3748/wjg.15.1921>.
- [5] M. Katdare, R. Ricciardi, Anal stenosis, *Surg. Clin. N. Am.* 90 (1) (2010) 137–145, <https://doi.org/10.1016/j.suc.2009.10.002>.
- [6] G. Brisinda, How to treat haemorrhoids, *BMJ* 321 (September) (2000) 582–583.
- [7] J. Milsom, W. Mazier, Classification and management of postsurgical anal stenosis, *Surg Gynecol Obstet* 163 (1) (1986) 60–64.
- [8] R. Agha, T. Franchi, C. Sohrabi, G. Mathew, A. Kerwan, For the SCARE Group, The SCARE 2020 guideline: updating consensus Surgical CAse REport (SCARE) guidelines, *Int. J. Surg.* 84 (2020) 226–230, <https://doi.org/10.1016/j.ijsu.2020.10.034>.
- [9] B. Jain, P. Garg, D. Palmo, D. Mohnaty, V. Agrawal, Anal symptoms to anal obliteration : quackery in proctology continues I, *Trop. Gastroenterol.* 35 (4) (2014) 274–276.
- [10] I. Njadat, K. Rumman, F. Maaaita, F. Almbaidin, Q. Qusus, Risk factors for post hemorrhoidectomy anal stenosis, *IOSR J. Dent. Med. Sci.* 17 (01) (2018) 63–65, <https://doi.org/10.9790/0853-1701096365>.
- [11] G. Gallo, A. Picciariello, G. Tanna, P. Pelizzo, D. Altomare, M. Trompetto, U. Grossi, Anoplasty for anatomical anal stenosis: systematic review of complications and recurrences, *Color. Dis.* (2022) 1–10, <https://doi.org/10.1111/codi.16248>.
- [12] G. Zhang, R. Liang, J. Wang, M. Ke, Z. Chen, J. Huang, R. Shi, Network meta-analysis of randomized controlled trials comparing the procedure for prolapse and hemorrhoids, milligan-Morgan hemorrhoidectomy and tissue-selecting therapy stapler in the treatment of grade III and IV internal hemorrhoids (meta-analysis), *Int. J. Surg.* 74 (2020) 53–60, <https://doi.org/10.1016/j.ijsu.2019.12.027>.

- [13] I. Corsale, M. Rigutini, S. Panicucci, D. Frontera, F. Mammoliti, Stenosis after stapled anopecty : personal experience and literature review, *Clin. Surg.* 3 (2018) 1–5.
- [14] M. Gülen, S. Leventoğlu, B. Menteş, Surgical treatment of anal stenosis with diamond flap anopecty performed in a calibrated fashion, *Dis. Colon ReCtum* 59 (3) (2016) 230–235, <https://doi.org/10.1097/DCR.0000000000000530>.
- [15] H. Yabanöglü, Outcomes of advancement flaps used in the treatment of anal stenosis developing after hemorrhoid surgery : one center experience, *Turk. J. Colorectal. Dis.* 28 (2018) 125–128, <https://doi.org/10.4274/tjcd.64497>.