

A Patient With Recurrent Immune Stromal Keratitis and Adherence Challenges

Amanda Glickman, OD^{a,b}; Amanda Hunter, OD^{a,b}; Paul B. Greenberg, MD, MPH^{a,c}; Ezra Galler, MD^{a,c}; Joseph Mega, OD^{a,b}; John Sellechio, OD^{a,b}

Background: Herpes simplex keratitis (HSK) is a common yet potentially blinding condition caused by a primary or reactivated herpetic infection of the cornea. Immune stromal keratitis (ISK), a type of HSK, is classified by a cellular and neovascularization infiltration of the cornea, and patients with ISK may experience low-grade chronic keratitis for years.

Case Presentation: A 52-year-old man presented to the eye clinic complaining of a watery and itchy right eye with mildly blurred vision. With consultation from a corneal specialist, the

patient was given the presumptive diagnosis of ISK in the right eye based on the unilateral corneal presentation and lack of corneal sensitivity.

Conclusions: ISK presents unilaterally with decreased or absent corneal sensitivity and nonspecific symptoms. It should be at the top of the list in the differential diagnosis in any patient with unilateral corneal edema, opacification, or neovascularization, and the patient should be started on oral antiviral therapy.

Herpes simplex keratitis (HSK) is a common yet potentially blinding condition caused by a primary or reactivated herpetic infection of the cornea.¹ The Herpetic Eye Disease Study established the standard of care in HSK management.² Treatments range from oral antivirals and artificial tears to topical antibiotics, amniotic membranes, and corneal transplantation.³ Patients with immune stromal keratitis (ISK) may experience low-grade chronic keratitis for years.⁴ ISK is classified by a cellular and neovascularization infiltration of the cornea.⁵ We present a case of a patient with recurrent ISK and review its presentation, diagnosis, and management.

CASE PRESENTATION

A 52-year-old man presented to the eye clinic with a watery and itchy right eye with mildly blurred vision. His ocular history was unremarkable. His medical history was notable for hepatitis C, hypertension, alcohol and drug dependence, homelessness, and a COVID-19–induced coma. His medications included trazodone, nifedipine, clonidine HCl, and buprenorphine/naloxone.

On clinical examination, the patient's best-corrected visual acuity was 20/40 in the right eye and 20/20 in the left. Corneal sensitivity was absent in the right eye and intact in the left. Anterior segment findings in the right eye included 360-degree superficial corneal neovascularization, deep neovascularization temporally,

scattered patches of corneal haze, epithelial irregularity, and 2+ diffuse bulbar conjunctival injection (Figure 1). The anterior segment of the left eye and the posterior segments of both eyes were unremarkable.

The differential diagnosis included HSK, syphilis, Cogan syndrome, varicella-zoster virus keratitis, Epstein-Barr virus keratitis, and Lyme disease. With consultation from a corneal specialist, the patient was given the presumptive diagnosis of ISK in the right eye based on unilateral corneal presentation and lack of corneal sensitivity. He was treated with 1-g oral valacyclovir HCl 3 times daily and 1 drop of prednisolone acetate 1% suspension 3 times daily in the right eye.

The patient returned a week later having only used the prednisolone drops for 2 days before discontinuing. Examination showed no change in his corneal appearance from the previous week. The patient was counseled on the importance of adherence to the regimen of topical prednisolone and oral valacyclovir.

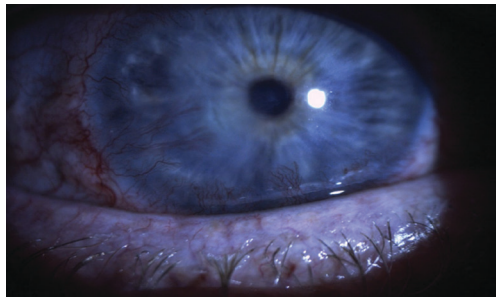
The patient followed up 2 weeks later. He reported good adherence to the ISK medication regimen. His symptoms had resolved, and his visual acuity returned to 20/20 in the right eye. Slit-lamp examination showed improvement in injection, and the superficial corneal neovascularization had cleared. A trace ghost vessel was seen temporally at a site of deep neovascularization (Figure 2). He was instructed to continue valacyclovir once daily and prednisolone drops once daily in the right eye and to follow up in 1 month.

Author affiliations can be found at the end of this article.

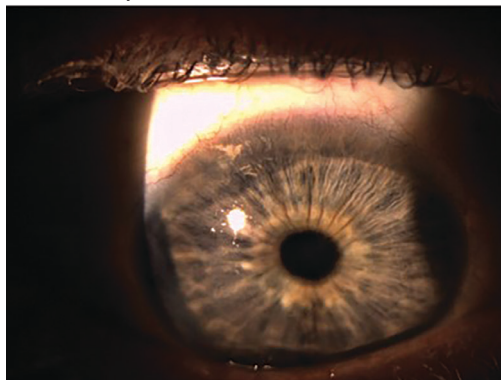
Correspondence:

John Sellechio
(john.sellechio@va.gov)

Fed Pract. 2022;39(10).
Published online October 14.
doi:10.12788/fp.0323

FIGURE 1 Initial Presentation

Zeiss slit-lamp image showing corneal neovascularization, mild corneal haze, and conjunctival injection.

FIGURE 2 Regression at 2-Week Follow-Up

Zeiss slit-lamp image showing regression of corneal neovascularization, haze, and conjunctival injection.

At the 1-month follow-up, the patient's signs and symptoms had reverted to his original presentation. The patient reported poor adherence to the medication regimen, having missed multiple doses of prednisolone drops as well as valacyclovir. The patient was counseled again on the ISK regimen, and the prednisolone drops and 1-g oral valacyclovir were refilled. A follow-up visit was scheduled for 2 weeks. Additional follow-up revealed a resolved corneal appearance and bimonthly follow-ups were scheduled thereafter.

DISCUSSION

HSK is the most common infectious cause of unilateral blindness and vision impairment in the world.² This case highlights the diagnosis and management of a patient with ISK, a type of HSK characterized by decreased corneal sensitivity and unilateral stromal opacification or neovascularization.⁶

ISK is caused by the herpes simplex virus (HSV), a double-stranded enveloped

DNA virus that occurs worldwide with little variation, replicates in many types of cells, has rapid growth, and is cytolytic, causing necrosis of nearby cells. Transmission is via direct contact and there is a lifelong latency period in the trigeminal ganglia. Both primary and reactivation infections of HSK can affect a broad array of ocular structures, from the lids to the retina. Infectious epithelial keratitis, also known as dendritic keratitis, is the reactivation of the live virus and is the most common presentation of HSK. ISK is responsible for 20% to 48% of recurrent HSV disease and is the leading cause of vision loss. ISK is the result of an immune-mediated inflammatory response due to a retained viral antigen within the stromal tissue.⁷ Inflammation in the corneal stroma leads to corneal haze and eventually focal or diffuse scarring, reducing the visual potential.⁷ This presentation may occur days to years after the initial epithelial episode and may persist for years. Although this patient did not present with infectious epithelial keratitis, it is possible he had a previous episode not mentioned as a history was difficult to obtain, and it can be subtle or innocuous, like pink eye.

Symptoms of ISK include unilateral redness, photophobia, tearing, eye pain, and blurred vision, as described by this patient. On examination, initial manifestations of ISK include corneal haze, edema, scarring, and neovascularization.⁷ Again, this patient presented with edema and neovascularization. These signs may improve with prompt diagnosis and treatment. More frequent reactivated disease leads to a higher propensity of corneal scarring and irregular astigmatism, reducing the visual outcome.

The standard of care established by the Herpetic Eye Disease Study recommends that a patient with presumed ISK should be started on oral antiviral therapy and, in the absence of epithelial disease, topical steroids. Oral antivirals, such as acyclovir and valacyclovir, have good ocular penetration, a good safety profile, a low susceptibility of resistance, and are well tolerated with long-term treatment.^{2,8} There were no known interactions between any of the patient's medications and valacyclovir. Oral antivirals should be used in the initial

presentation and for maintenance therapy to help reduce the chance of recurrent disease. Initial treatment for ISK is 1-g valacyclovir 3 times daily. When the eye becomes quiet, that dosage can be tapered to 1 g twice daily, to 1 g once daily, and eventually to a maintenance dose of 500 mg daily.

Topical steroids block the inflammatory cascade, therefore reducing the corneal inflammation and potential scarring, further reducing the risk of visual impairment.⁹ Initial treatment is 1 drop 3 times daily, then can be tapered at the same schedule as the oral acyclovir to help simplify adherence for the patient. After 1 drop once daily, steroids may be discontinued while the oral antiviral maintenance dosage continues. Follow-ups should be performed on a monthly to bimonthly basis to evaluate intraocular pressure, ensuring there is no steroid response.

As seen in this patient, adherence with a treatment regimen and awareness of factors, such as a complex psychosocial history that may impact this adherence, are of utmost importance.⁷

CONCLUSIONS

ISK presents unilaterally with decreased or absent corneal sensitivity and nonspecific symptoms. It should be at the top of the list in the differential diagnosis in any patient with unilateral corneal edema, opacification, or neovascularization, and the patient should be started on oral antiviral therapy.

Author affiliations

^aEye Clinic, Providence Veterans Affairs Medical Center, Rhode Island

^bNew England College of Optometry, Boston, Massachusetts

^cDivision of Ophthalmology, Alpert Medical School, Brown University, Providence, Rhode Island

Author disclosures

The authors report no actual or potential conflicts of interest or outside sources of funding with regard to this article.

Disclaimer

The opinions expressed herein are those of the authors and do not necessarily reflect those of *Federal Practitioner*, Frontline Medical Communications Inc., the US Government, or any of its agencies. This article may discuss unlabeled or investigational use of certain drugs. Please review the complete prescribing information for specific drugs or drug combinations—including indications, contraindications, warnings, and adverse effects—before administering pharmacologic therapy to patients.

Ethics and consent

Written informed consent was obtained from the patient.

References

1. Sibley D, Larkin DFP. Update on Herpes simplex keratitis management. *Eye (Lond)*. 2020;34(12):2219-2226. doi:10.1038/s41433-020-01153-x
2. Chodosh J, Ung L. Adoption of innovation in herpes simplex virus keratitis. *Cornea*. 2020;39(1)(suppl 1):S7-S18. doi:10.1097/ICO.0000000000002425
3. Pérez-Bartolomé F, Botín DM, de Dompablo P, de Arriba P, Arnalich Montiel F, Muñoz Negrete FJ. Post-herpes neurotrophic keratopathy: pathogenesis, clinical signs and current therapies. *Arch Soc Esp Ophthalmol*. 2019;94(4):171-183. doi:10.1016/j.oftal.2019.01.002
4. Holland EJ, Schwartz GS. Classification of herpes simplex virus keratitis. *Cornea*. 1999;18(2):144-154.
5. Gauthier AS, Noureddine S, Delbosc B. Interstitial keratitis diagnosis and treatment. *J Fr Ophthalmol*. 2019;42(6):e229-e237. doi:10.1016/j.jfo.2019.04.001
6. Farooq AV, Shukla D. Herpes simplex epithelial and stromal keratitis: an epidemiologic update. *Surv Ophthalmol*. 2012;5(57):448-462. doi:10.1016/j.survophthal.2012.01.005
7. Wang L, Wang R, Xu C, Zhou H. Pathogenesis of herpes stromal keratitis: immune inflammatory response mediated by inflammatory regulators. *Front Immunol*. 2020;11:766. Published 2020 May 13. doi:10.3389/fimmu.2020.00766
8. Tying SK, Baker D, Snowden W. Valacyclovir for herpes simplex virus infection: long-term safety and sustained efficacy after 20 years' experience with acyclovir. *J Infect Dis*. 2002;186(suppl 1):S40-S46. doi:10.1086/342966
9. Dawson CR. The herpetic eye disease study. *Arch Ophthalmol*. 1990;108(2):191-192. doi:10.1001/archophth.1990.01070040043027

CALL FOR PAPERS Neurology Special Issue

Federal Practitioner invites VA, DoD, and PHS health care professionals and researchers to contribute to a future special issue on neurology. Topics of interest include:

- Multiple sclerosis
- Epilepsy
- Headache and migraine
- COVID-19 and neurology
- Alzheimer and dementia
- Other neurological disorders

Interested authors should submit a proposal to fedprac@mdedge.com with the subject line "Neurology Special Issue" for consideration. For full details, see the Call for Papers posted at bit.ly/callforneuro