

# Awake Cranial Traction and Isolated Anterior Cervical Discectomy and Fusion in the Treatment of Traumatic Subaxial Cervical Facet Joint Dislocations: Analysis of a Cohort of 70 Patients and Predictors of Surgical Failure

ARNALDO SOUSA, MD<sup>1,2</sup>; CLÁUDIA RODRIGUES, MD<sup>1,2</sup>; MANUEL MARQUES, MD<sup>1,2</sup>;  
TIAGO AMORIM-BARBOSA, MD<sup>1,2</sup>; AND RICARDO RODRIGUES-PINTO, MD, PhD, FEBOT<sup>1,2</sup>

<sup>1</sup>Spinal Unit/ Unidade Vertebro-Medular (UVM), Department of Orthopaedics, Centro Hospitalar Universitário do Porto, Porto, Portugal; <sup>2</sup>Instituto de Ciências Biomédicas Abel Salazar, Universidade do Porto, Porto, Portugal

## ABSTRACT

**Background:** Cervical facet dislocations are among the most common traumatic spinal injuries. The management of this type of lesions is still controversial. The objective of the present study was to analyze the results of subaxial cervical facet dislocations submitted to an isolated anterior cervical discectomy and fusion (ACDF) after attempted closed reduction with cranial traction and to identify risk factors for treatment failure.

**Methods:** All patients who were operated on in a tertiary trauma center during an 11-year period (2008–2018) for traumatic single-level cervical facet joint dislocation (AO C F4 injuries) were retrospectively reviewed. Age, use of cranial traction, dislocation characteristics, neurologic injury, surgical data, and follow-up records were reviewed. A minimum of 18 months follow-up was required.

**Results:** A total of 70 patients with a mean age of 56 years (18–90) (72% men) were identified. The C6-C7 level was the most frequently affected (36/70 cases). Spinal cord injury (SCI) was present in 34% of the cases. Bilateral dislocations and rigid spines were risk factors for SCI. Cranial traction was performed in 59 cases with success in 52 cases (88%). There were 3 failures after anterior fusion, which required revision surgery with a 360° fusion, all occurring at the C7-T1 level.

**Conclusions:** Cranial traction of the cervical spine is an effective and fast way to achieve closed reduction of cervical facet dislocations. After successful reduction, ACDF, as a single procedure, offers an excellent surgical option. All cases of failure occurred at the C7-T1 level, suggesting that a 360° fusion may be needed at this level.

**Level of Evidence:** 3.

Cervical Spine

Keywords: facet dislocation, cervical dislocation, cranial traction, ACDF, spinal trauma

## INTRODUCTION

Traumatic cervical spine fracture dislocation is one of the most devastating injuries involving the axial skeleton and is frequently associated with direct spinal cord or nerve root injury.<sup>1</sup> Approximately two-thirds of cervical spine injuries affect the subaxial cervical spine with fractures occurring most often at C6 and C7 and dislocations at C5-C6 and C6-C7.<sup>2,3</sup>

Dislocation of cervical facets resulting from traumatic injury often leads to neurologic impairment due to narrowing of the spinal canal.<sup>4</sup> While the primary mechanical injury damages ligaments, blood vessels, and axonal connections, secondary injury due to continued compression with ischemia and the production of free radicals leading to apoptosis plays a significant role in the long-term recovery of the patient.<sup>5,6</sup> Early

reduction of cervical spine injuries is shown to improve the likelihood of neurologic recovery at or below the level of injury by reducing the effect of secondary injury.<sup>4,6,7</sup>

Cranial traction of the cervical spine seems to be an effective and fast way to achieve closed reduction of many cervical facet dislocations, especially in low impact injuries.<sup>6,8</sup> This less invasive technique allows for the decompression of the spinal cord compression due to the dislocation and realignment of the spine to an anatomic position.<sup>9,10</sup> However, some controversy still exists in the decision to perform a closed reduction compared with open surgical reduction.<sup>10</sup> Lee et al<sup>10</sup> postulated that the 2 factors influencing this decision are the safety of the patient and feasibility of performing a closed reduction. It requires close neurologic monitoring, imaging to monitor progress, and patience,

because closed reductions are not always feasible for various reasons.<sup>9,10</sup> While it is supported that closed reduction in awake patients suffering from acute spinal injuries is safe, the current literature is still not clear if this approach is effective in different types of fractures and neurologic status.<sup>4,11</sup>

The operative management of these injuries is also controversial. There are reports describing success with anterior,<sup>12–14</sup> posterior,<sup>14–18</sup> or combined approaches.<sup>19–21</sup> In the setting of cervical facet dislocation with a tandem disc herniation, increased surgeon agreement can be observed with regard to the utilization of the anterior approach. In one study by the Spine Trauma Study Group, 91% of survey spinal surgeons favored an anterior approach or anterior-posterior approach for cases with an associated disc herniation.<sup>22</sup>

The advantages of the anterior approach for cervical facet dislocations are numerous. One of the main advantages is to limit the fusion to a single level; multiple-level fusions are performed during a posterior approach. Also, this approach allows for the placement of a large structural graft with a greater surface area under compression, allows for the surgeon to remove an associated cervical disc herniation, and incorporates biomechanically the center of rotational instability in the sagittal plane within the graft. Additionally, the inherent risks of alignment change during the prone positioning and fixation, and the increased infection rates of the posterior approach are similarly avoided.<sup>23,24</sup>

Proponents of an initial posterior approach argue that a midline posterior exposure provides bilateral access to the facets for reduction and stabilization,<sup>22,25</sup> including the ability to remove a portion of the superior articular pillar of the inferior vertebra to assist in relocating the spine. In up to 25%–40% of cases, anterior intraoperative reduction forces provided chiefly by intervertebral distraction are insufficient to reduce unilateral or bilateral facet dislocations.<sup>13,20</sup> Alternatively, posterior cervical approaches allow for the direct visualization of facet dislocations and decompression of the central canal and neural foramen.<sup>24,26</sup>

The primary aim of the present study was to evaluate the efficacy of awake closed reduction in the initial management of cervical facet dislocations (specifically the AO-type C F4 injuries)<sup>27</sup> and to analyze the results of anterior-only surgical management for subaxial cervical facet dislocations. The secondary aim was to analyze the risk factors for treatment failure and reasons for reoperation.

## METHODS

After institutional review board approval, a retrospective review of a prospective, locally maintained database was conducted using medical records from January 2008 to the end of 2018, including all patients aged 18 or older with single-level subaxial cervical facet dislocations (AO spine classification C F4).<sup>27</sup>

Plain radiographs and cervical computed tomography (CT) including 3-dimensional reconstruction were performed in all patients. The imaging of each patient was individually reviewed and the injury characteristics were evaluated (unilateral or bilateral facet dislocations, level of injury, and presence of associated facet fracture or end-plate fracture).

Preoperative magnetic resonance imaging (MRI) was not routinely performed due to the risk of delayed reduction and surgery with consequent possible aggravation of the neurological function and due to the lack of clinical evidence of the necessity for this exam in all cases (as is better described in the Discussion).

Our tertiary hospital has a 24-hour on-call spine surgeon to respond to urgent spine fractures and all attempts are made to treat the patient as quickly as possible when not limited by other concomitant injuries, independently of the presence or absence of spinal cord injury (SCI). In this study, 97% of patients were operated on within the first 12 hours after injury. The other 3% (2 cases) had other severe concomitant injuries and were too unstable to proceed with the early treatment. They were treated 69 and 75 hours later, respectively.

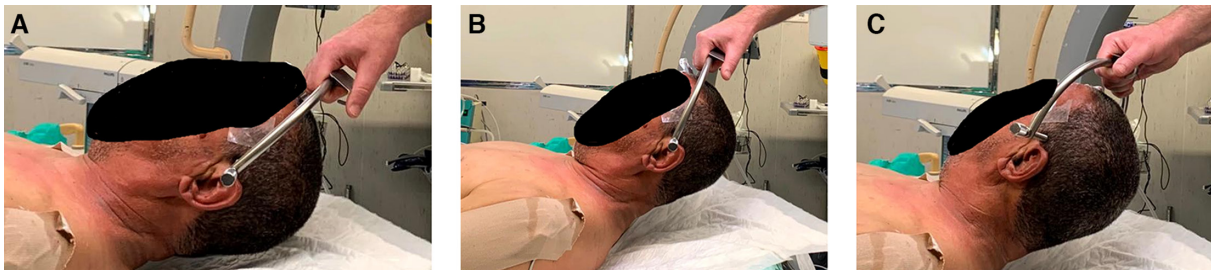Demographic variables, mechanism of trauma, initial Glasgow Coma Scale, presence of SCI (determined by the American Spinal Injury Association Impairment Scale [ASIA]), radiculopathy, surgical data, and follow-up records including all the imaging studies were reviewed.

Patients were assessed for the occurrence of a second posterior operation after a planned stand-alone anterior-only fusion. However, patients who required a supplementary posterior fusion were analyzed for the reasons of failure and rationale for posterior supplementation. Facet fractures, unilateral or bilateral facet dislocations, end plate fractures, and level of the injury were studied as possible risk factors for anterior-only fusion failure.

All patients with pathologic fractures, previous cervical fixation, and those with less than 2 years' follow-up were excluded.

### Reduction and Surgical Technique

The technique used for closed reduction was cranial traction with Gardner-Wells tongs. This was only



**Figure 1.** Closed reduction based solely on cranial manual traction without weights. (A) Neutral position; (B) flexion position; (C) neck flexion and rotation.

performed in awake patients in order to closely monitor them clinically. After the imaging study was finished, the patient with cervical facet dislocation was transferred to the operating room where appropriate analgesic medication was given by the anesthesiologist. With the patient awake, local anesthetic was administered to the cranial pin site and the pins were placed. The pin location was 1 cm above the pinna and 1 cm posterior to the line of the external auditory meatus and below the equator of the skull. This more posterior pin location allows for a slight cervical flexion during traction, which aids in the dislodgment of the perched facets.

In the first 21 cases, reported in this study, the initial traction weight was 2 kg and was increased progressively to a maximum of 20 kg or until appropriate reduction. Whenever reduction was not possible with this approach, a posterior reduction was performed (as reported in the results section).

However, and because traction has been reported to be safe up to 65 kg,<sup>7,11</sup> the technique used in the later cases was based solely on manual traction without weights (Figure 1). Immediately after pin placement, manual longitudinal traction was applied to the Gardner-Wells tongs. If this was ineffective, rotational maneuvers were added by performing gentle manual torsion with neck flexion and rotation toward the contralateral side of the dislocation, followed by rotation toward the side of the dislocation. The patient was kept awake throughout the whole process and his neurologic status was continuously assessed by the surgical team. Any worsening of neurological status would prompt immediate reversal of the reduction maneuvers and the patient would undergo MRI.

To avoid overdistraction C-arm fluoroscopy was used throughout the reduction process. After appropriate reduction, the traction weight was reduced to maintain the alignment but avoiding overdistraction (generally around 3–4 kg).

In cases where good realignment by closed reduction was achieved, an anterior approach was used and anterior discectomy or corpectomy and fusion (ACDF

or ACCF) with iliac crest autograft and plating was performed. The avoidance of oversizing the intervertebral graft was one important consideration to avoid inadvertently overdistraction of a relatively unstable spine (Figure 2).

If the reduction was not successful after closed maneuvers, an open posterior reduction was performed followed by an ACDF.

Postoperatively, all patients were prescribed a rigid cervical collar for 8 weeks.

### Statistical Analysis

The IBM Statistical Package for Social Sciences, version 23, was used for statistical analysis. Descriptive statistics were calculated and Kolmogorov-Smirnov test was used for assessing normal distribution. Depending on the variables analyzed,  $\chi^2$ , Fisher exact test, *t* test, and Mann-Whitney *U* test were used.

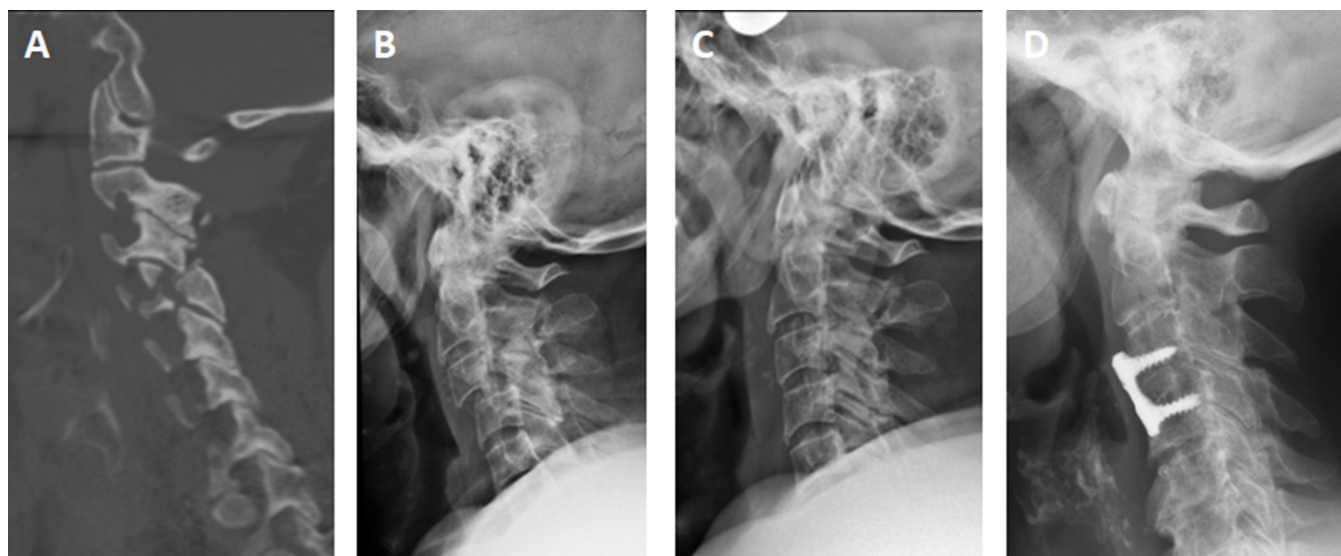
Bivariate and multivariate analyses were performed to access factors responsible for success of closed reduction, and also causes of ACDF failure and qualitative and quantitative variables relating to the patient.

All *P* values < 0.05 were considered statistically significant. Variables included in the logistic regression model were based on clinical indication or *P* value < 0.05 on univariate analysis. Odds ratios (ORs) and 95% confidence intervals (CIs) were calculated when appropriate.

## RESULTS

A total of 70 patients, 51 men and 19 women, with mean age of  $56 \pm 18$  years (18–90) were identified.

Motor vehicle accidents were the most common trauma mechanism followed by fall from height. Young adults were overrepresented among motor vehicle accidents, whereas falls contributed to a majority of facet joint dislocations sustained by older adults. The mechanism of trauma didn't impact the success of closed



**Figure 2.** Unilateral C3-C4 facet dislocation managed with closed reduction by cranial traction, followed by anterior cervical discectomy and fusion. (A) Sagittal sequence of the cervical CT showing left facet joint dislocation and fracture; (B) radiograph showing 50% anterior subluxation of C3 on C4; (C) radiograph showing the closed reduction with cranial traction; (D) radiograph taken 2 y after the surgery demonstrating a good cervical alignment and a complete incorporation of the allograft with the C3 and C4 vertebral bodies.

reduction ( $P = 0.58$ ) or was it a reason for ACDF failure ( $P = 0.67$ ).

The C6-C7 level was the most frequently affected (35/70 cases). Forty-six patients had unilateral dislocations and 24 had bilateral dislocations, with 48 of those cases (69%) having associated facet fractures. There were 4 cases of vertebral comminution and 9 cases of vertebral end plate fractures.

SCI was present in 36% of the cases (25/70); with 13% cases (9/70) having a complete SCI (ASIA A) and radiculopathy was present in 16% of the cases (ASIA E) (Table).

Bilateral dislocations were associated with the presence of SCI ( $P = 0.004$ ). Patients with bilateral dislocation were 4.7 times more likely to have an SCI (OR: 4.7; CI 95% = 1.6–13.8).

In this study, 3 patients had rigid/ankylosed spines (due to ankylosing spondylitis) and all of them had SCI. A subanalysis of these patients found that they were 2.96 times more likely to have an SCI (OR: 2.96; CI 95% = 2.11–4.15).

Cranial traction was attempted in 59 cases (84%) with success in 52 cases (88%). No worsening of the patient neurological status occurred during the reduction maneuver and, therefore, no postreduction MRI was performed. In patients achieving closed reduction, an anterior approach was performed. These 7 cases, where reduction was not successful, a posterior approach with effective open reduction was performed followed by ACDF. These 7 unsuccessful cases of closed reduction were all made with the older technique used at our

institution, previously described. Of those 7 cases, 6 were at C6-C7 and 1 at C7-D1. There were no cases of unsuccessful closed reduction using the manual traction and reduction maneuvers used more recently.

Cranial traction was not performed in 11 cases: in 3 cases it was the option of the surgeon not to perform cranial traction—these were cases of unilateral facet dislocation associated with facet fracture, which corrected with neck hyperextension so the decision was to

**Table.** Patients' characteristics ( $N = 70$ ).

Parameter	Finding
Age, y, mean $\pm$ SD (range)	56 $\pm$ 18 (18–90)
Gender, male, $n$ (%)	51 (73%)
Bilateral facet dislocation, $n$	24
Unilateral facet dislocation, $n$	46
Facet fractures, $n$ (%)	48 (69%)
Vertebral body fractures, $n$ (%)	13 (19%)
Rigid spines, $n$	3
Closed reduction attempted, $n$	59 (70%)
Closed reduction success % ( $n/N$ )	88% (52/59)
Follow-up, y, mean (range)	6.97 (1.5–12.5)
Failures needing revision, $n$ (%)	3 (4%)
Level	
C3-C4	3
C4-C5	4
C5-C6	22
C6-C7	35
C7-T1	6
ASIA	
A	9
B	2
C	5
D	9
E	45
Radiculopathy (in ASIA type E), $n$ (%)	11 (45)

Abbreviation: ASIA, American Spinal Injury Association Impairment Scale.

perform immediately ACDF without the need of cranial traction; 8 patients had a severe head injury or were unconscious, which made cranial traction impossible. The preferred approach in all of those 8 cases was anterior: in 6 cases the reduction was possible with open reduction maneuvers (convergent caspar pin placement and distraction) and then an ACDF/ACCF was performed; however, in 2 cases the anterior open reduction maneuvers were ineffective and, therefore, a posterior approach was used to reduce the perched facets, after which the ACDF was performed.

The rate of successful closed reduction did not differ between patients with complete, incomplete, and no neurological injury ( $P = 0.56$ ) and there were no cases of neurological worsening with closed reduction. The success of closed reduction was neither affected by the presence of unilateral or bilateral facet dislocations ( $P = 0.14$ ) nor by the presence of associated fractures ( $P = 0.27$ ).

Of the 52 cases with a successful closed reduction, 48 cases were submitted to an ACDF alone and 4 cases were submitted to ACCF with iliac crest autograft. The later was performed due to associated vertebral body comminution.

From the total of 70 cases, 3 cases (4%) failed after anterior fusion, which required revision surgery with a 360° fusion. All of these failures occurred after an isolated anterior fusion in the C7-T1 transition, with recurrent dislocation, neurological worsening, and screw pullout (Figure 3). The 3 cases of failure corresponded to 50% of all C7-T1 dislocations. And so, injury at this level was found to be a significant risk factor ( $P < 0.001$ ).

Facet fractures and bilateral dislocations were not shown to be a risk factor for treatment failure. Of the

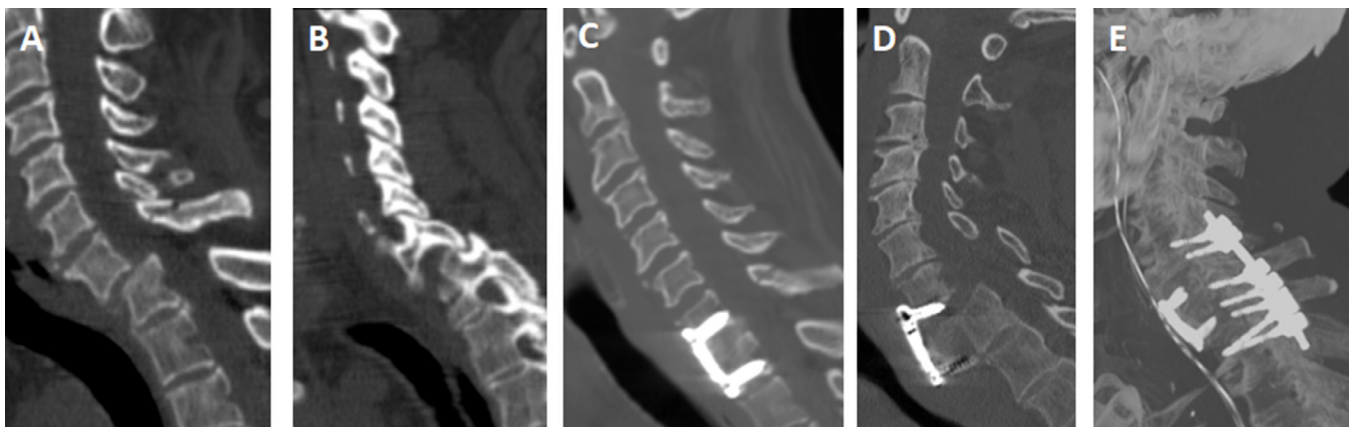
48 cases of facet fractures, failure only occurred in 3 cases and it was at the C7-T1 transition. Despite all of the cases of failure having facet fractures there was not a statistical difference from the ones that didn't fail ( $P = 0.163$ ). Bilateral dislocations were also not found to be at our study a risk factor for ACDF failure ( $P = 0.432$ ). End plate fracture was present at 1 of the 3 cases of ACDF failure, but was also not found to be a significant risk factor at our study ( $P = 0.071$ ).

## DISCUSSION

Traumatic cervical spine fracture dislocation is one of the most devastating injuries involving the axial skeleton. Several approaches to reduction and stabilization have been proposed with all demonstrating advantages and disadvantages. The objective of this paper was to evaluate the efficacy of wide-awake closed reduction in the initial management of cervical facet dislocations and to analyze the results of anterior-only surgical management for subaxial cervical facet dislocations. The secondary aim was to analyze the risk factors for treatment failure and reasons for reoperation.

Despite the obvious biomechanical advantage of combined anterior-posterior approach, some authors advocate for an anterior approach alone as an effective treatment option for single-level cervical fracture dislocations.<sup>12,28</sup> Advocates of this approach argue a shorter operative time, less blood loss, and the advantage of performing a discectomy with a direct spinal cord decompression view. Furthermore, this approach obviates the need to place patients in the prone position with unstable spinal injuries.<sup>12,13,25</sup>

In this study, cranial traction of the cervical spine was an effective, safe, and fast way to achieve closed



**Figure 3.** Bilateral C7-D1 facet dislocation treatment failure and revision surgery. (A) Central sagittal sequence of the cervical CT showing 50% anterior subluxation of C7 on T1; (B) Lateral sagittal sequence of the cervical CT showing facet joint dislocation; (C) CT showing anterior cervical discectomy and fusion (ACDF) on the immediate postop; (D) CT showing failure of the treatment with screw pullout and a new subluxation of the vertebral bodies; (E) CT 3-dimensional reconstruction of the 360° fusion revision surgery with a new C7-T1 ACDF and C6-C7-T1-T2 posterior fixation.

reduction of cervical facet dislocations, with an 88% success rate, which was higher than previously reported (41%–55%).<sup>11,29</sup> Additionally, while others have reported lower success rates of closed reduction in cases of SCI and unilateral jumped facets,<sup>11</sup> in this study, this was not found to influence the reduction success. Furthermore, a higher percentage of patients eligible for cranial traction (84%) was found in comparison with other studies<sup>29</sup> (63%), which preconize a prerelief MRI in every case.

As the MRI has become widely available, many authors have debated whether MRI is necessary to identify potential anterior impingements to the spinal cord (such as a herniated disc) prior to the reduction maneuver. Moreover, although prerelief MRI can demonstrate traumatic disc herniation and cord compression, the clinical significance of these findings is uncertain with only a few reports from the 90s suggesting neurological deterioration resulting from disc herniation following a satisfactory closed craniocervical reduction.<sup>30,31</sup> Several subsequent reports, including those by Vaccaro and colleagues<sup>32</sup> have indicated that closed reduction in an awake and alert patient is safe without obtaining a prerelief MRI. Furthermore, some recent studies have indicated that even closed reduction in sedated patients may be safe in most cases.<sup>33</sup> An interesting study from 2006 illustrated that a herniated disc may reconstitute itself into the disc space with distraction and reduction, as illustrated by an MRI-aided reduction technique.<sup>34</sup> Moreover, prerelief MRI requires movement of a patient with a potentially unstable cervical spinal fracture/dislocation injury to the MRI room. In addition, the use of prerelief MRI may delay the reduction of the spinal deformity and therefore is bound to delay decompression and realignment of the spinal cord. For these reasons, preoperative MRI was not routinely performed in the study.

Postreduction MRI and prior to surgery were also not performed in the patients in the study. The rationale for this was due to the fact that reduction was performed with the patient awake and none of the cases had worsening of the preoperative neurological status, therefore it was safe to proceed to surgery without an MRI. Additionally, since all these patients were submitted to an anterior discectomy and fusion, all remaining discs were removed intraoperatively.

There were 3 cases of instrumentation failure in the present study, all occurring at the C7-T1 level (which corresponded to 50% of all C7-T1 dislocations). There are several possible reasons for this higher failure rate at this level. First, the cervicothoracic junction is where the

mobile lordotic cervical spine joins the rigid kyphotic thoracic spine, making this a more complex and potentially unstable anatomic region with unique biomechanical properties.<sup>35</sup> Second, and since the reduction is ascertained by intraoperative fluoroscopy, it is possible that the anatomical landmarks and visibility of this region are hindered by the shoulders, and therefore the reduction may not have been the most appropriate. For these reasons, at this level, a 360° fusion may be necessary.

End plate fractures and facet fractures have been reported as possible risk factors for ACDF failure in some studies, however, with some inconsistent results.<sup>12,36</sup> Johnson et al<sup>36</sup> followed a cohort of 87 patients, with only radiographs, after ACDF for flexion distraction injuries and found that 65% of their failures were associated with facet fractures and end plate fractures. However, Anissipour et al<sup>12</sup> in a cohort with 36 patients corroborated that end plate fracture was a risk factor for treatment failure but did not find facet fractures to be a risk factor for treatment failure. In the present study, while all of cases of failure had facet fractures, their presence was not found to be a significant predictor of treatment failure ( $P = 0.163$ ). In fact, of the 48 cases of facet fractures only 3 cases had a treatment failure and it was at C7-T1 transition. End plate fractures were also not found to be significant predictor of treatment failure in our study ( $P = 0.071$ ), however, 1 of the 3 cases of treatment failure had an end plate fracture.

Bilateral facet dislocations with frank ligamentous disruption represent one area of heightened concern for cervical instability. However, despite this concern, bilateral facet dislocations were not associated with a significant risk of failure. This is in agreement with the findings by Razack et al<sup>37</sup> and Theodotou et al<sup>29</sup> where successful realignment, stabilization, and a solid fusion were possible using an anterior-only approach in cases with unilateral and bilateral facet fracture dislocations.

In agreement with other studies,<sup>11,38</sup> in the present study, bilateral dislocations were associated with the presence of SCI ( $P = 0.004$ ), and patients with bilateral dislocation were 4.7 times more likely to have a SCI (OR: 4.7; CI 95% = 1.6–13.8). Moreover, patients with rigid spines were 2.96 times more likely to have an SCI (OR: 2.96; CI 95% = 2.11–4.15).

To our knowledge, the present study is one of the largest studies to date analyzing closed reduction and anterior cervical reduction and fusion for the management of these fractures.

This study has some limitations. First, data collection was performed retrospectively, which may have

introduced bias. However, data collection was performed by independent researchers who were not involved in patient management and should not have influenced the data collection. A potential for selection bias could influence surgeon preference, particularly in cases of highly unstable injuries or comminuted facet fractures, which may have led surgeons to opt for combined anterior-posterior fixation. Second, a larger cohort of patients would have given more information on the reasons for failure and would potentially have allowed performing a more statistically significant multivariate analysis, instead of a univariate analysis, which was ultimately not possible in this study.

## CONCLUSION

Cranial traction of the cervical spine is an effective and fast way to achieve closed reduction of cervical facet dislocations, even in the absence of a prerelaxation MRI. After successful reduction, anterior discectomy and fusion, as a single procedure, offers an excellent surgical option in the management of cervical facet fracture dislocations with a low reoperation rate (4%). All cases of failure in this study occurred at the C7-T1 level, suggesting that a 360° fusion may be needed at that level.

## REFERENCES

1. Fredø HL, Rizvi SAM, Lied B, Rønning P, Helseth E. The epidemiology of traumatic cervical spine fractures: a prospective population study from Norway. *Scand J Trauma Resusc Emerg Med.* 2012;20:85:17–21. doi:10.1186/1757-7241-20-85
2. Goldberg W, Mueller C, Panacek E, et al. Distribution and patterns of blunt traumatic cervical spine injury. *Ann Emerg Med.* 2001;38(1):17–21. doi:10.1067/mem.2001.116150
3. Greenbaum J, Walters N, Levy PD. An evidenced-based approach to radiographic assessment of cervical spine injuries in the emergency department. *J Emerg Med.* 2009;36(1):64–71. doi:10.1016/j.jemermed.2008.01.014
4. Gelb DE, Hadley MN, Aarabi B, et al. Initial closed reduction of cervical spinal fracture-dislocation injuries. *Neurosurgery.* 2013;72 Suppl 2:73–83. doi:10.1227/NEU.0b013e318276ee02
5. Rowland JW, Hawryluk GWJ, Kwon B, Fehlings MG. Current status of acute spinal cord injury pathophysiology and emerging therapies: promise on the horizon. *Neurosurg Focus.* 2008;25(5):1–3. doi:10.3171/FOC.2008.25.11.E2
6. Newton D, England M, Doll H, Gardner BP. The case for early treatment of dislocations of the cervical spine with cord involvement sustained playing rugby. *J Bone Joint Surg Br.* 2011;93(12):1646–1652. doi:10.1302/0301-620X.93B12.27048
7. Cotler JM, Herbison GJ, Nasuti JF, Ditunno JF, An H, Wolff BE. Closed reduction of traumatic cervical spine dislocation using traction weights up to 140 pounds. *Spine (Phila Pa 1976).* 1993;18(3):386–390. doi:10.1097/00007632-199303000-00015
8. Aarabi B, Mirvis S, Shanmuganathan K, et al. Comparative effectiveness of surgical versus nonoperative management of unilateral, nondisplaced, subaxial cervical spine facet fractures without evidence of spinal cord injury: clinical article. *J Neurosurg Spine.* 2014;20(3):270–277. doi:10.3171/2013.11.SPINE13733
9. Khezri N, Ailon T, Kwon BK. Treatment of facet injuries in the cervical spine. *Neurosurg Clin N Am.* 2017;28(1):125–137. doi:10.1016/j.nec.2016.07.005
10. Lee JY, Nassr A, Eck JC, Vaccaro AR. Controversies in the treatment of cervical spine dislocations. *Spine J.* 2009;9(5):418–423. doi:10.1016/j.spinee.2009.01.005
11. Branche MJ, Ozturk AK, Ramayya AG, McShane BJ, Schuster JM. Neurologic status on presentation as predictive measurement in success of closed reduction in traumatic cervical facet fractures. *World Neurosurg.* 2018;114:e344–e349. doi:10.1016/j.wneu.2018.03.001
12. Anissipour AK, Agel J, Baron M, Magnusson E, Bellabarba C, Bransford RJ. Traumatic cervical unilateral and bilateral facet dislocations treated with anterior cervical discectomy and fusion has a low failure rate. *Global Spine J.* 2017;7(2):110–115. doi:10.1177/2192568217694002
13. Reindl R, Ouellet J, Harvey EJ, Berry G, Arlet V. Anterior reduction for cervical spine dislocation. *Spine (Phila Pa 1976).* 2006;31(6):648–652. doi:10.1097/01.brs.0000202811.03476.a0
14. Argenson C, de Peretti F, Ghabris A, Eude P, Hovorka I. Traumatic rotatory displacement of the lower cervical spine. *Bull Hosp Jt Dis.* 2000;59(1):52–60.
15. Stauffer ES, Kelly EG. Fracture-dislocations of the cervical spine. Instability and recurrent deformity following treatment by anterior interbody fusion. *J Bone Joint Surg Am.* 1977;59(1):45–48. doi:10.2106/00004623-197759010-00006
16. Shapiro SA. Management of unilateral locked facet of the cervical spine. *Neurosurgery.* 1993;33(5):832–837. doi:10.1227/00006123-199311000-00007
17. Shapiro S, Snyder W, Kaufman K, Abel T. Outcome of 51 cases of unilateral locked cervical facets: interspinous braided cable for lateral mass plate fusion compared with interspinous wire and facet wiring with iliac crest. *J Neurosurg.* 1999;91(1 Suppl):19–24. doi:10.3171/spi.1999.91.1.0019
18. Bohlman HH. Acute fractures and dislocations of the cervical spine. An analysis of three hundred hospitalized patients and review of the literature. *J Bone Joint Surg Am.* 1979;61(8):1119–1142. doi:10.2106/00004623-197961080-00001
19. Rizzolo SJ, Piazza MR, Cotler JM, Balderston RA, Schaefer D, Flanders A. Intervertebral disc injury complicating cervical spine trauma. *Spine.* 1991;16(Supplement):S187–S189. doi:10.1097/00007632-199106001-00002
20. Feng G, Hong Y, Li L, et al. Anterior decompression and nonstructural bone grafting and posterior fixation for cervical facet dislocation with traumatic disc herniation. *Spine (Phila Pa 1976).* 2012;37(25):2082–2088. doi:10.1097/BRS.0b013e31825ee846
21. Aebi M, Mohler J, Zäch GA, Morscher E. Indication, surgical technique, and results of 100 surgically-treated fractures and fracture-dislocations of the cervical spine. *Clin Orthop Relat Res.* 1986;203(amp;NA). doi:10.1097/00003086-198602000-00031
22. Nassr A, Lee JY, Dvorak MF, et al. Variations in surgical treatment of cervical facet dislocations. *Spine (Phila Pa 1976).* 2008;33(7):E188–93. doi:10.1097/BRS.0b013e3181696118
23. Burke DC, Berryman D. The place of closed manipulation in the management of flexion-rotation dislocations of the

cervical spine. *J Bone Joint Surg Br.* 1971;53-B(2):165–182. doi:10.1302/0301-620X.53B2.165

24. Levi AD, Dickman CA, Sonntag VK. Management of postoperative infections after spinal instrumentation. *J Neurosurg.* 1997;86(6):975–980. doi:10.3171/jns.1997.86.6.0975

25. Brodke DS, Anderson PA, Newell DW, Grady MS, Chapman JR. Comparison of anterior and posterior approaches in cervical spinal cord injuries. *J Spinal Disord Tech.* 2003;16(3):229–235. doi:10.1097/00024720-200306000-00001

26. Park JH, Roh SW, Rhim SC. A single-stage posterior approach with open reduction and pedicle screw fixation in subaxial cervical facet dislocations. *J Neurosurg Spine.* 2015;23(1):35–41. doi:10.3171/2014.11.SPINE14805

27. Vaccaro AR, Koerner JD, Radcliff KE, et al. AOSpine subaxial cervical spine injury classification system. *Eur Spine J.* 2016;25(7):2173–2184. doi:10.1007/s00586-015-3831-3

28. Do Koh Y, Lim TH, Won You J, Eck J, An HS. A biomechanical comparison of modern anterior and posterior plate fixation of the cervical spine. *Spine (Phila Pa 1976).* 2001;26(1):15–21. doi:10.1097/00007632-200101010-00005

29. Theodotou CB, Ghobrial GM, Middleton AL, Wang MY, Levi AD. Anterior reduction and fusion of cervical facet dislocations. *Neurosurgery.* 2019;84(2):388–395. doi:10.1093/neuros/nyy032

30. Farmer J, Vaccaro A, Albert TJ, Malone S, Balderston RA, Cotler JM. Neurologic deterioration after cervical spinal cord injury. *J Spinal Disord.* 1998;11(3):192–196.

31. Maiman DJ, Barolat G, Larson SJ. Management of bilateral locked facets of the cervical spine. *Neurosurgery.* 1986;18(5):542–547. doi:10.1227/00006123-198605000-00005

32. Vaccaro AR, Falatyn SP, Flanders AE, Balderston RA, Northrup BE, Cotler JM. Magnetic resonance evaluation of the intervertebral disc, spinal ligaments, and spinal cord before and after closed traction reduction of cervical spine dislocations. *Spine (Phila Pa 1976).* 1999;24(12):1210–1217. doi:10.1097/00007632-199906150-00007

33. Kim SG, Park SJ, Wang HS, Ju CI, Lee SM, Kim SW. Anterior approach following intraoperative reduction for cervical facet fracture and dislocation. *J Korean Neurosurg Soc.* 2020;63(2):202–209. doi:10.3340/jkns.2019.0139

34. Darsaut TE, Ashforth R, Bhargava R, et al. A pilot study of magnetic resonance imaging-guided closed reduction of cervical spine fractures. *Spine (Phila Pa 1976).* 2006;31(18):2085–2090. doi:10.1097/01.brs.0000232166.63025.68

35. Sapkas G, Papadakis S, Katonis P, Roidis N, Kontakis G. Operative treatment of unstable injuries of the cervicothoracic junction. *Eur Spine J.* 1999;8(4):279–283. doi:10.1007/s005860050174

36. Elgafy H, Fisher C, Zhao Y, et al. The radiographic failure of single segment posterior cervical instrumentation in traumatic cervical flexion distraction injuries. *Top Spinal Cord Inj Rehabil.* 2006;12(2):20–29. doi:10.1310/80JT-6AHM-ORL8-NF59

37. Razack N, Green BA, Levi ADO. The management of traumatic cervical bilateral facet fracture-dislocations with uncortical anterior plates. *J Spinal Disord.* 2000;13(5):374–381. doi:10.1097/00002517-200010000-00002

38. Quarrington RD, Jones CF, Tchervenjakov P, et al. Traumatic subaxial cervical facet subluxation and dislocation: epidemiology, radiographic analyses, and risk factors for spinal cord injury. *Spine J.* 2018;18(3):387–398. doi:10.1016/j.spinee.2017.07.175

**Funding:** The author(s) received no financial support for the research, authorship, and/or publication of this article.

**Declaration of Conflicting Interests:** The authors report no conflicts of interest in this work.

**Corresponding Author:** Ricardo Rodrigues-Pinto, Head of Spinal Unit/ Unidade Vertebro-Medular (UVM), Department of Orthopaedics, Centro Hospitalar Universitário do Porto, Porto 4099-001, Portugal; ric\_pinto@hotmail.com

Published 03 March 2022

This manuscript is generously published free of charge by ISASS, the International Society for the Advancement of Spine Surgery. Copyright © 2022 ISASS. To see more or order reprints or permissions, see <http://ijssurgery.com>.