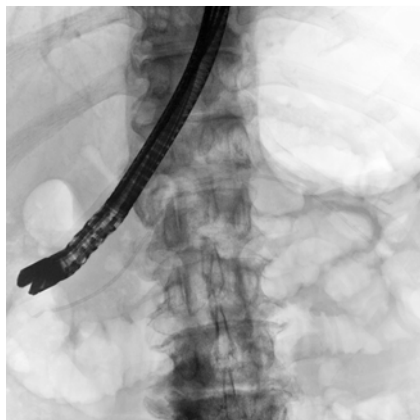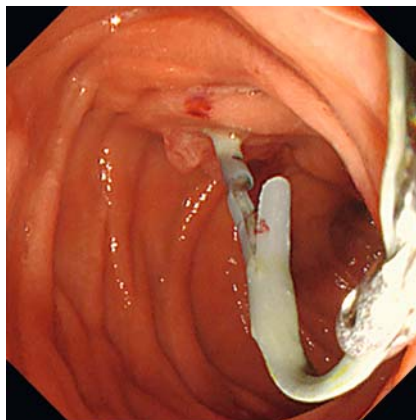


Application of a “retracting flaps” technique using a device delivery system for endoscopic removal of a pancreatic stent with 10 proximal flaps stuck in the pancreatic duct

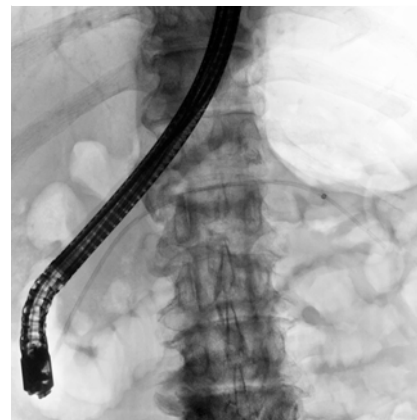OPEN
ACCESS




► **Fig. 1** Fluoroscopic image showing a 5-Fr stent with 10 proximal flaps stuck in the pancreatic duct.



► **Fig. 2** Endoscopic image of the pancreatic stent, the distal end of which was grasped using biopsy forceps.



► **Fig. 3** Fluoroscopic image showing the outer sheath of the device delivery system being advanced over the stent.



► **Fig. 4** Photographs showing: **a** a stent flap retracted within the outer sheath (arrow); **b** the retrieved stent whose flaps were folded in the opposite direction.

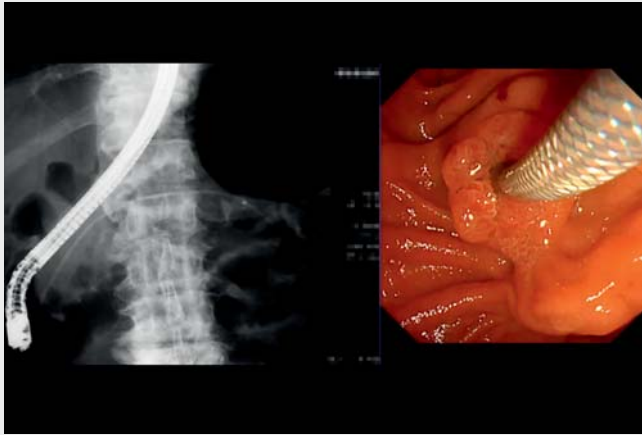
Endoscopic pancreatic duct stenting is used for a variety of conditions. Although numerous reports have described pancreatic stent migration [1], few have detailed the proximal flaps getting stuck in the pancreatic duct [2]. Here, we report a novel technique for endoscopic removal of a pancreatic stent that can be used when its flaps become stuck in the pancreatic duct.

A 73-year-old man who had undergone endoscopic pancreatic drainage 9 months previously for a malignant pancreatic duct stricture using a 5-Fr stent with 10 proximal flaps presented with obstructive pancreatitis. The initial attempt at endoscopic removal of the stent failed because the proximal flaps became stuck, and the distal portion of the stent was torn off. He was therefore referred for

endoscopic removal of the stent stuck in the pancreatic duct (► **Fig. 1**).

To treat this patient, we developed a novel removal technique, named the “retracting flaps” technique, that uses a device delivery system (EndoSheather; Piolax Medical Devices, Kanagawa, Japan). Biopsy forceps with a 1.8-mm diameter (Cospa; Century Medical, Tokyo, Japan) were inserted through the system’s outer sheath (6.2-Fr inner diameter). While grasping and pulling the distal end of the stent with the forceps (► **Fig. 2**), we advanced the outer sheath over the stent and retracted the flaps within the sheath (► **Fig. 3**). Finally, while still retracting the flaps, we were able to retrieve the stent from the pancreatic duct (► **Fig. 4**, ► **Video 1**). A 7-Fr stent was subsequently placed, and the patient was discharged without further complications.

Forcibly pulling a stuck pancreatic stent carries a high risk of triggering intraductal stent fragmentation, which makes retrieval of the fragmented stent technically more difficult [3]. The “retracting flaps” technique is easy to perform and enables safe stent removal.




Video 1 Application of the novel “retracting flaps” technique using a device delivery system for endoscopic removal of a pancreatic stent with 10 proximal flaps from the pancreatic duct.

Endoscopy_UCTN_Code_CPL_1AK_2AD

Competing interests

The authors declare that they have no conflict of interest.

The authors

Sho Kitagawa  **Yasutaka Nakai, Daiki Oku**
Department of Gastroenterology, Sapporo Kosei General Hospital, Sapporo, Japan

Corresponding author

Sho Kitagawa, MD
Department of Gastroenterology, Sapporo Kosei General Hospital, Kita 3 Higashi 8, Chuo-ku, Sapporo 060-0033, Japan
bossa0405@yahoo.co.jp

References

- [1] Matsumoto K, Katanuma A, Maguchi H. Endoscopic removal technique of migrated pancreatic plastic stents. *J Hepatobiliary Pancreat Sci* 2014; 21: E34–E40
- [2] Kitagawa S, Okamura K, Oku D. Endoscopic retrieval of an entrapped nasopancreatic drainage tube. *Dig Endosc* 2017; 29: 385–386
- [3] Jagielski M, Smoczyński M, Jabłońska A et al. Endoscopic treatment of intraductal pancreatic stent fragmentation. *Dig Endosc* 2017; 29: 798–805

Bibliography

Endoscopy 2023; 55: E474–E475
DOI 10.1055/a-2025-0342
ISSN 0013-726X
© 2023. The Author(s).

This is an open access article published by Thieme under the terms of the Creative Commons Attribution-NonDerivative-NonCommercial License, permitting copying and reproduction so long as the original work is given appropriate credit. Contents may not be used for commercial purposes, or adapted, remixed, transformed or built upon. (<https://creativecommons.org/licenses/by-nc-nd/4.0/>)
Georg Thieme Verlag KG, Rüdigerstraße 14, 70469 Stuttgart, Germany



ENDOSCOPY E-VIDEOS

<https://eref.thieme.de/e-videos>



Endoscopy E-Videos is an open access online section, reporting on interesting cases and new techniques in gastroenterological endoscopy. All papers include a high quality video and all contributions are freely accessible online. Processing charges apply, discounts and waivers acc. to HINARI are available.

This section has its own submission website at
<https://mc.manuscriptcentral.com/e-videos>