

PRIOR TO PUBLICATION, THIS GUIDELINE UNDERWENT REVIEW BY THE CUA GUIDELINES COMMITTEE, TOPIC EXPERTS, AND THE CUA EXECUTIVE BOARD

Canadian Urological Association guideline: Diagnosis, management, and followup of the incidentally discovered adrenal mass

Neal E. Rowe^{1*}, Ravi M. Kumar^{2*}, Nicola Schieda³, Ferhan Siddiqi⁴, Thomas McGregor⁵, Kristen McAlpine⁶, Philippe D. Violette⁷, Varun Bathini⁸, Michael Eng⁹, Jason Izard⁵

¹Division of Urology, University of Ottawa, Ottawa, ON, Canada; ²Division of Urology, University of Toronto, Toronto, ON, Canada; ³Department of Radiology, University of Ottawa, Ottawa, ON, Canada; ⁴Department of Endocrinology, Dalhousie University, Halifax, NS, Canada; ⁵Department of Urology, Queen's University, Kingston, ON, Canada; ⁶Urology, Credit Valley, Mississauga, ON, Canada; ⁷Division of Urology, McMaster University, Hamilton, ON, Canada; ⁸Division of Urology, University of Saskatchewan, Saskatoon, SK, Canada; ⁹Department of Urologic Sciences, University of British Columbia, Vancouver, BC, Canada

*Joint first author

REVIEWERS:

Kunal Jana, Division of Urology, University of Saskatchewan, Saskatoon, SK, Canada
Alexander Kutikov, Division of Urology and Urologic Oncology, Fox Chase Cancer Center, Philadelphia, PA, United States
Wesley Mayer, Department of Urology Baylor College of Medicine, Houston, TX, United States

Cite as: Rowe NE, Kumar RM, Schieda N, et al. Canadian Urological Association guideline: Diagnosis, management, and followup of the incidentally discovered adrenal mass. *Can Urol Assoc J* 2023;17(2):12-24. <http://dx.doi.org/10.5489/auaj.8248>

INTRODUCTION

Adrenal incidentalomas are adrenal masses greater than 1 cm in size that are detected on cross-sectional imaging performed for an unrelated indication.¹ These lesions are common, estimated to be present in 4% of patients on imaging series, and up to 10% of the elderly population.^{2,3} Most of these lesions are benign non-functioning adrenocortical adenomas, with a minority being hormonally active or malignant.

The evaluation and management of adrenal incidentalomas is a multidisciplinary process, relying on the expertise of family physicians, urologists, endocrinologists, and radiologists. In 2011, the Canadian Urological Association (CUA) released a guideline on the management of the incidentally discovered adrenal mass.⁴ Since then, there have been several clinical practice guidelines published by various endocrine, radiological, and surgical societies.⁵⁻⁸ A review by Maas et al compared these guidelines and found many points of discrepancy and controversy.⁹ Furthermore, in a letter to the editor from

April 2021, McInnes et al suggested an important revision to the current CUA guideline.¹⁰

The purpose of this guideline is to provide an updated approach to the diagnosis, management, and followup of adrenal incidentalomas, with a special focus on the areas of discrepancy/controversy existing among the published guidelines from other associations.

METHODS

This guideline was developed by a working group comprised of urologists, endocrinologists, and radiologists across Canada. The working group met virtually on multiple occasions to discuss the priorities for the guideline and to review the manuscript and recommendations. The recommendations and the evidence used to inform each recommendation were reviewed and agreed upon by the working group. When required, consensus was reached by discussion among group members. The target audience of this guideline is healthcare providers who manage patients with adrenal incidentalomas (e.g., family physicians, endocrinologists, internists, urologists, endocrine surgeons, etc.), as well as patients with adrenal incidentalomas.

The Grading of Recommendations Assessment, Development and Evaluation (GRADE) framework was used as a methodological basis for this guideline. Our evidence synthesis was completed using PubMed, Medline, and Cochrane Library databases.

The first step was defining clinical questions. A list of 12 clinical questions were compiled and are displayed in Table 1. Next, a systematic literature search was conducted to address each question. For questions where there was a recent high-quality guideline analysis and recommendation, focus was given towards any subsequent peer-reviewed publications and adapting the recommendation to a Canadian context. Special attention was paid to areas of controversy/discrepancy between the currently published guidelines.⁵⁻⁸ For each recommendation, the strength of recommendation was reported as weak or strong, and the quality of evidence

Table 1. Clinical questions regarding the workup, management, and surveillance of adrenal incidentalomas addressed in the guideline

1. What is the definition of an adrenal incidentaloma?
2. What is the differential diagnosis for an adrenal incidentaloma (malignant, benign, and functioning)?
3. What are key questions to ask on history and pertinent physical examination findings when evaluating a patient with an adrenal incidentaloma?
4. What are the best first-line and second-line imaging tests to characterize the incidentally discovered adrenal mass?
5. Which patients with adrenal incidentalomas require screening for hypersecretion of cortisol, aldosterone, catecholamines, and androgens? What are the best screening tests for each?
6. Is there a role for biopsy of an adrenal incidentaloma?
7. What are the indications for surgery for an incidentally detected adrenal mass?
8. Should patients with subclinical Cushing's be offered adrenalectomy?
9. Is there a specific size/growth rate threshold that can be used for offering treatment for a non-functioning mass with benign characteristics?
10. What is the best surgical approach for localized adrenocorticotrophic carcinomas?
11. What constitutes appropriate followup for a patient not undergoing surgery or postoperatively?
12. Are there any special considerations?

was evaluated as low, moderate, or high. A summary of all recommendations is displayed in Table 2.

DEFINITION OF ADRENAL INCIDENTALOMA

An adrenal incidentaloma is an adrenal mass detected on cross-sectional imaging performed for an unrelated indication. The imaging test could not have been ordered to evaluate symptoms of adrenal hormone excess or a suspected adrenal mass. Adrenal masses identified on imaging studies performed for tumor staging in patients with a known cancer are also not considered adrenal incidentalomas. Generally, these masses are found during the workup of signs/symptoms not felt to be related to the adrenal glands, such as abdominal or back pain. Adrenal incidentalomas must also be equal to or greater than 1 cm in size.¹

WORKUP OF AN INCIDENTALLY DETECTED ADRENAL MASS

The differential diagnosis for an adrenal incidentaloma is broad. These masses can be broken down into three categories: benign non-functioning, benign hyperfunctioning, and malignant lesions. A full breakdown of potential etiologies of adrenal masses and their estimated prevalence is presented in Table 3.¹⁻⁴ The most common lesion is a benign non-functioning adrenal adenoma. These are estimated to make up 75% of adrenal incidentalomas. Other potential benign adrenal masses include myelolipomas, cysts, lymphangiomas, and ganglioneuromas.

Hyperfunctioning adrenal lesions include cortisol-secreting adenomas (5.3% of all adrenal incidentalomas), aldosterone-secreting adenomas (1%), or catecholamine-secreting pheochromocytomas (5.1%).⁵ Finally, adrenal incidentalomas could represent malignant lesions, such as adrenocortical carcinoma (ACC) (4.7%) or metastases (2.5%).⁵ A systematic review found that approximately 20% of all adrenal incidentalomas were potential surgical lesions.^{3,6}

History and physical examination

When an adrenal incidentaloma is detected, a careful evaluation must be carried out to evaluate for any clinical signs or symptoms of a hyperfunctioning lesion or underlying malignancy. The general approach to the clinical history and physical exam for the patient with an incidentally detected adrenal mass is displayed in Table 4.

RECOMMENDATION 1

Workup for an adrenal incidentaloma should include a focused history and physical examination aimed at identifying signs/symptoms of adrenal hormone excess, adrenal malignancy, and/or extra-adrenal malignancy (*Clinical principle*).

RECOMMENDATION 2

There should be a low threshold for a multidisciplinary review by endocrinologists, surgeons, and radiologists when the imaging is not consistent with a benign lesion, there is evidence of hormone hypersecretion, the tumor has grown significantly during followup imaging, or adrenal surgery is being considered (*Clinical principle*).

Radiological evaluation

An algorithm for the use of imaging tests in the workup of adrenal incidentalomas is presented in Figure 1. Computed tomography (CT) and magnetic resonance imaging (MRI) are the primary imaging modalities performed to evaluate adrenal incidentalomas.

The first step in characterization of an adrenal mass is to determine if it is benign or malignant. The most validated initial imaging test to characterize adrenal masses is non-contrast CT. A mass that is homogeneous, well-circumscribed, and measures <10 Hounsfield Units (HU) in attenuation can be confidently diagnosed as benign, overwhelmingly representing lipid-rich adrenal cortical adenomas. In a retrospective review of 216 patients who underwent adrenalectomy, 143/143 (100%) patients who had benign features on CT had benign final pathology.¹¹ Similarly, in another retrospec-

Table 2. Summary of recommendations

	Recommendation	Strength of recommendation	Quality of evidence
1	Workup for an adrenal incidentaloma should include a focused history and physical examination aimed at identifying signs/symptoms of adrenal hormone excess, adrenal malignancy, and/or extra-adrenal malignancy.	Clinical principle	
2	There should be a low threshold for a multidisciplinary review by endocrinologists, surgeons, and radiologists when the imaging is not consistent with a benign lesion, there is evidence of hormone hypersecretion, the tumor has grown significantly during followup imaging, or adrenal surgery is being considered.	Clinical principle	
3	Patients found to have an indeterminate incidental adrenal mass should undergo a non-contrast CT as first-line imaging to distinguish benign lesions from those that require further radiological investigation.	Strong	Moderate
4	Patients who continue to have an indeterminate adrenal mass on non-contrast CT should undergo second-line imaging with either washout CT or chemical-shift MRI.	Weak	Moderate
5	Adrenal mass biopsy should not be performed routinely for the workup of an adrenal incidentaloma.	Strong	Moderate
6.1	All patients with adrenal incidentalomas should be screened for autonomous cortisol secretion.	Weak	Moderate
6.2	1 mg dexamethasone suppression testing is the preferred screening test for identifying autonomous cortisol secretion when clinically appropriate.	Strong	Moderate
7.1	Patients with adrenal incidentalomas and hypertension and/or hypokalemia should be screened for primary aldosteronism with an aldosterone-to-renin ratio.	Strong	Moderate
7.2	Adrenal vein sampling is recommended prior to offering adrenalectomy in patients with primary aldosteronism.	Strong	Moderate
8.1	We suggest against screening for pheochromocytoma in patients who have unequivocal adrenocortical adenomas confirmed on unenhanced CT (<10 HU) and no signs or symptoms of adrenergic excess.	Weak	Low
8.2	Patients with adrenal incidentalomas that display ≥ 10 HU on non-contrast CT or who have signs/symptoms of catecholamine excess should be screened for pheochromocytoma with plasma or 24-hour urinary metanephrines.	Strong	Moderate
9	In cases of suspected adrenocortical carcinoma and/or when clinical signs of virilization are present, serum testing of excess androgen testing should be performed.	Clinical principle	
10.1	Patients with unilateral cortisol-secreting adrenal masses and clinically apparent Cushing's syndrome should undergo unilateral adrenalectomy of the affected adrenal gland. Minimally invasive surgery should be performed when feasible for these procedures.	Clinical principle	
10.2	Younger patients with mild autonomous cortisol secretion who have progressive metabolic comorbidities attributable to cortisol excess can be considered for adrenalectomy after shared decision-making. Patients not managed surgically should undergo annual clinical screening for new or worsening associated comorbidities.	Weak	Low
11	Adrenalectomy should be performed for patients with unilateral aldosterone-secreting adrenal masses and pheochromocytomas. Minimally invasive surgery should be performed when feasible for these procedures.	Clinical principle	
12.1	Minimally invasive adrenalectomy can be offered to patients with suspected adrenocortical carcinomas that can be safely resected without rupturing the tumor capsule.	Weak	Low
12.2	Open adrenalectomy should be considered for patients with larger adrenocortical carcinomas or those presenting with locally advanced tumors, lymph node metastases, or tumor thrombus in the renal vein/inferior vena cava.	Strong	Low
13	Patients with benign non-functioning adenomas <4 cm, myelolipomas, and other small masses containing macroscopic fat detected on the initial workup for an adrenal incidentaloma do not require further followup imaging or functional testing.	Strong	Moderate
14.1	Patients with non-functioning adrenal lesions that are radiologically benign (<10 HU) but >4 cm should undergo repeat imaging in 6–12 months	Weak	Low
14.2	Adrenalectomy should be considered for patients with adrenal incidentalomas growing >5 mm/year after repeating a functional workup.	Weak	Low
14.3	No further imaging followup or functional testing is required for patients with adrenal lesions that grow <3 mm/year on followup imaging.	Weak	Low
15	Shared decision-making between patients and their clinicians should be used for the management of indeterminate non-functioning adrenal lesions. Management options include repeat imaging in 3–6 months vs. surgical resection.	Clinical principle	

CT: computed tomography.

tive review of 2219 adrenal incidentalomas that were either surgically removed or monitored for at least a year, the risk of finding an ACC was 0% if the HU were <10 on initial imaging (0.5% when HU=10–20 and 6.3% when HU >20).¹²

In masses that show large areas of macroscopic fat (isoattenuating to retroperitoneal fat and measuring <-10 to -15 HU) a diagnosis of benign myelolipoma can be made.¹³ Masses with small amounts of macroscopic fat have historically represented a diagnostic dilemma, since macroscopic fat has been found in adrenal cortical carcinoma.^{14,15} More recent data indicate that many adrenal masses with small amounts of macroscopic fat can be benign adrenal cortical adenomas with myelolipomatous degeneration.¹⁶ These can be diagnosed confidently when serial imaging shows a typical adrenal adenoma that later develops areas of macroscopic fat with or without calcification.¹⁶ Thus, the presence of small amounts of macroscopic fat in larger, heterogeneous masses should not be considered a diagnostically benign feature.

At a threshold of <10 HU, the sensitivity and specificity of non-contrast CT for benign adenomas is 71% and 98%, respectively.¹⁷ Dinnes et al tested this threshold in a systematic review with meta-analysis and found that lesions on non-contrast CT with HU <10 were only identified in those with benign disease.¹⁴ It should be noted that approximately 30% of benign adenomas have an attenuation value of >10 HU and are considered lipid-poor, overlapping in density with malignant lesions and pheochromocytomas. Thus, adrenal masses with HU >10 are considered indeterminate.¹⁷⁻¹⁹

RECOMMENDATION 3

Patients found to have an incidental adrenal mass should undergo a non-contrast CT as first-line imaging to distinguish benign lesions from those that require further radiological investigation (Strong recommendation, moderate-quality evidence).

Masses that do not fit the radiological criteria for lipid-rich adenoma or myelolipoma outlined above can be further evaluated with either a contrast-enhanced washout CT or chemical-shift MRI.

Adrenal washout CT (contrast-enhanced) has been considered the mainstay for indeterminate adrenal mass evaluation for many years. Adrenal adenomas characteristically take up contrast rapidly and have a rapid loss of contrast or “washout.” Conversely, malignant lesions typically display a slower washout of contrast. These parameters are exploited in contrast-enhanced washout CTs, which quantify the amount of “washout” by measuring lesion attenuation at specific time points

Table 3. Differential diagnosis of adrenal incidentalomas and estimated prevalence

Type	Range (%)
Benign non-functional	
Non-functioning adenoma	71–84
Ganglioneuroma	0–8
Myelolipoma	7–15
Cysts	4–22
Benign functioning	
Cortisol secreting adenoma	1–30
Aldosterone secreting adenoma	2–7
Pheochromocytoma	1.5–14
Malignant	
Adrenocortical carcinoma	1.2–12
Metastases	0–21
Pheochromocytoma	1.5–14

Data from references 1-4.

Table 4. Elements of a focused history and physical examination are tailored towards detecting possible etiologies for an adrenal incidentaloma

Condition	History	Physical exam
Hyper-cortisolism (Cushing's syndrome)	Weight gain, central obesity, easy bruising, severe hypertension, diabetes, proximal muscle weakness, fatigue, depression, sleep disturbances, menstrual irregularities and virilization (in females), or fragility fractures	Hypertension, central obesity, supraclavicular fat accumulation, a dorsocervical fat pad, facial plethora, thinned skin, purple and wide (>1 cm) striae, acne, ecchymoses, hirsutism, and proximal muscle weakness or wasting
Aldosteronism	Hypertension, hypokalemia, muscle cramping and weakness, headaches, intermittent or periodic paralysis	Hypertension, fluid retention
Pheochromocytoma	Headaches, anxiety attacks, sweating, palpitations, or family history of von Hippel-Lindau disease, multiple endocrine neoplasia type 2, familial paraganglioma syndrome, or neurofibromatosis type 1	Severe hypertension, tachycardia, arrhythmias, congestive heart failure, excessive sweating, anxiety, and pallor
Adrenocortical carcinoma	Flank pain, vague abdominal discomfort, hypercortisolism, virilization, feminization or aldosteronism	Weight loss, hirsutism, gynecomastia, signs of hypercortisolism
Metastasis	Personal and family history of malignant lesions, weight loss, unexplained fevers, lack of adherence to an age-appropriate cancer screening program, and smoking history	Lymphadenopathy, lung mass, breast mass, renal mass or skin lesion suspicious for melanoma, as well as other cancer-specific findings

during the CT: before injection of contrast medium (HU.pre), at 70 seconds following injection of contrast medium (HU.peak), and then at 15 minutes after contrast injection (HU.15min). From this, the absolute ($=100 \times [\text{HU.peak} - \text{HU.15min}] / [\text{HU.peak} - \text{HU.pre}]$) and relative ($=100 \times [\text{HU.peak} - \text{HU.15min}] / \text{HU.peak}$)

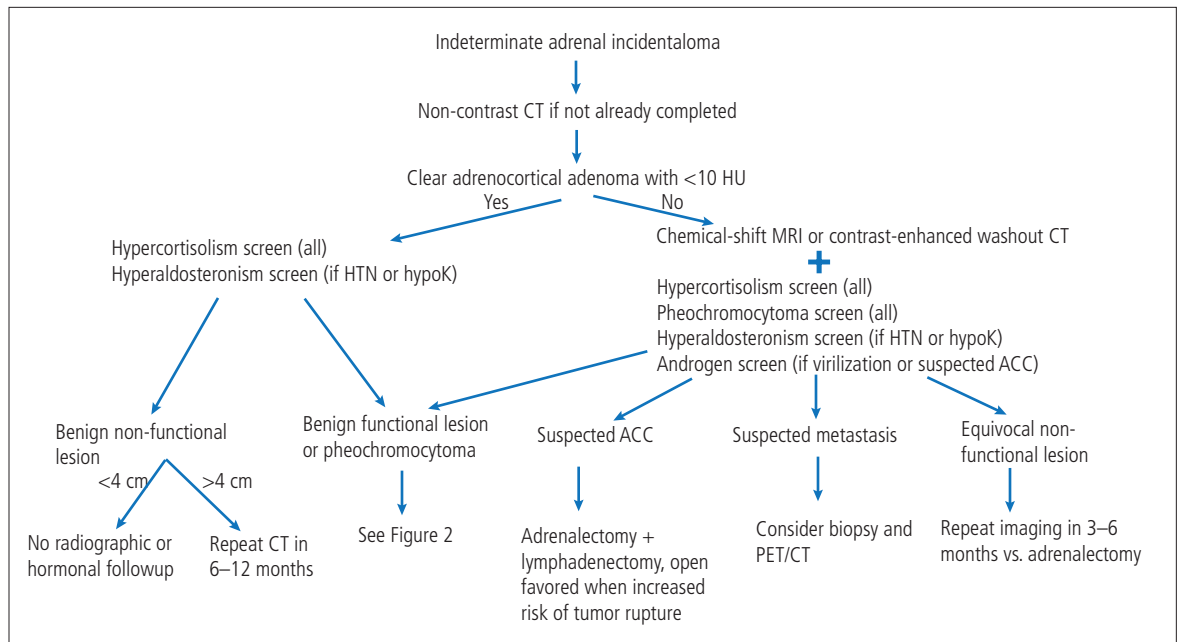


Figure 1. Algorithm for the workup of an adrenal incidentaloma. ACC: adrenocortical carcinoma; CT: computed tomography; HTN: hypertension; hypok: hypokalemia; MRI: magnetic resonance imaging; PET: positron emission tomography.

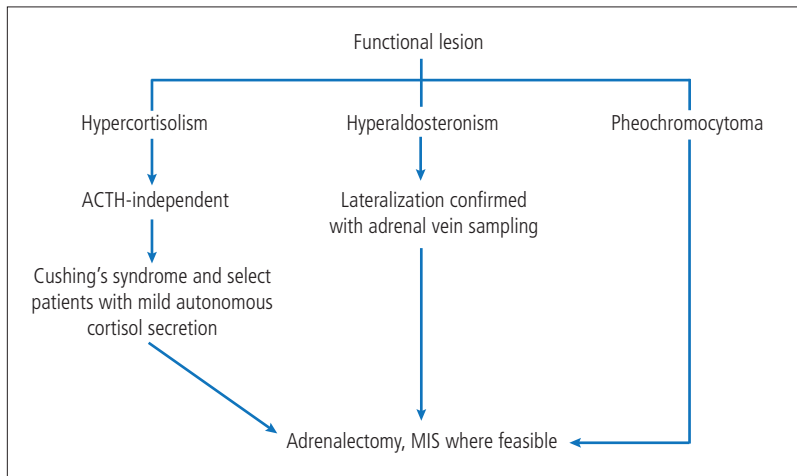


Figure 2. Management of a functional adrenal lesion. ACTH: adrenocorticotrophic hormone MIS: minimally invasive surgery.

contrast enhancement washout can be calculated. A relative washout >40% and an absolute washout >60% support the diagnosis of a benign mass.¹⁹⁻²³

Recently, contrast-enhanced washout CT has come under scrutiny due to newer data evaluating its test properties.²¹⁻²³ Limitations of the adrenal washout CT test relate to both false-positive and false-negative rates. It is now widely known that roughly 1/3 of pheochromocytomas may washout in the characteristic range of an adenoma.^{24,25} Although pheochromocytomas are usually heterogeneous and show higher CT peak attenuation compared to adenoma, there is significant

overlap between groups, preventing a confident imaging diagnosis.²⁶ On the contrary, approximately 1/3 of adrenal adenomas do not washout in the adenoma range.²⁷ Moreover, malignant masses can also washout in the adenoma range, which can result in adrenal cortical carcinoma or hypervascular metastases being mistaken for an adenoma on a CT washout.^{24,28} Clinicians who use washout CTs for characterization of indeterminate adrenal masses should be aware of these above-stated limitations.

A second option for imaging an adrenal mass that is indeterminate on a non-contrast CT scan is chemical-shift MRI. Chemical-shift MRI exploits the different frequency of protons in water and fat and is used to detect microscopic fat.²⁹ Chemical-shift MRI is highly sensitive for microscopic fat and can detect microscopic fat in adrenal adenomas that measure >10 HU on a non-contrast CT and would otherwise be considered lipid-poor.³⁰ Chemical-shift MRI is most useful for adrenal masses that measure 10–30 HU on a non-contrast CT.³⁰ When microscopic fat is identified as a homogeneous signal intensity drop on chemical-shift MRI, these features are diagnostic of lipid-rich adrenal adenoma. Heterogeneous signal intensity drop is a more controversial imaging finding since minute amounts of microscopic fat have been identified in pheochromocytoma, adrenal cortical carcinoma, and some fat-containing metastases.²⁹

A recent systematic review and meta-analysis assessing the test properties of washout CT scans vs. chemi-

cal-shift MRI at evaluating indeterminate adrenal lesions was unable to determine superiority of one second-line imaging modality over another. This was largely due to the low number and poor quality of eligible studies.⁵ Evidence for both washout CT and MRI are weak and there are no head-to-head comparisons for use as a second-line imaging test. The primary advantages of MRI compared to washout CT are the absence of radiation exposure and the lack of iodinated contrast media, making MRI appealing in both young patients (less than 40 years of age), pregnant patients, and those with renal insufficiency. Cost and access, however, are important limitations of MRI in Canada at the present time.

■ RECOMMENDATION 4

Patients who have an indeterminate adrenal mass on non-contrast CT should undergo second-line imaging with either washout CT or chemical-shift MRI (*Weak recommendation, moderate-quality evidence*).

Role of biopsy

Adrenal mass biopsy is rarely indicated in the workup of an incidental adrenal lesion. Biopsy may be considered when the diagnosis of metastatic disease from an extra-adrenal malignancy would be of value. While biopsy can differentiate metastasis from lipid-poor adenomas and pheochromocytomas, it cannot differentiate an adenoma from an ACC. A 2016 systematic review found that adrenal mass biopsy was associated with a low risk of complication (2.5%) and good diagnostic performance

(sensitivity of 87%, specificity 100%).⁵ Biopsy of suspected ACC should not be routinely performed due to potential risk of tumor seeding the needle tract.³¹ Prior to biopsy, it is crucial to ensure that a pheochromocytoma has been excluded.

■ RECOMMENDATION 5

Adrenal mass biopsy should not be performed routinely for the workup of an adrenal incidentaloma (*Strong recommendation, moderate-quality evidence*).

Laboratory evaluation

Adrenal lesions can be hormonally active and secrete cortisol, aldosterone, catecholamines, sex hormones, or steroid precursors. The optimal tests for each of these and their interpretation is outlined in Table 5.

The most widely accepted screening test to identify cortisol excess is the 1 milligram (mg) overnight dexamethasone suppression test, although there have been no head-to-head comparisons between alternative tests to assess their diagnostic performance. For the 1 mg overnight dexamethasone suppression test, the patient is given a prescription for 1 mg of dexamethasone to be taken at 11 pm, and the serum cortisol level is measured the following morning at 8 am. Even though cortisol secretion by adrenal adenomas is likely a continuous rather than categorical variable, it is clinically useful to have thresholds. There is evidence to support using a result of ≤ 50 nmol/L (≤ 1.8 $\mu\text{g/dL}$) as sufficient to exclude autonomous cortisol excess (sensitivity >95%).

Table 5. Functional workup for adrenal incidentalomas

Hormone excess	Population	Tests	Interpretation	Ancillary testing
Cortisol	All AIs	1 mg dexamethasone suppression test: 1 mg taken at 11 pm, serum cortisol measured at 8 am	<ul style="list-style-type: none"> – ≤ 50 nmol/L excludes cortisol hypersecretion – 51–138 nmol/L possible autonomous cortisol secretion – >138 nmol/L evidence of cortisol hypersecretion 	<ul style="list-style-type: none"> – ACTH-independency should be confirmed in all patients considering intervention by measuring plasma ACTH – 24-hr urinary-free cortisol, midnight salivary cortisol – DHEAS
Aldosterone	Hypertension/Hypokalemia	Aldosterone-to-renin ratio	20 ng/dL per ng/mL/hr has excellent sensitivity and specificity (>90%) for confirming hyperaldosteronism (labs may have their own calibrated reference cutoffs)	Adrenal vein sampling for lateralization, saline suppression, and salt-loading with 24-hr urine aldosterone measurement
Catecholamines	HU ≥ 10 or HU not available	<ul style="list-style-type: none"> – Plasma-free metanephrines – 24-hour urinary fractionated metanephrines 	$>2\text{X}$ upper limit of normal	N/A
Androgens	Suspected ACC or virilization	DHEAS, testosterone	Higher levels suggest greater burden of disease	17 β -estradiol, 17-OH progesterone, androstenedione, 17-OH pregnenolone, 11-deoxycorticosterone, progesterone, and estradiol

ACC: adrenocortical carcinoma; ACTH: adrenocorticotropic hormone; AI: adrenal incidentaloma; DHEAS: dehydroepiandrosterone sulfate; N/A: not applicable.

Similarly, cortisol levels >138 nmol/L (>5.0 $\mu\text{g/dL}$) are in keeping with autonomous cortisol secretions and levels between 51 and 138 nmol/L (1.9–5.0 $\mu\text{g/dL}$) can be considered equivocal.³²⁻³⁴

There are a few important factors to consider when interpreting the results of a 1 mg overnight dexamethasone suppression test. First, it is important to note that dexamethasone is metabolized through the CYP3A4 enzyme, and its levels can, therefore, be increased or decreased by several interacting medications. Second, estrogens increase cortisol-binding globulin, resulting in a 50% false-positive rate on the 1 mg dexamethasone suppression test in women taking oral contraceptives. Third, patients with critical illness, depression, or shift workers may have a blunted circadian rhythm of cortisol secretion. In these instances, an alternative biochemical test, such as a 24-hour urinary-free cortisol or midnight salivary cortisol, may be considered (Table 5). If hypercortisolism is confirmed on the 1 mg dexamethasone suppression test, referral to endocrinology for additional biochemical tests is warranted. This generally includes confirmatory testing and confirmation of adrenocorticotropic hormone (ACTH)-independent cortisol secretion.

The panel supports screening for cortisol excess in all patients with adrenal incidentalomas given that imaging remains imperfect, with many lipid-poor adenomas overlapping with malignant adrenal masses and pheochromocytomas as discussed above, as well as there likely being a subset of patients with autonomous cortisol secretion but no overt Cushing's syndrome who could benefit from surgical resection (discussed below).

■ RECOMMENDATION 6.1

All patients with adrenal incidentalomas should be screened for autonomous cortisol secretion (*Weak recommendation, moderate-quality evidence*).

■ RECOMMENDATION 6.2

1 mg dexamethasone suppression testing is the preferred screening test for identifying autonomous cortisol secretion when clinically appropriate (*Strong recommendation, moderate-quality evidence*).

For patients with hypertension and/or hypokalemia in whom hyperaldosteronism is suspected, the preferred initial test is the aldosterone/renin ratio (ARR).³⁵ This test is best done in the morning once the patient has been out of bed for two hours and has been seated for 5–15 minutes. Ideally, patients should be potassium-replete and mineralocorticoid receptor (MR) antagonists should be withdrawn for at least four weeks before ARR testing. Stopping angiotensin-converting

enzyme inhibitors (ACEI) and angiotensin II receptor blockers (ARB) prior to this testing is not required, as the effect on the ARR is minimal and can be interpreted in light of these confounding factors.^{35,36}

β -adrenergic blockers and central agonists, however, can lead to false-positive results by increasing plasma aldosterone and decreasing renin levels. Ideally, these medications would be halted at least two weeks prior to testing. In most cases, verapamil, hydralazine, prazosin, and doxazosin generally do not have a significant effect on ARR and can be continued or substituted for interfering medications.³⁷

An ARR >20 ng/dL per ng/mL/hr has excellent sensitivity and specificity ($>90\%$) for the diagnosis of hyperaldosteronism.³⁵⁻³⁸ In addition, suppressed renin levels (i.e., <0.6 ng/mL/hr) are a strong independent predictor of the autonomous aldosterone secretion seen in cases of hyperaldosteronism.³⁹ Saline suppression and salt-loading with 24-hour urine aldosterone measurement are confirmatory tests that can be considered. A comprehensive review of the diagnosis and management of hyperaldosteronism is outside the scope of this guideline, and we direct readers to clinical practice guidelines and excellent expert reviews on this topic.^{40,41}

Furthermore, for most patients, it is paramount to confirm lateralization of aldosterone hypersecretion to the side of the adrenal lesion with adrenal vein sampling (AVS). In a systematic review comprised of 950 patients treated between 1977 and 2009, the authors found that a CT/MRI lesion was discordant with AVS results in 40% of patients. Relying only on CT/MRI results would have led to inappropriate adrenalectomy in 15% of patients (where AVS showed a bilateral problem, better treated with medical therapy), inappropriate exclusion from adrenalectomy in 19% of patients (where AVS showed unilateral secretion), and wrong-sided adrenalectomy in 4% of patients (where AVS showed aldosterone hypersecretion on the contralateral side of the adrenal mass).^{42,43} The concordance between imaging and AVS appears better in younger patients (age less than 40), but omission of this test in this age group remains controversial.⁴⁴

■ RECOMMENDATION 7.1

Patients with adrenal incidentalomas and hypertension and/or hypokalemia should be screened for primary aldosteronism with an ARR (*Strong recommendation, moderate-quality evidence*).

■ RECOMMENDATION 7.2

Adrenal vein sampling is recommended prior to offering adrenalectomy in patients with primary aldosteronism (*Strong recommendation, moderate-quality evidence*).

Screening for pheochromocytoma is primarily done by measuring plasma-free metanephrines or 24-hour urinary fractionated metanephrines, depending on center-specific testing availability. Plasma normetanephrine levels >2.2 nmol/L or metanephrine levels >1.2 nmol/L are highly specific for catecholamine hypersecretion.⁴⁵ A 24-hour urinary metanephrine level two times greater than the upper limit of normal is similarly highly sensitive and specific.⁴⁶

Traditionally, it has been recommended that all patients with adrenal incidentalomas be tested for pheochromocytomas. Recent evidence from observational studies suggests that biochemical testing for pheochromocytoma is unnecessary in adrenal incidentalomas with unenhanced attenuation of <10 HU (adrenal adenomas).⁴⁷⁻⁴⁹ In the largest of these trials, 99.5% (374/376) of patients with pheochromocytomas had unenhanced attenuation of >10 HU upon retrospective review. The remaining two patients' masses were exactly 10 HU, with none displaying <10 HU.

Considering this emerging evidence, and the fact that biochemical testing for pheochromocytoma can be cumbersome, time-consuming, and frequently falsely positive, the panel felt it could be omitted in cases when unenhanced CT is clearly in keeping with an adrenocortical adenoma (HU <10).

■ RECOMMENDATION 8.1

Screening for pheochromocytoma can be omitted in patients who have unequivocal adrenocortical adenomas confirmed on unenhanced CT (HU <10) and no signs or symptoms of adrenergic excess (*Weak recommendation, low-quality evidence*).

■ RECOMMENDATION 8.2

Patients with adrenal incidentalomas that display ≥ 10 HU on non-contrast CT or who have signs/symptoms of catecholamine excess should be screened for pheochromocytoma with plasma or 24-hour urinary metanephrines (*Strong recommendation, moderate-quality evidence*).

Adrenocortical carcinoma is responsible for more than half of androgen hypersecretion, which can be confirmed by testing serum levels of dehydroepiandrosterone (DHEA-S), testosterone, 17 β -estradiol, 17-OH progesterone, androstenedione, 17-OH pregnenolone, 11-deoxycorticosterone, progesterone, and estradiol.⁵⁰

■ RECOMMENDATION 9

In cases of suspected ACC and/or when clinical signs of virilization are present, serum testing for excess androgen should be performed (*Clinical principle*).

MANAGEMENT OF ADRENAL INCIDENTALOMAS

Cortisol-secreting adrenal lesions

It is well-accepted that patients with unilateral cortisol-secreting adrenal lesions and clinical signs/symptoms of Cushing's syndrome should undergo surgical resection of the hypersecreting adrenal gland;⁵¹ however, the optimal management of patients with cortisol-secreting adrenal lesions without symptoms of Cushing's syndrome is less clear. These patients, historically referred to as having subclinical Cushing's syndrome, are now labelled to have mild autonomous cortisol secretion (MACS). A recent systematic review, comprised of generally low-quality observational studies, showed an association between failed cortisol suppression on 1 mg dexamethasone suppression testing and type 2 diabetes, hypertension, cardiovascular events, vertebral fractures, and mortality.⁵ Importantly, it also revealed that across three cohort studies with median followups ranging from 3–7.5 years, no patients with failed cortisol suppression progressed to develop overt Cushing's syndrome. Based on this, the panel felt that subclinical Cushing's should be regarded as having a low risk of progression to overt Cushing's but can still contribute to medical comorbidity.

To understand the impact of surgery compared to conservative management in patients with MACS, a systematic review consisting of one randomized control trial (RCT) and three observational studies was conducted.⁵ Despite the RCT, the quality of the evidence was downgraded to low-quality given problems with confounding, bias, imprecision, and indirectness. None of the studies included in the meta-analysis looked at the impact of surgery on vertebral fractures, cardiovascular events, or mortality. The review showed that without surgery, no patients improved with respect to diabetes, hypertension, or dyslipidemia. With surgery, however, improvements were seen in the rates of diabetes and the severity of hypertension and dyslipidemia.⁵ Based on this data, the panel felt that adrenalectomy could be an option for select patients with MACS, particularly those who are young or have progressive metabolic comorbidities attributable to cortisol excess.

RECOMMENDATION 10.1

Patients with unilateral cortisol-secreting adrenal masses and clinically apparent Cushing's syndrome should undergo unilateral adrenalectomy of the affected adrenal gland. Minimally invasive surgery (MIS) should be performed when feasible (*Clinical principle*).

RECOMMENDATION 10.2

Younger patients with mild autonomous cortisol secretion who have progressive metabolic comorbidities attributable to cortisol excess can be considered for adrenalectomy after shared decision-making. Patients not managed surgically should undergo annual clinical screening for new or worsening associated comorbidities (*Weak recommendation, low-quality evidence*).

Aldosterone-secreting adenomas and pheochromocytomas

It is also well-accepted that patients with confirmed pheochromocytomas or unilateral aldosterone-producing adrenal adenomas should undergo surgical resection.^{34,52} The perioperative considerations for removal of a functional adrenal lesion are beyond the scope of this guideline. Specific followup recommendations for pheochromocytomas can be found in a recently published CUA best practice report.⁵³ Following resection of aldosterone-secreting adenomas, postoperative imaging is not necessary and postoperative hormonal workup is only required in the short-term to confirm resolution of hyperfunction. Lack of biochemical cure should raise concern for bilateral disease, recurrence of aldosterone-secreting carcinoma (rare), or removal of the non-hypersecreting adrenal gland if surgery was not guided by AVS.

RECOMMENDATION 11

Adrenalectomy should be performed for patients with unilateral aldosterone-secreting adrenal masses and pheochromocytomas. MIS should be performed when feasible (*Clinical principle*).

Adrenocortical carcinomas

In patients with suspected ACC, resection is recommended.⁵⁴ A systematic review of the literature looked at the impact of laparoscopic vs. open approach for such cases.⁵ This systematic review included observational studies of very low quality and had important differences in prognostic factors, such as tumor size and stage. Authors did not detect any difference in completeness of resection, recurrence-free status, and overall survival between laparoscopic and open approaches to adrenalectomy. None of the included studies mea-

sured patients' postoperative pain scores or patient satisfaction, which tend to be improved with laparoscopic vs. open adrenalectomy. There did appear to be increased major postoperative complications with open rather than laparoscopic procedures.⁵ Other studies have found minimally invasive adrenalectomy for ACC to be associated with higher rates of peritoneal dissemination.^{55,56} The European Society of Endocrinology set a cutoff of 6 cm for opting for open rather than laparoscopic adrenalectomy, but this was not based on high-quality evidence from clinical studies.⁵ Similarly, a multidisciplinary expert panel from the University of Southern California strongly recommended an open approach when treating masses >5 cm.⁹

Based on the above, the panel did not feel it could confidently provide a size cutoff at which point it becomes unsafe to perform minimally invasive adrenalectomy for suspected ACC. It acknowledges that MIS adrenalectomy likely has benefits with decreased morbidity and improved recovery, provided resection can be done without rupture of the tumor capsule, which represents a major risk factor for recurrence.

The role of lymphadenectomy is not clearly established. The National Comprehensive Cancer Network guidelines recommend concurrent lymphadenectomy when performing an adrenalectomy.⁵⁷ In a retrospective review of 386 patients with stage I-III ACC who underwent a lymphadenectomy, the authors found that median survival was incrementally worse for patients with more positive nodes, and that lymphadenectomy may be associated with improved survival in cNI patients. If feasible, performing a lymphadenectomy at the time of ACC resection should be considered, as it can at least provide important prognostic information.⁵⁸

Lastly, adrenalectomy can be considered in select cases of metastatic ACC when complete resection of the primary tumor and all metastases is feasible at the time of primary diagnosis.⁵⁴ Management of metastatic ACC is beyond the scope of this guideline.

RECOMMENDATION 12.1

Minimally invasive adrenalectomy can be offered to patients with suspected ACC that can be safely resected without rupturing the tumor capsule (*Weak recommendation, low-quality evidence*).

RECOMMENDATION 12.2

Open adrenalectomy should be considered for patients with larger ACC or those presenting with locally advanced tumors, lymph node metastases, or tumor thrombus in the renal vein/inferior vena cava (*Strong recommendation, low-quality evidence*).

Benign non-functioning lesions

Previous recommendations from the CUA suggested repeating imaging at 12 months from diagnosis for benign non-functioning adrenal lesions and repeating a hormonal workup annually for four years.⁴

In over 2300 patients who had initial characteristic radiological features of an adenoma, no patients were found to develop an adrenal malignancy.^{1,59} Similarly, in a study of 973 consecutive patients with an incidental adrenal mass and no history of cancer, no malignant lesions were identified.² The sole case of malignancy identified in an adrenal lesion, which was referenced in the previous CUA guideline, occurred in a patient with known renal cell carcinoma, and hence the adrenal lesion was not truly an adrenal incidentaloma. In light of the demonstrated safety, as well as the burden of the number of followup imaging tests that would be required given the high prevalence of adrenal incidentalomas and the potential cost to the healthcare system, surveillance imaging is no longer recommended for patients with a characteristic adrenal adenoma (<10 HU on non-contrast CT).

A patient's risk of developing clinically relevant hormonal excess when the initial workup is in keeping with a non-functioning lesion is also low. A systematic review of over 2000 patients examining the natural history of apparently benign non-functioning adrenal incidentalomas found that the risk of developing clinically apparent Cushing's, an aldosterone-producing adenoma, or a pheochromocytoma were 0.3%, 0–2%, and 0–2%, respectively.^{1,5,6} Based on these numbers, over 95% of patients will be screened annually unnecessarily. Although a hormonal workup is non-invasive and has minimal procedural risks, the tests do come with a risk of false-positive results, which could lead to further unnecessary testing, intervention, and harm. Furthermore, there is no evidence that hormonal testing is superior to routine clinical assessment to identify clinically significant hormone excess.

Cawood et al calculated a baseline hormonal workup for an adrenal incidentaloma to cost \$120 USD in 2018.⁵⁹ Extrapolating this to the large number of incident cases detected per year would represent a significant cost burden, especially in a publicly funded healthcare system such as Canada's. Performing an annual targeted history and physical in these patients, and reserving repeat hormonal testing for those suspected to have developed clinically significant hormone excess is likely to be an efficacious strategy that will decrease the chances of false-positive results and will be cost-effective. For these reasons, repeat hormonal workups are also no longer recommended unless there are new clinical signs and/or symptoms of hormonal excess.

RECOMMENDATION 13

Patients with benign non-functioning adenomas <4 cm, myelolipomas, and other small masses containing macroscopic fat detected on the initial workup for an adrenal incidentaloma do not require further followup imaging or functional testing (*Strong recommendation, moderate-quality evidence*).

An exception to this rule has traditionally been patients with incidentalomas >4 cm. These patients would undergo resection out of concerns for possible malignancy, even if the imaging had characteristically benign features. This was based on retrospective studies showing that most surgically resected pheochromocytomas and ACCs were >4 cm at time of diagnosis.^{60,61} There is very little data on followup of benign-appearing, large adrenal incidentalomas to guide these decisions. Azoury et al, however, do report that regardless of size, when an adrenal mass is interpreted as benign on CT, there is 100% concordance with benign final pathology.¹¹

Corwin et al studied the growth rate of smaller adrenal masses. In their retrospective review, they compared the growth rate of adrenal adenomas (105) vs. malignant adrenal nodules (26).⁶² The mean nodule size at baseline was 18.4 mm (range 9–38 mm) for the adenoma group and 29.8 mm (range 0–117 mm) for the malignant group. Their results showed that approximately one-third of radiologically proven adrenal adenomas grew, all at a rate <3 mm/year. All malignant adrenal nodules grew, and all at a rate >5 mm/year. A growth rate of 3 mm/year distinguished adenomas from malignant nodules with a sensitivity of 100% (95% confidence interval [CI] 86.8–100%) and a specificity of 100% (95% CI 96.6–100%).⁶²

The European Endocrine Society recommends using the RECIST 1.1 criteria of an increase >20% with an absolute increase of at least 5 mm in diameter to define significant growth.⁶³ It is important to note that the RECIST 1.1 criteria have not been formally validated in adrenal tumors.

Ultimately, in the setting of a benign-appearing adrenal mass >4 cm, the panel felt that followup imaging after 6–12 months can be considered. Lack of growth of a mass over this period makes a malignancy highly unlikely. Conversely, significant growth of a lesion can be a clue to underlying malignancy and prompt the need for surgical excision. For lesions that grow less than this threshold, re-imaging in 6–12 months can be considered.

RECOMMENDATION 14.1

Patients with non-functioning adrenal lesions that are radiologically benign (<10 HU) but >4 cm should undergo repeat imaging in 6–12 months (*Weak recommendation, low-quality evidence*).

RECOMMENDATION 14.2

Adrenalectomy should be considered for patients with adrenal incidentalomas growing >5 mm/year after repeating a functional workup (*Weak recommendation, low-quality evidence*).

RECOMMENDATION 14.3

No further imaging followup or functional testing is required for patients with adrenal lesions that grow <3 mm/year on followup imaging (*Weak recommendation, low-quality evidence*).

Indeterminate non-functioning lesions

Despite first- and second-line imaging, some adrenal incidentalomas may still remain indeterminate. There is no data to guide the best treatment approach in this clinical scenario.

RECOMMENDATION 15

Shared decision-making between patients and their clinicians should be used for the management of indeterminate non-functioning adrenal lesions. Management options include repeat imaging in 3–6 months vs. surgical resection (*Clinical principle*).

SPECIAL POPULATIONS**Bilateral adrenal incidentalomas**

In the setting of bilateral adrenal incidentalomas, each lesion should be separately characterized in the same fashion as a unilateral adrenal incidentaloma, and the same indications for surgery/followup should be followed. Additional considerations include measuring serum 17-hydroxyprogesterone to exclude congenital adrenal hyperplasia, and assessing for adrenal insufficiency in suspected cases of bilateral infiltrative disease, metastases, or hemorrhage.^{5,64,65} Given that bilateral adrenalectomy is associated with higher morbidity than a unilateral adrenalectomy (such as dependence on lifelong adrenal replacement therapy and risk of adrenal crisis), consideration should be given to adrenal-sparing surgery when appropriate.

Young/pregnant/elderly patients

The prevalence of adrenal incidentalomas increases with age. Adrenal incidentalomas are felt to be rare in childhood and adolescence, have a prevalence of approximately 4% in adults, and 10% in individuals over 70 years of age.⁶⁶⁻⁶⁸ Although there is no strong data to support it, it is generally believed that adrenal lesions in young adults, children, and pregnant patients are more likely to be malignant and, therefore, an evaluation should

be expedited. In these individuals, radiation safety is an important consideration and low-dose CT, or chemical-shift MRI may be preferred first-line imaging tests.

A small incidentaloma in the elderly patient is less likely to be malignant and, therefore, when there is no clear sign or suspicion of malignancy, the planned workup and management should be adjusted based on the performance status of the individual and potential clinical gains.

History of extra-adrenal malignancy

Available evidence suggests that in patients with a history of an extra-adrenal malignancy, only 7% of adrenal metastases have <10 HU on CT. Lesions >10 HU, however, are malignant in 70% of patients with a history of extra-adrenal malignancy.⁵ When characterization of these lesions will alter clinical management, adrenal biopsy and fluorine-18 fluorodeoxyglucose positron emission tomography (¹⁸F-FDG-PET) can be useful adjuncts.^{69,70}

¹⁸F-FDG-PET is a nuclear medicine imaging test conducted after the intravenous injection of ¹⁸F-FDG. Uptake of ¹⁸F-FDG occurs in cells with increased energy requirements, such as malignant tumors. These studies are often combined with CT for better anatomic overlay and are most useful in oncology patients who have a large, enlarging, or indeterminate adrenal mass where exclusion of metastasis is warranted.⁷⁰⁻⁷³ Although adenomas generally do not exhibit significant FDG uptake on PET imaging, exceptions exist. Accordingly, increased standardized uptake values (SUVs) of an adrenal lesion with otherwise benign imaging characteristics must be interpreted in the context of each clinical scenario.^{74,75}

Surgery or other local therapies can be considered for metastasis to the adrenal gland on a case-by-case basis where potential oncological benefit exists, as determined by a multidisciplinary team.

Partial adrenalectomy

Patients with hereditary syndromes are at increased likelihood of disease in the contralateral gland. Similarly, pheochromocytomas and aldosterone-producing adenomas can also have bilateral involvement. It is also estimated that approximately 1% of the population have adrenal gland function affected by various pathological processes, such as infectious or infiltrative processes. In all these patients, there may be an emerging role for partial adrenalectomy to avoid the need for lifelong adrenal replacement therapy.⁷⁶

FUTURE DIRECTIONS

Our current workup of incidental adrenal lesions has sensitivity and specificity limitations in determining whether an incidental adrenal lesion is benign or malignant. As a result, some patients receive unne-

essary adrenalectomy, some patients' care is delayed, and some are subjected to unnecessary followup investigations with associated ionizing radiation. To address this, recent research efforts have focused on the development of urine steroid metabolomics to better risk-stratify patients. Studies have shown that ACC have a distinct pattern of urinary corticosteroid excretion, characterized by an excess of precursor steroid metabolites. Using a combination of mass spectrometry-based urinary steroid metabolite profiling and machine learning-based data analysis, urine steroid metabolomic testing can quantify this.

In a 2020, prospective, multicenter study (EURINE-ACT), urine steroid metabolomics were used in conjunction with tumor diameter and imaging characteristics to characterize adrenal incidentalomas, and this "triple test" strategy had a sensitivity of 82.7% and specificity of 95.7%.⁷⁷ Interestingly, in this study, the authors also showed that using a cutoff of 20 HU instead of 10 HU increased the specificity of unenhanced CT scans in detecting malignant lesion to 80% from 64%, while sensitivity remained similar. These results are certainly promising and require further validation. Hopefully, these non-invasive tests are able to help further risk-stratify patients in the future, allowing for prompt management of patients with ACC, and avoiding the need for unnecessary followup testing and associated harms in those with benign lesions.

CONCLUSIONS

Incidental adrenal masses are common, and most of these lesions are benign. Nonetheless, identification and timely management of functional and malignant lesions is crucial. This guideline provides a contemporary approach to the appropriate clinical, radiographical, and endocrine assessments required for the evaluation, management, and followup of patients with such lesions.

COMPETING INTERESTS: The authors and reviewers do not report any competing personal or financial interests related to this work.

REFERENCES

1. NIH state-of-the-science statement on management of the clinically inapparent adrenal mass ("incidentaloma"). *NIH Consens State Sci Statements* 2002;19:1-25. Available at <https://consensus.nih.gov/2002/2002AdrenalIncidentalomas021main.htm>
2. Song JH, Chaudhry FS, Mayo-Smith WW. The incidental adrenal mass on CT: Prevalence of adrenal disease in 1049 consecutive adrenal masses in patients with no known malignancy. *AJR Am J Roentgenol* 2008;190:1163-8. <https://doi.org/10.2214/AJR.07.2799>
3. Young Jr. WF. Management approaches to adrenal incidentalomas: A view from Rochester, Minnesota. *Endocrinol Metab Clin North Am* 2000;29:159-85. [https://doi.org/10.1016/S0889-8529\(05\)70122-5](https://doi.org/10.1016/S0889-8529(05)70122-5)
4. Kapoor A, Morris T, Rebello R. Guidelines for the management of the incidentally discovered adrenal mass. *Can Urol Assoc J* 2011;5:241-7. <https://doi.org/10.5489/cuaj.657>
5. Fassnacht M, Arlt W, Bancos I, et al. Management of adrenal incidentalomas: European Society of Endocrinology clinical practice guideline in collaboration with the European Network for the Study of Adrenal Tumors. *Eur J Endocrin* 2016;175:G1-34. <https://doi.org/10.1530/EJE-16-0467>
6. Zeiger MA, Thompson GB, Duh QY, et al. American Association of Clinical Endocrinologists and American Association of Endocrine Surgeons medical guidelines for the management of adrenal incidentalomas. *Endocrine Pract* 2009;15:1-20. <https://doi.org/10.4158/EP.15.S1.1>
7. Lee JM, Kim MK, Ko SH, et al. Clinical guidelines for the management of adrenal incidentaloma. *Endocrin Metab* 2017;32:200-18. <https://doi.org/10.3803/EnM.2017.32.2.200>
8. Mayo-Smith WW, Song JH, Boland GL, et al. Management of incidental adrenal masses: A white paper of the ACR Incidental Findings Committee. *J Am Coll Radiol* 2017;14:1038-44. <https://doi.org/10.1016/j.jacr.2017.05.001>
9. Maas M, Nassiri N, Bhanvadia S, et al. Discrepancies in the recommended management of adrenal incidentalomas by various guidelines. *J Urol* 2021;205:52-9. <https://doi.org/10.1097/JU.0000000000001342>
10. McInnes M, Schieda N. Revising adrenal incidentalomas followup recommendations in CUA guideline. *Can Urol Assoc J* 2021;15:E232. <https://doi.org/10.5489/cuaj.7267>
11. Azoury SC, Nagarajan N, Young A, et al. Computed tomography in the management of adrenal tumors. *J Computer Assist Tomograph* 2017;41:628-32. <https://doi.org/10.1097/RCT.0000000000000578>
12. Kahramangil B, Kose E, Remer EM, et al. A modern assessment of cancer risk in adrenal incidentalomas. *Ann Surg* 2020;275:e238-44. <https://doi.org/10.1097/SLA.00000000000004048>
13. Young WF Jr. The incidentally discovered adrenal mass. *N Engl J Med* 2007;356:601-10. <https://doi.org/10.1056/NEJMc065470>
14. Dinnes J, Bancos I, Ferrante di Ruffano L, et al. Imaging for the diagnosis of malignancy in incidentally discovered adrenal masses — a systematic review and meta-analysis. *Eur J Endocrinol* 2016;175:R51-64. <https://doi.org/10.1530/EJE-16-0461>
15. Ranathunga DS, Cherpak LA, Schieda N, et al. Macroscopic fat in adrenocortical carcinoma: A systematic review. *Am J Roentgenol* 2020;214:390-4. <https://doi.org/10.2214/AJR.19.21851>
16. Guccione J, Soliman M, Zhang M, et al. Imaging characteristics of pathologically proven adrenal adenomas with myelolipomatous degeneration: Correlation with clinical and pathologic features. *Br J Radiol* 2022;95:20210555. <https://doi.org/10.1259/bjr.20210555>
17. Boland GW, Lee MJ, Gazelle GS, et al. Characterization of adrenal masses using unenhanced CT: An analysis of the CT literature. *Am J Roentgenol* 1998;171:201-4. <https://doi.org/10.2214/ajr.171.1.9648789>
18. Caoili EM, Korobkin M, Francis IR, et al. Delayed enhanced CT of lipid-poor adrenal adenomas. *Am J Roentgenol* 2000;175:1411-5. <https://doi.org/10.2214/ajr.175.5.1751411>
19. Pena CS, Boland GW, Hahn PF, et al. Characterization of indeterminate (lipid-poor) adrenal masses: Use of washout characteristics at contrast-enhanced CT. *Radiology* 2000;217:798-802. <https://doi.org/10.1148/radiology.217.3.r00d29798>
20. Zhang HM, Perrier ND, Grubbs EG, et al. CT features and quantification of the characteristics of adrenocortical carcinomas on unenhanced and contrast-enhanced studies. *Clin Radiol* 2012;67:38-46. <https://doi.org/10.1016/j.crad.2011.03.023>
21. Corwin MT, Remer EM. Adrenal washout CT: Point-not useful for characterizing incidentally discovered adrenal nodules. *Am J Roentgenol* 2021;216:1166-7. <https://doi.org/10.2214/AJR.20.24417>
22. Corwin MT, Badawy M, Caoili EM, et al. Incidental adrenal nodules in patients without known malignancy: Prevalence of malignancy and utility of washout CT for characterization — a multi-institutional study. *Am J Roentgenol* 2022;219:804-12. <https://doi.org/10.2214/AJR.22.27901>
23. Dunnick NR, Korobkin M. Imaging of adrenal incidentalomas: Current status. *Am J Roentgenol* 2002;179:559-68. <https://doi.org/10.2214/ajr.179.3.1790559>
24. Szolar DH, Kammerhuber FH. Adrenal adenomas and non-adenomas: Assessment of washout at delayed contrast-enhanced CT. *Radiology* 1998;207:369-75. <https://doi.org/10.1148/radiology.207.2.9577483>
25. Akbulut S, Erten O, Kahramangil B, et al. A critical analysis of computed tomography washout in lipid-poor adrenal incidentalomas. *Ann Surg Oncol* 2021;28:2756-62. <https://doi.org/10.1245/s10434-020-09329-1>
26. Schieda N, Siegelman ES. Update on CT and MRI of adrenal nodules. *Am J Roentgenol* 2017;208:1206-17. <https://doi.org/10.2214/AJR.16.17758>
27. Schieda N, Alrashed A, Flood TA, et al. Comparison of quantitative MRI and CT washout analysis for differentiation of adrenal pheochromocytoma from adrenal adenoma. *Am J Roentgenol* 2016;206:1141-8. <https://doi.org/10.2214/AJR.15.15318>
28. Choi YA, Kim CK, Park BK, et al. Evaluation of adrenal metastases from renal cell carcinoma and hepatocellular carcinoma: Use of delayed contrast-enhanced CT. *Radiology* 2013;266:514-20. <https://doi.org/10.1148/radiol.12120110>

29. Schieda N, Al Dandan O, Kielar AZ, et al. Pitfalls of adrenal imaging with chemical shift MRI. *Clin Radiol* 2014;69:1186-97. <https://doi.org/10.1016/j.crad.2014.06.020>
30. Haider MA, Ghai S, Jhaveri K, et al. Chemical-shift MR imaging of hyperattenuating (>10 HU) adrenal masses: Does it still have a role? *Radiology* 2004;231:711-6. <https://doi.org/10.1148/radiol.2313030676>
31. Mody MK, Kazerooni EA, Korobkin M. Percutaneous CT-guided biopsy of adrenal masses: Immediate and delayed complications. *J Comp Assist Tomograph* 1995;19:434-9. <https://doi.org/10.1097/00004728-199505000-00017>
32. Di Dalmazi G, Vicennati V, Rinaldi E, et al. Progressively increased patterns of subclinical cortisol hypersecretion in adrenal incidentalomas differently predict major metabolic and cardiovascular outcomes: A large, cross-sectional study. *Eur J Endocrin* 2012;166:669-77. <https://doi.org/10.1530/EJE-11-1039>
33. Debono M, Bradburn M, Bull M, et al. Cortisol as a marker for increased mortality in patients with incidental adrenocortical adenomas. *J Clin Endocrinol Metab* 2014;99:4462-70. <https://doi.org/10.1210/jc.2014-3007>
34. Di Dalmazi G, Vicennati V, Garelli S, et al. Cardiovascular events and mortality in patients with adrenal incidentalomas that are either non-secreting or associated with intermediate phenotype or subclinical Cushing's syndrome: A 15-year retrospective study. *Lancet Diabetes Endocrinol* 2014;2:396-405. [https://doi.org/10.1016/S2213-8587\(13\)70211-0](https://doi.org/10.1016/S2213-8587(13)70211-0)
35. Funder JW, Carey RM, Fardella C, et al (Endocrine Society). Case detection, diagnosis, and treatment of patients with primary aldosteronism: An Endocrine Society clinical practice guideline. *J Clin Endocrinol Metab* 2008;93:3266-3281. <https://doi.org/10.1210/jc.2008-0104>
36. Seifarth C, Trenkel S, Schobel H, et al. Influence of antihypertensive medication on aldosterone and renin concentration in the differential diagnosis of essential hypertension and primary aldosteronism. *Clin Endocrinol* 2002;57:457-65. <https://doi.org/10.1046/j.1365-2265.2002.01613.x>
37. Jedrusik P, Symonides B, Lewandowski J, et al. The effect of antihypertensive medications on testing for primary aldosteronism. *Front Pharmacol* 2021;12:684111. <https://doi.org/10.3389/fphar.2021.684111>
38. Stowasser M, Gordon RD. Primary aldosteronism-careful investigation is essential and rewarding. *Mol Cell Endocrinol* 2004;217:33-9. <https://doi.org/10.1016/j.mce.2003.10.006>
39. Hundemer GL, Baudrand R, Brown JM, et al. Renin phenotypes characterize vascular disease, autonomous aldosteronism, and mineralocorticoid receptor activity. *J Clin Endocrinol Metab* 2017;102:1835-43. <https://doi.org/10.1210/jc.2016-3867>
40. Funder JW, Carey RM, Mantero F, et al. The management of primary aldosteronism: Case detection, diagnosis, and treatment: An endocrine society clinical practice guideline. *J Clin Endocrinol Metab* 2016;101:1889-916. <https://doi.org/10.1210/jc.2015-4061>
41. Vaidya A, Carey RM. Evolution of the primary aldosteronism syndrome: Updating the approach. *J Clin Endocrinol Metab* 2020;105:3771-83. <https://doi.org/10.1210/clinem/dgaa006>
42. Tan YY, Ogilvie JB, Triponez F, et al. Selective use of adrenal venous sampling in the lateralization of aldosterone-producing adenomas [with discussion]. *World J Surg* 2006;30:879-87. <https://doi.org/10.1007/s00268-005-0622-8>
43. Kempers MJ, Lenders JW, van Outhousden L, et al. Systematic review: Diagnostic procedures to differentiate unilateral from bilateral adrenal abnormality in primary aldosteronism. *Ann Intern Med* 2009;151:329-37. <https://doi.org/10.7326/0003-4819-151-5-200909010-00007>
44. Quencer KB, Singh A, Sharma A. Best practices: Indications and procedural controversies of adrenal vein sampling for primary aldosteronism. *Am J Roentgenol* 2022;171:1-1. <https://doi.org/10.2214/AJR.22.27692>
45. Van Berkel A, Lenders JW, Timmers HJ. Diagnosis of endocrine disease: Biochemical diagnosis of pheochromocytoma and paraganglioma. *Eur J Endocrinol* 2014;170:R109-19. <https://doi.org/10.1530/EJE-13-0882>
46. Perry CG, Sawka AM, Singh R, et al. The diagnostic efficacy of urinary fractionated metanephrines measured by tandem mass spectrometry in detection of pheochromocytoma. *Clin Endocrinol* 2007;66:703-8. <https://doi.org/10.1111/j.1365-2265.2007.02805.x>
47. Canu L, Van Hemert JA, Kerstens MN, et al. CT characteristics of pheochromocytoma: Relevance for the evaluation of adrenal incidentaloma. *J Clin Endocrinol Metab* 2019;104:312-8. <https://doi.org/10.1210/jc.2018-01532>
48. Buitenwerf E, Korteweg T, Visser A, et al. Unenhanced CT imaging is highly sensitive to exclude pheochromocytoma: A multicenter study. *Eur J Endocrinol* 2018;178:431-7. <https://doi.org/10.1530/EJE-18-0006>
49. Gruber LM, Strajina V, Bancos I, et al. Not all adrenal incidentalomas require biochemical testing to exclude pheochromocytoma: Mayo clinic experience and a meta-analysis. *Gland Surg* 2020;9:362. <https://doi.org/10.21037/gs.2020.03.04>
50. Allolio B, Fassnacht M. Clinical review: Adrenocortical carcinoma; clinical update. *J Clin Endocrinol Metab* 2006;91:2027-37. <https://doi.org/10.1210/jc.2005-2639>
51. Nieman LK, Biller BM, Findling JW, et al. Treatment of Cushing's syndrome: An Endocrine Society clinical practice guideline. *J Clin Endocrinol Metab* 2015;100:2807-31. <https://doi.org/10.1210/jc.2015-1818>
52. Lenders JW, Duh QY, Eisenhofer G, et al. Pheochromocytoma and paraganglioma: An Endocrine Society clinical practice guideline. *J Clin Endocrinol Metab* 2014;99:1915-42. <https://doi.org/10.1210/jc.2014-1498>
53. Kumar RM, Violette PD, Tran C, et al. Canadian Urological Association best practice report: Long-term surveillance following resection of pheochromocytoma. *Can Urol Assoc J* 2019;13:372-6. <https://doi.org/10.5489/cuoj.6254>
54. Fassnacht M, Allolio B. Clinical management of adrenocortical carcinoma. *Best Pract Res Clin Endocrinol Metab* 2009;23:273-89. <https://doi.org/10.1016/j.beem.2008.10.008>
55. Payabyab EC, Balasubramaniam S, Edgerly M, et al. Adrenocortical carcinoma: A molecularly complex disease where surgery matters. *Clin Cancer Res* 2016;22:4989. <https://doi.org/10.1158/1078-0432.CCR-16-1570>
56. Wu K, Liu Z, Liang J, et al. Laparoscopic vs. open adrenalectomy for localized (stage 1/2) adrenocortical carcinoma: Experience at a single, high-volume center. *Surgery* 2018;164:1325. <https://doi.org/10.1016/j.surg.2018.07.026>
57. Shah MH, Goldner WS, Benson AB, et al. Neuroendocrine and adrenal tumors, version 2.2021, NCCN clinical practice guidelines in oncology. *J Natl Compr Canc Netw* 2021;19:839-68. <https://doi.org/10.6004/jnccn.2021.0032>
58. Tseng J, DiPeri T, Chen Y, et al. Adrenocortical carcinoma: The value of lymphadenectomy. *Ann Surg Oncol* 2022;29:1965-70. <https://doi.org/10.1245/s10434-021-11051-5>
59. Cowood TJ, Hunt PJ, O'Shea D, et al. Recommended evaluation of adrenal incidentalomas is costly, has high false-positive rates and confers a risk of fatal cancer that is similar to the risk of the adrenal lesion becoming malignant; time for a rethink? *Eur J Endocrinol* 2009;161:513-27. <https://doi.org/10.1530/EJE-09-0234>
60. Angeli A, Osella G, Ali A, et al. Adrenal incidentaloma: An overview of clinical and epidemiological data from the National Italian Study Group. *Horm Res* 1997;47:279. <https://doi.org/10.1159/000185477>
61. Tezzolo M, Ali A, Osella G, et al. Prevalence of adrenal carcinoma among incidentally discovered adrenal masses. A retrospective study from 1989-1994. *Arch Surg* 1997;132:914-9. <https://doi.org/10.1001/archsurg.1997.01430320116020>
62. Corwin MT, Navarro SM, Malik DG, et al. Differences in growth rate on CT of adrenal adenomas and malignant adrenal nodules. *Am J Roentgenol* 2019;213:632-6. <https://doi.org/10.2214/AJR.19.21342>
63. Eisenhauer EA, Therasse P, Bogaerts J, et al. New response evaluation criteria in solid tumors: Revised RECIST guideline (version 1.1). *Eur J Cancer* 2009;45:228-47. <https://doi.org/10.1016/j.ejca.2008.10.026>
64. Jaresch S, Kornely E, Kley HK, et al. Adrenal incidentaloma and patients with homozygous or heterozygous congenital adrenal hyperplasia. *J Clin Endocrinol Metab* 1992;74:685-89. <https://doi.org/10.1210/jcem.74.3.1311000>
65. Del Monte P, Bernasconi D, Bertolazzi L, et al. Increased 17 alpha-hydroxyprogesterone response to ACTH in silent adrenal adenoma: Cause or effect? *Clin Endocrinol* 1995;42:273-7. <https://doi.org/10.1111/j.1365-2265.1995.tb01875.x>
66. Bovio S, Cataldi A, Reimondo G, et al. Prevalence of adrenal incidentaloma in a contemporary computerized tomography series. *J Endocrinol Invest* 2006;29:298-302. <https://doi.org/10.1007/BF03344099>
67. Hammarstedt L, Muth A, Wangberg B, et al. Adrenal lesion frequency: A prospective, cross-sectional CT study in a defined region, including systematic re-evaluation. *Acta Radiologica* 2010;51:1149-56. <https://doi.org/10.3109/02841851.2010.516016>
68. Davenport C, Liew A, Doherty B, et al. The prevalence of adrenal incidentaloma in routine clinical practice. *Endocrine* 2011;40:80-3. <https://doi.org/10.1007/s12020-011-9445-6>
69. Bancos I, Tamhane S, Shah M, et al. The diagnostic performance of adrenal biopsy: A systematic review and meta-analysis. *Eur J Endocrinol* 2016;175:R60-85. <https://doi.org/10.1530/EJE-16-0297>
70. Mackie GC, Shulkin BL, Ribeiro RC, et al. Use of [18F] fluorodeoxyglucose positron emission tomography in evaluating locally recurrent and metastatic adrenocortical carcinoma. *J Clin Endocrinol Metab* 2006;91:2665-71. <https://doi.org/10.1210/jc.2005-2612>
71. Groussin L, Bonardel G, Silveira S, et al. ¹⁸F-Fluorodeoxyglucose positron emission tomography for the diagnosis of adrenocortical tumors: A prospective study in 77 operated patients. *J Clin Endocrinol Metab* 2009;94:1713-22. <https://doi.org/10.1210/jc.2008-2302>
72. Deandreis D, Leblouex S, Caramella C, et al. FDG-PET in the management of patients with adrenal masses and adrenocortical carcinoma. *Hormones Cancer* 2011;2:354-62. <https://doi.org/10.1007/s12672-011-0091-5>
73. Becherer A, Vierhapper H, Potzi C, et al. FDG-PET in adrenocortical carcinoma. *Cancer Biother Radiopharm* 2001;16:289-95. <https://doi.org/10.1089/108497801753131363>
74. Canter D, Simhan J, Wu KN, et al. Intensely positron emission tomography-avid benign adrenal adenoma. *Urology* 2011;78:1307-8. <https://doi.org/10.1016/j.urology.2011.01.049>
75. Boland GW, Dwamena BA, Jagtiani Sangwaiya M, et al. Characterization of adrenal masses by using FDG-PET: A systematic review and meta-analysis of diagnostic test performance. *Radiology* 2011;259:117-26. <https://doi.org/10.1148/radiol.11100569>
76. Madala A, Daugherty M, Bratslavsky G. Partial adrenalectomy — why should it be considered? *Urol Pract* 2015;2:359-66. <https://doi.org/10.1016/j.urp.2015.03.006>
77. Bancos I, Taylor AE, Chortis V, et al. Urine steroid metabolomics for the differential diagnosis of adrenal incidentalomas in the EURINE-ACT study: A prospective test validation study. *Lancet Diabetes Endocrinol* 2020;8:773-81. [https://doi.org/10.1016/S2213-8587\(20\)30218-7](https://doi.org/10.1016/S2213-8587(20)30218-7)

CORRESPONDENCE: Dr. Neal Rowe, Division of Urology, University of Ottawa, Ottawa, ON, Canada; nrowe@toh.ca