

# The clinicopathological features and prognosis of multifocal high-grade gliomas in adults with *H3F3A* mutation

Yongrui Zhao, MM, Yidong Chen, MD, Leiming Wang, MD, Ying Gao, MM, Jiankun Xu, MD.

## ABSTRACT

**الأهداف:** لاستكشاف السمات الإكلينيكية المرضية والتشخيص للأورام الدبقية عالية الدرجة متعدد الأشكال (M-HGGs) مع طفرة *H3F3A* في البالغين.

**المنهجية:** أجريت مراجعة 4 مرضى بالغين مصابين بـ M-HGGs متحولة *H3F3A* وتلقوا العلاج في مؤسستنا خلال الفترة من أغسطس 2020م إلى ديسمبر 2021م، بما في ذلك البيانات السريرية المرضية والإشعاعية. استخدمنا سلسلة من 16 مريضاً بالغاً مصاباً بـ M-HGGs بدون طفرة *H3F3A* كمجموعة مقارنة. تمت مقارنة البقاء على قيد الحياة دون تقدم المرض (PFS) والبقاء الكلي (OS) بين المجموعات باستخدام طريقة كابلن ميرير.

**النتائج:** كان جميع المرضى من النوع الشديد IDH والنوع الشديد TERT، وكان التعبير P53 مفرطاً. مريض مصاب بطفرة *H3 G34R* وواحد من كل 3 مرضى مصابين بطفرة *H3 K27 M* كان لديهم مثيلة ميثيل MGMT. وجدنا آفات مع طفرة *H3 G34R* في نصف المخ الأيسر. كانت الآفات مع تعديلات *H3 K27* بشكل رئيسي في هيكل خط الوسط، ويمكن أيضاً أن يكون نصف المخ الأيسر مشترك. خضع مريض واحد لعملية استئصال جزئي (STR)، وخضع 3 مرضى للخزعة. تلقى جميع المرضى العلاج الإشعاعي، وكان متوسط PFS والبقاء الكلي 9.5 شهراً و 14.5 شهراً على التوالي. كانت النتائج السريرية مماثلة لتلك الخاصة بمرضى M-HGGs غير المتحولين من *H3F3A* (كان متوسط PFS و OS 7.0 أشهر و 18.0 شهراً، على التوالي).

**الخلاصة:** لقد وصفنا السمات والنتائج السريرية المرضية لعدد 4 مرضى بالغين من M-HGGs مصابين بطفرة *H3F3A*، ووجدنا أن هذه الطفرة لا يبدو أن لها نتائج سلبية مع إعطاء العلاجات الحالية.

**Objectives:** To explore the clinicopathological features and prognosis of multifocal high-grade gliomas (M-HGGs) with *H3F3A* mutation in adults.

**Methods:** Four adult patients with *H3F3A*-mutant M-HGGs who were treated at our institution from August 2020 to December 2021 were reviewed,

including clinical, pathological and radiologic data. A series of 16 adult patients with M-HGGs without *H3F3A* mutation was used as a comparative group. Progression-free survival (PFS) and overall survival (OS) were compared between the groups using the Kaplan–Meier method.

**Results:** All patients were IDH wild-type and TERT wild-type, and P53 was overexpressed. A patient with the *H3 G34R* mutation and 1 of 3 patients with the *H3 K27 M* mutation had MGMT promoter methylation. The lesions with the *H3 G34R* mutation were located in the cerebral hemisphere; the lesions with *H3 K27* alterations were mainly in the midline structure, and the cerebral hemisphere could also be involved. One patient underwent subtotal resection (STR), and 3 patients underwent biopsy. All patients received radiotherapy, and the median PFS and OS were 9.5 months and 14.5 months, respectively. The clinical outcomes were similar to those of non-*H3F3A*-mutated M-HGGs patients (median PFS and OS were 7.0 months and 18.0 months, respectively).

**Conclusion:** We describe the clinicopathological features and outcomes of 4 adult M-HGGs patients with *H3F3A* mutation, and found this mutation doesn't appear to have a negative outcome with the administration of current therapies.

*Neurosciences* 2023; Vol. 28 (1): 42-47  
doi: 10.17712/nsj.2023.1.20220080

From the Department of Radiation Oncology (Zhao, Chen, Gao, Xu), Department of Pathology (Wang), Xuanwu Hospital, Capital Medical University, Beijing, China.

Received 8th July 2022. Accepted 23th November 2022.

Address correspondence and reprint request to: Dr. Jiankun Xu, Department of Radiation Oncology, Xuanwu Hospital, Capital Medical University, Beijing, China. E-mail: xjk\_7563@163.com  
ORCID ID: <https://orcid.org/0000-0003-2447-6348>

In recent years, the mutations of a regulatory histone *H3F3A*, including *H3 K27 M* and *H3 G34R/V* mutations, have been found to be an important genetic driver of high-grade glioma, especially in children and

adolescents.<sup>1-2</sup> The biological behavior of high-grade glioma with *H3F3A* mutation often shows a diffuse infiltrative growth pattern. Previous reports revealed that *H3 K27 M*-mutant glioma commonly occurs in the midline structure,<sup>3</sup> while *H3 G34*-mutant glioma is predominantly found in the supratentorial nonmidline structure.<sup>4</sup> The mutation rate of *H3 G34* is lower than that of *H3 K27 M*, and they are mutually exclusive, and exclusive from IDH-mutant cases.<sup>4-5</sup> According to the 2021 World Health Organization (WHO) classification of CNS tumors, pediatric-type diffuse high-grade gliomas are named “Diffuse midline glioma, *H3 K27*-altered” and “Diffuse hemispheric glioma, *H3 G34*-mutant”.<sup>6</sup> However, the *H3F3A* mutation in adult-type diffuse gliomas is still not fully understood.

Multifocal high-grade gliomas (M-HGGs) are a subtype of malignant glioma with a worse prognosis than solitary high-grade glioma.<sup>7-8</sup> M-HGGs with *H3F3A* mutations are rare. This study retrospectively reviewed the clinicopathological features and outcomes of M-HGGs with *H3F3A* mutation in adults to gain insight into the understanding of high-grade gliomas with *H3F3A* mutation.

**Methods.** We retrospectively analyzed 4 adult patients with *H3F3A*-mutant M-HGGs who underwent radiotherapy at Xuanwu Hospital, Capital Medical University from August 2020 to December 2021. A series of 16 adult patients with M-HGGs without *H3F3A* mutation was used as a comparative group. Cases with solitary high-grade glioma were excluded. The patients underwent at least 6 months of postoperative follow-up. The cases were classified according to the 2016 WHO classification of CNS tumors.<sup>9</sup> The M-HGGs are defined as 2 or more lesions on magnetic resonance imaging (MRI). The clinical, radiologic and pathological data were reviewed. This study was reviewed and approved by the Ethics Committee of Xuanwu Hospital, Capital Medical University.

The extent of resection was classified as gross total resection (GTR), subtotal resection (STR), and biopsy. Postoperative radiotherapy was performed with the volume-modulated arc therapy (VMAT) technique based on the recommendations for high-grade glioma

target delineation in the 2020 version of the National Comprehensive Cancer Network (NCCN) guidelines. Chemotherapy was given using the Stupp protocol.

Histological pathology is the result of hematoxylin and eosin (HE) staining and immunohistochemical staining, and antibodies are routinely detected, including IDH1, P53, Ki-67, and H3 K27 M. H3 G34R/V was partially detected. The molecular data included IDH1/2, TERT, MGMT promoter methylation, and partial H3 G34 or H3 K27 detection. Mutational analysis of IDH1/2, H3 G34 and H3 K27 was performed using polymerase chain reaction and Sanger sequencing. MGMT promoter methylation was assessed by pyrosequencing.

Progression-free survival (PFS) was defined as the time from surgery to progression. Overall survival (OS) was defined as the time from surgery to death from any cause or to the date of the last visit. Follow-up was mainly performed through outpatient and telephone visits. Clinical characteristics were described using descriptive statistics, while survival analysis comprised the median PFS estimation, the median OS estimation, the Kaplan–Meier curve, and the log-rank test using GraphPad Prism.<sup>9</sup> A *p*-value <0.05 was considered statistically significant.

**Results. Patient characteristics.** The median age of adult patients with the *H3F3A*-mutated M-HGGs was 36 years old (range, 27-65 years), including 2 males and 2 females (Table 1). Headache was the most common clinical symptom, without seizure. All patients underwent surgery, including 1 with STR and 3 with biopsy. Two patients received concomitant radiochemotherapy, another 2 patients received radiotherapy alone, and one patient received tumor-treating fields after radiotherapy.

**Imaging characteristics.** The imaging characteristics of *H3F3A*-mutant M-HGGs are shown in Figure 1-4.<sup>1-4</sup> According to the MRI results, three patients had 2 lesions, and the lesions were found on the right side of the brain with enhancement. In another patient, 3 lesions in the bilateral brain showed no enhancement. The location of the lesions in one patient was in the midline structure, that of another patient was in the cerebral hemisphere, and both the cerebral hemisphere and midline structure were involved in another 2 patients.

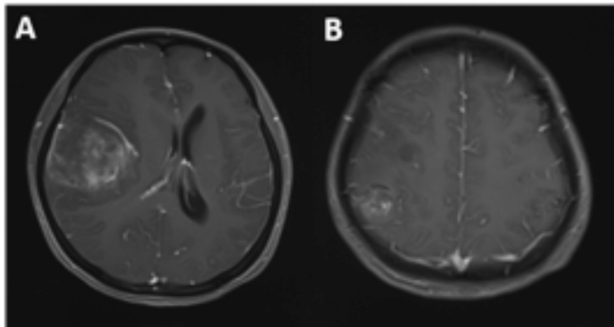
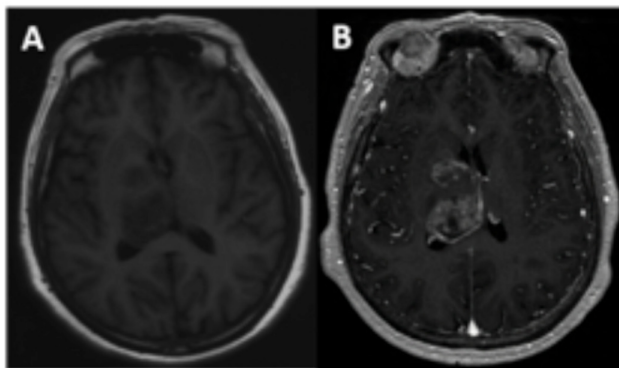
**Pathological features.** Histopathological immunohistochemistry showed that P53 was overexpressed in 4 patients, and IDH1 was positive in one patient but negative in next-generation sequencing (NGS). The H3.3 histone test showed that one patient

**Disclosure.** Authors have no conflict of interests, and the work was not supported or funded by any drug company.

**Table 1** - Characteristics of 4 patients with *H3F3A*-mutant M-HGGs.

No.	Age (y)	Sex	Histo-diagnosis	No. of lesions	Location	H3F3A	IDH	TERT	MGMT	Treatment	PFS (mo.)	OS (mo.)
1	27	F	GBM	2	FL+TL+PL, R	H3G34R	wt	wt	met	STR+RT(66Gy)+TMZ	13	16
2	65	F	HGG	2	BG+TH, R	H3K27 M	wt	wt	met	Biopsy+RT(60Gy)+TMZ	11	14
3	37	M	AA	3	FL+TH, B	H3K27 M	wt	wt	unmet	Biopsy+RT(54Gy)	8	15
4	35	M	HGG	2	TL+BG+TH, R	H3K27 M	wt	wt	unmet	Biopsy+RT(60Gy)+TTF	6	7

M - male; F - female; GBM - glioblastoma; HGG - high-grade glioma; AA - anaplastic astrocytoma; FL - frontal lobe; PL - parietal lobe; TH - thalamus; TL - temporal lobe; BG - basal ganglia; R - right; L - left; B - bilateral; wt - wild-type; met - methylated; unmet - unmethylated; STR - subtotal resection; RT - radiotherapy; TMZ - temozolomide; TTF - tumor-treating fields; mo - month(s)

**Figure 1** - Radiographic features of case 1. Contrast-enhanced MRI shows 2 lesions in the right frontal-temporal (A) and right parietal lobes (B).**Figure 2** - Radiographic features of case 2. T1-weighted image shows 2 lesions located in the right basal ganglia and right thalamus (A), with obvious inhomogeneous enhancement on enhanced scans (B).

was *H3 G34R* positive, and 3 patients were *H3 K27 M* positive. The Ki-67 index was between 15% and 50% in *H3 K27*-altered patients, and the Ki-67 proliferation rate was up to 80% in *H3 G34*-mutant patients.

The molecular data are shown in Table 1. None of the 4 patients had *IDH* mutations or *TERT* mutations. Two patients had *MGMT* promoter methylation, including 1 patient with the *H3 G34R* mutation and 1

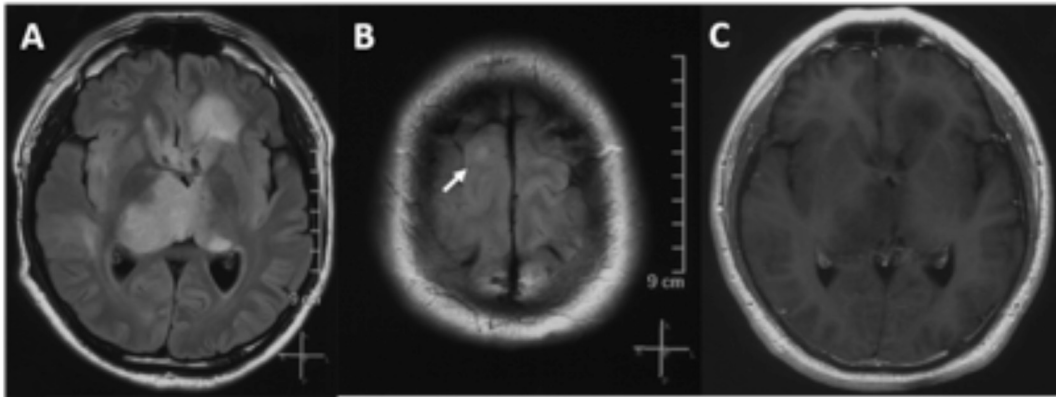
patient with the *H3 K27 M* mutation. The mutational analysis findings of histone H3.3 were consistent with the immunohistochemical results.

**Follow-up and outcomes.** All patients passed away at the last follow-up. Two patients with *H3 K27* alterations had local recurrence; other 2 patients (one with *H3 K27* alteration, one with *H3 G34R* mutation) experienced distant brain progression. The median PFS and OS were 9.5 months and 14.5 months, respectively.

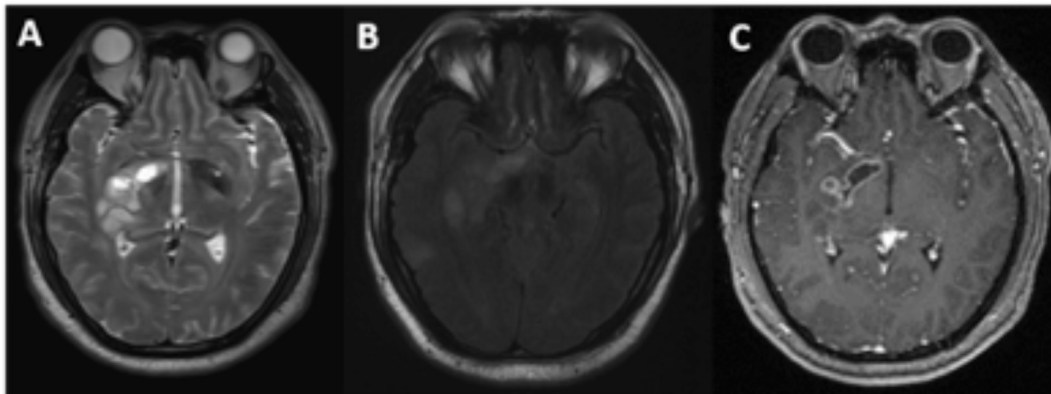
The clinical outcomes of patients with *H3F3A*-mutant M-HGGs were compared to those of 16 M-HGGs patients without *H3F3A* mutations treated at the same time. In the control group, 1 patient had an *IDH1* mutation, and 4 of 16 patients had *MGMT* promoter methylation. The median PFS and OS of patients without *H3F3A* mutation were 7.0 months and 18.0 months, respectively. There was no significant difference between the 2 groups (Figure 5).

**Discussion.** To date, an increasing number of *H3F3A*-mutant high-grade gliomas have been reported, yet *M-HGGs* with *H3F3A* mutations are rare. It is not clear whether multifocal gliomas represent a unique biological variation or whether multifocal gliomas are an inevitable process in the natural history of high-grade glioma.<sup>10</sup> Previous studies have shown that the incidence of M-HGGs is approximately 0.5%-35%,<sup>11</sup> but the incidence of M-HGGs with *H3F3A* mutation is unknown. In this study, we describe the clinicopathological characteristics and outcomes of 4 adult M-HGGs patients with *H3F3A* mutation, including one with *H3 G34R* mutation and 3 with *H3 K27* alteration.

High-grade glioma with the histone *H3* mutation tends to occur in children but also in adolescents or young patients, most of whom are younger than 30 years.<sup>12-13</sup> The prognosis of *H3F3A*-mutant glioma has been reported with varying results in children and adults.<sup>3-4,14-16</sup> Vuong et al. showed that the prognosis of *H3 K27 M* mutation is influenced by patient age and



**Figure 3** - Radiographic features of case 3. The lesion was unevenly enhanced on contrast-enhanced MRI. The FLAIR image shows multiple lesions in the left frontal lobe, bilateral thalamus (A), and right frontal lobe (B), and the lesions are not enhanced (C).



**Figure 4** - Radiographic features of case 4. The T2-weighted image shows that the lesion was located in the right basal ganglia, involving the thalamus (A), and the FLAIR image shows that another lesion was located in the right temporal lobe (B). Contrast-enhanced MRI shows that the lesion was enhanced in the right basal ganglia (C).

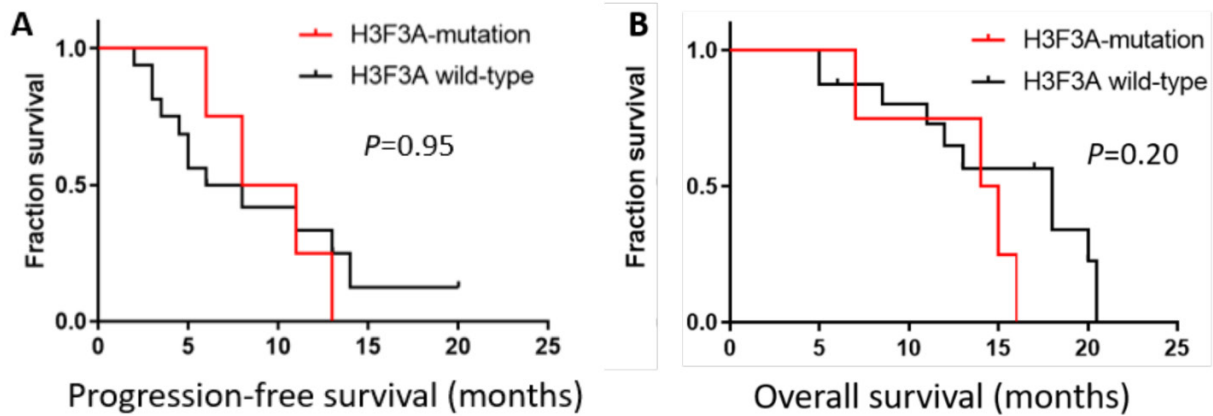
that the pediatric group has a favorable prognosis.<sup>12</sup> Tumors with the *H3 G34* mutation were consistently located within the cerebral hemisphere and frequently invaded the parietal and temporal lobes.<sup>4</sup> Interestingly, *H3 K27 M*-mutant diffuse midline gliomas in adults mainly involved the thalamus and spinal cord.<sup>3</sup> However, in pediatric patients, the brainstem is the most common location of tumors harboring the *H3 K27 M* mutation.<sup>13</sup> In the present case series, the radiological characteristics of adult *H3F3A*-mutant gliomas are consistent with those reported in previous studies. The lesions of *H3 G34R*-mutant patients were located in the frontal, parietal and temporal lobes. Three patients with *H3 K27* alterations had lesions involving the thalamus, and 2 patients had lesions affecting the basal ganglia.

As previously reported, the *H3F3A* mutation was exclusive to IDH mutations and TERT promoter mutations.<sup>5,17</sup> *H3 G34*-mutant gliomas were associated

with MGMT promoter methylation in most patients, which is also one of the reasons for its better prognosis.<sup>15</sup> Our data showed that 4 patients were IDH wild-type and TERT wild-type; P53 was overexpressed in all patients; and the patient with the *H3 G34R* mutation and 1 of 3 patients with the *H3 K27 M* mutation had MGMT promoter methylation. The PFS was better than that in patients with MGMT promoter unmethylation.

Although case reports of M-HGGs with *H3F3A* mutation have been published, few studies have reported the outcome. Lim et al<sup>18</sup> and Wang Q et al<sup>19</sup> reported one patient with multifocal *H3 K27 M*-mutant diffuse midline glioma respectively, but the final survival outcome was not obtained.<sup>18-19</sup> Yekula et al<sup>20</sup> reported one adult *H3 K27 M*-mutant diffuse midline glioma with a gliomatosis cerebri growth pattern, and the OS was 8 months. Schulte et al reported *H3 K27 M*-mutant multifocal gliomas in 2 of 60 adult patients





**Figure 5** - Kaplan-Meier survival curve. Kaplan-Meier survival curves and log-rank tests for PFS (A) and OS (B). The median PFS and OS were 9.5 months and 14.5 months, respectively, in M-HGGs patients with *H3F3A* mutations. For non-*H3F3A*-mutated M-HGGs patients, the median PFS and OS were 7.0 months and 18.0 months, respectively. Comparisons between the 2 groups using the log-rank test indicated no significant difference.

with diffuse midline glioma. The median PFS was 9.6 months and the OS was 27.6 months in this adult cohort.<sup>21</sup> Vettermann et al<sup>22</sup> reported 2 patients with *H3 G34*-mutant multifocal gliomas without an outcome or molecular profile.<sup>22</sup> In our series, the median PFS and OS of all 4 patients were 9.5 months and 14.5 months, respectively. The clinical outcomes were similar to those of non-*H3F3A*-mutated M-HGGs patients.

At present, there is no standard treatment for M-HGGs, and the commonly used treatment modalities include surgery, radiotherapy, and chemotherapy. There were 3 *H3 K27*-altered patients with biopsy and one *H3 G34*-mutant patient with STR; all 4 patients received radiotherapy, and 2 patients received temozolomide during this study. The recurrence pattern of M-HGGs in adults with *H3F3A* mutation was similar to that of high-grade glioma: 2 patients had local recurrence, and 2 patients had distant brain lesions with diffuse leptomeningeal enhancement. There have also been reports of high-grade glioma with the *H3F3A* mutation with extraneural metastasis.<sup>23-25</sup> The most common sites of distant metastasis are the osseous and peritoneal regions. Mohiuddin et al. reported three cases of high-grade glioma with *H3F3A* mutation and diffuse extraneural dissemination in young adulthood (age range: 10-25 years).<sup>25</sup> However, extraneural metastasis in adults with *H3F3A*-mutant glioma has not been reported. The patient with the *H3 G34R* mutation in our study experienced gastrointestinal bleeding

after recurrence of the disease, but an abdominal computed tomography (CT) scan showed no obvious abnormalities, and the patient died less than a month after the onset of intestinal bleeding.

The main limitation of this study is the small number of patients due to the rarity of M-HGGs with *H3F3A* mutations. Moreover, the patients did not receive salvage treatment, such as reirradiation or systemic treatment, after disease progression because of coronavirus disease 2019 pandemic and personal reasons. This may affected the overall prognosis of the patients to some extent, and the patients died soon after recurrence.

In Conclusion, The *H3F3A*-mutant glioma mainly affects the pediatric population but can also occur in adults. In this study, we analyzed a case series of M-HGGs with *H3F3A* mutation in adults, including clinical, radiological, pathology, and outcome data. This disease entity may rarely be present in the clinic and has a complicated, multifactorial etiology that has not yet been fully described. Even so, current treatments may lead to a satisfactory prognosis. More clinical studies are needed to further investigate the clinicopathological characteristics and prognosis of *H3F3A*-mutant M-HGGs in adults.

**Acknowledgment.** We acknowledge the work of our colleagues at the Radiology Department in offering the original images and data related to this article. We acknowledge the neurosurgeons for their special contributions to these cases.

## References

1. Wu G, Broniscer A, McEachron TA, Lu C, Paugh BS, Becksfors J, et al. Somatic histone H3 alterations in pediatric diffuse intrinsic pontine gliomas and non-brainstem glioblastomas. *Nat Genet* 2012; 44: 251-253.
2. Roux A, Pallud J, Saffroy R, Edjlali-Goujon M, Debily MA, Boddaert N, et al. High-grade gliomas in adolescents and young adults highlight histomolecular differences from their adult and pediatric counterparts. *Neuro Oncol* 2020; 22: 1190-1202.
3. Meyronet D, Esteban-Mader M, Bonnet C, Joly MO, Uro-Coste E, Amiel-Benouaich A, et al. Characteristics of H3 K27M-mutant gliomas in adults. *Neuro Oncol* 2017; 19: 1127-1134.
4. Picart T, Barrिताult M, Poncet D, Berner LP, Izquierdo C, Tabouret E, et al. Characteristics of diffuse hemispheric gliomas, H3 G34-mutant in adults. *Neurooncol Adv* 2021; 3: 1-12.
5. Sturm D, Witt H, Hovestadt V, Khuong-Quang DA, Jones DT, Konermann C, et al. Hotspot mutations in H3F3A and IDH1 define distinct epigenetic and biological subgroups of glioblastoma. *Cancer Cell* 2012; 22: 425-437.
6. Louis DN, Perry A, Wesseling P, Brat DJ, Cree IA, Figarella-Branger D, et al. The 2021 WHO Classification of Tumors of the Central Nervous System: a summary. *Neuro Oncol* 2021; 23: 1231-1251.
7. Haque W, Thong Y, Verma V, Rostomily R, Brian Butler E, Teh BS. Patterns of management and outcomes of unifocal versus multifocal glioblastoma. *J Clin Neurosci* 2020; 74: 155-159.
8. Di Carlo DT, Cagnazzo F, Benedetto N, Morganti R, Perrini P. Multiple high-grade gliomas: epidemiology, management, and outcome. A systematic review and meta-analysis. *Neurosurg Rev* 2019; 42: 263-275.
9. Louis DN, Perry A, Reifenberger G, von Deimling A, Figarella-Branger D, Cavenee WK, et al. The 2016 World Health Organization classification of tumors of the central nervous system: a summary. *Acta Neuropathol. (Berl.)* 2016; 131: 803-820.
10. Paulsson AK, Holmes JA, Peiffer AM, Miller LD, Liu W, Xu J, et al. Comparison of clinical outcomes and genomic characteristics of single focus and multifocal glioblastoma. *J Neurooncol* 2014; 119: 429-435.
11. Thomas RP, Xu LW, Lober RM, Li G, Nagpal S. The incidence and significance of multiple lesions in glioblastoma. *J Neurooncol* 2013; 112: 91-97.
12. Vuong HG, Ngo TNM, Le HT, et al. The prognostic significance of HIST1H3B/C and H3F3A K27M mutations in diffuse midline gliomas is influenced by patient age. *J Neurooncol* 2022; 158: 405-412.
13. López-Pérez CA, Franco-Mojica X, Villanueva-Gaona R, Díaz-Alba A, Rodríguez-Flórido MA, Navarro VG. Adult diffuse midline gliomas H3 K27-altered: review of a redefined entity. *J Neurooncol* 2022; 158: 369-378.
14. Wang L, Shao L, Li H, Yao K, Duan Z, Zhi C, et al. Histone H3.3 G34-mutant Diffuse Gliomas in Adults. *Am J Surg Pathol* 2022; 46: 249-257.
15. Korshunov A, Capper D, Reuss D, Schrimpf D, Ryzhova M, Hovestadt V, et al. Histologically distinct neuroepithelial tumors with histone 3 G34 mutation are molecularly similar and comprise a single nosologic entity. *Acta Neuropathol* 2016; 131: 137-146.
16. Wang L, Li Z, Zhang M, Piao Y, Chen L, Liang H, et al. H3 K27M-mutant diffuse midline gliomas in different anatomical locations. *Hum Pathol* 2018; 78: 89-96.
17. Louis DN, Wesseling P, Aldape K, Brat DJ, Capper D, Cree IA, et al. cIMPACT-NOW update 6: new entity and diagnostic principle recommendations of the cIMPACT-Utrecht meeting on future CNS tumor classification and grading. *Brain Pathol* 2020; 30: 844-856.
18. Lim JX, Leong A, Tan AP, Tan CL, Nga VDW. H3K27M-mutant diffuse midline glioma presenting as synchronous lesions involving pineal and suprasellar region: A case report and literature review. *J Clin Neurosci* 2020; 81: 144-148.
19. Wang Q, Niu W, Pan H. Targeted therapy with anlotinib for a H3K27M mutation diffuse midline glioma patient with PDGFR- $\alpha$  mutation: a case report. *Acta Neurochir (Wien)* 2022; 164: 2063-2066.
20. Yekula A, Gupta M, Coley N, Sang U H. Adult H3K27M-mutant diffuse midline glioma with gliomatosis cerebri growth pattern: Case report and review of the literature. *Int J Surg Case Rep* 2020; 68: 124-128.
21. Schulte JD, Buerki RA, Lapointe S, Molinaro AM, Zhang Y, Villanueva-Meyer JE, et al. Clinical, radiologic, and genetic characteristics of histone H3 K27M-mutant diffuse midline gliomas in adults. *Neurooncol Adv* 2020; 2: 1-10.
22. Vettermann FJ, Felsberg J, Reifenberger G, Hasselblatt M, Forbrig R, Berding G, et al. Characterization of Diffuse Gliomas With Histone H3-G34 Mutation by MRI and Dynamic 18F-FET PET. *Clin Nucl Med* 2018; 43: 895-898.
23. Kay MD, Pariury HE, Perry A, Winegar BA, Kuo PH. Extracranial Metastases From Glioblastoma With Primitive Neuronal Components on FDG PET/CT. *Clin Nucl Med* 2020; 45: e162-e164.
24. Jethanandani A, Gule-Monroe MK, Chen M, Johnson JM. Extraneural Metastases From a High-Grade Glioma (HGG) With an H3F3A G34R Mutation. *Front Oncol* 2019; 9: 373.
25. Mohiuddin S, Maraka S, Usman Baig M, Gupta S, Muzzafar T, Valyi-Nagy T, et al. Case series of diffuse extraneural metastasis in H3F3A mutant high-grade gliomas: Clinical, molecular phenotype and literature review. *J Clin Neurosci* 2021; 89: 405-411.