

## An immunohistological study of secondary Sjögren's syndrome

D. A. ISENBERG,<sup>1</sup> DEBORAH ROWE,<sup>2</sup> A. TOOKMAN,<sup>1</sup> ANN HOPP,<sup>3</sup>  
MERYL GRIFFITHS,<sup>3</sup> ELIZABETH PAICE,<sup>1</sup> JANE STEWART,<sup>4</sup> AND  
P. C. L. BEVERLEY<sup>2</sup>

*From the <sup>1</sup>Whittington Hospital, Highgate Hill, London N19; <sup>2</sup>ICRF Human Tumour Immunology Group, School of Medicine, University College London, Faculty of Clinical Sciences, University Street, London WC1E 6JJ; <sup>3</sup>Department of Morbid Anatomy, School of Medicine, University College London, Faculty of Clinical Sciences, University Street, London WC1E 6JJ; and the <sup>4</sup>Department of Oral Surgery, University College Hospital Dental School, Huntley Street, London WC1*

**SUMMARY** The labial biopsies from 13 patients with secondary Sjögren's syndrome (SS) and four disease controls were examined with a panel of monoclonal antibodies to human leucocyte antigens. Large numbers of T cells were found in most of the biopsies. In seven SS patients the T helper/inducer subset was found to be predominant. Antibody to HLA class I antigens consistently stained leucocytes, but other cell types stained more variably. Although the staining with antibody to HLA class II antigen was often weak, approximately as many cells stained with this antibody as with an antileucocyte antibody, implying that the T cells were activated. Anti-IgD revealed membrane staining of a corona of IgD-positive cells in structures resembling germinal centres. Isolated cells throughout the sections also showed strong cytoplasmic staining with anti-IgD. These results suggest a role for T-cell-dependent local antibody synthesis in the pathogenesis of the disease.

Sjögren's syndrome is a chronic inflammatory autoimmune disorder. It is characterised histologically by infiltration of salivary and lacrimal glands by lymphocytes and plasma cells with destruction of acinar tissue. The principal change seen in major salivary glands is a dense diffuse lymphocytic infiltrate. The acinar loss is accompanied by duct proliferation to form myoepithelial islands.<sup>1</sup> Minor salivary glands may be less involved, and the lymphocytic infiltrate is usually focal, but labial salivary gland biopsy has become established as a safe, simple, and reliable method of confirming the diagnosis.<sup>2</sup>

Primary Sjögren's syndrome (SS) comprises the clinical features of dry eyes and mouth (sicca complex) with histological involvement limited to exocrine glands. It is frequently associated with a variety of extraglandular manifestations.<sup>3</sup> Secondary Sjögren's syndrome describes the association of the 'sicca complex' with another autoimmune rheumatic dis-

ease, most frequently rheumatoid arthritis. Strand and Talal<sup>2</sup> have suggested that a third category with 'aggressive lymphocyte behaviour' should be acknowledged. In this case lymphocyte and plasma cell infiltration of many organs occurs, with prominent lymphadenopathy, which has been termed 'pseudolymphoma'. The chance of developing malignant non-Hodgkin's lymphoma is increased.<sup>4</sup>

Numerous immunological abnormalities have been demonstrated in SS, including polyclonal hypergammaglobulinaemia, the presence of multiple autoantibodies, and various abnormalities in T cell function. The nature and function of the infiltrating cells present in the salivary and lacrimal glands have thus come under scrutiny. Several authors have demonstrated the presence of T and B lymphocytes using conventional heteroantisera.<sup>5</sup> The availability of monoclonal antibodies identifying leucocyte subsets has prompted a further examination of the nature of the infiltrating lymphocytes in labial salivary gland biopsies. An initial study of 5 biopsied patients with primary SS demonstrated the presence of more helper than suppressor T lymphocytes.<sup>6</sup> In this report we present the results of a more extensive

Accepted for publication 24 October 1983.

Correspondence to Dr D. A. Isenberg, School of Medicine, University College London, Faculty of Clinical Sciences, University Street, London WC1E 6JJ.

Table 1 Clinical details of Sjögren's syndrome patients

Patient no.	Age	Sex	Associated diseases	Duration of sicca symptoms	Autoantibodies	Corticosteroid therapy	Other drugs (dose per day)
1	59	F	RA for 23 yr	1 year	Latex +ve ANA +ve 1:160 Sal duct ab +ve	—	Indomethacin 75 mg Diclofenac 150 mg
2	61	F	Hypertthyroidism, arthralgia	2 months	Thyroid micrososome ab +ve	—	Ketoprofen 150 mg
3	71	F	RA for 18 yr	4 years	Latex +ve ANA +ve 1:10	—	Penicillamine 500 mg Fencllofenac 90 mg Methylodopa 500 mg Indomethacin 75 mg Benorylate 20 ml Fenbuten 900 mg
4	68	F	RA for 24 yr	6 months	Latex +ve	—	—
5	57	M	RA for 15 yr, polymyositis for 4 yr	1 month	Latex +ve	Prenisolone 10 mg/day for 4 years	—
6	66	F	Osteogenesis imperfecta	10 years	ANA +ve 1:10	Prednisolone 2 mg/day	—
7	70	F	RA for 40 yr	10 years	Latex +ve, mitochondrial ab +ve	ACTH 0.25 mg IM twice weekly	Benorylate 20 ml
8	48	F	amyloidosis RA for 15 yr	6 months	Latex +ve	—	Sol aspirin 1800 mg Indomethacin 50 mg Indoprofen 600 mg
9	62	M	RA for 15 yr	1 year	Latex +ve, ANA +ve 1:160, sal duct ab +ve	—	—
10	44	F	RA for 1 yr	6 months	Latex +ve	—	Fenoprofen 2.4 g Indomethacin 150 mg
11	54	F	RA for 6 yr	6 months	—	—	Azapropazone 1,200 mg
12	64	F	RA for 20 yr	12 years	ANA +ve 1:10	Prednisolone 5 mg/day for 7 years	Indomethacin 150 mg Gold 50 mg IM every 3 wks
13	69	F	RA for 10 yr	6 months	Latex +ve	—	Benorylate 20 ml

ANA = antinuclear antibody test. IM = intramuscular.

immunohistological study of 13 patients with secondary SS using a panel of antibodies to leucocyte differentiation antigens and HLA class I and II.

### Patients, materials, and methods

The clinical details of the 13 patients with confirmed SS are indicated in Table 1. All these patients met each of the following criteria for the diagnosis: (a) four or more of the symptoms of Sjögren's syndrome<sup>7</sup>; (b) a positive Schirmer's test (the filter paper strips, Clement Clarke Int. Ltd, London, being damp to less than 10 mm after challenge with smelling salts for 5 minutes); (c) a positive labial biopsy (graded 3 or 4 according to the criteria of Chisholm and Mason<sup>8</sup>).

Four further patients were also included in the study (Table 2). Each had rheumatoid arthritis and some symptoms of SS, though this was not confirmed on biopsy. Two of the patients (nos. 14, 15) showed obstruction of some ducts with accompanying leucocyte infiltrate, so that the possibility of Sjögren's syndrome could not be excluded. The labial biopsies were performed with the informed consent of the patients concerned. Labial biopsies of normal individuals were not available.

### COLLECTION OF SPECIMENS

Biopsy specimens were snap frozen in isopentane with a liquid nitrogen coolant. Several sections of 6  $\mu$ m thick were cut, air dried, and stored at  $-20^{\circ}\text{C}$  prior to examination.

### ANTISERA

UCHT1 (T28) is an IgG1 mouse monoclonal antibody against the T3 antigen present on mature T lymphocytes and some thymocytes.<sup>9</sup>

DA2 is a monoclonal antibody of IgG1 class with specificity for a non-polymorphic determinant of HLA-Dr.<sup>10</sup>

Anti-HLe-1 (2D1) is an IgG1 mouse monoclonal antibody and identifies a common leucocyte antigen.<sup>11</sup>

2A1 is an IgG1 mouse monoclonal antibody. It recognises a non-polymorphic determinant of human HLA class I antigens.<sup>11</sup>

Leu 2a (Becton Dickinson) is an IgG mouse anti-human monoclonal antibody recognising the suppressor/cytotoxic T cell subset.<sup>12</sup>

UCHT4 (C3) is an IgG2 mouse monoclonal antibody recognising the suppressory/cytotoxic T cell subset.<sup>13</sup>

Leu 3a (Becton Dickinson) is an IgG1 mouse monoclonal antibody recognising the helper/inducer T cell subset.<sup>12</sup>

The anti-IgD mouse monoclonal antibody was a gift of Dr D. Mason.

### PEROXIDASE-CONJUGATED RABBIT

#### ANTIMOUSE IMMUNOGLOBULIN

Antiserum was purchased from Dako. It was absorbed by passage through a human immunoglobulin sepharose column and titrated on tonsil sections by means of UCHT1 to ascertain the optimal working concentration.

### STAINING BY INDIRECT IMMUNOPEROXIDASE

Sections were washed for a minute in tris-buffered saline (TBS) at pH 7.6, drained, and incubated in 25  $\mu$ l of the monoclonal first layer for 30 minutes at room temperature. The excess antibody was drained and the sections washed twice in TBS. They were then incubated with 25  $\mu$ l of rabbit antimouse immunoglobulin conjugated to horseradish peroxidase, at a concentration of 1/50 in TBS for 30 minutes at room temperature.

Sections were washed twice in TBS, incubated with 3,3 diaminobenzidine at a concentration of 6 mg in 10 ml. 3  $\mu$ l of hydrogen peroxide was added to this just before adding to the sections. After 7 minutes'

Table 2 Clinical details of control patients

Patient no.	Date of biopsy	Age	Sex	Underlying disease	Schirmer's test	Labial biopsy report
16	11 Aug 1981	69	F	Rheumatoid arthritis (latex test +ve)	Normal	Normal
15	8 Sept 1981	65	F	Rheumatoid arthritis (latex test +ve)	Normal	Sialadenitis
14	8 Sept 1981	55	F	Rheumatoid arthritis (latex test +ve)	Normal	Duct obstruction with two lymphocytic foci
17	22 Sept 1981	62	F	Rheumatoid arthritis	Normal	Normal, with minor focus of duct obstruction

Table 3 Results of monoclonal antibodies in the Sjögren's syndrome patients

Patient no.	2A1	DA2	HLe-1	UCHT1	Leu 3a	UCHT4	IgD
1	+++	+++	+++	++→++++	++	+	0→+
2	++	0→+	++→++	+	+	0→+	0→+
3	+++	+	+	++	++→++++	0→+	0
4	+++	ND	++→++++	++	0→+	+	0→+
5	+++	++→++	++→++	++→++	0→+	0→+	0→+
6	+++	—	—	ND	+	0→+	++→++
7	+++	++	+++	++→++	++	++→++	0→+
8	+++	++→++	+	+	0→+	0→+	0→+
9	+++	++→++++	+++	++	++	0→+	0→+
10	+++	++→++	ND	++→++++	++→++++	++	ND
11	+++	0→+	++→++++	++	—	0→+	+
12	+++	+	+	ND	ND	ND	—
13	+++	++→++++	++→++++	++→++	+	+	++

ND = not done.

incubation the sections were washed in 3 changes of TBS, and then for an hour in running tap water. The sections were counterstained for 12 seconds in Mayer's haematoxylin. Sections were blued in tap water and dehydrated through a series of graded alcohols (50%, 70%, 90%, one minute each, and 100% alcohol, 2 changes of 5 minutes each). They were then cleared in xylene (2 changes for 5 minutes each). Permanent mounts were made in DPX. The results were scored on a semi-quantitative 0→++++ scale according to the numbers of positive cells seen.

**Results**

The Sjögren's patients all showed a considerable

level of leucocyte infiltration as evidenced by their staining with anti-HLe-1 (Table 3, Fig. 1). Of the 4 patients treated with steroids (or ACTH) 2 (nos. 6 and 12) had few infiltrating cells and 2 (nos. 5 and 7) showed a denser infiltration. Staining with UCHT1 relative to anti-HLe-1 indicated that a high proportion of these infiltrating cells were T cells (Fig. 2). Results with the T cell subset antibodies indicated that more cells stained with Leu 3a (helper/inducer T cell subset) than UCHT4 (suppressor/cytotoxic subset) in 7 patients (Figs. 3 and 4). In 3 patients approximately equal numbers of cells were stained with Leu 3a and UCHT4 and in only 2 patients was the ratio reversed. In 3 of the 4 control cases equal or greater staining with UCHT4 than Leu 3a was found.

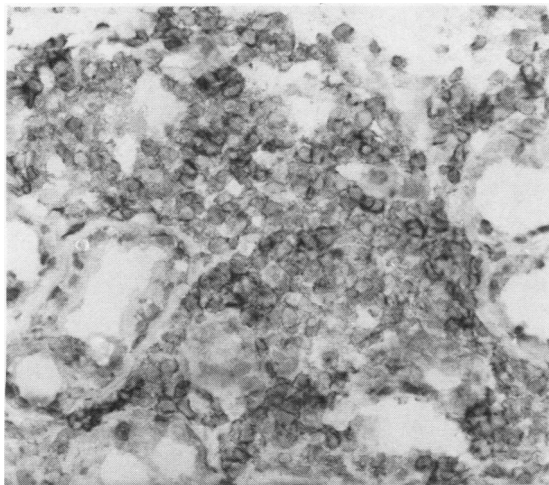


Fig. 1 A leucocyte infiltrate stained with HLe-1. All the infiltrating cells are membrane stained. Patient 7. (Indirect immunoperoxidase, counterstained with haematoxylin, ×220).

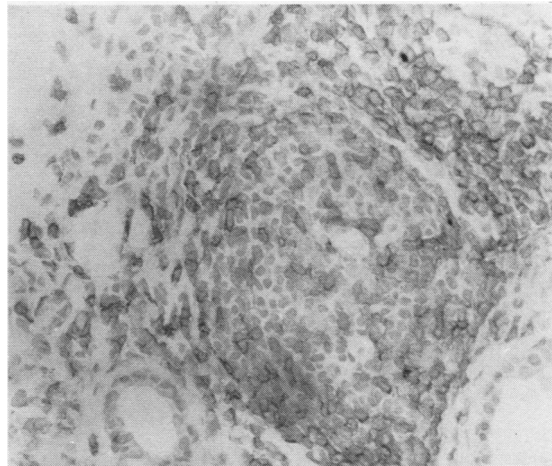


Fig. 2 Leucocyte infiltrate stained with UCHT1. The cells are largely confined to the periphery of the infiltrate, suggesting the formation of a germinal centre. Patient 14. (Indirect immunoperoxidase, counterstained with haematoxylin, ×210).

Table 4 *Results of monoclonal antibodies in the control patients*

<i>Patient no.</i>	<i>2A1</i>	<i>DA2</i>	<i>HLe-1</i>	<i>UCHT1</i>	<i>Leu 3a</i>	<i>UCHT4</i>	<i>IgD</i>
14	+++	++→+++	+++	++	++→+++	+→+++	+→+++
15	+++	+→+++	++	+→+++	+	+	+
16	+++	ND	+	+	0→+	+	0→+
17	++	+	+	0→+	—	0→+	ND

The number of cells shown to have HLA class I antigens was high in biopsy specimens from both controls and patients with Sjögren's syndrome. Leucocytes were invariably strongly positive. Fibrous material was generally negative, though in some cases diffuse staining was seen all over the section. Ducts stained variably but never displayed as much HLA class I antigen as leucocytes. Staining with anti-HLA class II was weak but in several patients (nos. 1, 3, 5, 8, 9, 12, 13, 14) as many cells were positive as with anti-HLe-1.

Two distinct types of labelling with anti IgD were seen, cytoplasmic and membrane. Cytoplasmically labelled cells were distributed singly throughout the sections, often in areas where heavy leucocyte infiltration was not apparent (Fig. 5). In larger infiltrates (+ or greater, patients 6, 11, 13, 14, 15) (Tables 3 and 4) both membrane and cytoplasm stained cells were seen. In two patients (9 and 13) (Table 3), the presence of germinal centres was indicated by a 'corona' of IgD+ cells surrounding larger IgD negative cells (Fig. 6).

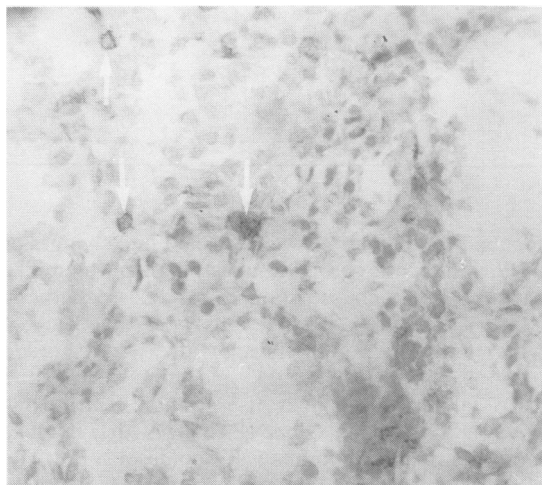


Fig. 4 *Leucocyte infiltrate from the same patient as Fig. 3. Stained with UCHT4. Very few of the infiltrating cells are stained (arrowed) Patient 7. (Indirect immunoperoxidase, counterstained with haematoxylin, ×212).*

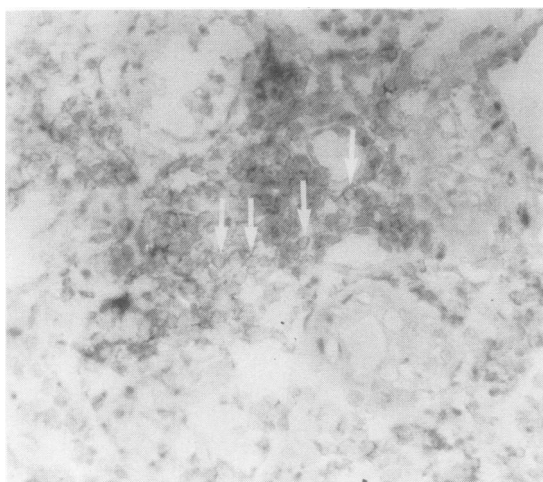


Fig. 3 *Leucocyte infiltrate stained with Leu 3a. Most of the infiltrating cells show weak membrane staining; representative cells are arrowed. Patient 7. (Indirect immunoperoxidase, counterstained with haematoxylin, ×235).*

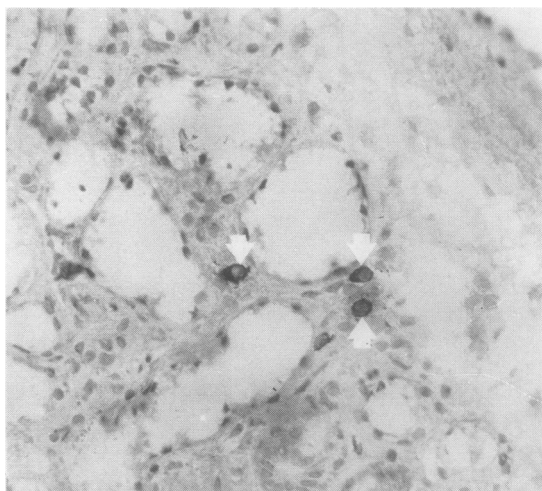


Fig. 5 *Cytoplasmic staining with IgD (arrowed) in a patient with Sjögren's syndrome. Patient 10. (Indirect immunoperoxidase, counterstained with haematoxylin, ×240).*

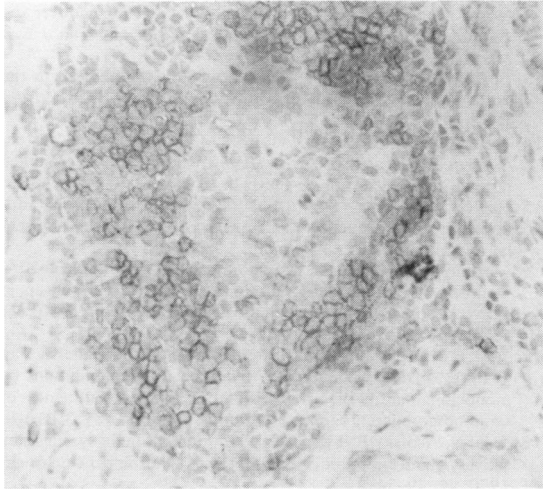


Fig. 6 Leucocyte infiltrate stained for IgD. A 'halo' of membrane stained cells around centrally unstained cells is visible. Patient 13. (Indirect immunoperoxidase, counterstained with haematoxylin,  $\times 245$ ).

In the two control patients with normal labial biopsies (nos. 16, 17) a few infiltrating leucocytes were seen, some of which were T cells. The low numbers of cells made it difficult to see which subset predominated. In the two patients with duct obstruction (nos. 14, 15) more infiltration was seen, and in one (14) more helper/inducer T cells were seen. IgD-positive cells were seen in all the samples tested.

## Discussion

In all the patients showing leucocyte infiltrate as indicated by HLe-1 a considerable proportion of the positive cells were also UCHT1-positive, indicating that they were T lymphocytes. This was seen in both Sjögren's syndrome patients and controls. A previous study<sup>5</sup> using non-monoclonal heterologous antisera indicated that the level of T cells is correlated with the extent of infiltration. In all the cases we examined the proportion of T cells was high.

Our study has indicated a higher proportion of helper/inducer T cells (Th) relative to suppressor/cytotoxic T (Ts) cells in the biopsies from many patients with secondary SS, both treated and untreated. Fox *et al.*,<sup>6</sup> using the OKT monoclonal antibody series, observed an increased Th/Ts ratio ( $>3.0$ ) in five patients with primary SS. It is of interest that in two other autoimmune disorders in which monoclonal antibodies have been used to study Th and Ts cells within affected tissue an increased Th/Ts ratio was also observed. Thus

Janossy *et al.*<sup>14</sup> found 7–10 times as many Th as Ts cells in synovial biopsies from patients with rheumatoid arthritis, and Rowe *et al.*<sup>15</sup> found a Th/Ts ratio of approximately 2 : 1 in muscle biopsies from untreated patients with polymyositis. In contrast Fox *et al.*<sup>6</sup> found a diminished level of Ts cells in the peripheral blood of 15 patients with primary SS. A diminished Ts level in peripheral blood has also been noted in systemic lupus erythematosus<sup>16</sup> and rheumatoid arthritis.<sup>17</sup>

The observed local salivary gland synthesis of IgG and IgM<sup>18</sup> and the presence of rheumatoid factor<sup>19, 20</sup> in the saliva of SS patients strongly suggest local B-lymphocyte hyperactivity.<sup>21</sup> Our demonstration of the predominance of local Th cells would support the contention that these cells stimulate B cells to produce immunoglobulin locally. Further the relative lack of Ts cells argues against a direct cytotoxic T cell mechanism as the cause of salivary gland damage.

We used anti-IgD as a marker for B cells in this study, since staining with this reagent does not give the high background associated with anti-IgG M or anti-light-chain antibodies. Clearly IgD is not a marker for all B lymphocytes, so that we may underestimate the frequency of B cells in the infiltrates, though comparison of serial sections stained with UCHT1 and anti-IgD suggests that most lymphocytes are accounted for. In a few patients structures similar to germinal centres were seen with a corona of IgD-positive cells. More surprisingly, cells with cytoplasmic IgD were seen scattered throughout the sections. It is not possible to say whether these were plasma cells secreting IgD or were cells secreting Ig of another class. Shortage of material precluded attempts to confirm the identity of these cells by staining with other monoclonal antibodies or cytochemical methods.

No obvious differences in the nature of the infiltrate were seen in patients with different underlying conditions. Similarly, treatment did not consistently alter the distribution of cell types. The presence of Th cells strongly suggests that these play an active role in the disease process. Since B lymphocytes are also readily demonstrable, it is likely that local Ig production is also important.

Antibody to HLA class I gave consistent staining of leucocytes, but other cell types stained variably a finding in line with our own and other results.<sup>15, 22</sup> In contrast to our findings in polymyositis there was no clear evidence of increased staining of tissue cells in the vicinity of leucocyte infiltrates. Similarly, staining with antibody to HLA class II gave less clear-cut results in this study of Sjögren's syndrome than in our previous studies of polymyositis.<sup>15, 23</sup> In many cases the staining was weak. However, since in several patients approximately as many cells stained with

anti-HLA class II as with antileucocyte antibody, this implies that the T cells were activated.

#### References

- Morgan W S, Castleman B. A clinicopathologic study of 'Mikulicz's Disease'. *Am J Pathol* 1980; **29**: 471-503.
- Strand V, Talal N. Advances in the diagnosis and concept of Sjögren's syndrome (autoimmune exocrinopathy). *Bull Rheum Dis* 1980; **30**: 1046-52.
- Isenberg D A, Crisp A. Sjögren's syndrome. *Hospital Update* in press.
- De Coteau W E, Katakarr S B, Skinnider L, Hayton R C, Somerville E A. Sjögren's syndrome terminating as a myelo-proliferative disorder. *J Rheumatol* 1975; **2**: 331-5.
- Talal N, Sylvester R, Daniels T, Greenspan J, Williams R. T and B lymphocytes in peripheral blood tissue lesions in Sjögren's syndrome. *J Clin Invest* 1974; **53**: 18-9.
- Fox R I, Covstene S A, Fong S, Robinson C A, Howell F, Vaughan J. Use of monoclonal antibodies to analyse peripheral blood and salivary gland lymphocyte subsets in Sjögren's syndrome. *Arthritis Rheum* 1982; **25**: 419-26.
- Anderson J A, Whaley K, Williamson J, Watson Buchanan W. A statistical aid to the diagnosis of keratoconjunctivitis. *Q J Med* 1972; **41**: 175-89.
- Chisholm D M, Mason D K. Labial salivary gland biopsy in Sjögren's syndrome. *J Clin Pathol* 1970; **21**: 656-60.
- Beverley P C L, Callard R E. Distinctive functional characteristics of human 'T' lymphocytes defined by E rosetting on a monoclonal anti-T cell antibody. *Eur J Immunol* 1981; **11**: 329-34.
- Brodsky F M, Parham P, Barnstaple C J, Crumpton M J, Bodmer W F. Monoclonal antibodies for analysis of the HLA system. *Immunol Rev* 1979; **47**: 536-45.
- Beverley P C L. Production and use of monoclonal antibodies in transplantation immunology. In: Touraine J, Traeger J, Betuel H, Brochier J, Duber J M, Revillard J P, eds. *Proceedings of the XI International Course in Transplantation and Clinical Immunology*. Amsterdam: Excerpta Medica, 1980: 87-94.
- Ledbetter J A, Evans R L, Lipinski M, Cunningham-Rundles C, Corad R A, Herzenberg L A. Evolutionary conservation of surface molecules that distinguish T lymphocyte helper/inducer and cytotoxic/suppressor subpopulations in mouse and man. *J Exp Med* 1981; **153**: 310-27.
- Beverley P C L. Application of monoclonal antibodies to the typing and isolation of lymphoreticular cells. *Proc R Soc Edin* 1982; **81B**: 221-32.
- Janossy G, Panayi G, Duke O, Bofil M, Poulter L W, Goldstein G. Rheumatoid arthritis: a disease of T lymphocyte/macrophage immunoregulation. *Lancet* 1981; **ii**: 839-43.
- Rowe D J, Isenberg D A I, Beverley P C L. Monoclonal antibodies to human leucocyte antigens in polymyositis and muscular dystrophy. *Clin Exp Immunol* 1983; **54**: 327-36.
- Morimoto C, Reinherz E L, Schlossman S F, Schur P, Mills J A, Strinberg A. Alterations in immunoregulatory T cell subsets in active systemic lupus erythematosus. *J Clin Invest* 1980; **66**: 1171-4.
- Veys E M, Hermanns P, Goldstein G, Kung P, Schindler J, Van Wauwe J. Determination of T lymphocyte subpopulations by monoclonal antibodies in rheumatoid arthritis. Influence of immunomodulating agents. *Int J Immunopharm* 1981; **3**: 313-9.
- Talal N, Asofsky R, Lightbody P. Immunoglobulin synthesis by salivary gland lymphoid cells in Sjögren's syndrome. *J Clin Invest* 1970; **49**: 49-54.
- Anderson L G, Cummings N A, Asofsky R, et al. Salivary gland: immunoglobulin and rheumatoid factor synthesis in Sjögren's syndrome. *Am J Med* 1972; **53**: 456-63.
- Dunne J, Carson D, Spiegelberg H, Alspaich M, Vaughan J H. IgA rheumatoid factor in the sera and saliva of patients with rheumatoid arthritis and Sjögren's syndrome (reticulin cell sarcoma, pseudolymphoma, macroglobulinaemia). *Ann Rheum Dis* 1979; **38**: 161-79.
- Manthorpe R, Frost-Larsen K, Isager H, Prause J V. Sjögren's syndrome. A review with emphasis on immunological features. *Allergy* 1981; **36**: 139-53.
- Fleming K I A, McMichael A J, Norton J A, Woods J, McGhee J O. Distribution of HLA class I antigens on normal human tissue and in mammary cancer. *J Clin Pathol* 1971; **34**: 779-98.
- Rowe D J, Isenberg D A, MacDougall J, Beverley P C L. Characterisation of polymyositis infiltrates using monoclonal antibodies to human leucocyte antigens. *Clin Exp Immunol* 1981; **45**: 290-8.