

Correspondence

Cyclosporin for polymyositis

SIR, Cyclosporin has proved its value as an immunosuppressive drug in transplant patients. In addition, it appears to be effective in patients with autoimmune diseases. Recently, some reports have been published on the successful administration of cyclosporin to patients with severe polymyositis and dermatomyositis, in whom conventional treatment with prednisolone, azathioprine, cyclophosphamide, or methotrexate had failed.^{1 2} In these cases cyclosporin was given as last resort. We describe here a case of polymyositis in which prednisolone was effective but only in such high dosage that severe side effects occurred. With the addition of cyclosporin, however, the need for steroids was reduced.

A 55 year old man was admitted to hospital for treatment of his polymyositis. One year earlier, polymyositis group I had been diagnosed on the basis of the clinical findings, characteristic muscle biopsy and electromyographic data, and serum skeletal muscle enzyme abnormalities. At admission he was taking prednisolone 100 mg/day with a good clinical response and a serum creatine kinase value of 39 U/l (normal value <70 U/l). In the previous period attempts to lower this dosage had led to increased muscle weakness and a raised serum creatine kinase level up to 1064 U/l. Since this patient was already suffering from osteoporosis it seemed worthwhile trying cyclosporin as an alternative treatment. An oral dose of 10 mg/kg cyclosporin was given daily with prednisolone, tapering from 100 mg/day to 10 mg/day over a few weeks. Trough levels of cyclosporin (by the radioimmunoassay method) ranged from 350 to 700 ng/ml, measured in whole blood. He has now been on cyclosporin and a low dose of prednisolone for 13 months. He is doing well and there has been no relapse of the polymyositis. The serum creatine kinase level varies from 80 to 120 U/l. There have been no signs of kidney or liver dysfunction during therapy. Clearly, giving cyclosporin made it possible to lower the dosage of prednisolone considerably. Therefore, it may be that cyclosporin will be a useful adjunct in the treatment of polymyositis and that the use of this drug should not be restricted only to patients unresponsive to conventional therapy.

Department of Internal Medicine, S VAN DER MEER
Hospital De Lichtenberg, J W IMHOF
Utrechtseweg 160, J C C BORLEFFS*
3818 ES Amersfoort, The Netherlands

*Present address: Department of Internal Medicine, University Hospital Utrecht, The Netherlands.

References

- 1 Zabel P, Leimenstoll G, Gross WL. Cyclosporin for acute dermatomyositis. *Lancet* 1984; i: 343.
- 2 Bendtzen K, Tvede N, Andersen V, Bendixen G. Cyclosporin for polymyositis. *Lancet* 1984; i: 792-3.

Severe dermatomyositis treated with cyclosporin A

SIR, Dermatomyositis (DM) and polymyositis (PM) are treated with corticosteroids and severe cases with corticosteroids in combination with a cytostatic agent.^{1 2}

Recently one case of DM and two cases of PM treated with cyclosporin A (CyA) were published.^{3 4} In all cases the disease went into remission.

The following report describes a case of DM treated with CyA.

Case report

A 42 year old man who had previously been in good health developed mild pain and slight swelling of many joints. On admission he was treated with bed rest and non-steroidal anti-inflammatory drugs for reactive arthritis, and was discharged after three days in hospital. The only abnormal findings were increased liver enzymes and erythrocyte sedimentation rate 29 mm/1st h.

One week later he was readmitted because of deterioration in his general condition, increasing pain and swelling of joints, and myalgia—especially in the proximal muscles. His temperature had risen to 38.4°C. Examination showed tenderness of the proximal muscles, diffuse swelling of the fingers (sausage fingers), and transient rash on both upper arms and thighs.

Serum levels of muscle enzymes were considerably increased with a maximum creatine kinase concentration of 13 180 U/l (normal <250 U/l) (Fig. 1), and myoglobinuria was present. Myositis was confirmed by muscle biopsy, and the patient was treated with prednisone 75 mg daily. Because of lack of clinical response azathioprine (AZA) 150 mg daily was added one week later.

Despite decreasing levels of muscle enzymes in the serum considerable muscle pain persisted and generalised weakness progressed. The corticosteroid treatment was then tapered off because of steroid psychosis (Fig. 1). His general condition had worsened considerably. Increasing serum muscle enzymes and increasing respiratory insufficiency led to cerebral hypoxia as a result of weakening of the respiratory muscles. He developed pneumonia and became unconscious. At this stage his heart was also affected with tachycardia due to myocarditis, confirmed by increased creatine kinase muscle-brain isoenzyme. The patient was transferred to the university hospital and was placed on a respirator, at which stage he regained consciousness. By this time there was severe general muscle atrophy and weakness. Treatment with corticosteroids and AZA was reintroduced, after which the muscle enzymes decreased again, but the general condition of the patient did not improve. After 10 days AZA was discontinued and treatment with CyA 560 mg daily (corresponding to 7.5 mg/kg daily) was started. After one week's

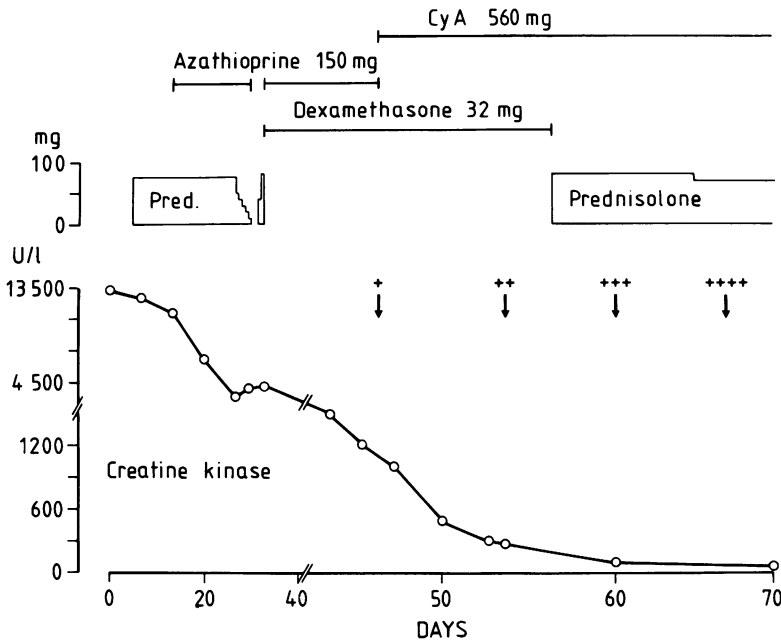


Fig. 1 The course of serum creatine kinase and muscular strength in relation to the treatment of a patient with severe dermatomyositis. Cyclosporin A (CyA); Prednisolone (Pred). + +++++ indicates the muscular strength.

treatment pronounced clinical improvement with increasing muscular strength was noted, and during the following week the respiratory support was withdrawn. There was parallel improvement in the muscular strength, and the muscle enzyme values fell to normal (Fig. 1).

Over the following weeks clinical improvement continued with increasing muscular strength and improved bulk. Prednisolone was reduced from 80 mg to 12.5 mg daily without causing deterioration.

After three months of treatment with CyA and prednisolone the patient was transferred to a rehabilitation hospital, where further improvement continued during the following two months. He was then able to walk alone without support. His mental facilities were completely restored and he was free of pain in muscles and joints. On discharge he was still taking CyA and prednisolone.

Discussion

This case illustrates the classical, clinical course of severe DM.

Initially, prednisolone appeared to have a pronounced effect as both clinical and laboratory parameters deteriorated during the gradual discontinuation of corticosteroids (Fig. 1). It is probable, however, that the subsequent dramatic clinical remission was induced by CyA because of the temporal relationship between the clinical improvement and the CyA treatment. The mechanism of action of CyA is thought to be a blockade of the antigen stimulation induced T lymphocyte response through a blockade of interleukin 1 on the T helper cell surface, resulting in a reduced production of interleukin 2.⁵

The treatment with CyA is not harmless. Severe side

effects have been reported, including lymphomas, spinocellular carcinomas, epileptic seizures, and kidney and liver damage.⁵⁻⁷ There seems to be a close relationship between the serum concentration of CyA and the development of side effects, and the frequency of side effects is low if the serum concentration is kept below 200-400 ng/ml.⁸

In the light of this it seems reasonable to add CyA treatment to the management of severe DM and PM, where traditional treatment is not sufficiently effective.

Department of Rheumatology,
University Hospital,
Odense

LEIF EJSTRUP

References

- 1 Pearson CM. Polymyositis and dermatomyositis. In: McCarty DJ, ed. *Arthritis and allied conditions*. Philadelphia: Lea and Febiger, 1979: 742-61.
- 2 Bohan A, Peter JP, Bowan RL, Pearson CM. A computer-assisted analysis of 153 patients with polymyositis and dermatomyositis. *Medicine (Baltimore)* 1977; **56**: 255-86.
- 3 Zabel P, Leimenstoll G, Gross WL. Cyclosporin for acute dermatomyositis. *Lancet* 1984; **i**: 343.
- 4 Bendtzen K, Tvede N, Andersen V, Bendixen G. Cyclosporin for polymyositis. *Lancet* 1984; **i**: 792-3.
- 5 Bendtzen K. Cyclosporin A: a different immunosuppressive agent. *Ugeskr Laeger* 1983; **145**: 2745-8.
- 6 Thompson JP, Allen R, Morris PJ, Wood R. Skin cancer in renal transplant patients treated with cyclosporin. *Lancet* 1985; **i**: 158-9.
- 7 Veln T, Debusscher L, Stryckmans PA. Cyclosporin associated fatal convulsions. *Lancet* 1985; **i**: 219.
- 8 Irschik E, Tilg H, Niederwieser D, Gastl G, Huber Ch, Margreiter R. Cyclosporin blood levels do correlate with clinical complications. *Lancet* 1984; **ii**: 692-3.