

## Discussion

The epidemiologic and clinical identification of the toxic shock syndrome according to the Centers for Disease Control rests on the following criteria<sup>4</sup>: Fever, rash, hypotension, and desquamation that occurs within two weeks after the disease starts must all be present. Three organ systems must be involved. Diseases that can mimic the syndrome, such as bacterial sepsis as in the case presented here, must be appropriately excluded. Clinical and laboratory manifestations of the syndrome have been recently reviewed.<sup>5</sup>

All four major criteria as well as evidence of multisystem involvement were met in both episodes of the toxic shock syndrome that followed chemotherapy in our patient. Cultures of blood were negative for pathogens, consistent with the diagnosis.

Renal toxicity of cisplatin has been well described,<sup>6</sup> along with metabolic abnormalities that include hypomagnesemia, which is common and may be profound. The hypomagnesemia is dose dependent and correlates with the cumulative cisplatin dose.<sup>7-9</sup> It has been reported to occur in some patients, however, after the first course of chemotherapy even with lower doses of cisplatin at 50 mg per m<sup>2</sup>.<sup>8,9</sup>

Profound hypomagnesemia was documented when symptoms were present during the recurrent toxic shock syndrome episode that followed the second course of chemotherapy. Our patient received cisplatin at 100 mg per m<sup>2</sup>, and, in addition, she had non-insulin-dependent diabetes that may have contributed to the degree of hypomagnesemia. Subclinical hypomagnesemia has been associated with poorly controlled diabetes mellitus and correlated with high levels of fasting blood glucose and an increased level of glycosylated hemoglobin.<sup>10</sup> The patient did not have evidence of renal disease or documented hypomagnesemia before the first course of chemotherapy, and, unfortunately, her serum magnesium level was not measured during the episode that followed the initial administration of cisplatin. The hypomagnesemia documented during the second episode required parenteral replacement.

Many studies indicate a central role for TSST-1 in the pathogenesis of the toxic shock syndrome.<sup>11</sup> The in vitro production of TSST-1, an exotoxin, by *S aureus* has been intensively investigated, in particular in regard to the effect of trace metals. The toxin is produced in excess in hypomagnesemic environments.<sup>1-3</sup>

The role of foreign bodies, particularly tampons, in menstrual toxic shock syndrome is well known.<sup>4,5</sup> The postulated mechanisms of tampons in the pathogenesis include a foreign body effect with alteration of the vaginal microflora<sup>12</sup> and the binding of magnesium by tampon fibers, producing a magnesium-deficient local environment.<sup>3</sup> Epidemic menstrual toxic shock syndrome was linked to the use of tampons composed of polyacrylate rayon that is thought to function as an ion exchange resin.<sup>13</sup>

Recurrent toxic shock syndrome in our patient was temporally related to repeated courses of chemotherapy. The symptoms occurred far too early to invoke immunosuppression by chemotherapy. Moreover, there was no evidence of leukopenia during the episodes of toxic shock.

We propose that hypomagnesemia due to cisplatin chemotherapy created conditions favorable to TSST-1 production by existing *S aureus* in the wound, precipitating the toxic shock syndrome in our patient.

We emphasize the need to monitor serum magnesium levels and to correct hypomagnesemia, if present, during episodes of this syndrome.

## REFERENCES

1. Bergdoll MS: Regulation and control of toxic shock syndrome toxin-1: Overview. *Rev Infect Dis* 1989; 11:S142-143
2. Reeves MW: Effect of trace metals on the synthesis of toxic shock syndrome toxin-1. *Rev Infect Dis* 1989; 11:S145-149
3. Kass EH: Magnesium and the pathogenesis of toxic shock syndrome. *Rev Infect Dis* 1989; 11:S167-172
4. Reingold AL, Hargrett NT, Shands KN, et al: Toxic shock surveillance in the United States, 1980 to 1981. *Ann Intern Med* 1982; 96 (Pt 2):875-880
5. Chesney PJ: Clinical aspects and spectrum of illness of toxic shock syndrome: Overview. *Rev Infect Dis* 1989; 11:S1-7
6. Schilsky RL, Anderson T: Hypomagnesemia and renal magnesium wasting in patients receiving cisplatin. *Ann Intern Med* 1979; 90:929-931
7. Vogelzang NJ, Torkelson JL, Kennedy BJ: Hypomagnesemia, renal dysfunction and Raynaud's phenomenon in patients treated with cisplatin, vinblastine and bleomycin. *Cancer* 1985; 56:2765-2770
8. Lam M, Adelstein DJ: Hypomagnesemia and renal magnesium wasting in patients treated with cisplatin. *Am J Kidney Dis* 1986; 8:164-169
9. Buckley JE, Clark VL, Meyer TJ, Pearlman NW: Hypomagnesemia after cisplatin combination chemotherapy. *Arch Intern Med* 1984; 144:2347-2348
10. Pun KK, Ho PWM: Subclinical hyponatremia, hyperkalemia and hypomagnesemia in patients with poorly controlled diabetes mellitus. *Diabetes Res Clin Pract* 1989; 7:163-167
11. Schlievert PM: Role of toxic shock syndrome toxin-1 in toxic shock syndrome: Overview. *Rev Infect Dis* 1989; 11:S107-109
12. Chow AW, Bartlett KH: Sequential assessment of vaginal microflora in healthy women randomly assigned to tampon or napkin use. *Rev Infect Dis* 1989; 11:S68-73
13. Kass EH: Magnesium, *Staphylococcus aureus* and toxic shock syndrome. *Magnesium* 1988; 7:315-319

## Hepatocellular Carcinoma Coexisting With Hepatic Adenoma: Incidental Discovery After Long-Term Oral Contraceptive Use

JACOB KORULA, MD  
ALBERT YELLIN, MD  
GARY KANEL, MD  
GAIL CAMPOFIORI, MD  
PETER NICHOLS, MD  
Los Angeles, California

THE CAUSAL RELATIONSHIP between oral contraceptive use and hepatic adenoma is well documented,<sup>1</sup> though the evidence for the mechanism of the transformation of adenomas to hepatocellular carcinoma is not conclusively established.<sup>2</sup> Recently Gyorffy and colleagues reported the development of hepatocellular carcinoma in a woman in whom hepatic adenoma was diagnosed 18 months earlier when she presented with abdominal pain.<sup>3</sup> We report a case where a hepatic adenoma with coexistent hepatocellular carcinoma was diagnosed in an asymptomatic woman in whom the hepatic neoplasm was identified by incidental hepatic ultrasonography.

### Report of a Case

The patient, a 40-year-old woman, was referred to the University of Southern California (Los Angeles) Liver Unit

---

(Korula J, Yellin A, Kanel G, Campofiori G, Nichols P: Hepatocellular carcinoma coexisting with hepatic adenoma—Incidental discovery after long-term oral contraceptive use. *West J Med* 1991 Oct; 155:416-418)

---

From the Departments of Medicine (Hepatology) (Drs Korula and Campofiori), Surgery (Dr Yellin), and Pathology (Drs Kanel and Nichols), University of Southern California School of Medicine, and the USC Liver Unit, Rancho Los Amigos Medical Center (Drs Korula and Kanel), Los Angeles, California.

Reprints are not available.

for the management of a hepatic mass initially noted on ultrasonographic examination of the abdomen. She was employed, asymptomatic, and physically active at the time of referral. When she was 19, it is thought that a combination drug, ethynodiol diacetate, 1 mg, and mestranol, 0.1 mg (Ovulen 21), was prescribed for irregular menses, which she continued taking until age 28. She was briefly given a combination of norethindrone, 1 mg, and mestranol, 0.08 mg (Ortho Novum 1/80), for a few months before another combination, ethynodiol diacetate, 1 mg, and ethinyl estradiol, 35  $\mu$ g (Demulen 1/35-21), was prescribed from age 28 to age 34. At that time, endometriosis was diagnosed, the oral contraceptive therapy was discontinued, and a regimen of the progestin, norethindrone acetate (Norlutate), 5 mg daily, was started. She was fairly compliant in continuing to take the prescribed medications without interruption, except perhaps for about six months before starting Norlutate therapy. She has never conceived. In March 1989, a pelvic ultrasonogram done as part of the gynecologic workup was extended to the upper abdomen, at which time a large hepatic mass was identified. She had no risks for hepatitis, history of toxin exposure, known previous liver disease, or family history of

liver disease or neoplasms. Serum liver function test values, a complete blood count, and an  $\alpha$ -fetoprotein level were in the normal range, and serologic tests for hepatitis B—hepatitis B surface antigen, hepatitis B core antibody IgG—were negative; a test for hepatitis C virus antibody was not done.

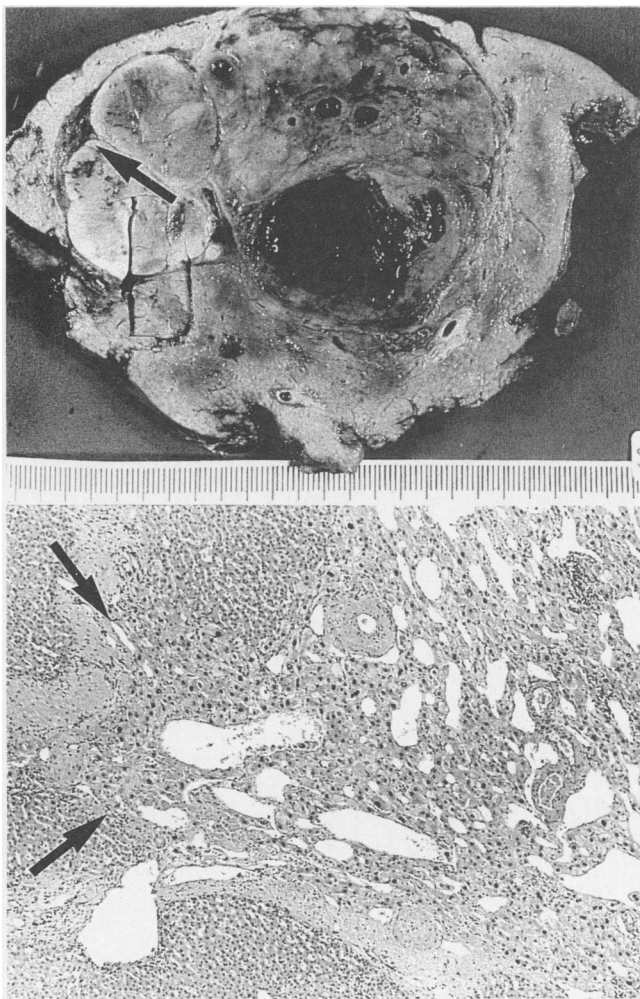
A series of scanning tests ensued: computed tomography confirmed the presence of a 6.5- by 3.5-cm mass in the right lobe of the liver that corresponded with a "cold" defect on a liver scan using technetium Tc 99m sulfur colloid. A selective uptake of gallium in this "cold" defect was observed. Arteriography confirmed that it was a vascular tumor, but it showed neither the typical vascular pattern of an adenoma nor the neovascularity of hepatocellular carcinoma. Because surgical resection is not usually done for focal nodular hyperplasia and because that possibility could not be excluded, biopsies of the hepatic mass were considered helpful in the decision regarding subsequent management. Directed percutaneous needle biopsies using peritoneoscopy confirmed that it was a hepatic adenoma.

Because of the risk of intraperitoneal hemorrhage from an adenoma that remained large despite discontinuing oral contraceptive use, surgical resection was recommended. A right hepatic lobectomy was successfully accomplished and was followed by an uneventful postoperative course. Histologic examination of the resected specimen revealed multiple encapsulated adenomatous nodules (Figure 1, top) and areas of hemorrhage thought to correspond to the sites of the needle biopsies. Microscopic examination of tissue sections from a crescent-shaped zone on the superior margin of the largest nodule (Figure 1, top) showed features of a well-differentiated hepatocellular carcinoma. There was definite invasion of tumor cells beyond thickened peripheral vascular structures, with the resultant location of cells immediately adjacent to a portal tract (Figure 1, bottom). The liver not involved with tumor was normal.

## Discussion

Epidemiologic data have shown a clear association between hepatic adenoma and oral contraceptive use.<sup>4</sup> It is estimated that more than 50 million women in the United States have been or are currently taking oral contraceptives.<sup>5</sup> Despite this widespread use, the incidence of hepatic adenoma is low.<sup>6</sup> Large hepatic adenomas are frequently symptomatic, and about a third initially present with intraperitoneal hemorrhage.<sup>6</sup> Therefore, surgical resection has been advocated to prevent this complication. Small adenomas are usually found incidentally at an operation or during hepatic imaging. Adenomas may regress with the discontinuation of oral contraceptive use.<sup>7</sup>

Although cases of adenoma with coexistent or transformed hepatocellular carcinoma were reported previously, to our knowledge this is the first case reported in an asymptomatic woman who had been taking contraceptives long term. Our case differs from that reported by Gordon and co-workers in which hepatocellular carcinoma developed at the site of contraceptive-induced hepatic adenoma that had regressed when contraceptive use was discontinued.<sup>8</sup> In the case reported by Gyorffy and associates, the outcome was not known.<sup>3</sup> Despite these differences, we think that our case provides further evidence supporting the concept of the transformation of hepatic adenoma to hepatocellular carcinoma. The histologic features of invasion in the resected specimen



**Figure 1.**—**Top.** The photograph of a gross specimen of the resected right lobe of the liver shows the adenoma and areas of hemorrhage from the sites of needle biopsy. **Arrow** shows the focus of hepatocellular carcinoma. **Bottom.** A photomicrograph of the area indicated by the **arrow** in the gross specimen shows features of hepatocellular carcinoma with microscopic invasion into adjacent normal hepatic parenchyma (**arrows**) (hematoxylin and eosin, original magnification  $\times$  56).

in our patient clearly distinguish hepatocellular carcinoma from hepatic adenoma with dysplasia.<sup>9</sup>

Our case also demonstrates the dilemma in making decisions regarding management in this asymptomatic woman. The difficult decision to proceed with hepatic resection was based on the demonstration of adenoma at biopsy, the large size of the lesion despite the discontinuation of oral contraceptive use, and the increased selective uptake of gallium by the tumor, a finding suspicious for malignancy. The early diagnosis and the right hepatic lobectomy maximized the probability of a cure in this young woman.

The role of progestins in the development of hepatocellular carcinoma in our patient is uncertain. Hepatocellular carcinoma has been reported in patients treated with anabolic steroids,<sup>10</sup> and androgens have a chemical structural similarity to progestins.<sup>11</sup> We can only speculate that in our patient, the ingestion of progestins for six years after discontinuing the estrogen-containing medications may have contributed to the transformation to hepatocellular carcinoma.

It is fortuitous that ultrasonography in our patient included the liver and thus identified the lesion. Of great concern is the observation that hepatocellular carcinoma can occur without symptoms, elevated serum  $\alpha$ -fetoprotein levels, or radiologic evidence for malignancy. What is not clear is whether women using oral contraceptives long term need to undergo surveillance ultrasonography. The potential cost-benefits of carrying out such surveillance will be diminished by the identification of many common incidental tumors, such as cavernous hemangiomas, that will necessitate additional scanning tests. Besides, the anxiety associated with the

identification of these hepatic lesions may lead to unwanted interventions, including surgical intervention, with their attendant complications. Because the risk of hepatic adenoma developing in women taking oral contraceptives increases with prolonged use,<sup>12</sup> a pilot study targeting the population at risk may provide guidelines to clarify this issue.

#### REFERENCES

1. Klatskin G: Hepatic tumors: Possible relationship to use of oral contraceptives. *Gastroenterology* 1977; 73:386-394
2. Goodman ZD, Ishak KG: Hepatocellular carcinoma in women: Probable lack of etiologic association with oral contraceptive steroids. *Hepatology* 1982; 2:440-444
3. Gyorfy EJ, Bredfeldt JE, Black WC: Transformation of hepatic cell adenoma to hepatocellular carcinoma due to oral contraceptive use. *Ann Intern Med* 1989; 110:489-490
4. Rooks JB, Ory HW, Ishak KG, et al: Epidemiology of hepatocellular adenoma: The role of oral contraceptives. *JAMA* 1979; 242:644-648
5. Kew MC: Tumors of the liver, chap 45. *In* Zakim D, Boyer TD (Eds): *Hepatology: A Textbook of Liver Disease*, 2nd Edition. Philadelphia, Pa, WB Saunders, 1990, pp 1206-1240
6. Mays ET, Christopherson W: Hepatic tumors induced by sex steroids. *Semin Liver Dis* 1984; 4:147-157
7. Edmondson HA, Reynolds TB, Henderson B, Benton B: Regression of liver cell adenomas associated with oral contraceptives. *Ann Intern Med* 1977; 86:180-182
8. Gordon SC, Reddy R, Livingstone AS, Jeffers LJ, Schiff ER: Resolution of a contraceptive-steroid-induced hepatic adenoma with subsequent evolution into hepatocellular carcinoma. *Ann Intern Med* 1986; 105:547-549
9. Craig JR, Peters RL, Edmondson HA: *Atlas of Tumor Pathology: Tumors of the Liver and Intrahepatic Bile Ducts (Fascicle 26)*. Washington, DC, Armed Forces Institute of Pathology, 1988
10. Johnson FL, Feagler JR, Lerner KG, et al: Association of androgenic-anabolic steroid therapy with the development of hepatocellular carcinoma. *Lancet* 1972; 2:1273-1276
11. Davis M, Portman B, Searle M, Wright R, Williams R: Histological evidence of carcinoma in a hepatic tumour associated with oral contraceptives. *Br Med J* 1975; 4:496-499
12. Edmondson HA, Henderson BA, Benton B: Liver cell adenomas associated with use of oral contraceptives. *N Engl J Med* 1976; 294:470-472