

Case report

Ehlers-Danlos syndrome, clotting disorders and muscular dystrophy

Ph BERTIN,¹ R TREVES,¹ A JULIA,² S GAILLARD,² AND R DESPROGES-GOTTERON¹

From the Departments of ¹Rheumatology, ²Haematology, CHU Dupuytren, Limoges, France

SUMMARY Ehlers-Danlos syndrome includes 11 distinct entities. The diversity of this collagen dysplasia and its combination with other abnormalities make it difficult to understand physiopathologically. A case of Ehlers-Danlos syndrome is reported, which is novel owing to its combination with clotting abnormalities and especially with muscular dystrophy. To our knowledge this has not previously been reported. The patient was a young man aged 16 years who presented with Ehlers-Danlos syndrome satisfying Perelman's diagnostic criteria. His father and two brothers had comparable clinical symptoms, but his mother and sister were healthy. The four male subjects had an increased cephalin-kaolin time, reduced levels of factor VIII and Willebrand's factor (but without haemophilia A or Willebrand's disease), and, especially, an abnormal platelet ATP secretion. The proband alone had muscular disease with bilateral quadriceps fatigability and amyotrophy. The muscle enzyme levels were greatly increased, the electromyographic trace was myogenic, and the biopsy showed severe muscular dystrophy. This new observation poses the problem of the relation between clotting abnormalities and collagen abnormalities in the Ehlers-Danlos syndrome. It is difficult to classify this case within any of the 11 known types because of its muscular manifestations. It may perhaps be a fortuitous combination or an extension of the nosological framework of this syndrome.

The syndrome described by the Dane Ehlers in 1899 and by the Frenchman Danlos in 1908, combining articular hyperlaxity, cutaneous hyperelasticity, vascular fragility, and cutaneous fragility, has long remained a clinical curiosity.^{1,2} For some years the physiopathological understanding of this collagen dysplasia has benefited from progress in genetics, biochemistry, and microscopy.³

Eleven types of Ehlers-Danlos syndrome are currently differentiated according to their clinical expression, mode of genetic transmission, and their biochemical abnormalities.^{2,4-6} Almost half of the cases cannot be classified precisely.^{5,7}

We report a new case of this syndrome not belonging to any of the 11 currently defined entities, the novel feature of which is that it is combined with clotting disorders and especially with muscular

dystrophy, which, to our knowledge, has not previously been reported.

Case report

A young man age 16 years consulted for weakness of

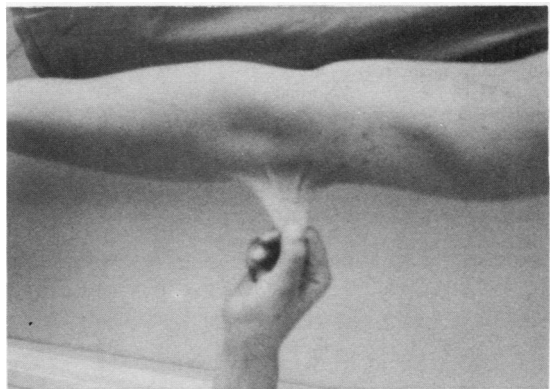

Fig. 1 Skin hyperelasticity.

Accepted for publication 1 March 1989.

Correspondence to Dr Ph Bertin, Rheumatology Department, CHU Dupuytren, 2 Avenue Alexis-Carrel, 87042 Limoges Cedex, France.

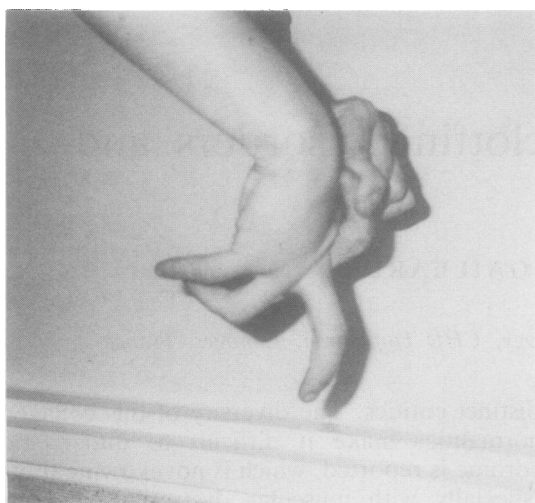


Fig. 2 Severe joint hypermobility.

the legs, which had been developing for three years. The symptoms had recently become so marked that he could no longer run or climb stairs. He had always suffered haematomas after minimal traumas, especially around the knee, leaving a wrinkled and crumpled appearance of the skin after resorption.

Examination showed the presence of pectus excavatum, haematomas undergoing resorption on the anterior face of the knees, and several dystrophic cicatrices in 'onion skin' folds. His skin was fine and hyperelastic (Fig. 1). Gorlin's sign was

present (ability to touch the tip of the nose with the tongue unaided). There was obvious articular hypermobility with the ability to place the dorsal face of the fingers on the dorsal face of the forearm (Fig. 2). Neurological examination showed bilateral quadriceps amyotrophy with a decrease in muscular force in the two quadriceps, scored as 4-. The rest of the clinical examination was normal.

Laboratory tests showed the following features: erythrocyte sedimentation rate, blood counts, differential count, platelet count, protein electrophoresis, plasma electrolytes, kidney and liver function, phosphorus and calcium balance, and amino acid chromatography (blood and urine) were normal. The muscle enzyme values were greatly increased; aldolase 9.9 U/l (normal value <3 U/l) and creatine phosphokinase 3330 U/l (normal value <130 U/l).

The clotting tests were perturbed, with increase of the cephalin-kaolin time, reduced factor VIII, reduced Willebrand's factor, and perturbation of platelet aggregation (Table 1).

HLA grouping showed the specificity A2-29, B12, DR5-7.

The electromyogram showed a myogenic trace in the quadriceps. Histological study of a right quadriceps muscle biopsy specimen showed marked heterogeneity in fibre calibres; a significant incidence of necrotic fibres with moderate proliferation of interstitial tissue.

The histoenzymological study was normal for ATPases (9.4-4.63-4.35), Sudan black, periodic acid-Schiff reagent, and phosphorylase, but the

Table 1 Clotting tests and HLA grouping in proband and relatives

	Proband	Father	Brother No 1	Brother No 2
Bleeding time (min)	5	2½	2	5
Prothrombin level (%)	100	—	—	—
CKT* (seconds)	66	53	55	49
Factor VIII (%)	25	34	46	62
Factor IX (%)	80	—	—	—
Willebrand's factor (%)	40	30	60	80
Factor XIII	Normal	—	—	—
Platelet aggregation with:				
ADP	Reduced	Normal, without ATP secretion	Weak, without ATP secretion	Weak, without ATP secretion
Adrenaline	Increased	Normal, without ATP secretion	Normal, without ATP secretion	Normal, without ATP secretion
Collagen	Normal	Normal	Normal	Weak, without ATP secretion
Ristocetin	Normal	Normal	Normal	Normal
HLA:				
A	2-29	29	2-29	2
B	12	13-12	13-21	13-21
DR	5-7	7	5-7	5-7

*CKT=creatine phosphokinase—standard 40 seconds.

Table 2 Genetic transmission of each type of Ehlers-Danlos syndrome and the associated biochemical deficiency

Type	Transmission*	Deficiency
I	D	Unknown
II	D	Unknown
III	D	Unknown
IV	R or D	Collagen type III
V	X	Lysine oxidase
VI	R	Lysine hydroxylase
VII	R or D	Procollagen peptidase
VIII	D	α_1 -Antitrypsin
IX	X	Hydroxylase and copper metabolism
X	D	Fibronectin
XI	D	Unknown

*D=dominant autosomal transmission; R=recessive autosomal transmission; X=sex linked X chromosome transmission.

oxidative enzymes (menaphthone, succinate dehydrogenase, dihydro-diphosphopyridine nucleotide) showed reduced activity in the centres of most fibres.

All these abnormalities showed the presence of a severe muscular dystrophic process.

The family survey showed that the mother and daughter were free from all disease and that the father and two brothers presented a clinical picture identical with that of our subject, with articular hyperlaxity and cutaneous hyperelasticity but without muscular fatigue or amyotrophy. Table 1 summarises the clotting tests and HLA grouping in each subject.

Discussion

Ehlers-Danlos syndrome is currently divided into 11 types.² Each entity includes the four clinical signs initially described (articular hyperlaxity, cutaneous hyperelasticity, cutaneous fragility, vascular fragility) in various proportions plus clinical symptoms specific to each type.^{2, 8, 9} Types I, II, and III are very similar: type III corresponds to a moderate condition, in which articular hyperlaxity dominates,

Table 3 Perelman's diagnostic criteria¹² for diagnosis of the Ehlers-Danlos syndrome

Clinical signs	Score
Cutaneous hyperelasticity or ligamentary hyperlaxity	1-5
Cutaneous fragility or indication of hereditary factor	1
Papyraceous, disjointed cicatrices or aneurysm or acrocyanosis or pneumothorax or digestive ectasias	0-5
Osteoarticular dystrophies	0-25

This diagnosis can be accepted with a score of three or more.

type II is the form of moderate gravity, and type I the grave form. Type IV, in which the arterial condition predominates, is marked by its vascular complications, often fatal (deep artery ruptures, visceral haemorrhages).^{3, 10, 11} Type V combines the four cardinal signs with nanism, facial dysmorphism, and cardiopathy. Type VI is distinguished by its frequent and sometimes grave ocular manifestations (blue sclerotic, retinal detachment, microcornea). Type VII is marked by small stature and predisposition to congenital hip dislocation and post-natal dislocation of other joints. Type VIII is characterised by periodontosis, leading to early loss of teeth. Type IX combines the cutaneous and articular signs with skeletal dysplasia and bladder diverticulosis. Type X is distinguished by its ecchymotic tendency. Type XI is dominated by repeated joint dislocations. Table 2 summarises the genetic transmission of each type and the biochemical deficiencies associated with them.

In our case the diagnosis of Ehlers-Danlos syndrome is unequivocal and satisfies Perelman's diagnostic criteria¹² (Table 3) but cannot be integrated into any of the 11 types described above. It belongs to the group of 'unclassifiable' Ehlers-Danlos syndromes. Its combination with specific clotting disorders and muscular dystrophy make it novel.

Clotting abnormalities have long been known during Ehlers-Danlos syndromes. In 1970 Caen *et al* studied platelet aggregation with collagen in a young woman with collagen dystrophy and prolonged bleeding time.¹³ Her platelets did not aggregate with her own cutaneous collagen but did aggregate with the cutaneous collagen from her parents. In 1973 Onel *et al* reported a case of Ehlers-Danlos syndrome combined with platelet abnormalities: deficiency of ADP and platelet factor 3 release during primary release and an absence of secondary release during aggregation with ADP, adrenaline, and collagen.¹⁴ These platelet aggregation abnormalities have been reported by other authors.^{15, 16}

In 1980, when Arneson *et al* described type X, he discovered a fibronectin dysfunction, which may explain both the platelet aggregation abnormalities and the clinical symptoms of Ehlers-Danlos syndrome.

In our case the cephalin-kaolin time was increased, factor VIII and Willebrand's factor were both below normal but not reaching levels associated with haemophilia A or with Willebrand's disease. Finally, platelet aggregation was disturbed with, as the principal feature, a decrease in ADP production.

All these abnormalities do not form any precise haematological syndrome. They do integrate into the Ehlers-Danlos syndrome and may explain the

haemorrhagic clinical signs frequently encountered in this syndrome.

The muscular condition is not known in Ehlers-Danlos syndrome but was a major factor in our patient. The absence of muscular symptoms in the father and two brothers, who had cutaneous and articular symptoms plus clotting abnormalities, should be noted. This clinical muscular condition was confirmed, on the one hand, by the marked increase in muscle enzymes and by the myogenic electromyogram trace, and, on the other hand, by the histological study of the quadriceps biopsy specimen, which showed severe muscular dystrophy.

Our observation combining Ehlers-Danlos syndrome with clotting abnormalities and muscular dystrophy confirms the polymorphism of this syndrome, which groups together several clinical, biochemical, genetic, and histological entities that are difficult to classify. Is this combination fortuitous or does it define a new Ehlers-Danlos subgroup?

References

- 1 Beylot C., Bioulac P. Le syndrome d'Ehlers-Danlos. *Bordeaux Medicine* 1978; **11**: 115-28.
- 2 McKusick V A., Pyeritz R E. Heritable and developmental disorders of connective tissues and bone. In: McCarty D J, eds. *Arthritis and allied conditions*. Vol 1. Philadelphia: Lea and Febiger, 1985: 1168-94.
- 3 Sasaki T, Arai K, Ono M, Yamaguchi T, Furuta S, Nagai Y. Ehlers-Danlos syndrome. A variant characterized by the defi-

- ciency of pro $\alpha 2$ chain of type I procollagen. *Arch Dermatol* 1987; **123**: 76-9.
- 4 Cousin J, Creusy-Guilbert C, Barlovatz-Meimom G, et al. Le syndrome d'Ehlers-Danlos en pediatrie. *Medicine et Hygiene* 1985; **43**: 518-25.
- 5 Prockop D J, Kivirikko K I. Heritable diseases of collagen. *N Engl J Med* 1984; **311**: 376-86.
- 6 Gajdos A. Deficiencias héréditaires en enzymes de la biosynthèse du collagène. "Les syndromes" d'Ehlers-Danlos. *La Nouvelle Presse Medicale* 1977; **6**: 3101-5.
- 7 Cupo L N, Pyeritz R E, Olson J L, McPhee S J, Hutchins G M, McKusick V A. Ehlers-Danlos syndrome with abnormal collagen fibrils, sinus of valsalva aneurysm, myocardial infarction, panacinar emphysema and cerebral heterotopias. *Am J Med* 1981; **71**: 1051-8.
- 8 Arneson M A, Hammerschmidt D E, Furcht L T, King R A. A new form of Ehlers-Danlos syndrome. *JAMA* 1980; **244**: 144-7.
- 9 McKusick V A. *Mandelian inheritance in man*. 5th ed. Baltimore: The Johns Hopkins University Press, 1979: 106-7, 488-9, 725-6.
- 10 Sparkman R S. Ehlers-Danlos syndrome type IV: dramatic, deceptive and deadly. *Am J Surg* 1984; **147**: 703-4.
- 11 Beylot C, Bioulac P, Doutre M S. Les manifestations artérielles du syndrome d'Ehlers Danlos. *Ann Med Interne (Paris)* 1983; **134**: 451-7.
- 12 Perelman R. *Syndrome d'Ehlers Danlos in pediatrie pratique*. Vol 2. Maloine, Ed 1980: 2110-4.
- 13 Caen J, Legrand Y, Sultan Y, Cronberg S, Jeanneau C, Pignaud G. Allongement du temps de saignement et anomalies du collagène. *Nouv Rev Fr Hematol* 1970; **10**: 426-30.
- 14 Onel D, Ulutin S B, Ulutin O N. Platelet defect in a case of Ehlers-Danlos syndrome. *Acta Haematol (Basel)* 1973; **50**: 238-44.
- 15 Hedner U, Nilsson I M. Ehlers-Danlos syndrome. *Thrombosis et Diathesis Haemorrhagica* 1975; **33**: 380.
- 16 Karaca M, Cronberg L. Platelet aggregating properties of Ehlers-Danlos syndrome "collagen". *Thrombosis et Diathesis Haemorrhagica* 1975; **33**: 380-1.