

Arthritis associated with hidradenitis suppurativa

Ravi Bhalla, Winston Sequeira

Abstract

Objective—To review the presentation and clinical findings of arthritis associated with hidradenitis suppurativa.

Method—Medical records from the rheumatology clinics of two major teaching hospitals were reviewed for arthritis and hidradenitis suppurativa. The nine patient records fulfilling these criteria were reviewed and compared with 20 previous reports.

Results and conclusion—The arthritis associated with hidradenitis suppurativa is rare and most commonly affects the peripheral joints. The axial skeleton is less frequently involved and is often asymptomatic.

(*Ann Rheum Dis* 1994; 53: 64-66)

Hidradenitis suppurativa is a suppurative condition of the apocrine sweat glands associated with induration, scarring, destruction of skin appendages and sinus formation.¹ Hidradenitis with acne conglobata and perifollicular capitis constitutes the follicular occlusion triad.¹

We describe nine patients with a seronegative arthropathy and associated skin manifestations of hidradenitis suppurativa. This is the largest series of patients with these associated condition. Previous reports of five such patients have been isolated case reports.

Method

Medical records of inpatient consultations and outpatient visits to Cook County and the University of Illinois Hospitals were reviewed retrospectively. Between 1981-91 there were nine patients with a diagnosis of hidradenitis and arthritis. These patients were followed between three months to four years. The history, laboratory data and radiographs were reviewed and compared with 20 other cases previously reported.²⁻¹⁰ Four additional cases were excluded because data presented was inadequate.¹¹ Three cases with acne and well defined rheumatological syndromes, such as, Reiter's, (2) Crohn's disease (5) and human immunodeficiency virus infection (5) were also excluded.

Results

All nine patients were Afro-americans. There were five women in the group. The average age at the time of musculoskeletal symptoms was 36.9 years with a range of 28 to 48.

Skin All nine patients had hidradenitis suppurativa involving the axilla and the groin, with a chronic draining sinus in five. Three of these nine cases also had acne conglobata. None had a full spectrum of follicular occlusion triad or acne fulminans.

Joints: Axial—Axial involvement was present with pain in the lumbar region in 3 (30%), thoracic and cervical in 1 (10%) each. Asymmetrical sacroiliac tenderness was observed in three patients, sternoclavicular, acromioclavicular, second, third and fourth costochondral joints in one case.

Peripheral—All nine patients had peripheral arthritis with episodic symptoms and morning stiffness lasting up to four hours during the acute phase of the disease. The onset of arthritis was insidious occurring 2-15 years after the appearance of skin lesions. Eight of the nine patients had an asymmetrical involvement (fig). The upper and lower extremities were equally involved, with the knee 6/9 (67%) being the most common (table). At onset, the arthritis was oligoarticular in all cases and further involvement was additive. The number of joints affected during a single episode varied from one to seven. The duration of each episode was variable. Five patients flared a total of seven times during the observation period of six months to four years, with each episode lasting from 1-5 months. The joints involved were not always the same and there were residual changes after the flare up resolved. The activity of the arthritis coincided with the skin manifestations in five patients and an exacerbation of the disease occurred with recurrence of drainage from the sinus tracts.

One patient with ankle pain had enthesopathy with Achilles tendinitis and plantar fasciitis. A second patient had pain around the knee with tenderness over the patella and at the insertion of the patellar ligament.

Muscle and soft tissue Two patients had complaints of generalised fatigue, arthralgias and hyperalgesic tender sites indicative of fibromyalgia with partial control of symptoms on amitriptyline. One patient had proximal muscle weakness of the lower extremities and an elevated creatinine phosphokinase of three times the normal level without evidence of inflammation on needle muscle biopsy or electromyography.

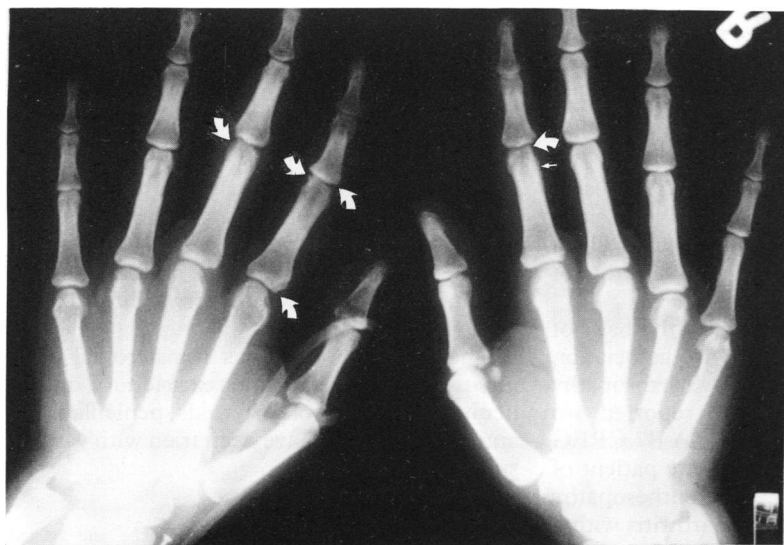
Ocular manifestations Two of the nine patients (22%) had conjunctivitis, one of them with recurrent episodes of pericorneal scleritis and a single episode of corneal ulceration and keratitis. The episcleritis responded to steroids.

Others None of the patients had psoriasis,

Division of
Rheumatology,
University of Illinois
and Cook County
Hospital,*
Chicago, IL, USA
R Bhalla
W Sequeira*

Correspondence to:
Dr Sequeira,
Department of
Rheumatology,
Cook County Hospital,
1900 W. Polk Street,
Rm 651, Chicago,
IL 60621, USA.

Accepted for publication
10 August 1993



Case 1. Asymmetrical arthropathy involving the hands. There is soft tissue swelling of the second left proximal interphalangeal joint, erosions around the proximal interphalangeal and metacarpophalangeal joints (curved arrows) and periosteal reaction of the phalanges (small arrow).

Clinical and radiographic features of arthritis associated with hidradenitis and acne conglobata—comparison of present study with previous reports

	Review* n = 20(%)	Present Study n = 9(%)	Total n = 29(%)
Age—average (years)	34.1	36.9	35.0
Sex. Male:Female	16:4	4:5	20:9
Race—Afro-americans	14 (70)	9 (100)	23 (79.5)
Whites	5 (25)	0	5 (17)
Oriental	1 (6)	0	1 (3.5)
Skin involvement:			
Hidradenitis alone	5 (25)	6 (67)	11 (38)
Acne conglobata alone	5 (29)	0	5 (17)
Acne conglobata + hidradenitis	4 (23)	3 (33)	7 (24)
Follicular occlusion triad	6 (34)	0	6 (21)
JOINT INVOLVEMENT			
Peripheral joints	16 (80)	9 (100)	25 (86)
Sites			
Knee	11 (55)	6 (67)	17 (59)
Wrist	10 (50)	4 (44)	14 (48)
Ankle	9 (45)	5 (56)	14 (48)
Elbow	6 (34)	4 (44)	10 (34)
Proximal interphalangeal	6 (30)	4 (44)	10 (34)
Metacarpophalangeal	7 (34)	2 (22)	9 (31)
Shoulder	5 (29)	2 (22)	7 (24)
Metatarsophalangeal	6 (34)	1 (11)	7 (24)
Distal interphalangeal	2 (11)	2 (22)	4 (14)
First metatarsophalangeal	3 (17)	1 (11)	4 (14)
Hip	2 (11)	1 (11)	3 (10)
Radiographic features			
erosions	8 (40)	3 (33)	11 (38)
periarticular osteoporosis	3 (15)	5 (56)	8 (28)
periosteal reaction	5 (25)	3 (33)	7 (28)
new bone formation	2 (10)	1 (11)	3 (10)
enthesopathy	2 (10)	1 (11)	3 (10)
Axial joints	16 (80)	4 (44)	20 (69)
Sites			
Unilateral sacroiliitis	9 (45)	3 (33)	12 (41)
Bilateral sacroiliitis	7 (35)	0	7 (24)
Sternoclavicular	2 (11)	1 (10)	3 (10)
Acromioclavicular	2 (11)	1 (10)	3 (10)
Costochondritis	0	1 (10)	1 (3.5)
Radiographic features			
syndesmophytes	11 (55)	0	11 (38)
squaring of vertebrae	5 (25)	2 (22)	7 (24)
Calcification of anterior longitudinal ligament	3 (15)	0	3 (10)
lytic bone lesions, hyperostosis and erosion of distal clavicle	2 (10)	1 (11)	3 (10)
osteitis pubis	2 (10)	0	2 (7)

Percentages are rounded off to nearest number *References 3,4,5,6,7,8,9,10.

pyoderma gangrenosum, oral ulcers, urethritis, erythema nodosum or inflammatory bowel disease.

Laboratory data Four of the nine patients had a normocytic, normochromic anaemia, leucocytosis with a normal differential and thrombocytosis. The sedimentation rate was elevated

in half of the cases. The rheumatoid factor was negative in 8/9 cases. One had a titre of 37 I.U/ml ($n < 30$) without other evidence of rheumatoid arthritis. The ANA was negative in 7/9 patients while two had titres of 1:80 with speckled patterns, which were negative when repeated. Complements (C3 and C4) were elevated in 1/3 cases. HLA B27 was negative in all the four cases tested, though a patient with sacroiliitis was positive for HLA B7 and B35.

Cultures from the hidradenitis lesions showed growth of *Staphylococcus aureus* and diptheroids in 2; *Streptococcus epidermidis* and enterococcus in 1 case each. Joint fluid was aspirated in 2 patients, one each from the knee and the ankle. In both cases the fluid was sterile non inflammatory with WBC counts of less than 60/mm³.

Radiology Radiographic abnormalities of peripheral joints were noted in all nine patients (table). The dominating lesions were erosions, periosteal reaction and cystic sclerotic changes.

Four patients had axial involvement with asymmetrical sacroiliitis (3), spondylolethrosis (2) and enthesopathy (1). One patient had a single focus of increased isotope uptake in the left ileum adjacent to the sacroiliac joint, and a focal hypointense area with calcification on magnetic resonance imaging. A bone scan on another patient noted an increased uptake in the lumbar and cervical vertebrae.

Treatment Nonsteroidal anti-inflammatory agents, prednisone and isotretinoin were used with varying success.

Surgical excision of hidradenitis was performed on four patients with improvement of arthritis, though no change was noted in the erosions. Recurrence of drainage from a new lesion was associated with a flare up of arthritis, progression of the erosions and periosteal reaction.

Discussion

Burns and Colleville¹² were the first to describe arthritis with severe acne, followed by similar case reports of acne fulminans. Rosner² first reported on arthritis with hidradenitis.

We compared the arthritis associated with hidradenitis and acne conglobata described in our patients with other reports (table). In our study there were an equal number of males and females. The predominance of Afro-americans in this group may reflect the population served at Cook County and University of Illinois Hospitals, which is probably true for the study from Cleveland.² Six of the nine cases with arthritis had hidradenitis without acne. There are only five such previous case reports.^{2,3,8-10} All our six cases had an asymmetrical peripheral arthritis and absence of sacroiliitis. Enthesopathy was the only axial change noted in one case. In published reports, three of five patients with hidradenitis as the only skin manifestation had axial involvement – two had unilateral sacroiliitis with peripheral arthritis^{2,8} and one with a picture resembling ankylosing spondylitis.⁹ In contrast, all three of our cases with both acne conglobata and hidradenitis as

the skin manifestations had unilateral sacroiliitis with peripheral arthritis, which is consistent with previous reports.

The keratitis and corneal ulceration noted in one case has not been previously reported with the arthritis of hidradenitis suppurativa. The muscle involvement with myalgias in two cases may be indicative of more severe skin lesions or an overlap between the musculoskeletal disease associated with hidradenitis and that of acne fulminans.

The exact cause of this arthropathy has not been determined. There is no association between this seronegative spondyloarthropathy and the B 27 antigen. Vasey¹³ reported 4/6 patients who were positive for HLA B7 CREG group while six had DRw4 and one patient of Gallo's had B51 and Cw4.⁷ The enthesopathy would suggest this is a reactive arthritis with a hypersensitivity response to bacterial antigens involved in acne. However, the occurrence of arthritis before the appearance of skin lesions contradicts this possibility. The reports of positive immune complexes⁸ and response of some patients to prednisone may be indicative of an autoimmune phenomenon.

The arthropathy associated with acne conglobata and hidradenitis is a reactive arthritis occurring over the age of 22. It is not entirely a disease of Afro-american males as previously suggested¹⁴ Five whites have been reported with this syndrome and the centres reporting these cases have a larger Afro-american population. We noted equal number of males and females in our cases. The onset of arthritis usually follows the skin condition by one to 28 years, but there are three case reports of the arthritis preceding the skin manifestations.^{8 10} The rheumatoid factor, antinuclear antibody and HLA B27 are absent. These patients have no constitutional symptoms of fever and weight loss in contrast to patients with acne fulminans, and only rarely have myalgias. The axial involvement includes unilateral or bilateral sacroiliitis, presence of syndesmophytes and squaring of vertebrae. There is an asymmetrical peripheral arthritis with erosions and periosteal reaction, equally

involving the joints of the upper and lower extremities. We find that generally hidradenitis suppurativa has a more prominent asymmetrical peripheral arthritis on initial presentation and the axial involvement occurs later, is less severe, and commonly asymptomatic. In contrast 72% of acne conglobata patients have sacroiliitis and is more commonly symptomatic. However, these are based on a small number of patients reported and more case reports need to be brought forward to validate this.

The treatment includes nonsteroidal anti-inflammatory agents and excision of hidradenitis where possible. Steroids, penicillamine² and methotrexate⁸ have been tried with varying success.

- 1 Plewig G, Stegar M. Acne inversa: acne and related disorders: *Proc International Symposium, Cardiff 1988*. In: Plewig G, Marks R, Martin Dunitz, eds. 1989: 345-76.
- 2 Rosner I A, Richter D E, Huettner T L, Kuffner G H, Wisniewski J J, Burg C G. Spondyloarthropathy associated with hidradenitis suppurativa and acne conglobata. *Ann Int Med* 1982; 97: 520-5.
- 3 Kenik J, Hurley J. Arthritis associated with hidradenitis suppurativa: *J Rheumatol* 1985; 12(1): 183-84 (letter).
- 4 Ehrenfeld M, Samra Y, Kaplinsky N. Acne conglobata and arthritis: report of a case and review of the literature. *Clin Rheumatol* 1986; 5: 407-9.
- 5 Ellis B I, Shier C K, Leisen J J C, Kastan D J, McGoey J W. Acne associated Spondyloarthropathy. Radiographic features. *Radiol* 1987; 162: 541-45.
- 6 Bookbinder S A, Fenske N A, Clement G B, Espinoza L R, Germain B F, Vasey F B. Clavicular hyperostosis and acne arthritis: *Ann Int Med* 1982; 97(4): 615-16.
- 7 Gallo M, Montagna W, Tirri G. Ankylosing Spondyloarthritis associated with acne conglobata. *Rheumatol Int* 1989; 9(2): 91-93.
- 8 Bennett R E, Wilke W S, Murphy D P. Spondyloarthropathy and Hidradenitis Suppurativa. *Ann Int Med* 1983; 97(1): 112.
- 9 Grassi W, Offidani A M, Blasetti P, Simonetti O, Cervini C. HLA-B27 negative ankylosing spondylitis and hidradenitis suppurativa: report of a case. *Clin Rheum* 1988; 7(2): 278-84.
- 10 Tallo R, Quinet R, Waxman J. Reactive arthritis due to hidradenitis suppurativa mimicking osteomyelitis. *South Med J* 1991; 84(9): 1147-49.
- 11 Clemens G B, Vasey F B, Fenske N A, Bridgeford P, Germain B F, Espinoza L R. Acne arthritis, Clinical manifestations, human leucocyte antigen and immune complexes. *Arthritis Rheum* 1982; 25: S12(abs).
- 12 Burns R E, Colleville J M. Acne conglobata and septicemia. *Arch Derm* 1959; 79: 361-3.
- 13 Vasey F B, Fenske N A, Clement G B, Bridgeford P H, Germain B F, Espinoza L R. Immunologic studies of the arthritis of acne conglobata and hidradenitis suppurativa. *Clin Exp Rheumatol* 1984; 2(4): 309-11.
- 14 Knitzer R H, Needleman B W. Musculoskeletal syndromes associated with acne. *Sem Arthritis Rheum*. 1991; 20(4): 247-55.