

Thermoanalytical and histological study of intra-articular papain-induced degradation and repair of rabbit cartilage

I. Immature animals

T. FARKAS, M. BIHARI-VARGA,* AND T. BIRÓ

From the National Institute of Traumatology and the Third Department of Medicine, Semmelweis University, Budapest, Hungary*

Arthritis has been defined as the inability of cartilage to respond to stress (Kellgren, 1961). Many methods have been developed to produce an experimental model of this disease. In a survey of the literature, Gardner (1960) referred to about 300 investigations on this subject. The results of Thomas (1956), who demonstrated reversible collapse of rabbit ears after intravenous papain, stimulated many investigators to use this agent in the research of early degenerative changes in cartilage. Bentley (1971), applying repeated intra-articular injections of papain into mature rabbit hips, succeeded in producing alterations which resembled those seen in osteoarthritis.

In young animals, repair capacity is expected to be more intense than in aged ones. In our experiments, in order to investigate the early degenerative alterations of articular cartilage and the following reparative processes, papain was injected intra-articularly into the knee joints of immature rabbits.

Papain-induced morphological changes were demonstrated by histological and histochemical methods.

Chemical determinations were performed by a complex thermoanalytical method (Paulik, Paulik, and Erdey, 1958), applied for the investigation of biological tissues by one of us (M. B. V.). By the introduction of thermal analysis into biological research the water content and glycosaminoglycan (GAG) content (Bihari-Varga, 1971a) could be measured and the structural stability of the fibrillar proteins (Bihari-Varga, 1971b) could be demonstrated simultaneously in the same original tissue-sample.

Material and methods

Twenty 6-month-old rabbits were used for the investigations. They were housed under normal conditions and kept on stock diet.

0.4 ml of a 3.0 per cent. papain solution (dissolved in physiological saline containing 0.75 mol/l. cysteine) was

injected into the knee of the right hind limb of the animals three times on consecutive 48 hrs. The same volume of sterile isotonic saline was injected into the opposite knee joint serving as control.

1, 2, 14, and 42 days after the third injection five animals were killed.

A 2-mm thick osteochondral layer was removed from the largest extension of the femoral condyles for histology. Decalcified paraffin sections were prepared and stained with haematoxylin and eosin (HE) and periodic acid-Schiff (PAS) Alcian blue.

The femoral and tibial cartilage of the knee joints as well as the menisci were excised and subjected to thermal analysis. Fresh tissue samples were cut into small pieces and delipidated by extraction with 25 per cent. ether in ethanol for 2 days, followed by 50 per cent. chloroform in methanol for 2 days, both at room temperature, and then dried to constant weight by 50 per cent. saturated air of constant flow rate. Thermal analysis was carried out using a Paulik-Paulik-Erdey MOM derivatograph. The samples, approximately 50 mg, were weighed into a platinum crucible. Heating rate was 2°/min up to 900°C.

Results

(1) MORPHOLOGICAL FINDINGS

Early changes are demonstrated on hyaline cartilage sections 48 hrs after the third papain injection (Figs 1 and 2). Surface fibrillation and loss of matrix staining in the superficial zone of the cartilage with deficient nuclear staining and empty chondrocyte lacunae indicate cellular death and depletion of GAG content.

One week after the last papain injection, similar but more extensive changes with erosion of the cartilage were observed (Fig. 3).

Signs of regeneration appeared on the sections 2 weeks after the third papain injection. Chondrocyte clusters with mitotic figures on the HE section (Fig. 4), and the irregular rich uptake of stain around the chondrocyte lacunae on the PAS-Alcian blue sections (Figs 5 and 6) are suggesting synthesis of new matrix

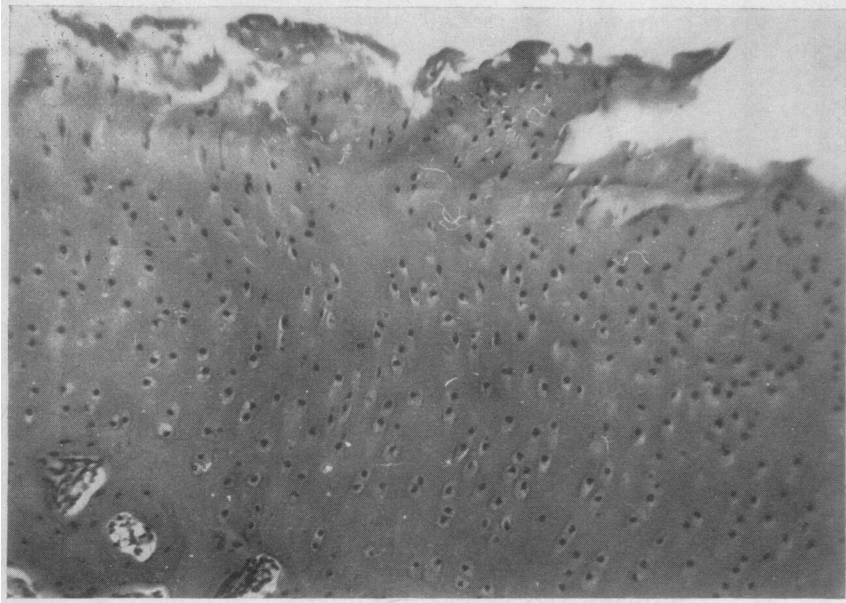


FIG. 1 Articular cartilage from knee joint of rabbit, 48 hrs after last papain injection. Haematoxylin and eosin. $\times 20$

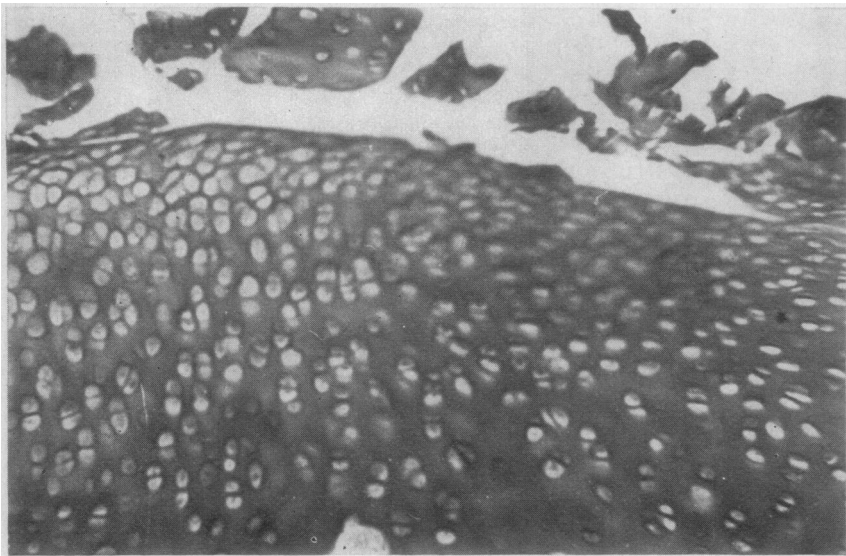


FIG. 2 Articular cartilage from knee joint of rabbit, 48 hrs after last papain injection. Periodic acid-Schiff and Alcian blue. $\times 20$

by the surviving and multiplying cartilage cells. Similar appearance was noted on the sections 6 weeks after the third papain injection.

(2) RESULTS OF THERMAL ANALYSIS

Fig. 7 shows typical thermoanalytical curves, obtained for connective tissue samples (Bihari-Varga and Biró, 1971, 1972; Bihari-Varga, Biró, and Lévai, 1971; Biró and Bihari-Varga, 1972). The instrument measured and recorded simultaneously the weight change (TG curve), rate of weight change (DTG curve), and change in heat content (DTA curve) as a function of temperature.

The first thermal process indicated by the DTG curve was the departure of the water content bound chemically to the structural components of the sample between 20° and 180°C , the amount of which can be calculated from the TG curve. This is followed by the decomposition of the structural glycosaminoglycans: polyglycuronides, sulphated acid glycosaminoglycans, and sulphated neutral glycosaminoglycans, reaching maximum rate at 220° , 240° , and 270°C , respectively. The percentage weight change measured at these characteristic temperatures was, according to our previous investigations, proportional to the amount of glycosaminoglycans present in the sample.




FIG. 3 Articular cartilage from knee joint of rabbit, 1 week after last papain injection. Haematoxylin and eosin. $\times 20$

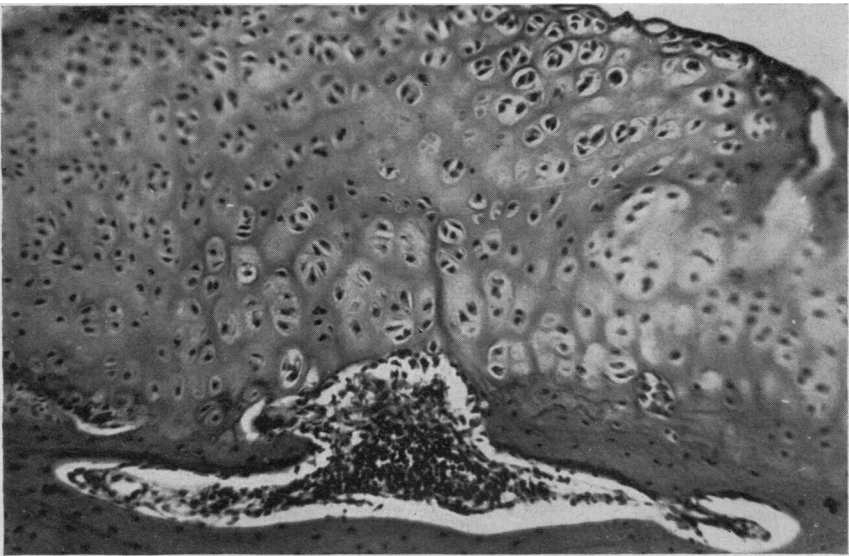


FIG. 4 Articular cartilage from knee joint of rabbit, 2 weeks after last papain injection. Haematoxylin and eosin. $\times 20$

The next main decomposition process took place with maximum rate at about 300°C and was found to be characteristic for the partial cleavage of peptide linkages in the protein moiety of the tissues, leading to the formation of polypeptide fragments. The very exotherm (positive DTA peak) final decomposition of these polypeptides took place between 450° and 800°C . Within this interval, the exact temperature when the decomposition reached its maximum rate, and the percentage weight loss due to the decomposition, depended on the thermostability of the fragments previously formed, and was correlated with the stability of intermolecular cross-links present in the fibrillar proteins of the tissue.

Fig. 8 demonstrates changes taking place in the

composition of the hyaline cartilage tissue previously exposed to papain *in vivo*.

Structural water content, remaining in the sample after partial dehydration caused by the organic solvents used for delipidation, decreased significantly in the papain-treated cartilage. After the 7th day a slow increase started, and 6 weeks after treatment structural dehydration reached the normal level.

Similar tendencies could be observed in the curves showing alterations in the GAG concentration. The only difference was that, while the decreased water content did not change in the course of the first week, there was a further diminution in the GAG level in this period.

The parallel decrease of water content and GAG

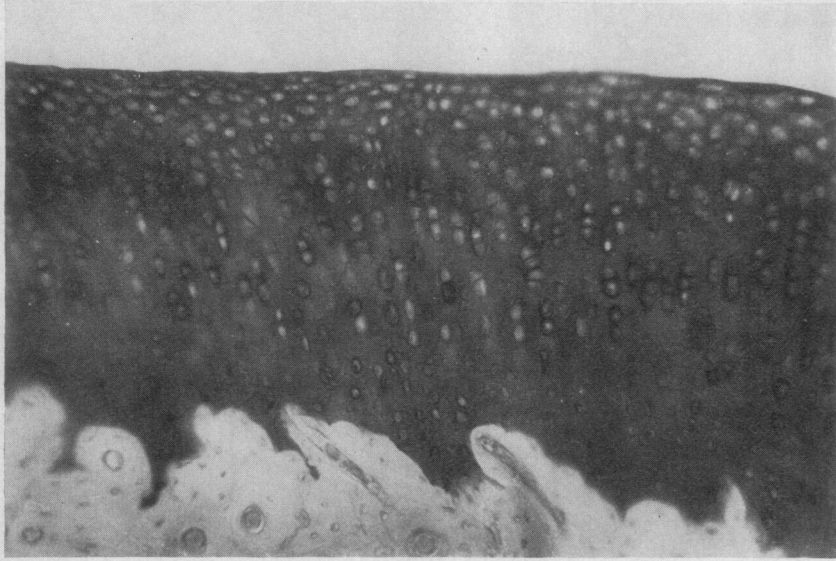


FIG. 5 *Articular cartilage from knee joint of rabbit, 2 weeks after last papain injection. Periodic acid-Schiff and Alcian blue. $\times 20$*

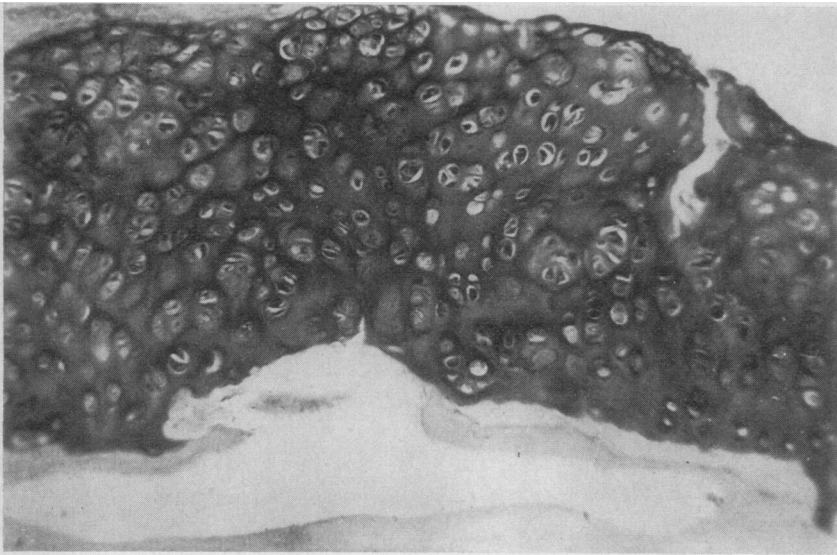


FIG. 6 *Articular cartilage from knee joint of rabbit, 2 weeks after last papain injection. Periodic acid-Schiff and Alcian blue. $\times 20$*

content of the cartilage samples indicates that the enzyme degraded at about 30 per cent. of the ground substance consisting of protein polysaccharide gel. The slow increase of hydration and of GAG level from the 7th day after treatment onwards is a sign that the repair processes, which are completed at about 5 weeks later, are beginning.

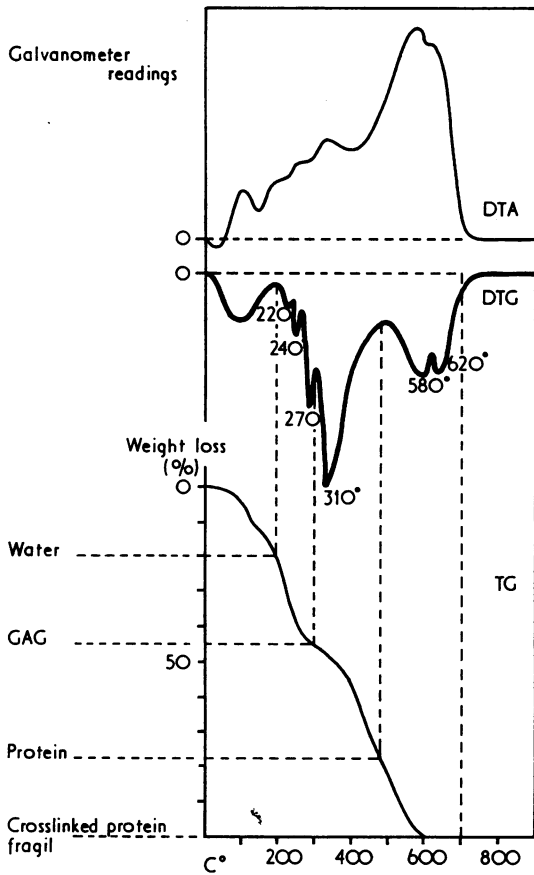
Fig. 9 shows the changes taking place in the meniscus of the knee joints previously treated with papain. Initial loss of water is similar to that found in articular cartilage; in contrast, rehydration in the meniscus during recovery is much slower despite the rapid return to almost normal values of GAG.

The decrease in GAG concentration was slighter, and the reparative process started earlier, probably

because of the different structure and lower protein polysaccharide content of meniscus tissue.

Discussion

Results of experiments *in vitro* (Strawich and Nimni, 1971; Benmaman, Ludowieg, and Anderson, 1969) and *in vivo* (Thomas, 1956; Spicer and Bryant, 1957; Tsaltas, 1958) proved that papain degraded the protein polysaccharide complexes of the ground substance of various cartilaginous tissues; the enzyme did not affect collagen proteins, but the 'unmasking' of the fibrillar elements might lead to the mechanical depletion of the latter. Destruction of chondrocytes was also observed (Murray, 1967; Engfeldt, 1969).



20°-200°	Departure of structural water
200°-290°	Cleavage of chemical bonds in glycosaminoglycans
	220° = Polyglucuronides
	240° = Acid GAG's
	270° = Sulphated neutral polysaccharides
290°-450°	Splitting of peptide linkages
450°-700°	Decomposition of crosslinked protein subunits

FIG. 7 Typical thermoanalytical curves of connective tissue samples

On the other hand, the enzymatic breakdown of protein polysaccharides is known to stimulate an increased GAG synthesis. Recovery of young rabbit ear cartilage after a single injection of papain took 2 to 4 days; the healing process was accompanied by the reappearance of matrix polysaccharides arising from a synthesis *de novo* by the cellular elements of the tissue (McElligott and Potter, 1960; Murray, 1966; Derge and Davidson, 1972).

Thus, the consequence of the sequence of events, initiated by the enzymatic degradation of the ground

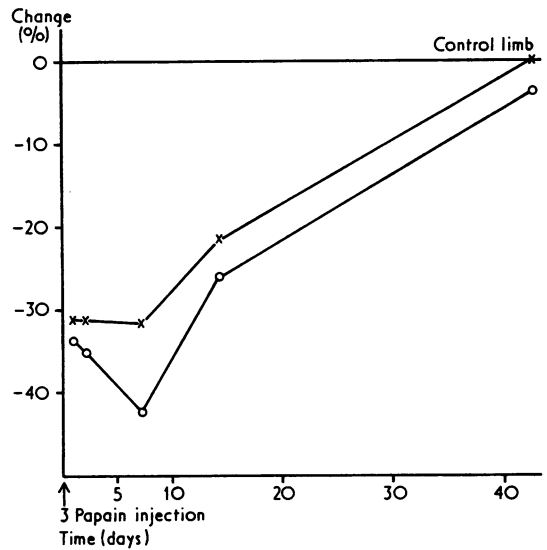


FIG. 8 Percentage changes in structural water content (x-x) and glycosaminoglycan content (o-o) of rabbit knee articular cartilage as a function of time after papain treatment. Data are referred to those measured in corresponding tissues of the control extremity

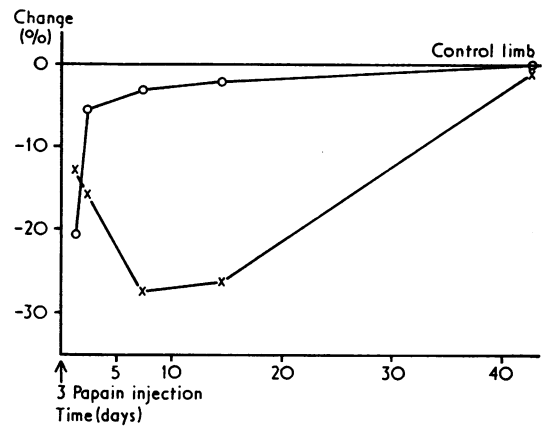


FIG. 9 Papain-induced changes in structural water content (x-x) and glycosaminoglycan content (o-o) of rabbit meniscus as a function of time after papain treatment. Data are referred to those measured in corresponding tissues of the control extremity

substance, might be either the production of tissue alterations resembling degenerative arthritis, or a gradual regeneration process due to the predominance of the reparative capacity.

In our experiments massive cartilage lesions were found in the papain-treated knees of young animals. The significant decrease measured in the GAG content and structural water concentration indicated the depolymerization of the protein polysaccharide

gel and was in good agreement with the histochemical findings.

The papain-induced changes did not lead to the destruction of the collagen of articular cartilages and to the consequent subchondral sclerosis, and cyst and osteophyte formation seen in osteoarthritis, as described by other authors (Bentley, 1971; Bryant, Leder, and Stetten, 1958) in experiments performed on mature animals.

These discrepancies might be explained by the difference in the reparative capacity of young and aged organization, possibly correlated with the known age-related decrease of cell count in articular cartilage (Mankin, 1968). The repair processes taking place in the injured tissues could be observed in our experiments; they are demonstrated by the proliferative

features seen in the corresponding sections and by the increasing GAG content of the healing cartilage.

Summary

Changes taking place in the cartilage tissue of the knee joint of immature rabbits treated with papain were investigated by histochemical and thermo-analytical methods.

As a result of papain injection, a significant decrease in the structural water content and glycosaminoglycan concentration could be demonstrated in the hyaline cartilage and meniscus tissues, indicating the selective destruction of the ground substance.

Papain-induced changes were found to be partly reversible.

References

- BENMAMAN, J. D., LUDOWIEG, J. J., AND ANDERSON, C. E. (1969) *Clin. Biochem.*, **2**, 461 (Glucosamine and galactosamine distribution in human articular cartilage: relationship to age and degenerative joint disease)
- BENTLEY, G. (1971) *J. Bone Jt Surg.*, **53B**, 324 (Papain-induced degenerative arthritis of the hip in rabbits)
- BIHARI-VARGA, M. (1971a) *Acta biochim. biophys. Acad. Sci. hung.*, **6**, 271 (Thermoanalytical assay of glycosaminoglycans)
- (1971b) *Ibid.*, **6**, 265 (Thermoanalytical characterization of the stability of cross-linked proteins)
- , AND BIRÓ, T. (1971) *Gerontologia*, **17**, 2 (Thermoanalytical investigations on the age-related changes in articular cartilage, meniscus and tendon)
- , — (1972) *Z. Alternsforsch.*, **26**, 57 (Die chemische Untersuchung der altersbedingten funktionellen Knorpel- und Sehngewebsadaptation)
- , —, AND LÉVAI, J. (1971) *Gerontologia*, **17**, 148 (Changes in the thermal decomposition of aorta, tendon, and articular cartilage in experimental lathyrisms)
- BIRÓ, T., AND BIHARI-VARGA, M. (1972) *Connect. Tiss. Res.*, **1**, 305 (Thermoanalytical studies of tendon healing)
- BRYANT, J. H., LEDER, J. G., AND STETTEN, D. (1958) *Arch. Biochem. Biophys.*, **76**, 122 (The release of chondroitinsulfate from rabbit cartilage following the intravenous injection of crude papain)
- DERGE, J. G., AND DAVIDSON, E. A. (1972) *Biochem. J.*, **126**, 217 (Protein-polysaccharide biosynthesis)
- ENGFELDT, E. B. (1969) *Acta path. microbiol. scand.*, **75**, 220 (Studies on the epiphyseal growth Zone IV. The effect of papain on the ultra-structure of epiphyseal cartilage)
- GARDNER, D. L. (1960) *Ann. rheum. Dis.*, **19**, 297 (The experimental production of arthritis. A review)
- KELLGREN, J. H. (1961) *Brit. med. J.*, **2**, 1 (Osteoarthrosis in patients and populations)
- MCCELLIGOTT, T. F., AND POTTER, J. L. (1960) *J. exp. Med.*, **112**, 743 (Increased fixation of sulfur³⁵ by cartilage *in vitro* following depletion of the matrix by intravenous papain)
- MANKIN, H. J. (1968) *Bull. N.Y. Acad. med.*, **44**, 545 (The effect of ageing on articular cartilage)
- MURRAY, D. G. (1966) *J. Surg. Res.*, **6**, 488 (Modification of experimental arthritis in rabbits by tenotomy)
- (1967) *Clin. Orthop.*, **55**, 191 (The effect of papain on epiphyseal cartilage, an electron microscopic study)
- PAULIK, F., PAULIK, J., AND ERDEY, L. (1958) *Z. analyt. Chem.*, **160**, 241 (Der Derivatograph)
- SPICER, S. S., AND BRYANT, J. H. (1957) *Amer. J. Path.*, **33**, 1237 (Cartilage changes in papain-treated rabbits)
- STRAWICH, E., AND NIMNI, M. E. (1971) *Biochemistry*, **10**, 3905 (Properties of a collagen molecule containing three identical components extracted from bovine articular cartilage)
- THOMAS, L. (1956) *J. exp. Med.*, **104**, 245 (Reversible collapse of rabbit ears after intravenous papain and prevention of recovery by cortisone)
- TSALTAS, T. T. (1958) *Ibid.*, **108**, 507 (Papain-induced changes in rabbit cartilage)