

Development with age of human articular cartilage surface structure

A survey by interference microscopy of the lateral femoral condyle

R. B. LONGMORE AND D. L. GARDNER

From the Institute of Pathology, The Queen's University, Belfast BT12 6BA

Longmore, R. B., and Gardner, D. L. (1975). *Annals of the Rheumatic Diseases*, 34, 26. **Development with age of human articular cartilage surface structure. A survey by interference microscopy of the lateral femoral condyle.** The weight-bearing surfaces of the lateral femoral condyles taken from twenty normal human cadavers aged 0–47 years have been examined by reflected light interference microscopy (RLIM) and by scanning electron microscope (SEM). The surfaces appeared normal by naked eye examination. The presence of both 200–400 μm diameter secondary undulations and small ovoid 20–45 μm diameter tertiary hollows was confirmed in all specimens using both techniques. Measurements by RLIM showed that the tertiary hollows increase significantly in depth and diameter with increasing age. A further order of quaternary surface irregularities was shown. Small irregular ridges, 130–275 nm deep and 1–4 μm diameter, were found with increasing frequency on specimens obtained from persons aged 21 years. These quaternary irregularities are thought to be due to exposure of superficial fibre bundles after the loss, with age, of surface ground substance.

It is now widely accepted that normal articular cartilage surfaces are 'irregular', i.e. not smooth, when examined in the nonloaded state *in vivo* and *in vitro*. The surface irregularities were first shown by scanning electron microscopy (SEM) (Dowson, Longfield, Walker, and Wright, 1968; Gardner and Woodward, 1968; McCall, 1968; Inoue, Kodama, and Fujita, 1969), by profile recording methods (Walker, Dowson, Longfield, and Wright, 1968), and by replica techniques on fresh and fixed isolated cartilage (Gardner and Woodward, 1969; Clarke, 1971a, b). Using incident light microscopy, the presence of the irregularities was confirmed *in vivo* in mammalian and avian joints. A classification of the orders of structure (Gardner and McGillivray, 1971) resolved surface detail into *primary* anatomical contours; *secondary* undulations of 200–500 μm diameter; *tertiary* ovoid hollows of 20–40 μm diameter, superimposed on the secondary undulations. A further quaternary order of ridges 130–275 nm deep and 1–4 μm in diameter has been described (Gardner, Longmore, Gilmore, and Elliott, 1973) (Fig. 1).

It is believed that surface morphology contributes to joint lubrication mechanisms; further, altered lubrication may influence both the age-related

cartilage changes of Byers (Byers, Contepomi, and Farkas, 1970) and the onset of osteoarthritis. Although measurements have been made of the depths and diameters of the tertiary hollows *in vitro* (Clarke, 1973), nothing is known of their chronological development. The present investigations were therefore designed to provide a sequential analysis of the microscopical structure of cartilage surfaces from birth until middle age. To permit comparison with other investigations of cartilage in this laboratory, the surveys were confined to selected zones of the lateral femoral condyle.

Material and methods

The left lateral femoral condyle was removed at autopsy from eleven females and nine males, ages ranging from birth to 47 years. The mean age was 19.25 years. The investigation was limited to knee joints that displayed smooth cartilage surfaces on naked eye examination. Joints showing areas of fibrillation were discarded; nevertheless, slight marginal osteophytosis was present in several specimens from patients aged more than 30 years. Material was not taken from obese patients, from those with an occupational history predisposing to osteoarthritis, or with renal, metabolic, or endocrine disease. Joints from immobilized persons or from limbs directly involved or near sites of injury were also discarded.

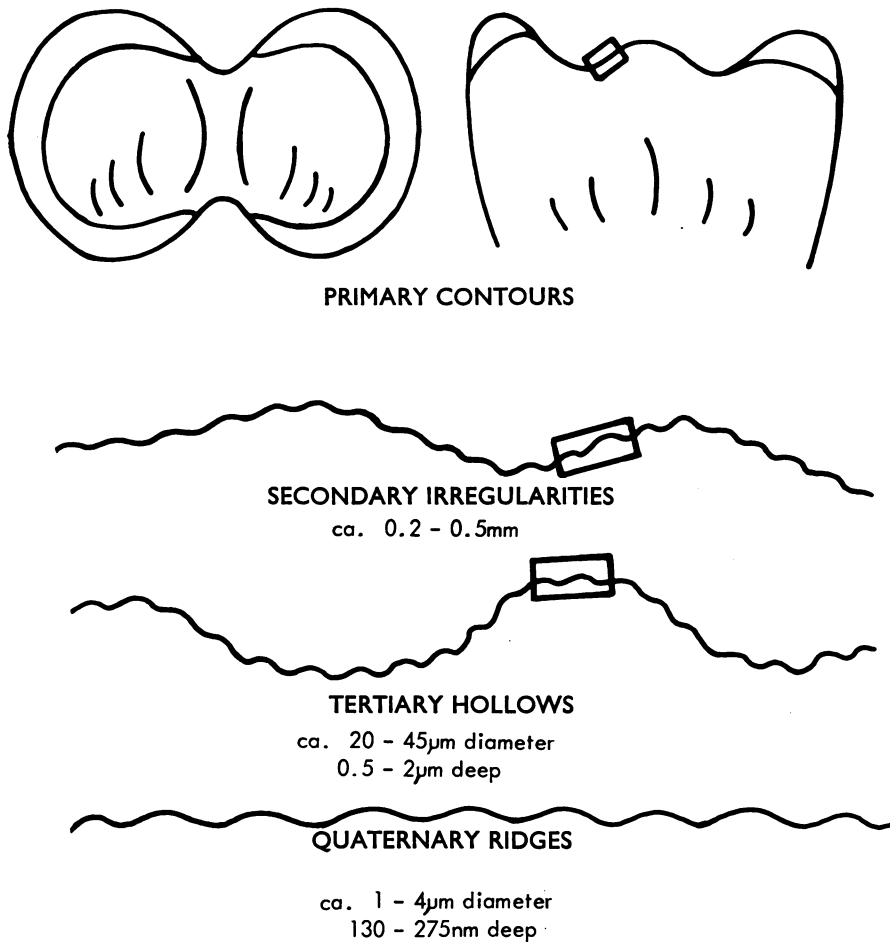


FIG.1 Diagram representing the four orders of anatomical irregularity detectable in vitro on articular cartilage surfaces. Rectangles indicate extent of surface shown in subsequent diagrams

REFLECTED LIGHT INTERFERENCE MICROSCOPY (RLIM)

Investigations were begun immediately the material was obtained. Cartilage surfaces were irrigated with a saline jet, using a hand-held wash bottle. This procedure appeared to remove most of the synovial fluid. The surfaces were then viewed with a X10 hand lens. The specimens were placed on their side for several minutes and excess fluid drained off. At no time were the surfaces touched or wiped; they were then viewed without further treatment, using a Leitz RLIM. The RLIM, based on Michelson's two-beam method and designed for metallurgical purposes, was first tested as a biological instrument in 1972 (Gardner, 1972). Since then the use of this microscope has been extended and developed (Gardner and others, 1973; Longmore, O'Brien, and Gardner, 1973). The RLIM can be used in either the *reflected* or *interference* mode. For each joint specimen, areas of the weight-bearing region of the condyle are viewed first in the

reflected mode (Fig. 2a) and photographed. The same areas are then recorded in the interference mode (Fig. 2b) without moving the specimen. In both modes an incident green light beam of wave length 550 nm is selected. The interference image provides a 'contour' map of the areas viewed in the reflected mode. The relative height difference between adjacent contour lines (interference bands of equal brightness or light extinction) is $\lambda/2$ where $\lambda = 550$ nm. Hollow depths are therefore estimated by the degree of interference band deviation in $\lambda/2$ units.

It is often difficult to be certain whether individual surface features, viewed *en face*, are depressions or elevations. Active fine focusing and through-focus photography are used to aid interpretation. The identification of saline droplets or persistent synovial fluid strands lying on the surface and their associated interference images provides a more reliable method of resolving this dilemma (Fig. 3a, 3b).

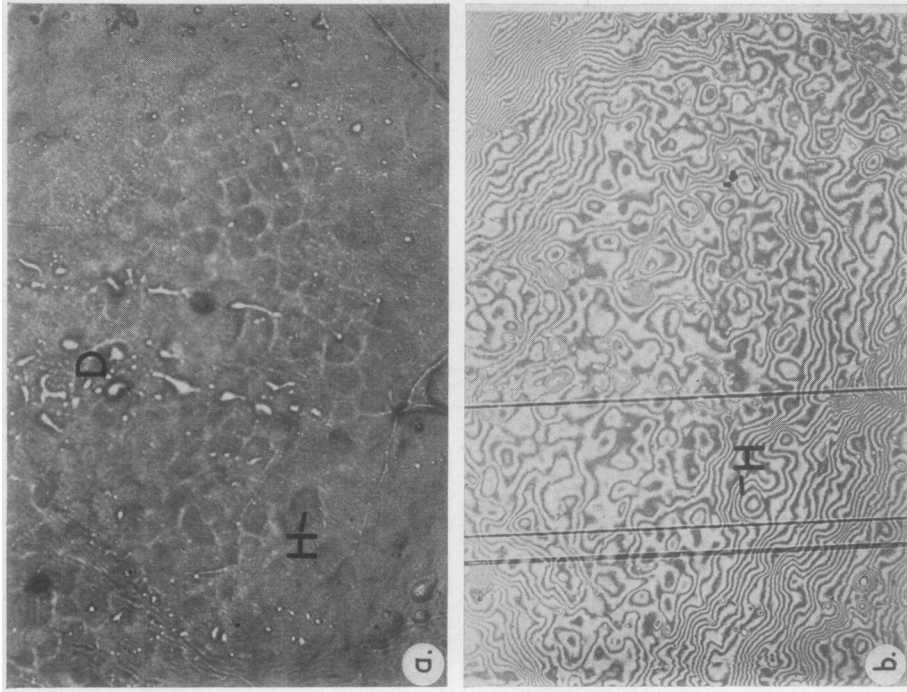


FIG. 3 (a) Articular surface of a 10-month-old female. Tertiary hollows are abundant. H = prominent hollow; D = saline droplets. RM, $\times 170$; (b) Same area. Band deviations due to the fluid droplets (known elevations) occur in a specific direction while those due to hollows have the opposite. Note the band pattern caused by hollow (H) above. IM, $\times 170$

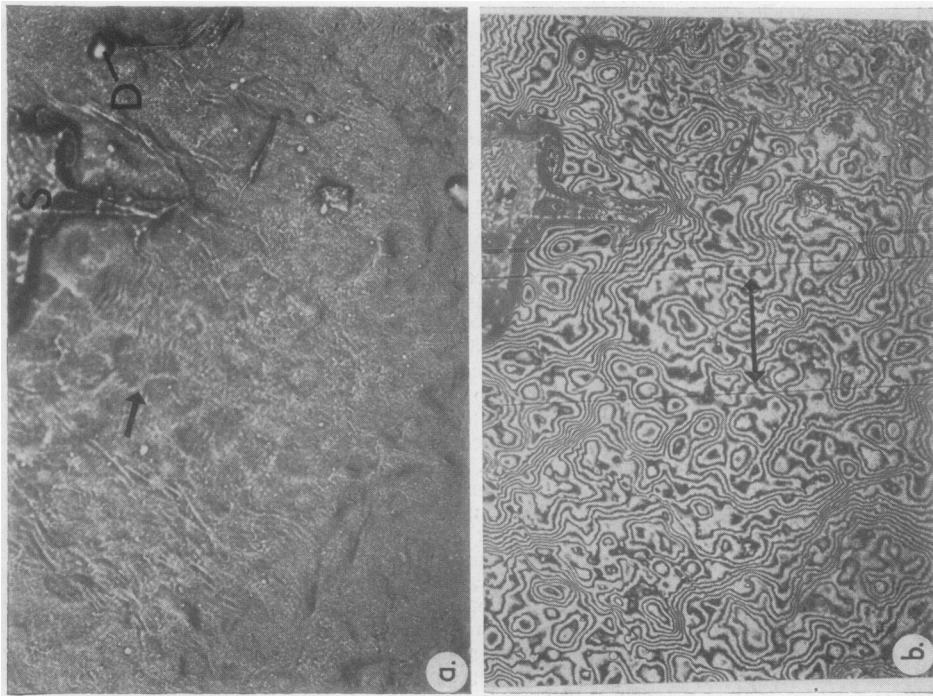


FIG. 2 (a) Articular cartilage surface of a 4-year-old female. Shallow tertiary hollows can be seen (arrowed). S = synovial fluid; D = saline droplet. Reflected light mode (RM), $\times 170$; (b) Same area. The distance between the vertical reference lines (arrowed) is $100 \mu\text{m}$. Interference mode (IM), $\times 170$

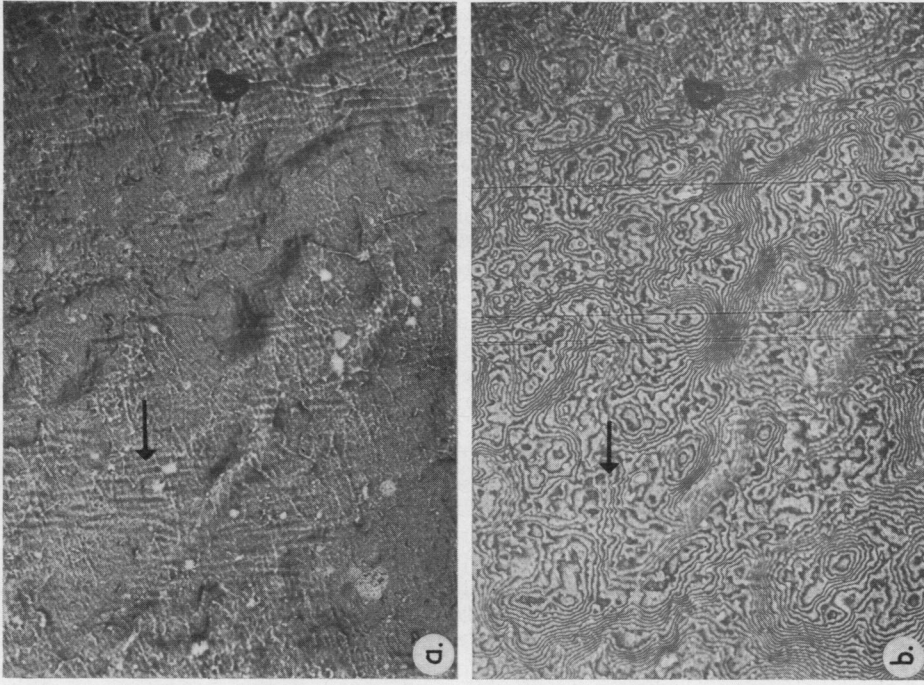


FIG. 5 (a) Articular surface in a 13-year-old female. Faint parallel ridging present. RM. $\times 170$; (b) same area. Band deviations of $\lambda/4 - \lambda/2$ (130–275 nm) corresponding to these ridges are present (arrowed). IM. $\times 170$

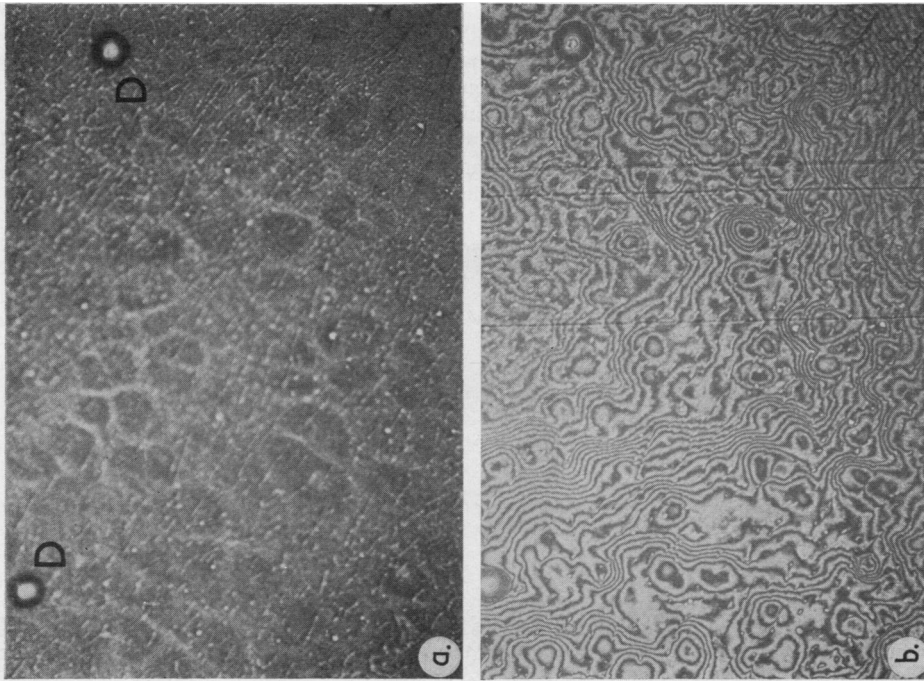


FIG. 4 (a) Articular surface in a 10-year-old male. Paired 'figure-of-eight' hollows are present. D = saline droplet. RM. $\times 170$; (b) same area. IM. $\times 170$

Tertiary hollows were selected and measurements of their maximum diameters and depths recorded. Measurements were made on 50 to 150 hollows per specimen.

SCANNING ELECTRON MICROSCOPY (SEM)

The reflected light study was supplemented by SEM. Blocks of cartilage 2–5 mm square by 1–2 mm deep were taken from adjacent weight-bearing regions of each femoral condyle. Each block was rinsed in saline to remove synovial fluid and fixed for up to one week in 3% glutaraldehyde in either phosphate or 0.1 mol/l cacodylate buffer, both at pH 7.4. After rinsing in 6 changes of buffer for one hour and then in 6 changes of distilled water for 30 min, each specimen was further prepared by 3 methods (Gardner, Cameron, and Longmore, 1974)

- (a) Dehydration in ascending grades of ethanol and, finally, in propylene oxide followed by vacuum drying.
- (b) Plunging in Freon slush and placing on the cold stage of a Pearse-Edwards tissue drier, precooled to -55°C to -60°C , followed by evaporation for 2 days. After evacuation overnight at -20°C and then for 6 hrs at 0° , blocks were brought slowly to room temperature over a 4-hour period.
- (c) Dehydration in ascending grades of ethanol, finally in amyl acetate, followed by Critical Point Drying.

After each preparative technique blocks were mounted on specimen stubs using Lö-Kit*, coated with gold-palladium, and viewed in a Cambridge Stereoscan Mark II SEM at an accelerating voltage of 20 kV.

Results

(i) **NAKED EYE AND HAND LENS EXAMINATION**
All specimens displayed secondary irregularities when examined with a X10 hand lens. These were seen as a fine stippling of the cartilage surface. When compared with the bluish-white colour of the infant and adolescent, cartilage from the 30–50 year group was white or had a yellowish hue. In several of the

* Kricheldorf, Alles-Kitt-Fabrik, Munich.

older specimens, areas of slight fibrillation were occasionally revealed by the hand lens. These areas were usually detected near the medial end of the groove for the lateral semilunar cartilage.

(ii) REFLECTED LIGHT INTERFERENCE MICROSCOPY

Tertiary hollows were present in all specimens. In young cartilage, due to the convexity of the joint surfaces, observation and recording of surface features was difficult owing to the restricted depth of focus of the RLIM. An accurate analysis of the surface frequency of the tertiary hollows in infants was therefore not possible. However, the impression was gained that there is a decrease in hollow frequency in older specimens (>20 yrs), compared with the 0–10 year group.

In the 0–10 year age group the tertiary hollows were abundant and readily observed (Fig. 4a, b). They were seen as discrete shallow depressions, frequently paired and occasionally found in clusters. The surface material between the hollows was compact and smooth. Occasionally the surface of the inter-hollow regions appeared granular.

By the second decade both hollow depth and diameter had increased. The inter-hollow regions were still relatively smooth. In some specimens (Fig. 5a, b) faint ridging was seen on parts of the joint surface. The complexity of the interference band patterns reflected these slight surface changes. Band deviations of less than half a wave length ($\lambda/2$) showed that the ridging observed ranged from 130–275 nm in height and up to 2 μm in diameter. The presence of these very small quaternary irregularities in the inter-hollow areas became more conspicuous with advancing age.

When compared with the 0–5 year specimens, there was an apparent decrease in tertiary hollow frequency in specimens over 10 years.

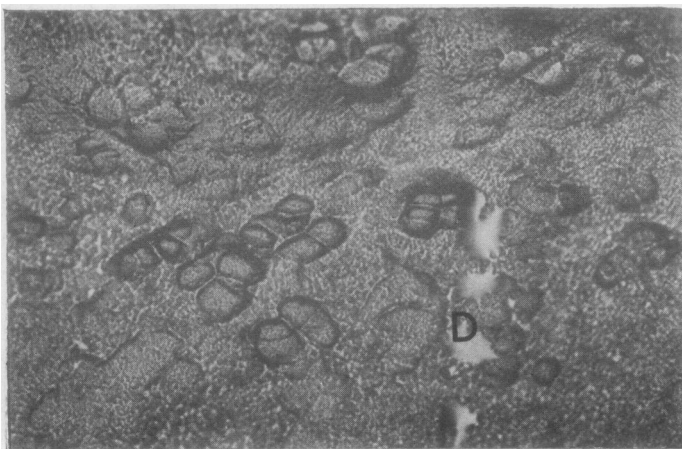


FIG. 6 *Articular surface in a 28-year-old male. D = saline droplets. RM. $\times 170$*

By the third decade, hollow diameter and depth had increased noticeably. Variations from area to area over the joint surface in each specimen were seen. In some instances (Fig. 6) the hollows were very conspicuous and even resembled chondrocyte

lacunae. Surface changes in the inter-hollow areas became more obvious with a corresponding complexity of the associated interference images. Interpretation of these intricate patterns became correspondingly more difficult (Fig. 7a, b).

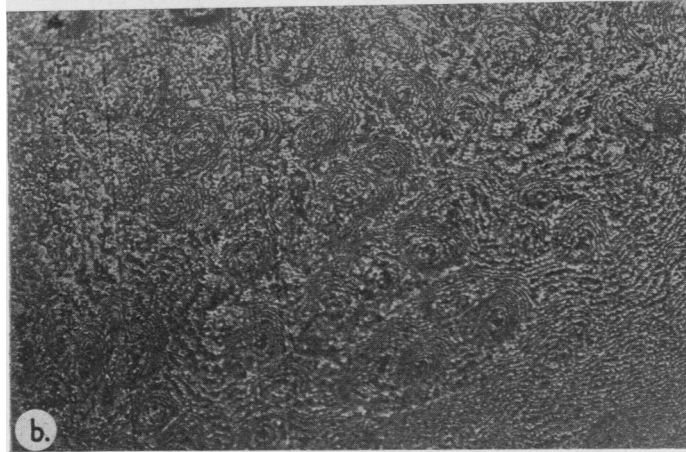
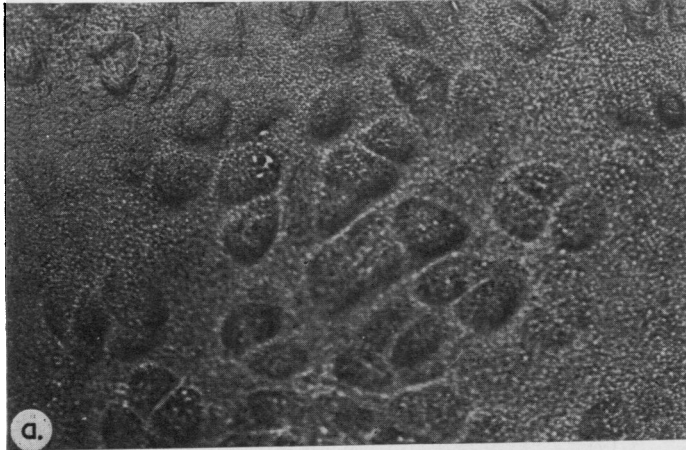


FIG. 7 (a) *Articular surface in a 36-year-old female. RM. $\times 170$* ; (b) *same area. The band patterns are extremely complicated. IM. $\times 170$*

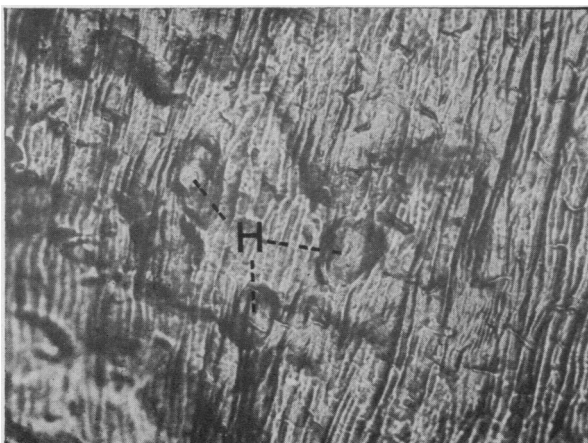

FIG. 8 *Articular surface in a 47-year-old male. H = hollows. RM. $\times 170$*

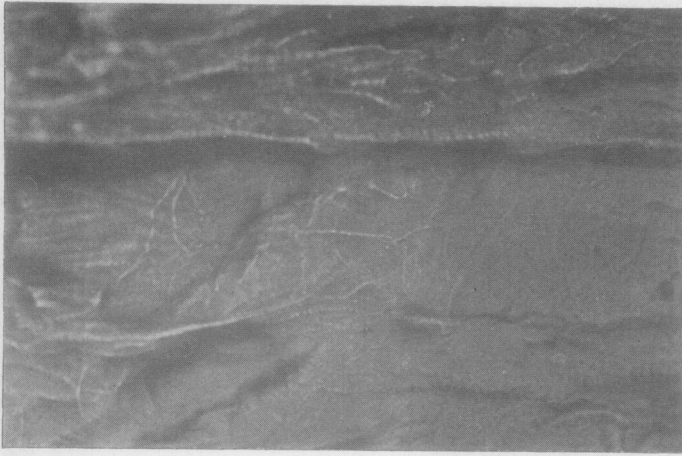


FIG. 9 *Articular surface in a 47-year-old male. No hollows are present. RM. $\times 170$*

In older specimens (30–50 yrs) variations in surface appearance were more frequent. These did not appear to be related to particular anatomical sites but occurred in areas which were normal when examined with the naked eye or by means of a hand lens. Areas of prominent surface ridging (Fig. 8), in which the large, deep hollows were present, were observed. By contrast, all specimens of this group had regions where tertiary hollows were sparse (Fig. 9). These areas consisted of plateaux separated by pronounced ridges; the plateaux were relatively smooth but showed fine, randomly orientated ridges that were frequently striated. Where fibrillation was discernible with the hand lens, the surface was found to be grossly disordered when studied at X200 with the RLIM. In these regions the cartilage appeared more translucent and displayed large irregular troughs and deep ridges. Tertiary hollows were invariably absent from these sites (Fig. 10). However, the prevalent surface appearance in the older speci-

mens was one in which hollows were prominent. In the inter-hollow regions quaternary undulations were marked and large ridges frequently seen (Fig. 11).

Hollow depth and diameter had a normal distribution in each specimen (Fig. 12). Mean tertiary hollow depth and diameter were plotted against age (Fig. 13*a, b*). Hollow depth increased significantly with age, from 0.6–0.7 μm at 0–5 years to 1.4–1.7 μm at 30–50 years. A significant increase in diameter with age was also shown, from 20–25 μm at 0–5 years to 35–45 μm at 30–50 years.

(iii) SCANNING ELECTRON MICROSCOPY

With the SEM, the presence of secondary undulations and tertiary hollows was confirmed in all specimens examined. Blocks prepared by the alcohol/propylene oxide method, by critical point drying, and by the Freon/vacuum drying method were studied. The former methods were found to be more satisfactory.

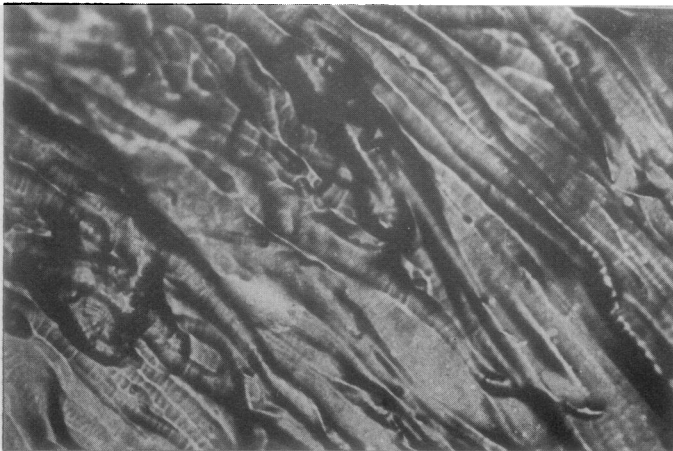

FIG. 10 *Articular surface in a 47-year-old male. No hollows are present. RM. $\times 170$*

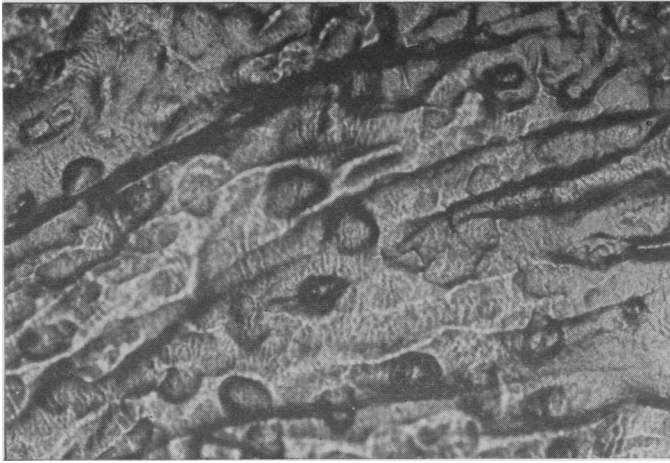


FIG. 11 Articular surface in a 38-year-old female. RM. $\times 170$

Blocks prepared by the latter technique were prone to beam damage and displayed surface ridging due to shrinkage.

In younger specimens (0–10 yrs), tertiary hollows were distinct and shallow. The inter-hollow matrix was smooth and compact (Fig. 14). In older specimens, from persons of 20–30 years, ridging was frequently observed. The greater part of these surfaces remained similar to those of the younger specimens; there was, however, increased hollow depth and diameter. In the inter-hollow areas, the fibrous nature of the surface was apparent. In older specimens, over 30 years, the surface often appeared frayed, with tongue-like projections (Fig. 15). In other regions large fibre bundles, often twisted and ‘rope-like’, were observed; they tended to lie parallel

to each other and to the surface (Fig. 16). Where the fibre bundles were apparent, there appeared to have been a loss of interfibrillar matrix.

From these observations it was concluded that the large fibre bundles were responsible for the numerous quaternary undulations commonly detected by RLIM in specimens over 30 years and sometimes in younger age groups.

Discussion

The superficial zone of articular cartilage consists of *chondrocytes* and *collagen fibres* with a complex *ground substance*.

The *chondrocytes* are ellipsoidal, lying with their long axes parallel to the surface. Light microscopic

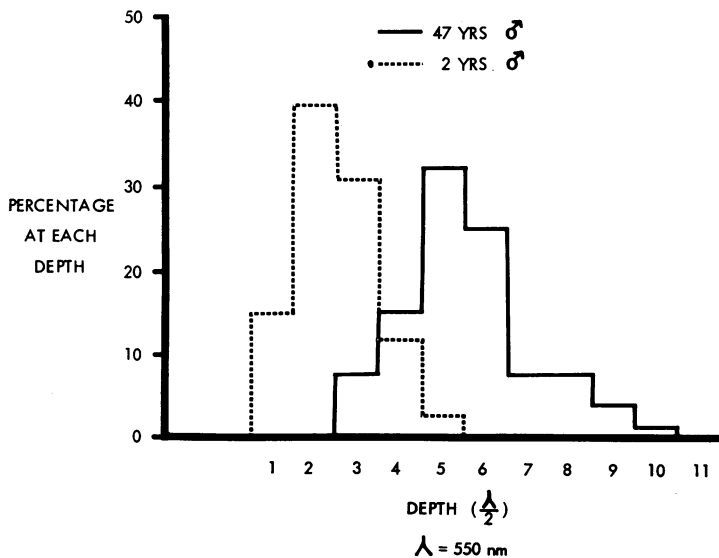


FIG. 12 Histogram of percentage of tertiary hollows at each depth in a 2-year-old male and a 47-year-old male. Hollow diameter showed a similar distribution

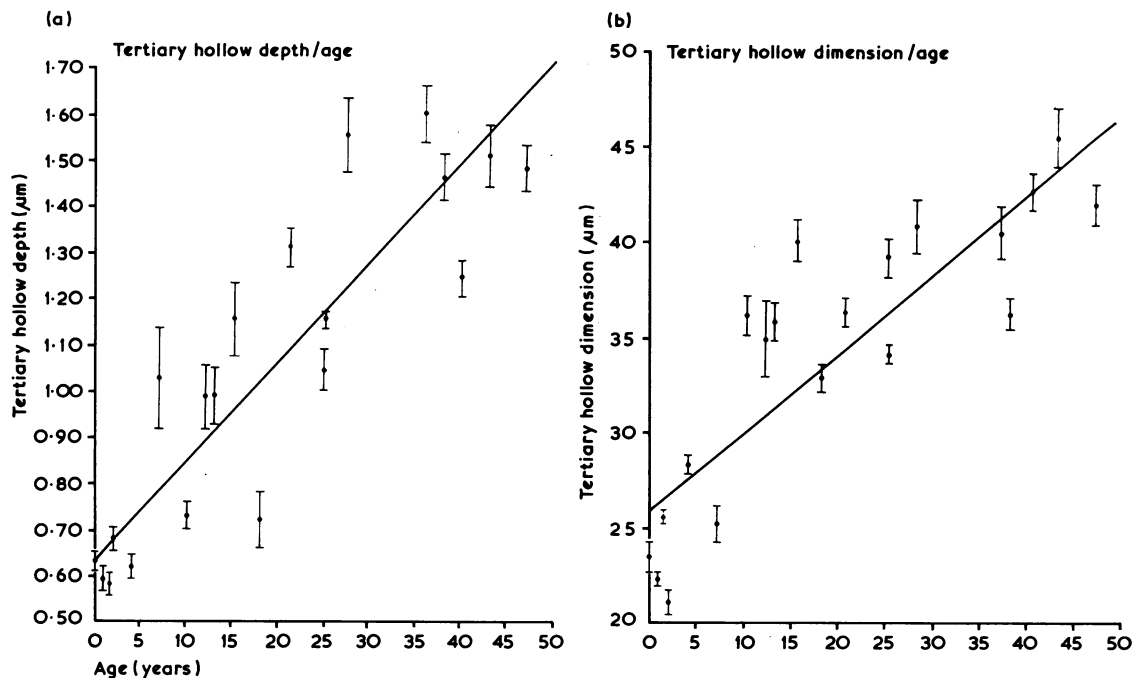


FIG. 13 (a) Graph of tertiary hollow depth against age. Regression of depth on age is given by $y = 0.6519 + (0.0205)x$; $P < 0.001$; (b) graph of tertiary hollow diameter against age. Regression of diameter on age is given by $y = 26.3274 + (0.4131)x$; $P < 0.001$



FIG. 14 Articular surface in a 10-month female infant. The white structure (S) is a strand of synovial fluid. SEM. $\times 470$

measurements of superficial chondrocytes from femoral condylar cartilage and other joints give their size as about $14 \mu\text{m}$ long and $3 \mu\text{m}$ deep (R. A. Stockwell, personal communication, 1973). With

SEM, Clarke (1971b) found that the length of the cells was greater and was in the range $10\text{--}40 \mu\text{m}$ in young adult hip joint cartilage. The measurements were made on sections cut tangential to the surface. Others have found that superficial zone cell density decreases with age; the overall cellularity remains unchanged due to an increase in cell numbers in deeper zones (Stockwell, 1967).

The superficial collagen fibres are arranged in closely packed bundles parallel to each other and to the surface. Viewed *en face*, the bundles have specific orientation which can be revealed by the 'prick-pattern' method (Benninghoff, 1925; Bullough and Goodfellow, 1968; Meachim and Roy, 1969). The tensile stiffness of articular cartilage is related to this predominant fibre orientation (Kempson, Freeman, and Swanson, 1968; Kempson, 1973), being greater in test specimens taken parallel to the surface and along the fibre alignment than from specimens taken perpendicular to the fibre orientation. These workers also reported that tensile stiffness decreases with increasing depth below the surface. No relationship between tensile strength and stiffness with age has been described. Total collagen content does not vary with age, and no reports of increased cross linkages of articular cartilage collagen with age have been published.

The fibres and cells are embedded in a ground

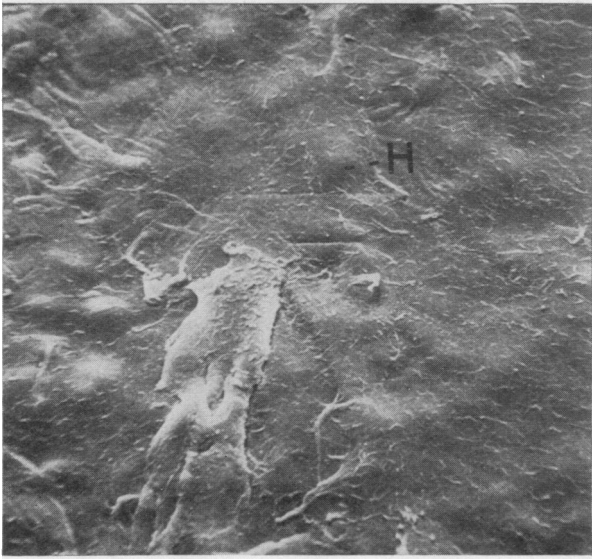


FIG. 15 *Articular surface in a 38-year-old female. H = hollow. SEM. $\times 480$*

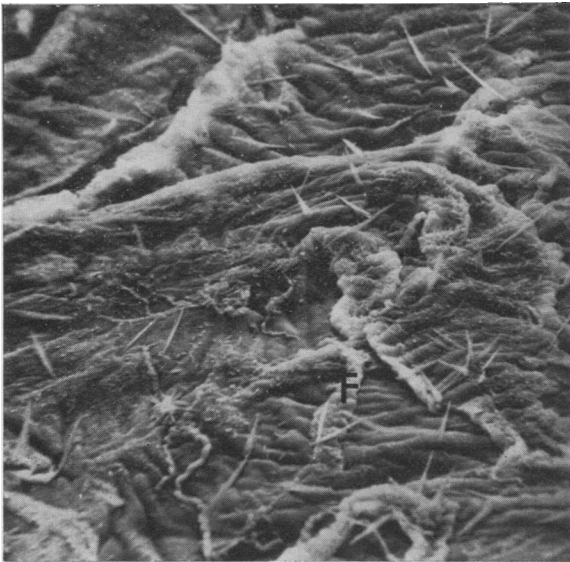


FIG. 16 *Articular surface in a 47-year-old male. No hollows are present. The fibrillar nature of the surface is evident. F = fibre bundle. SEM. $\times 487$*

substance that gives cartilage its elasticity; the chemical composition of the ground substance is complex (McDevitt, 1973). Stockwell (1970) has shown that in femoral condylar cartilage from cases over 40 years of age, a glycosaminoglycan similar to keratin sulphate is demonstrable as a lamina within $5 \mu\text{m}$ of the surface. This is associated with a decreased frequency of superficial chondrocytes and Stockwell has suggested that these factors constitute a regressive change.

In fibrillation, focal disruption of the integrity of the superficial layer of articular cartilage occurs. Fibrillation is an age-related process (Collins and

Meachim, 1961; Byers and others, 1970). The latter workers have proposed that in the hip joint two types of cartilage lesion occur: the first described as of limited cartilage degeneration, is age-related; the second differs on a topographical basis and is progressive, being part of an osteoarthrotic disease process. Despite intensive study, the initiation of fibrillation is not understood. Limited recent work (Weightman, Freeman, and Swanson, 1973) suggests that fatigue failure of surface collagen may be an important major factor in the onset of fibrillation.

In the present investigation, the surface topography was studied to define the microscopical

changes that occur with advancing age. The depth and diameter of the tertiary hollows have been measured *in vitro* by SEM, surface replica, profile-recording, and stereo-photogrammetric techniques (Clarke, 1971a, b, 1972, 1973). These studies of adult femoral head cartilage, not age controlled, showed that the 20–40 μm diameter hollows varied from 0.9–15 μm in depth measured by stereomicroscopy. Profile recording of one-stage replicas gave measurements of 0.2–5 μm . Clarke (1971a) also proposed that the tertiary hollows observed with both reflected light and SE microscopy are similar in size, configuration, and frequency to underlying superficial chondrocytes. In the present investigation hollow diameter increased significantly from 20–25 μm at 0–5 years to 35–45 μm at 40–50 years. If the hollows are the surface expressions of underlying chondrocyte lacunae, this increase may reflect the chondrocyte and lacunar enlargement that takes place during early skeletal development and, later, as an adult ageing process. The resemblance noted between hollow configuration and lacunar form when seen in section may be coincidental; however, this observation provides limited support for Clarke's proposition that the tertiary hollows are surface expressions of underlying cell lacunae.

The presence of a further quaternary order of surface irregularities was confirmed. These quaternary undulations, of depth 130–275 nm and diameter 1–4 μm , become more frequent with advancing age and were detected in the inter-hollow areas. This change in the quality of the surface was best revealed by SEM. With this instrument the gradual loss of surface ground substance and the resulting exposure of superficial fibre bundles could be appreciated readily. It is suggested that the large exposed bundles are responsible for the quaternary undulations detected by RLIM.

The relationship between joint function and the ageing changes described in this report are uncertain. Preliminary experiments on loaded cartilage *in vivo*

(Gardner, 1972) indicated that while the tertiary surface hollows may persist under load, flattening of the larger secondary undulations takes place. The concept of 'boosted' lubrication (Longfield, Dowson, Walker, and Wright, 1969; Dowson, Unsworth, and Wright, 1970) suggests that synovial fluid becomes trapped and concentrated in the irregularities on opposed cartilage loaded surfaces. However, Swanson (1973) has proposed that only an 'inconceivable regularity' of surface undulations would enable such pools to be trapped continuously. Extensive studies (Wilkins, 1968; Maroudas, 1969) indicate that the protein component of the hyaluronate-protein complex is adsorbed into the cartilage surface, the adsorbed layer acting as a boundary lubricant.

There may be a critical point in microscopical surface change where the mechanical properties of the cartilage first begin to fail. Equally, the sequence described in the present report may detract from the efficiency of lubrication and increase the wear rate of the cartilage surface, particularly if the dominant mode of lubrication is 'boundary' in type. However, little firm evidence exists to show that these are causative factors in fibrillation. The present investigation suggests that an ageing process is associated with exposure of superficial fibre bundles in macroscopically normal joints. There may be a gradual loss of surface proteoglycans. The microscopical tertiary hollows, present at birth, also show significant size changes with age. Further investigations are required to establish the connexion, if any, between this sequence and disease.

This work was generously supported by the Arthritis and Rheumatism Council for Research. Expert technical assistance was given by Mr. Stewart Cameron, Mr. John White, and Mr. Albert Copeland. Scanning electron microscope facilities were made available by courtesy of Professor Alwyn Williams, F.R.S. The advice of Mr. Robert Reid of the Queen's University Electron Microscope Unit is acknowledged.

References

- BENNINGHOFF, A. (1925) *Z. Zellforsch.*, **2**, 783 (Form und Bau der Gelenkknorpel in ihren Beziehungen zur Funktion. II. Der Aufbau des Gelenkknorpels in seinen Beziehungen zur Funktion)
- BULLOUGH, P., AND GOODFELLOW, J. (1968) *J. Bone Jt Surg.*, **50B**, 852 (The significance of the fine structure of articular cartilage)
- BYERS, P. D., CONTEPOMI, C. A., AND FARKAS, T. A. (1970) *Ann. rheum. Dis.*, **29**, 15 (A *post mortem* study of the hip joint)
- CLARKE, I. C. (1971a) *Ibid.*, **30**, 15 (Human articular surface contours and related surface depression frequency studies)
- (1971b) *J. Anat.*, **108**, 23 (Surface characteristics of human articular cartilage—a scanning electron microscope study)
- (1972) *Ann. Biomed. Eng.*, **1**, 31 (The microevaluation of articular surface contours)
- (1973) *J. Microsc.*, **97**, 309 (Quantitative measurement of human articular surface topography *in vitro* by profile recorder and stereo microscopy techniques)
- COLLINS, D. H., AND MEACHIM, G. (1961) *Ann. rheum. Dis.*, **20**, 117 (Sulphate ($^{35}\text{SO}_4$) fixation by human articular cartilage compared in the knee and shoulder joints)

- DOWSON, D., LONGFIELD, M. D., WALKER, P. S., AND WRIGHT, V. (1968) *Proc. Inst. mech. Engrs.*, **182**, Part 3N. Tribology Convention, 1968, p. 68. (An investigation of the friction and lubrication in human joints)
- , UNSWORTH, A., AND WRIGHT, V. (1970) *J. Mech. Eng. Sci.*, **12**, 364 (Analysis of 'boosted lubrication' in human joints)
- GARDNER, D. L. (1972) *Ann. rheum. Dis.*, **31**, 235 (Heberden Oration 1971. The influence of microscopic technology on knowledge of cartilage surface structure)
- , CAMERON, C. H. S., AND LONGMORE, R. B. (1974) *Proc. Roy. Microsc. Soc.*, **9**, Part 4. Micro 74 Suppl., p. 26. (Comparison of preparative techniques for cartilage in terms of surface structure)
- , LONGMORE, R. B., GILMORE, R. ST. C., AND ELLIOTT, R. J. (1973) 'Age-related changes in articular cartilage determined by interferometry', in 'Proceedings of the XIII International Congress on Rheumatology'. Excerpta Medica International Congress Series No. 299, p. 132.
- , AND MCGILLIVRAY, D. C. (1971) *Ann. rheum. Dis.*, **30**, 3 (Living articular cartilage is not smooth. The structure of mammalian and avian joint surfaces demonstrated *in vivo* by immersion incident light microscopy)
- , AND WOODWARD, D. H. (1968) *Lancet*, **2**, 1246 (Scanning electron microscopy of articular surfaces)
- , — (1969) *Ann. rheum. Dis.*, **28**, 379 (Scanning electron microscopy and replica studies of articular surfaces of guinea-pig synovial joints)
- INOUE, H., KODAMA, T., AND FUJITA, T. (1969) *Arch. hist. jap.*, **30**, 425 (Scanning electron microscopy of normal and rheumatoid articular cartilages)
- KEMPSON, G. E. (1973) 'Mechanical properties of articular cartilage', in 'Adult Articular Cartilage', ed. M. A. R. Freeman, p. 171. Pitman Medical, London
- , FREEMAN, M. A. R., AND SWANSON, S. A. V. (1968) *Nature (Lond.)*, **220**, 1127 (Tensile properties of articular cartilage)
- LONGFIELD, M. D., DOWSON, D., WALKER, P. S., AND WRIGHT, V. (1969) *Bio-med. Engng. (Lond.)*, **4**, 517 ('Boosted lubrication' of human joints by fluid enrichment and entrapment)
- LONGMORE, R. B., O'BRIEN, F. V., AND GARDNER, D. L. (1973) IRCS (73-6) 19-1-3. (Reflected light interference microscopy of the human temporomandibular joint)
- MCCALL, J. G. (1968) *Lancet*, **2**, 1194 (Scanning electron microscopy of articular surfaces)
- MCDIVITT, C. A. (1973) *Ann. rheum. Dis.*, **32**, 364 (Biochemistry of articular cartilage: nature of the proteoglycans and collagen of articular cartilage and their role in ageing and in osteoarthritis)
- MARODAS, A. (1969) 'Studies on the formation of hyaluronic acid films,' in 'Lubrication and Wear in Joints', ed. V. Wright, p. 124. Sector, London
- MEACHIM, G., AND ROY, S. (1969) *J. Bone Jt Surg.*, **51B**, 529 (Surface ultrastructure of mature adult human articular cartilage)
- STOCKWELL, R. A. (1967) *J. Anat.*, **101**, 753 (The cell density of human articular and costal cartilage)
- (1970) *Ann. rheum. Dis.*, **29**, 509 (Changes in the acid glycosaminoglycan content of the matrix of ageing human articular cartilage)
- SWANSON, S. A. V. (1973) 'Lubrication', in 'Adult Articular Cartilage', ed. M. A. R. Freeman, p. 247. Pitman Medical, London
- WALKER, P. S., DOWSON, D., LONGFIELD, M. D., AND WRIGHT, V. (1968) *Ann. rheum. Dis.*, **27**, 512 ('Boosted lubrication' in synovial joints by fluid entrapment and enrichment)
- WEIGHTMAN, B. O., FREEMAN, M. A. R., AND SWANSON, S. A. V. (1973) *Nature (Lond.)*, **244**, 303 (Fatigue of articular cartilage)
- WILKINS, J. (1968) *Ibid.*, **219**, 1050 (Proteolytic destruction of synovial boundary lubrication)