

Empyema in rheumatoid arthritis

P. A. DIEPPE

From the Brompton Hospital, Fulham Road, London

Dieppe, P. A. (1975). *Annals of the Rheumatic Diseases*, 34, 181. **Empyema in rheumatoid arthritis.** Case notes of the last 67 patients to present at the Brompton Hospital with nontuberculous empyemas, and without malignant disease, have been examined. Three cases of empyema in association with rheumatoid arthritis (RA) were found, and these cases are reported. Previous literature concerning this association is reviewed. It is concluded that two types of empyema may occur in patients with RA. Some develop in association with nodular pleuropulmonary disease and the formation of pyopneumothoraces; in other cases large, recurrent, primary empyemas build up in the presence of active rheumatoid disease alone. As with rheumatoid pleural effusions, middle-aged men seem to be particularly susceptible.

Pleural effusions are now recognized as a not uncommon complication of rheumatoid arthritis (RA) (Walker and Wright, 1967; Scadding, 1969). They occur particularly in middle-aged men, may be bilateral, and often run a protracted course. Diagnosis is partly by exclusion of other causes, but may be aided by demonstration of a low sugar content (Carr and Mayne, 1962; Lillington, Carr, and Mayne, 1971), and so-called 'rheumatoid arthritis cells' in the pleural fluid (Carmichael and Golding, 1967; Lillington and others, 1971), or pleural histology consistent with RA (Carr and Mayne, 1962; Walker and Wright, 1967; Campbell and Ferrington, 1968; Lillington and others, 1971).

An increased incidence of many infections has been described in RA (Cobb, Anderson, and Bauer, 1953; Kellgren, Ball, Fairbrother, and Barnes, 1958; Baum, 1971), and chest infections including chronic bronchitis, pneumonia, and bronchiectasis all occur more commonly than in control groups (Walker, 1967; Kay, 1967). However, in spite of this and the well-recognized incidence of pleural effusions, little has been written concerning the occurrence of empyema in RA. There are a small number of case reports (Kellgren and others, 1958; Cudkovicz, Madoff, and Abelmann, 1961; Hindle and Yates, 1965; Basten, Camens, and Schwartz, 1966; Davies, 1966; Rubin, Gordon, and Thelmo, 1967; Walker and Wright, 1967; Huskisson and Hart, 1972; Sahn, Lakshminarayan, and Char, 1973), and in 1971 Jones and Blodgett described 5 cases and suggested that empyema should be regarded as a complication of RA.

In a recent survey of all patients with nontuberculous empyema, excluding those due to malignant

disease, who have presented to the Brompton Hospital over the last 15 years, 67 case histories have been examined. Three cases of empyema in association with RA were found and are reported below. The common features of these and other cases which have been described are discussed.

Case reports

CASE 1

A 53-year-old man was well until the age of 41 when he developed classical seropositive, nodular RA. He was initially treated with salicylates and indomethacin and had one course of chrysotherapy in 1963. In 1969, because of increasing disease activity, corticosteroid therapy was initiated and he has been taking between 5 and 15 mg prednisolone daily ever since. In December 1970 he developed increasing dyspnoea and malaise without cough or sputum production. On examination he was febrile, and had a large right-sided pleural effusion (Fig. 1). Thick, purulent fluid, with a white cell count of $>50.0 \times 10^9/l$ ($>50\,000/mm^3$), predominantly neutrophils, was aspirated and was sterile on culture.

Treatment was with antibiotics and continuous drainage, and the empyema resolved over the next 6 weeks. In March 1971 he developed a left-sided pleural effusion and again sterile pus was obtained on the first aspiration. Later in that year pus again accumulated on both sides of the chest and he also developed septic lesions on the feet. In December 1971 a left thoracotomy and partial decortication was performed. At operation nodules were noted on the pleura, and histology was consistent with rheumatoid pleuritis. In spite of the operation he continued to accumulate pus in both pleural spaces, and in 1972 developed a right pyopneumothorax. In August 1972 *Escherichia coli* was isolated from pus on the left side, and this was treated by pleural washouts with appropriate antibiotics. He was readmitted in August 1973 with pus

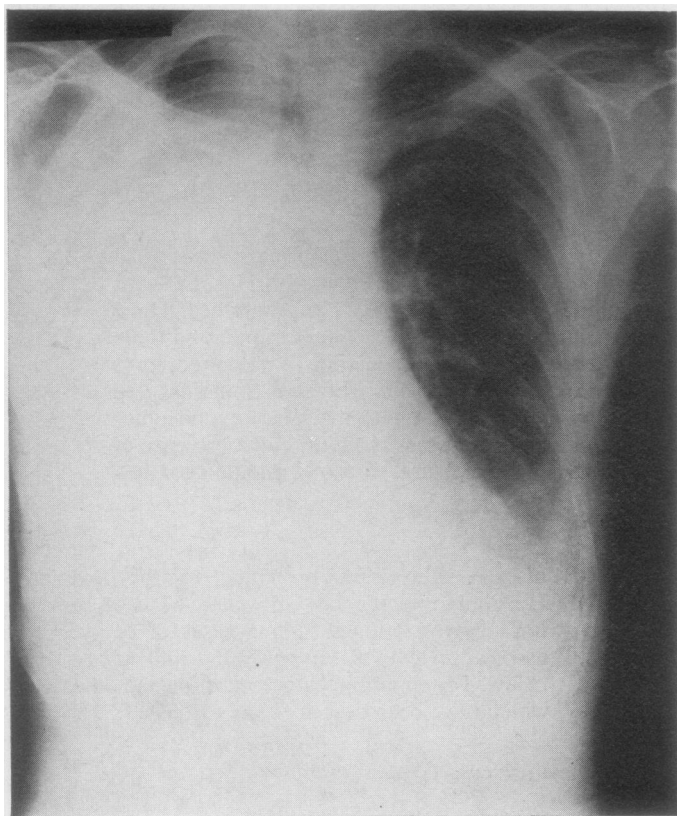


FIG. 1 *Case 1. Massive right-sided empyema in a patient with rheumatoid arthritis*

again in both pleural spaces. The appearance of the chest x-ray after aspiration at that time is shown (Fig. 2). A similar readmission was necessary in January 1974, when he was found to have a pericardial effusion in addition to bilateral pleural pus. Investigations at that time included Hb 12.7 g/dl, WBC $13.8 \times 10^9/l$ ($13\,800/mm^3$), ESR 95 mm/h, latex test positive, DAT 1:256. The patient has noticed a tendency for his arthritis to be worse when fluid accumulates in the chest.

CASE 2

A 64-year-old man developed seropositive, nodular, RA in 1940. Three months after the onset of his arthritis he developed a small right-sided pleural effusion, and on aspiration a clear yellow fluid was obtained; his chest x-ray soon returned to normal. Between 1940 and 1960 his arthritis was treated with salicylates alone. In October 1960 he suddenly developed dyspnoea, fever, and malaise, but no cough or sputum production. Examination revealed a massive left-sided effusion (Fig. 3) as well as active nodular RA and arteritic lesions on the fingers. The first aspiration yielded thick pus from which a heavy growth of *Staphylococcus aureus* was isolated. Treatment was with repeated aspiration and systemic antibiotics, but the pus was slow to clear. After 2 months he was left with a posterior loculation of fluid, and was discharged from hospital. Investigations at the time of admission included: Hb 13.8 g/dl, WBC $6.2 \times 10^9/l$ ($6\,200/mm^3$), ESR 92 mm/h, latex test positive, DAT 1:32. During

regular follow-up he has had no further chest trouble, and his rheumatoid disease has required salicylate therapy alone.

CASE 3

A 50-year-old man with a previous history of episodes of pneumonia in 1943 and 1946, and onset of chronic bronchitis in 1949. In 1958 he developed seropositive nodular RA and has been treated with salicylates, indomethacin, two courses of gold, and one of antimalarial therapy, but he has never been on steroids. In 1964 he was admitted to hospital with a short history of increasing cough, dyspnoea, and malaise; on examination he was febrile and had a large right-sided pleural effusion. Frank pus was aspirated at the first tap, but no organisms were isolated, perhaps because he had been receiving antibiotics from his general practitioner. The fluid slowly cleared over a 2-month period of antibiotic treatment and repeated drainage. In 1968 he was readmitted with a 3-week history of cough and dyspnoea. He was found to have active RA and a massive right-sided effusion from which sterile pus was again aspirated. Investigations at the time included Hb 12.5 g/dl, WBC $8.5 \times 10^9/l$ ($8\,500/mm^3$), ESR 59 mm/h, latex test positive, DAT 1:16. The pleural fluid was frankly purulent on macroscopical examination and had a white cell count of $54.0 \times 10^9/l$ ($54\,000/mm^3$), predominantly neutrophils. Repeated drainage and antibiotics again resulted in slow resolution. There has been no recurrence on follow-up, and he has

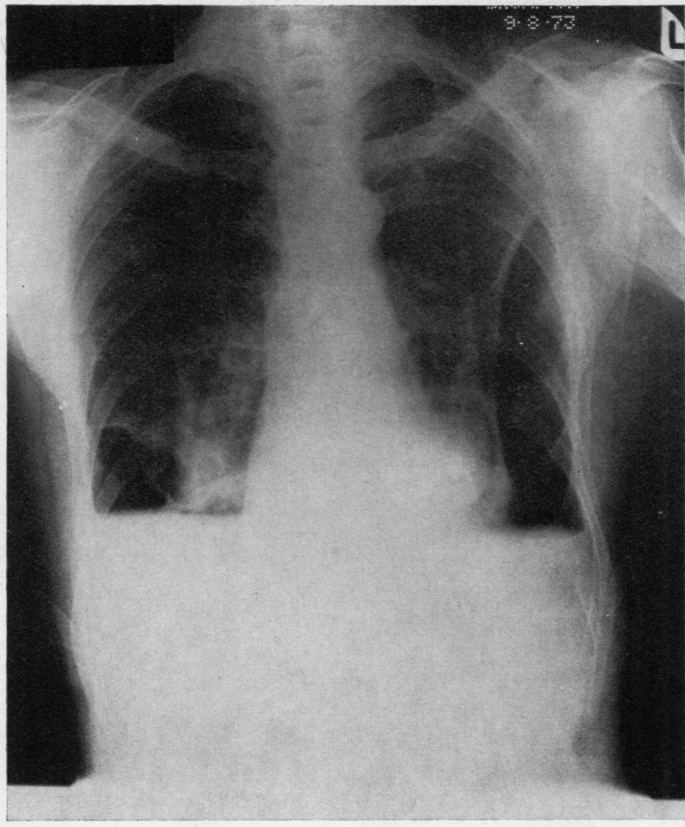


FIG. 2 Case 1. Showing the development of bilateral pyopneumothoraces

continued to take salicylates to control his RA. This patient had also noted worsening of his arthritis on admission for treatment of the empyema.

Discussion

A number of case reports of empyema in association with RA appears in the literature. In 1943 Baggenstoss and Rosenberg found pus in the pleural space in 2 of 30 autopsied cases of RA. In 1961 Cudkowicz and others described the case of a 63-year-old man with severe RA, treated with steroids, who developed repeated bilateral empyemas in the absence of prior evidence of intrapleural infection or pneumothorax. Similar cases have been described by Kellgren and others (1958), Walker and Wright (1967), Huskisson and Hart (1972), and Sahn and others (1973). In two of these papers the relevant cases were part of a series of patients showing severe, unusual infections in RA and more than one site of infection (Kellgren and others, 1958; Huskisson and Hart, 1972), as did Case 1 of the present series. Slightly different cases in which there was spontaneous development of a pyopneumothorax in patients with nodular rheumatoid pleuritis have been documented by

Hindle and Yates (1965), Basten and others (1966), Davies (1966), and Rubin and others (1967). Davies (1966) has postulated that in these cases necrosis of the rheumatoid pleural nodules leads to communication between lung and pleural space, and the secondary development of a pyopneumothorax.

In 1971, Jones and Blodgett reported a series of 10 cases of rheumatoid pleural effusion, 5 of which developed empyemas. Of these 5 cases, 4 were women and 3 were on steroids. 4 of them had previously developed serous pleural effusions which had been aspirated. The authors suggested that empyema might be regarded as a relatively common complication of rheumatoid pleuropulmonary disease; but Blau (1971) reported that of 75 cases of rheumatoid pleural effusions aspirated in his unit, none had developed an empyema and he suggested that introduction of infection may have occurred in some of Jones and Blodgett's cases. In this study the last 67 cases of empyema seen at a chest hospital were examined; one patient with mild RA developed an empyema after chest trauma, and another 3 cases with RA were found and these have been described above. From this it seems that empyema is a rare occurrence in association with RA.

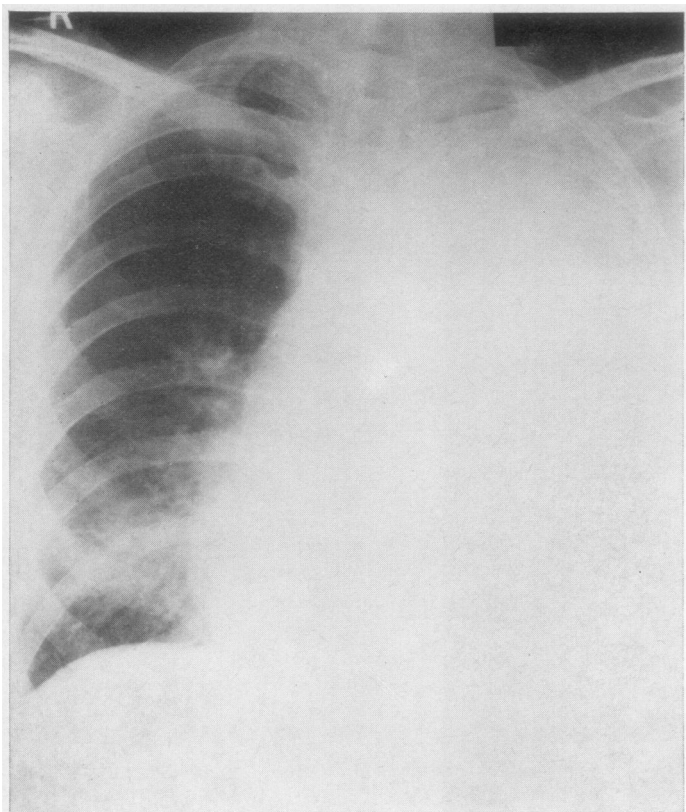


FIG. 3 Case 2. Left-sided empyema

Some features of these cases are worthy of mention. All occurred in middle-aged men and in each case pus was aspirated at the first pleural tap. There was no evidence of intrapulmonary infection, pneumothorax, or serous pleural effusion having been present immediately before the accumulation of pus, so these men have developed primary empyemas. All cases required prolonged treatment and Case 1 later developed a pyopneumothorax. In view of the size of the empyemas (Figs 1 and 3), systemic manifestations were perhaps not marked. Sahn and others (1973) have stressed the development of silent empyemas in patients on steroids, although this was only true in the first of these 3 cases. Two of the patients reported a marked 'flare' of their arthritis at times when fluid accumulated in the chest, and in these two bacteriological examination of the pus was repeatedly negative. This suggests that the active rheumatoid disease may have been contributing directly to the formation of pus in the pleural space. Only in Case 1 was rheumatoid pleuritis confirmed by a characteristic pleural biopsy, although in Case 2 the previous occurrence of a pleural effusion near the time of onset of his arthritis seems to be good circumstantial evidence of the nature of the disease, and in Case 3 the diagnosis was made by exclusion

of other causes for the empyema. In each case the pleural fluid was thick and macroscopically frankly purulent, and in the 2 cases in which the cell count was measured it was greater than $50.0 \times 10^9/l$ ($50\,000/mm^3$) with neutrophils predominating. This clearly distinguishes the fluid in the above cases from that which accumulates in simple rheumatoid effusions, as the latter is usually thin and clear, with a cell count of less than $10.0 \times 10^9/l$ ($10\,000/mm^3$) and a pleomorphic cell picture.

A number of infections are thought to occur more commonly in people with RA and the subject has recently been reviewed (Baum, 1971; *British Medical Journal*, 1972). Both Walker (1967) and Kay (1967) have reported an increased incidence of chronic bronchitis, pneumonia, and bronchiectasis in large groups of patients with RA compared with age- and sex-matched control groups with degenerative joint disease. In many cases the pulmonary disease seems to antedate the onset of the arthritis, although the cause for this susceptibility is unknown. It is of interest to note that Case 3 was a chronic bronchitic who had had 2 previous attacks of pneumonia before the onset of RA. There was, however, no evidence of any other pulmonary pathology, such as fibrosing alveolitis, in any of the 3 cases.

Empyemas are now rare, but RA is a common disease and it is difficult to conclude that any specific complication is a direct result of the rheumatoid disease. However, from these cases and the previous literature, it seems that two distinct types of empyema may occur in patients with RA. In the first group nodular pleuritis seems to lead to the development of a pyopneumothorax. In the second group large accumulations of pus are found in the presence of active RA, but in the absence of any other apparent predisposing pleural or intrapulmonary condition,

the pus may build up in the absence of very marked systemic symptoms and may be sterile. All cases have proved difficult to treat, and the middle-aged, or elderly male, appears to be particularly susceptible.

I am grateful to Dr. K. M. Citron for his help and encouragement with this paper, and for permission to publish Case 1. I would also like to thank Dr. J. R. Bignall and Professor J. G. Scadding for permission to publish Cases 2 and 3 respectively, and Drs. H. C. Burry and E. C. Huskisson for advice with the manuscript.

References

- BAGGENSTOSS, A. H., AND ROSENBERG, E. F. (1943) *Arch. Path.*, **35**, 503 (Visceral lesions associated with chronic infectious (rheumatoid) arthritis)
- BASTEN, A., CAMENS, I., AND SCHWARTZ, C. J. (1966) *Aust. Ann. Med.*, **15**, 175 (Rheumatoid lung disease with report of a case)
- BAUM, J. (1971) *Arthr. and Rheum.*, **14**, 135 (Infection in rheumatoid arthritis)
- BLAU, S. P. (1971) *Ann. intern. Med.*, **75**, 476 (Empyema in rheumatoid lung disease)
- British Medical Journal* (1972) **2**, 549 (Infection in rheumatoid disease)
- CAMPBELL, G. D., AND FERRINGTON, E. (1968) *Dis. Chest.*, **53**, 521 (Rheumatoid pleuritis with effusion)
- CARMICHAEL, D. S., AND GOLDING, D. N. (1967) *Brit. med. J.*, **2**, 814 (Rheumatoid pleural effusion with 'R.A. cells' in the pleural fluid)
- CARR, D. T., AND MAYNE, J. G. (1962) *Amer. Rev. Resp. Dis.*, **85**, 345 (Pleurisy with effusion in rheumatoid arthritis with reference to the low concentration of glucose in the pleural fluid)
- COBB, S., ANDERSON, F., AND BAUER, W. (1953) *New Engl. J. Med.*, **249**, 553 (Length of life and cause of death in rheumatoid arthritis)
- CUDKOWICZ, L., MADOFF, I. M., AND ABELMANN, W. H. (1961) *Brit. J. Dis. Chest*, **55**, 35 (Rheumatoid lung disease: a case report which includes respiratory function studies and a lung biopsy)
- DAVIES, D. (1966) *Thorax*, **21**, 230 (Pyopneumothorax in rheumatoid lung disease)
- HINDLE, W., AND YATES, D. A. H. (1965) *Ann. rheum. Dis.*, **24**, 57 (Pyopneumothorax complicating rheumatoid lung disease)
- HUSKISSON, E. C., AND HART, F. D. (1972) *Ibid.*, **31**, 118 (Severe, unusual, and recurrent infections in rheumatoid arthritis)
- JONES, F. L., AND BLODGETT, R. C. (1971) *Ann. intern. Med.*, **74**, 665 (Empyema in rheumatoid pleuropulmonary disease)
- KAY, A. (1967) *Lancet*, **2**, 152 (Infection in rheumatoid arthritis)
- KELLGREN, J. H., BALL, J., FAIRBROTHER, R. W., AND BARNES, K. L. (1958) *Brit. med. J.*, **1**, 1193 (Suppurative arthritis complicating rheumatoid arthritis)
- LILLINGTON, G. A., CARR, D. T., AND MAYNE, J. G. (1971) *Arch. intern. Med.*, **128**, 764 (Rheumatoid pleurisy with effusion)
- RUBIN, E. H., GORDON, M., AND THELMO, W. L. (1967) *Amer. J. Med.*, **42**, 567 (Nodular pleuropulmonary rheumatoid disease)
- SAHN, S. A., LAKSHMINARAYAN, S., AND CHAR, D. C. (1973) *Amer. Rev. Resp. Dis.*, **107**, 873 ('Silent' empyema in patients receiving corticosteroids)
- SCADDING, J. G. (1969) *Proc. roy. Soc. Med.*, **62**, 227 (The lungs in rheumatoid arthritis)
- WALKER, W. C. (1967) *Quart. J. Med.*, **36**, 239 (Pulmonary infections and rheumatoid arthritis)
- , AND WRIGHT, V. (1967) *Ann. rheum. Dis.*, **26**, 467 (Rheumatoid pleuritis)