

# Involvement of the eye in SLE and scleroderma

A study using fluorescein angiography in addition to clinical ophthalmic assessment

DAVID M. GRENNAN AND JOHN FORRESTER

*From the Centre for Rheumatic Diseases and University Department of Medicine, Glasgow Royal Infirmary, and University Department of Ophthalmology, Western Infirmary, Glasgow*

**SUMMARY** General examination of the eye was carried out in 22 patients with systemic lupus erythematosus (SLE) and in 10 with scleroderma. 3 of the SLE and 2 of the scleroderma patients had keratoconjunctivitis sicca. Fluorescein angiography showed abnormalities of the retinal vasculature in one of a subgroup of 12 SLE patients and one of 10 scleroderma patients. None of the 12 SLE patients had abnormalities of the choroidal vasculature, while 5 of the 10 scleroderma patients had patchy areas of nonperfusion of the choroidal capillary bed.

Eye involvement was studied in patients with scleroderma and systemic lupus erythematosus (SLE) seen in a connective tissue disease clinic. In addition to routine clinical methods we used fluorescein angiography to study the choroidal and retinal vasculatures (Wessing, 1969).

There have been few reports on the use of this technique in connective tissue disease (Hammanis and Streiff, 1973). A recent review suggested that in SLE retinal microvascular abnormalities could be shown using fluorescein angiography in the absence of visible fundal lesions (Lachman and Hazelman, 1975). It has also been suggested that this technique may be important in assessing disease activity in patients with suspected cerebral lupus (Edmonds *et al.*, 1975). Therefore we considered it important to investigate the ocular circulation by this technique in our patients with SLE.

Post-mortem studies in patients with scleroderma have shown abnormalities of the choroidal vasculature (Maclean and Guthrie, 1969; Farkas *et al.*, 1972) as well as exudates in the retina (Maclean and Guthrie, 1969). These abnormalities were associated with advanced disease, often in hypertensive patients. In addition, other fundal abnormalities have been described in scleroderma including retinal oedema, haemorrhages, and exudates (Dolfus, 1958), venous thrombosis (Josten, 1958), and cotton wool spots

(Pollack and Becker 1962). The pathology of these lesions was described by Manschot (1965) and they are generally regarded as being secondary to late hypertensive disease. We investigated the choroidal and retinal vasculatures in a group of patients with early as well as advanced manifestations of scleroderma and believe this to be the first report of a systematic study of such patients by fluorescein angiography.

## Patients

### SLE

Twenty-two patients with SLE had a general ophthalmic examination and were screened for keratoconjunctivitis sicca (KCS). All patients satisfied the preliminary criteria of the ARA for a diagnosis of SLE (Cohen *et al.*, 1971). Fluorescein angiography was carried out on 12 of these patients. 9 were being treated with steroids and the disease process was considered to be under reasonable control in all except one patient. 8 patients, however, had some clinical evidence of disease activity. 7 had renal disease but none had evidence of cerebral involvement at the time the test was carried out. 9 patients had antibodies to native DNA as shown by the Farr test (Hughes, 1971) at the time of fluorescein angiography, 4 had diminished levels of complement C4, and 2 of these also had lowered complement C3 levels at this time.

### SCLERODERMA

The clinical features of the 10 patients investigated are shown in the Table. 3 patients had florid, rapidly

Accepted for publication June 14, 1976  
Correspondence to Dr. D. M. Grennan, Rheumatic Diseases Unit, Wellcome Medical Research Institute, Department of Medicine, University of Otago Medical School, Dunedin, New Zealand.

progressive generalized cutaneous disease which was associated with Raynaud's phenomenon and polyarthralgia in the first, oesophageal involvement in the second, and oesophageal and pulmonary involvement, Raynaud's phenomenon, and telangiectasia in the third. The disease in the other 7 patients has been less aggressive and, unlike Cases 2 and 3 who received penicillamine, their untreated prognosis was judged not to justify any potentially hazardous drug therapy. Case 10 had sclerodactyly, Raynaud's phenomenon, and polyarthritis, while Cases 4-9 all had some internal organ involvement in addition to cutaneous changes.

## Methods

### OPHTHALMIC ASSESSMENT

In addition to general ophthalmological examination, including binocular indirect ophthalmoscopy, all patients had tear flow measurements taken by augmented Schirmer tear testing, plus slit-lamp biomicroscopy of the anterior segment of the eye after the instillation of Rose bengal dye for the diagnosis of KCS. Fundal photographs were taken in all cases.

### FLUORESCIN ANGIOGRAPHY

Fundal fluorescein angiography was carried out using an intravenous bolus of 3 ml sodium fluorescein 15% solution in distilled water. Rapid sequence photographs at intervals of 1.5 seconds were taken using a Nikon F2 modified fundus camera with a blue excitor filter (Kodisk W27A) and a yellow barrier filter (Kodisk W12). A wide angle lens was incorporated into the camera.

## Results

### SLE

Three of the 22 patients had KCS. One patient had cytooid bodies in both fundi (Fig. 1). When these were first seen this patient had florid active disease with cutaneous, renal, and pleural involvement plus a peripheral neuropathy. Her blood pressure was 130 systolic/90 diastolic mmHg. Treatment with steroids (60 mg prednisolone daily) had just been started before the fundal photograph in Fig. 1. Her disease responded to treatment and 4 months later when the general disease activity had decreased (though she still had some skin rash) the cytooid bodies had nearly disappeared from both fundi.

Table Clinical features of 10 patients with scleroderma

Case no.	Sex	Clinical features	Blood pressure (mmHg)	Fundus	KCS	Retinal vasculature	Choroidal vasculature	Therapy
1	M	Diffuse cutaneous (rapidly progressive), Raynaud's phenomenon, polyarthralgia	120/75	Normal	No	Normal	Patches of choroidal underperfusion	Nil
2	M	Diffuse cutaneous (rapidly progressive), oesophageal involvement	160/100	"	"	Venular dilatations	Normal	Penicillamine 600 mg
3	F	Diffuse cutaneous (rapidly progressive), oesophageal involvement, pulmonary, Raynaud's phenomenon, telangiectasia	130/90	"	"	Normal	Patches of choroidal underperfusion	Penicillamine 1g
4	F	Acroscleriosis (slowly progressive), Raynaud's phenomenon, pulmonary involvement, polyarthritis	150/90	"	"	"	Normal	Ibuprofen
5	M	Sclerodactyly (slowly progressive), Raynaud's phenomenon, oesophageal involvement	180/100	"	"	"	"	Nil
6	F	Acroscleriosis (slowly progressive), Raynaud's phenomenon, polyarthritis, oesophageal involvement, telangiectasia	160/100	"	"	"	"	Salicylates
7	F	Sclerodactyly (slowly progressive), Raynaud's phenomenon, small intestinal involvement	90/70	"	Yes	—	—	Nil
8	F	Sclerodactyly (slowly progressive), calcinosis, Raynaud's phenomenon, telangiectasia, oesophageal involvement	180/80	"	No	Normal	Patches of choroidal underperfusion	Nil
9	F	Sclerodactyly (slowly progressive), calcinosis, oesophageal involvement	160/100	"	No	"	"	Nil
10	F	Sclerodactyly (slowly progressive), Raynaud's phenomenon, polyarthritis, telangiectasia	140/80	"	Yes	"	"	

KCS=keratoconjunctivitis sicca.

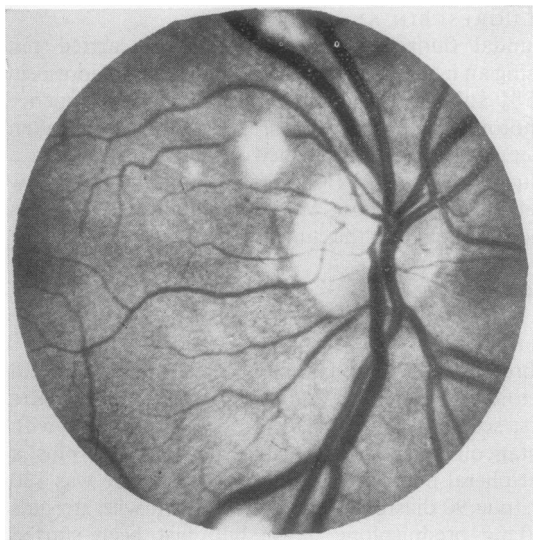


Fig. 1 *Right fundus of a patient with active SLE showing cytotoid bodies.*

Among the 12 patients who had fluorescein angiography, abnormalities of dye perfusion in the retinal vessels were seen in only one patient who was also the patient with visible fundal lesions shown in Fig. 1. Fig. 2 shows the 11-second fluorescein angiogram of the right fundus in the arteriolar phase

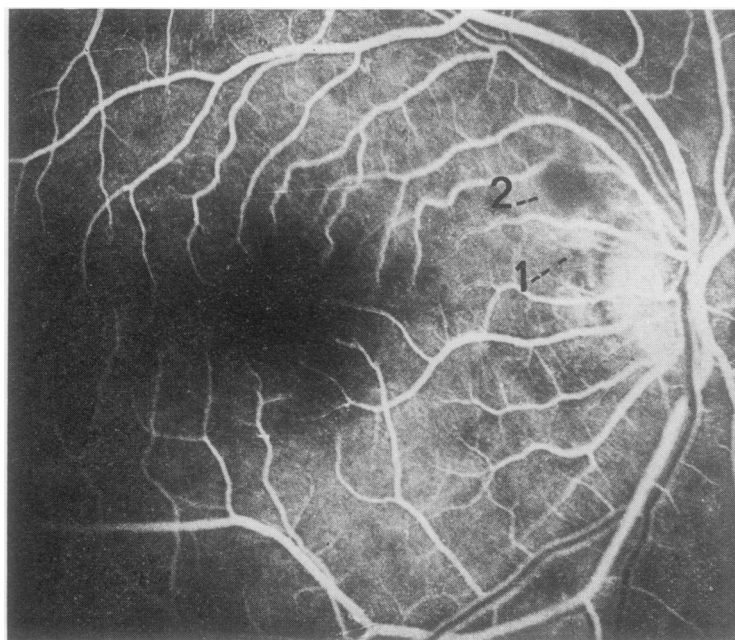


Fig. 2 *11-second fluorescein angiogram of the right fundus in the early venous phase of a patient with active SLE and cytotoid bodies. (1) Area of capillary leakage adjacent to (2) the cytotoid body.*

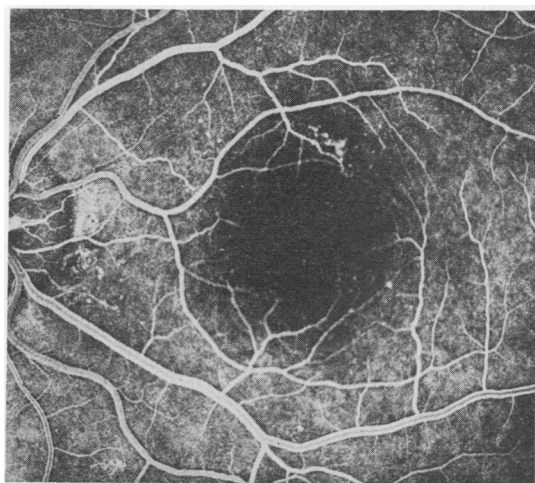
where areas of dye leakage from the retinal capillaries near the disc are apparent. The areas are adjacent to the avascular infarcted areas which correspond to the cytotoid bodies of Fig. 1. Similar but less marked areas of leakage were also seen in the left fundus. No abnormalities of choroidal perfusion were seen in these 12 patients with SLE.

#### SCLERODERMA

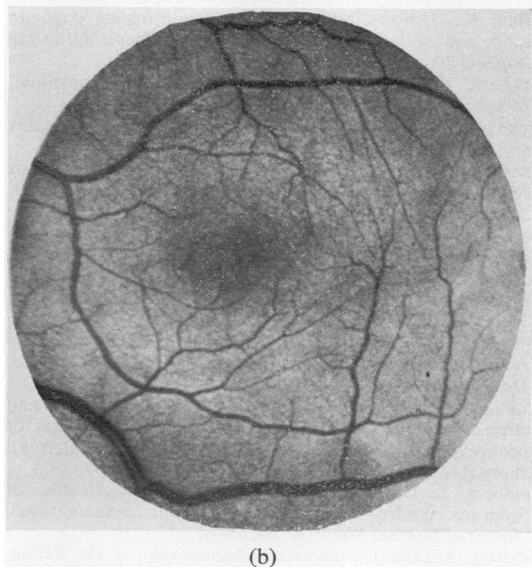
Two of the 10 scleroderma patients had KCS. The fundi of all 10 showed no abnormality on ophthalmoscopy. Fluorescein angiography, however, showed abnormalities in the retinal vasculature in one patient and in the choroidal vasculature in 5 of the 10 patients. Case 2 (Table) showed microaneurysmal dilatation of the terminal venules of the superotemporal retinal veins (macular branch) (Fig. 3). Fluorescein dye stained the wall of the vessel as shown by persistence of staining into the late stages of dye passage, but there was no leakage of dye from the vessel. A similar microvascular abnormality was seen in the small peripapillary arterioles at 5 o'clock on the disc.

In 5 patients there were patchy areas of non-perfusion of the choroidal capillary bed which persisted in all cases for over 5 seconds and in 3 cases for more than 8 seconds (Fig. 4). Filling of these areas with dye eventually occurred by diffusion of fluorescein from the normally leaking choriocapillaris of healthy adjacent areas. All 3 patients with

aggressive generalized scleroderma had some abnormality on fluorescein angiography, 2 showing abnormal choroidal vessels and one showing abnormal retinal vessels. The 3 other patients with abnormal choroidal vasculatures had fairly benign disease. One patient with abnormal choroidal vessels had a raised blood pressure (160/100 mmHg). Patchy choroidal ischaemia did not interfere with either visual acuity or visual fields.



(a)



(b)

Fig. 3 (a) 12.5-second fluorescein angiogram in the midvenous phase of the one patient with scleroderma and retinal vascular abnormalities. There is microaneurysmal dilatation of the superotemporal retinal vein which is not apparent on funduscopy (b).

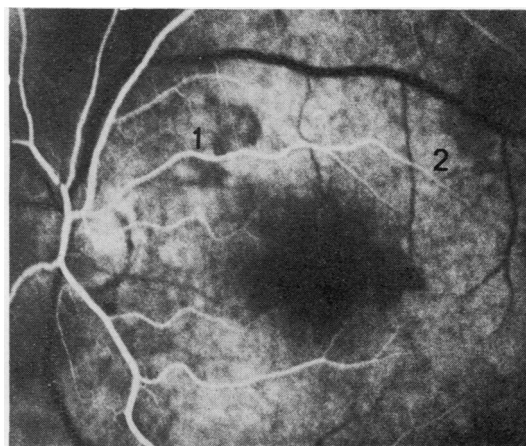


Fig. 4 6-second fluorescein angiogram of a patient with scleroderma in the retinal arteriolar phase shows back-ground fluorescence from the normal choroid surrounding areas of nonperfusion of dye (1,2).

## Discussion

Keratoconjunctivitis sicca has been reported previously in both SLE and scleroderma (Steinberg and Talal, 1971; Whaley *et al.*, 1973; Alarcon-Segovia *et al.*, 1974). In the series of Alarcon-Segovia *et al.*, 6 of 25 patients with scleroderma had abnormal Schirmer and Rose bengal staining tests, thus satisfying our criteria for KCS, and this is roughly equivalent to its incidence in our smaller series. In addition to showing reduced tear flow plus typical staining of the conjunctival epithelium with Rose bengal dye, 3 of our cases (2 SLE, 1 scleroderma) had filamentary keratopathy. 2 further SLE patients, not included in the KCS group, had reduced tear flow but there was no uptake of Rose bengal dye. No blepharophimosis, cataract, or disturbances of ocular mobility was found in any of the scleroderma patients.

The incidence of fundal lesions in SLE has been variously reported at 5% (Lachman and Hazelman, 1975) and 9.3% (Dubois and Tuffanelli, 1964). In our series only one of more than 22 patients with SLE had fundal abnormalities (Fig. 1) which correlated with the fluorescein angiographic appearance of altered retinal vascular haemodynamics, including obliteration of the small arterioles (Fig. 2). This patient had active systemic disease at the time. None of our patients had known cerebral lupus, so our findings do not conflict with those of Edmonds *et al.* (1975) regarding the potential usefulness of this technique in the assessment of patients with suspected cerebral lupus. However, we were unable to show fluorescein angiographic abnormalities in any

case with normal fundi and low disease activity, in contrast to others (Lachman and Hazleman, 1975). We will continue to assess this technique where possible in patients with exacerbations of SLE. No choroidal vasculature abnormalities were found in the SLE patients.

In the scleroderma group no cases of retinopathy were found on ophthalmoscopy, confirming the report of Kirkham (1969) who studied 10 cases. Previous case reports of retinopathy were associated with significant degrees of hypertension (Josten, 1958; Pollack and Becker, 1962; Ashton *et al.*, 1968), and a true correlation with scleroderma could not be made. However, the most significant finding in our study was of abnormalities of choroidal perfusion affecting the choriocapillaris and small choroidal arterioles in 5 out of 10 cases with scleroderma as shown by fluorescein angiography. Only one of these patients had a diastolic blood pressure over 90 mmHg, suggesting that the abnormalities were not related to systemic hypertension. Previous histological studies have shown thickening of the basement membrane of the precapillary arteriole plus endothelial swelling with obliteration of the lumen of the vessel and areas of infarction in the choroid (MacLean and Guthrie, 1969; Farkas *et al.*, 1972). Arterioles elsewhere in the body may also be obliterated in scleroderma (Rodnan, 1963). Although other authors have noted that a clear distinction could not be made between the choroidopathy of scleroderma and that of malignant hypertension since they studied post-mortem eyes, often in previously hypertensive patients, the pathology seemed sufficiently out of proportion to the degree of hypertension noted to merit a tentative correlation with scleroderma. Our findings of patchy choroidal ischaemia are in keeping with this. These findings were noted in 3 patients with benign variants of scleroderma as well as in the 2 with aggressive disease.

The significance of the retinal microvascular abnormality recorded in Case 2 (Fig. 3) is not clear, as it was not found in the other cases of scleroderma, and has not been reported before. Its relevance therefore is dubious.

One characteristic of scleroderma may be a generalized vascular abnormality which as Norton and Nardo (1970) have suggested could be a primary factor in the pathogenesis of the disease. In view of the apparent frequency of choroidal vascular abnormalities in this preliminary series of patients with scleroderma, we suggest that fluorescein angiography may prove to be a useful additional method of characterizing patients with early connective tissue disease, although further study of larger numbers of patients is now required.

D.M.G. is a Robins Clinical Research Fellow. We are grateful to Professor W. S. Foulds for advice and helpful comments.

#### References

- Alarcon-Segovia, D., Ibanez, G., Hernandez-Ortiz, J., Velazquez-Forero, F., and Gonzalez-Jimenez, Y. (1974). Sjögrens syndrome in progressive systemic sclerosis (scleroderma). *American Journal of Medicine*, **57**, 78–82.
- Ashton, N., Coomes, E. N., Garner, A., and Oliver, D. O. (1968). Retinopathy due to progressive systemic sclerosis. *Journal of Pathology and Bacteriology*, **96**, 259–268.
- Cohen, A. S., Reynolds, W. E., Franklin, E. C., Kulka, T. P., Ropes, M. W., Shulman, L. E., and Wallace, S. L. (1971). Preliminary criteria for the classification of systemic lupus erythematosus. *Bulletin on Rheumatic Diseases*, **21**, 643–648.
- Dolfus, M. A. (1958). A further case of scleroderma 'en coup de sabre' with multiple ocular lesions progressing for more than 12 years. *Bulletin de la Société Belge d'Ophthalmologie*, **118**, 377–379.
- Dubois, E. L., and Tuffanelli, D. L. (1964). Clinical manifestations of systemic lupus erythematosus. *Journal of the American Medical Association*, **190**, 104–111.
- Edmonds, J. P., Bruneau, C., and Hughes, G. R. V. (1975). Assessment of activity in SLE: a clinical and serological study. (Abst.) *Annals of the Rheumatic Diseases*, **34**, 543–544.
- Farkas, T. G., Sylvester, V., and Archer, D. (1972). The choroidopathy of progressive systemic sclerosis (scleroderma). *American Journal of Ophthalmology*, **74**, 875–886.
- Hammanis, H., and Streiff, E. B. (1973). Vascular retinal alteration in a case of disseminated lupus erythematosus. *Ophthalmologica*, **166**, 16–35.
- Hughes, G. R. V. (1971). Significance of anti-DNA antibodies in systemic lupus erythematosus. *Lancet*, **2**, 861–863.
- Josten, K. (1958). Circumscribed scleroderma en coup de sabre and ocular involvement. *Klinische Monatsblätter für Augenheilkunde*, **133**, 567–568.
- Kirkham, T. (1969). Scleroderma and Sjögrens syndrome. *British Journal of Ophthalmology*, **53**, 131–133.
- Lachmann, S., and Hazleman, B. (1975). Rheumatic diseases and the eye. *Hospital Update* (October), 617–633.
- MacLean, H., and Guthrie, R. (1969). Retinopathy in scleroderma. *Journal of the Ophthalmological Society*, **89**, 209–212.
- Manschot, W. A. (1965). Generalised scleroderma with ocular symptoms. *Ophthalmologica*, **149**, 131–137.
- Norton, W. L. and Nardo, J. M. (1970). Vascular disease in progressive systemic sclerosis. *Annals of Internal Medicine*, **73**, 317–324.
- Pollack, I. P., and Becker, B. (1962). Cytoid lesions of the retina in a patient with scleroderma. *American Journal of Ophthalmology*, **54**, 655–660.
- Rodnan, G. P. (1963). A review of recent observations and current theories on the aetiology and pathogenesis of progressive systemic sclerosis (diffuse scleroderma). *Journal of Chronic Diseases*, **16**, 929–949.
- Steinberg, A. D., and Talal, N. (1971). The coexistence of Sjögrens syndrome and systemic lupus erythematosus. *Annals of Internal Medicine*, **74**, 55–61.
- Wessing, A. (1969). *Fluorescein Angiography of the Retina*. Mosby, St. Louis.
- Whaley, K., Webb, J., McAvoy, B. A., Hughes, G. R. V., Lee, P., MacSween, R. N. M., and Buchanan, W. W. (1973). Sjögren's syndrome. 2. Clinical associations and immunological phenomena. *Quarterly Journal of Medicine*, **42**, 513–548.