

THERAPY OF "FELTY'S SYNDROME"

BY

PHILIP ELLMAN, LEON CUDKOWICZ, AND J. STANLEY ELWOOD

From the Rheumatism Unit and Department of Pathology, St. Stephen's Hospital, London

(RECEIVED FOR PUBLICATION AUGUST 19, 1954)

The incidence of normocytic hypochromic anaemia in rheumatoid disease is very high (Nilsson, 1948; Empire Rheumatism Council Scientific Advisory Committee, 1950; Jeffrey, 1952); while its aetiology is obscure, its severity appears to fluctuate with exacerbations of joint swellings (Kahlmeter, 1922; Nilsson, 1948). Occasionally the anaemia has the additional feature of a severe leucopenia, and if this becomes associated with progressive arthritis and splenomegaly, as was first noted by Chauffard and Ramond (1896), the clinical syndrome described by Felty (1924) emerges. This symptom complex is comparatively rare and has only been seen three times in this unit during the last 3 years. The reports in the literature of "Felty's syndrome" similarly comprise only small series (Singer and Levy, 1936; Edström, 1941; Talkov, Bauer, and Short, 1942; Trolle and Trolle, 1943; Dameshek, 1944; Hatch, 1945; Hirschboek, 1946; Nyström, 1946; Cole, Walter, and Limarzi, 1949; Hutt, Richardson, and Staffurth, 1951).

The duration of the rheumatoid disease and the onset of the clinical manifestations of "Felty's syndrome" are not significantly related. Hutt and others (1951) reported four cases in which the time interval varied between 7 and 29 years. Similarly no specific age incidence was found by these authors. A predominance of this syndrome in females is noted, but rheumatoid disease is usually more common in women.

Certain unusual clinical manifestations encountered in the course of rheumatoid disease suggest the possible presence of "Felty's syndrome". Refractory anaemia, recurrent disabling infections, and buccal and other mucosal ulcerations may suggest pancytopenia or agranulocytosis in view of the numerous drugs used in the management of rheumatoid disease. The agranulocytosis may be cyclical and associated with splenomegaly (Löffler and Maier, 1947). Hutt and others (1951) recorded two cases of "Felty's syndrome" presenting corneal ulceration, and one with ulceration of the legs. They also

referred to the records of two other patients in their hospital who apparently suffered from severe keratitis.

In patients with "Felty's syndrome", leucopenia is associated with splenomegaly and normal maturation of granulocytes in the bone marrow, unlike agranulocytosis. Marrow hypoplasia with leucopenia which improved with splenectomy was, however, observed by Rogers and Langley (1950). The peripheral blood findings are variable, but a severe granulopenia with total white cell counts varying from 800 to 3,500 was noted by Hutt and others (1951). Thrombocytopenia is not uncommon, and haemorrhagic features were reported by Dameshek (1944).

Present Investigations

This paper records the clinical management of three cases of this syndrome.

Case 1, a male aged 49, gave a history of rheumatoid disease affecting the left knee and both wrists for the past 10 years. He had also had psoriasis for many years. More recently he had developed progressive diarrhoea which occasionally contained blood. On examination, the most striking findings, apart from the joint lesions, were splenomegaly, anaemia, and leucopenia. Sigmoidoscopy did not reveal any abnormality in the colon.

The diagnosis of "Felty's syndrome" was made and whole blood was given in preparation for splenectomy. The clinical course of this patient before splenectomy was dominated by neutropenia which persisted in spite of transfusion and necessitated operation (Fig. 1, opposite). L.E. cells were not found.

Operation.—An enlarged but otherwise normal spleen was removed.

Effects of Splenectomy.—Splenectomy controlled the anaemia (one year later the haemoglobin was 13 g. per cent.), no further blood transfusions were required and the leucocytes rose to 16,000 per c.mm. on the 16th post-operative day. They gradually fell and a moderate leucocytosis persisted for a year. With the restoration of the patient's white cell count his general health improved and his arthritis remitted.

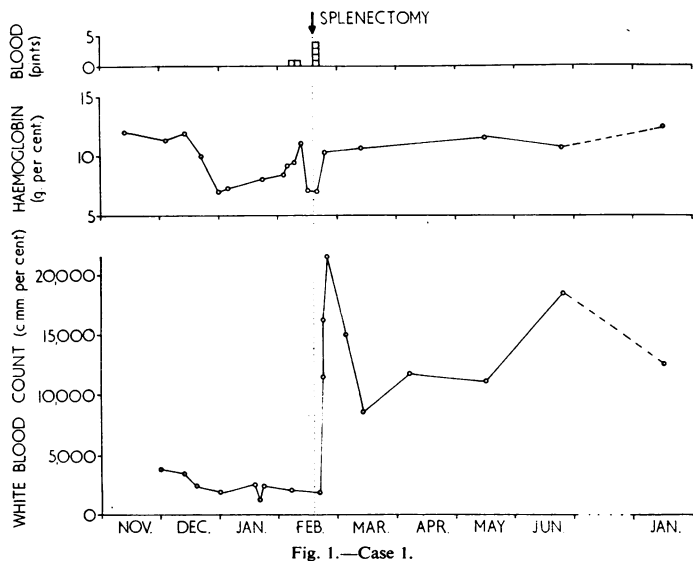


Fig. 1.—Case 1.

Case 2, a female aged 66, gave a history of severe pain and swelling of the elbows, wrists, proximal interphalangeal joints, and knees for the past 6 years. There had been much loss of weight. Typical rheumatoid changes were found in both elbows, wrists, and knees, and in all proximal interphalangeal joints; an old congenital dislocation of the left hip joint was also present. Emaciation, splenomegaly, neutropenia, and anaemia were the other findings of note.

In spite of whole blood transfusion and intravenous iron, improvement in the anaemia and white cell count was only temporary. The marrow was cellular and micronormoblastic. A weakly positive occult blood test on the stool was not considered a suitable explanation for the persistent fall of haemoglobin. Haemolysis could not be excluded, but the survival time of transfused red cells appeared to be normal over a period of 14 days.

In an attempt to stem her downhill course and prepare her for splenectomy a short course of 900 mg. ACTH and multiple transfusions were given over a period of 9 days, during which the white cell count remained unchanged and the haemoglobin showed only a slight rise—probably due to transfusion (Fig. 2).

While clinically the diagnosis was apparent at the time of her out-patient attendance, her general condition, and particularly the refractory anaemia, created many obstacles before splenectomy could be contemplated. Liver palms, spidery naevi, enlarged abdominal veins (seen by infrared photography), and oesophageal varices suggested additional liver disease with portal hypertension. During a liver biopsy

the liver felt hard and was penetrated with some difficulty, but the piece of liver obtained appeared normal. Liver function tests showed parenchymal liver damage.

Operation.—The liver appeared to be fibrotic. The biopsy macroscopically suggested cirrhosis, but microscopically there was some increase in periportal fibrous tissue only and moderate infiltration of the portal tracts with lymphocytes.

The spleen was enlarged, its surface was mottled, and some adhesions were present. The cut surface showed an indistinct pattern with some fibrosis of the pulp. Histological examination showed fibrosis of the sinusoids with scanty infiltration by histiocytes, some plasma cells and lymphocytes, and scanty eosinophils. The Malpighian bodies were small and atrophic. Frequent foci of fibrosis and haemosiderin-laden macrophages were noted.

Post-Operative Course.—Following splenectomy this patient's haemoglobin rose to 11 g. per cent., the white cells to 8,000 per c.mm., and the platelets to 220,000 per c.mm.; 50 days later the haemoglobin began to fall and the rheumatoid arthritis became active again. She was then given a second course of ACTH totalling 700 mg. over 7 days; this was followed 12 days later by another course of 750 mg. lasting 10 days. While the patient improved subjectively, there was no immediate significant change in the blood picture. It is of interest, however, that less than a month after the cessation of

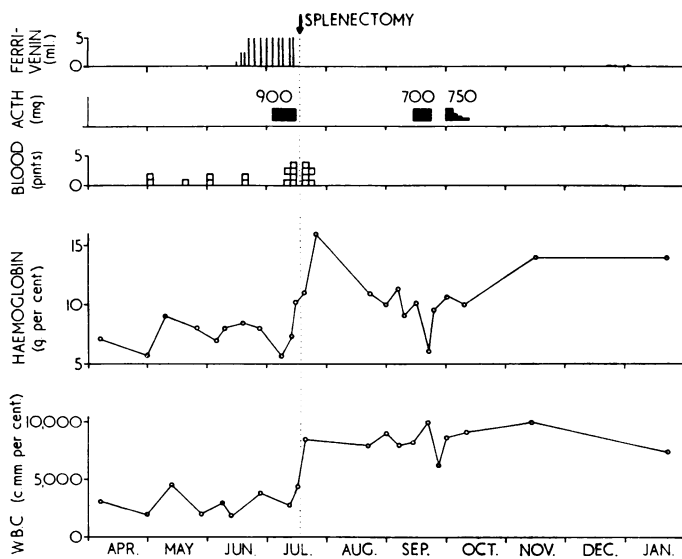


Fig. 2.—Case 2.

ACTH both the haemoglobin and the white blood count rose rapidly to 14 g. per cent. and 10,000 per c.mm. respectively without further need of specific therapy, and these levels were maintained for 6 months until the patient's death (Fig. 2). While the plasma proteins showed little change, some deterioration in liver function tests suggested progressive liver disease. Subjectively the patient was markedly improved and able to walk once more after many years of crippledom, but she succumbed, 6 months later, with a pontine haemorrhage.

Case 3, a female aged 57, suffered from rheumatoid disease for 14 years which affected principally the elbows, wrists, metacarpo-phalangeal joints, and the right knee. At the time of admission she was emaciated and had multiple septic lesions affecting the skin over the left external malleolus, right great toe, and right tibia. Melaena was also present.

On examination signs of rheumatoid involvement of the aforementioned joints were seen and splenomegaly was noted. Severe anaemia, leucopenia, and thrombocytopenia were found. Sigmoidoscopy showed mucosal oozing only. The melaena demanded rapid transfusion and 8 pints of blood were given without immediate improvement. However, after a further 4 pints of blood the melaena ceased. As the peripheral blood was megalocytic, a sternal marrow puncture was carried out, which showed marked megaloblastic degeneration of the marrow. Vitamin B₁₂ was then given in doses of 200 µg. weekly for 2 weeks, and then 300 µg. weekly for a further 2 weeks. The failure of the red cell count to rise in the presence of a reticulocytosis of 15 per cent. excluded a typical pernicious anaemia (achlorhydria was present). No evidence of haemolysis was found, the serum bilirubin excretion were normal, and the direct Coombs test was negative. While she was receiving vitamin B₁₂, the platelet count rose from 75,000 to 144,000 per c.mm., but the total white cell count remained at the level attained by transfusion alone (between 3,000 and 4,000 per c.mm.). The marrow, however, reverted to normoblastic and remained so for about 4 months after cessation of B₁₂ therapy. An interesting feature was the presence of giant multinucleated megaloblasts in the earlier films and normoblasts in subsequent films. This feature persisted throughout the period of observation. L.E. cells were not found.

While the haemoglobin increased by 3 g. (from 9 to 12) per cent. and the platelets increased from 75,000 to 144,000 per c.mm. during B₁₂ therapy, the total white cell count was uninfluenced.

After 4 weeks of continuous B₁₂ therapy it was found that the leucocytes remained at a level between 3,000 and 4,000 per c.mm. (with the exception of one short interval), and similarly the haemoglobin level remained between 9 and 10 g. per cent. 920 mg. ACTH were then given over a period of 13 days; this caused the haemoglobin to rise from 10 g. to 11.8 g. per cent., the white cells from 3,000 to 6,100 per c.mm., and the platelets from 110,000 to 180,000 per c.mm. The reticulocytes, formerly about 2 per cent., rose to 5 per cent. These levels did not persist and were only reached again after splenec-

tomy, which was carried out to prevent renewed leucopenia after cessation of ACTH. This, in fact, was probable as the white cells fell again just before splenectomy (Fig. 3, opposite). The patient's liver function tests were as follows:

Total serum protein	..	4.8	per cent.
Albumin	..	2.8	per cent.
Globulin	..	2.0	per cent.
A/G ratio	..	1.4	
Serum bilirubin	..	0.6	mg. per cent.
Zinc turbidity	..	4.5	units
Thymol turbidity	..	4	units
Alkaline phosphatase	..	4.2	units (King-Armstrong)

The increased urinary urobilinogen suggested the possibility of portal hypertension and cirrhosis, but a pre-operative punch biopsy of the liver was normal.

Operation.—An enlarged but otherwise normal liver was found; and histological examination showed slight focal fatty change of the parenchymal cells only. The spleen weighed 570 g. Its capsule was smooth with an occasional area of perisplenitis and fibrinous exudate. The cut surface was uniformly red with distinct, small, and widely-scattered Malpighian bodies. Histologically the pulp showed some fibrosis and considerable infiltration by histiocytes, lymphocytes, plasma cells, and eosinophils. The Malpighian bodies were large and contained prominent germinal centres.

Post-Operative Course.—Splenectomy had no effect on the haemoglobin level; the leucocytes, formerly never above 8,200 per c.mm., after splenectomy and during a mild post-operative infection, rose to 17,800 per c.mm. The platelets, 180,000 per c.mm. pre-operatively, rose to 300,000 per c.mm. post-operatively, falling later to 233,000.

The marrow remained normoblastic for 4 months when macronormoblastic change was seen. Although it was difficult to see why there should have been a deficiency of folic acid, the diet and fat balance (28 g. total fat per 100 g. dried faeces) being normal, 10 mg. folic acid were given daily; in spite of a reticulocytosis of 8 per cent., however, there was no significant change in the total red cell count and haemoglobin. One month after beginning folic acid therapy the marrow was found to be normoblastic.

The liver function tests showed some further deterioration. The total plasma proteins rose with the improvement in the anaemia, but the A/G ratio deteriorated as did the parenchymal liver function tests. Splenectomy did not bring about any change in the reticulocytes.

The general condition improved after operation, and the patient was able to go to a convalescent home as an ambulant and self-sufficient person. Here for 4 months her condition was satisfactory and improvement continued. Death, however, occurred after a short acute illness.

Post-mortem Examination.—An acute fibrinous pericarditis was found, the pericardial sac containing some yellowish-green pus, and the visceral pericardium showing some irregular patches of yellow deposit which were

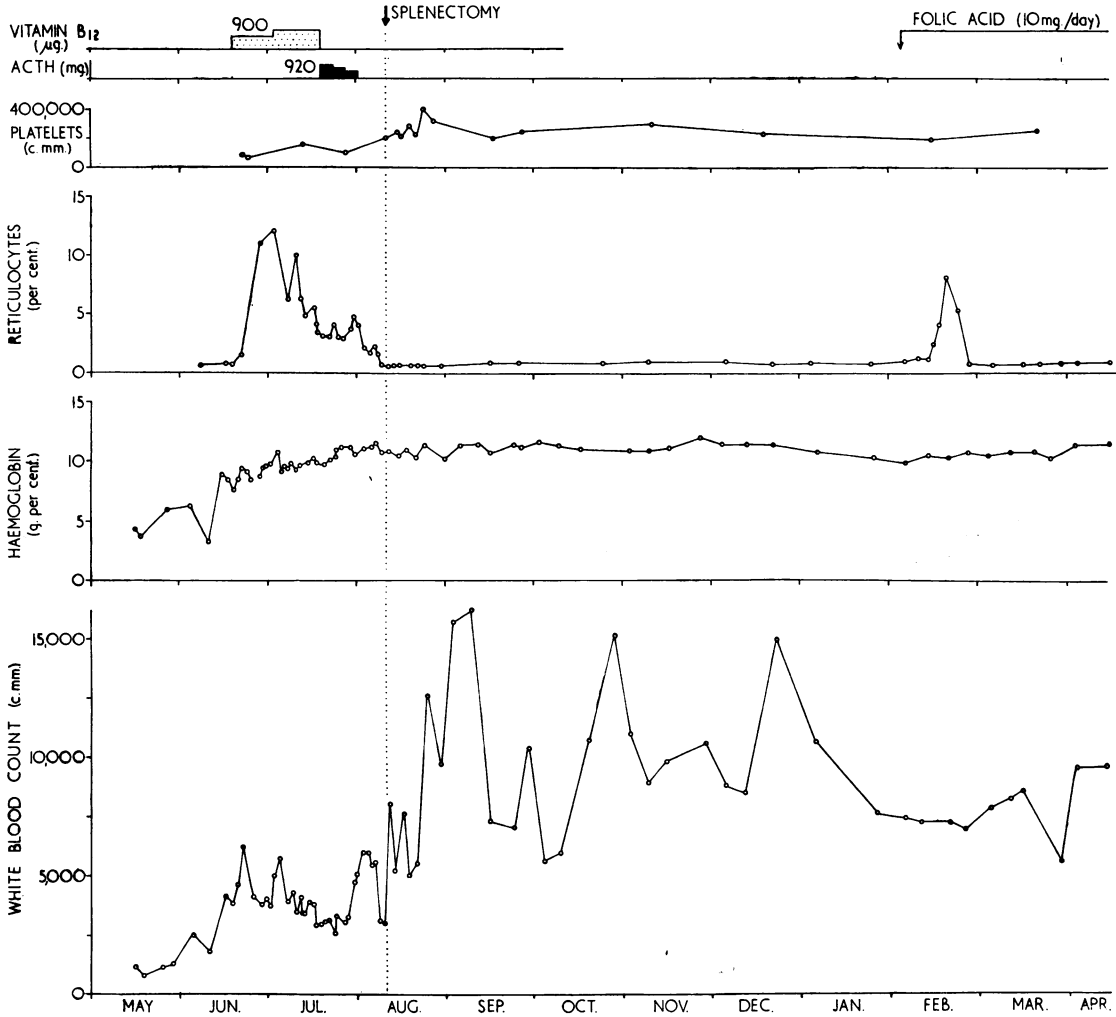


Fig. 3.—Case 3.

almost crystalline in appearance. Histological examination showed non-specific inflammatory changes only, and culture of the pus grew a few coliform bacilli.

The only other significant finding was an enlargement of the aortic lymph nodes which were red in colour; histological examination showed active haemopoiesis. Three small spleniculi (together weighing 5 g.) were present in the splenic bed; histologically these were essentially the same as the spleen removed at operation. The liver was enlarged (2,286 g.) and mottled; histological examination showed some fibrosis and chronic inflammatory cell infiltration of the portal tracts and zonal necrosis of the parenchyma consistent with congestive cardiac failure. A small collection of pus, which grew coagulase positive *Staph. pyogenes*, was present in the middle cranial fossa. A healed subchronic gastric ulcer was present in the pyloric canal.

Discussion

The experience gained from these three cases counsels splenectomy as the only therapy so far known to arrest the blood dyscrasia and restore the peripheral blood picture in "Felty's syndrome".

In Cases 1 and 2 agranulocytosis was excluded by marrow puncture. In Case 3 the marrow was megaloblastic but did not show a primary defect of granulopoiesis. After the marrow reverted to normoblastic following B₁₂ therapy, the total number of white cells in the peripheral blood stayed low until after splenectomy. The granulopenia seen in this disease cannot, therefore, be attributed to faulty granulopoiesis and its cause should probably be sought in the concomitant hypersplenism.

Case 3 presented with a pancytopenia, not unlike that described by Doan and Wright (1946), who thought that this was a manifestation of "splenic overaction". The assumption that hypersplenism was responsible for the blood changes in our three cases is probably correct, particularly as the peripheral blood reverted to nearly normal after splenectomy.

We have no explanation to offer regarding the precise mechanism of hypersplenism in "Felty's syndrome". Hirschboeck (1946) discusses two explanations of the accompanying phenomena: the one suggests that the bone marrow may become inhibited by some hormonal factor related to the enlarged spleen, the other that leucopenia results from increased splenic phagocytosis (Wiseman and Doan, 1939).

The possibility that these cases might well be variant patterns of disseminated lupus erythematosus had been considered, but the absence of cutaneous, visceral, and urinary manifestations, and the failure to find L.E. cells in Cases 1 and 3 made this diagnosis improbable. The response to ACTH was poor, and splenectomy became imperative in order to arrest further clinical deterioration.

The possibility that haemolysis plays a part in these cases has not been excluded. The anaemia associated with rheumatoid disease constitutes a separate problem, but Jeffrey (1952) found no haemolysis in anaemic patients with rheumatoid arthritis. Nilsson (1948) thought that disturbances in haemoglobin synthesis resulted from failure of iron utilization and absorption, and he found it rare for serum iron to be above 35 μ g. even after intravenous iron. It is improbable that in "Felty's syndrome" a primary defect of haemoglobin synthesis is solely responsible for the anaemia, which probably also has a haemolytic element. This latter possibility was borne out in our cases by the rapid relapse of the anaemia after massive transfusions.

The aetiology of portal hypertension in "Felty's syndrome" remains obscure. Hepatosplenomegaly is a not uncommon finding in rheumatoid disease, and Schlesinger (1949) found it present in 50 per cent. of his series of cases of Still's disease. It can thus be regarded as part of the rheumatoid process, although not associated with any specific pathological appearances.

Splenic enlargement is often associated with portal hypertension, but "hypersplenism" is unusual in simple portal hypertension and it would appear that hypersplenism may be the end result of reticulo-endothelial hyperplasia consequent upon a very chronic inflammatory condition, in this case rheumatoid disease.

That progressive liver damage was in fact taking place is evidenced by the deterioration of liver function in Case 2, and it was to be expected in Case 3 as portal hypertension was evidenced by distended abdominal veins and oesophageal varices. It is unfortunate that two of our cases have died. The cause of death in Case 2 was probably unrelated to her rheumatoid disease, but in Case 3 the acute pericarditis was clearly the immediate cause of death. This was not found to be bacterial in origin, and, although of non-specific inflammatory type, is probably rheumatoid in origin. Pericarditis is a recognized complication of rheumatoid disease (Ellman, Cudkovicz, and Elwood, 1954).

Hanrahan and Miller (1932) reported satisfactory improvement both in the blood picture and in the joint manifestations following splenectomy. It appears to us that splenectomy is still the treatment of choice to be carried out as soon as the patients are fit enough for surgery. The subjective improvements in the joints in our three patients developed gradually; they were not directly related to splenectomy but occurred as soon as the general health improved. The use of iron, vitamin B₁₂, folic acid, hormones, and blood transfusion can only be regarded as ancillary aids; in Case 2 transfusion alone was by far the most important single form of therapy permitting the patient to come to surgery.

Summary

Three cases of "Felty's syndrome" are described. Of the various forms of therapy tried blood transfusion was found to be the most important ancillary aid, but only splenectomy gave any degree of immediate relief.

The pathogenesis of the condition is briefly discussed.

We are indebted to Dr. J. V. Dacie of the Department of Haematology, Post-Graduate School of Medicine, London, for his valuable help in connexion with Case 3; to Dr. A. Dolphin, Consultant Physician to Mile End Hospital, for permitting us to include Case 1, seen repeatedly by one of us (P.E.) in consultation; and to Dr. A. G. Signy, Director of the Group Laboratory, St. Mary Abbott's Hospital, London, for his help in the pathological sphere.

REFERENCES

- Chauffard, A., and Ramond, F. (1896). *Rev. Med.*, 16, 345.
 Cole, W. H., Walter, L., and Limarzi, L. R. (1949). *Ann. Surg.*, 129, 702.
 Dameshek, W. (1944). "The Oxford Medicine", ed. H. A. Christian, vol. 2, p. 841.
 Doan, C. A., and Wright, C. S. (1946). *Blood*, 1, 10.
 Edström, G. (1941). *Nord. Med.*, 10, 1873.
 Ellman, P., Cudkovicz, L., and Elwood, J. S. (1954). *J. clin. Path.*, 7, 239.

- Empire Rheumatism Council Scientific Advisory Committee (1950). "Report on an Enquiry into the Aetiological Factors Associated with Rheumatoid Arthritis", prepared by E. Lewis-Faning. Suppl. *Annals of the Rheumatic Diseases*, vol. 9.
- Felty, A. R. (1924). *Johns Hopk. Hosp. Bull.*, 35, 16.
- Hanrahan, E. M., and Miller, S. R. (1932). *J. Amer. med. Ass.*, 99, 1247.
- Hatch, F. N. (1945). *Ann. intern. Med.*, 23, 201.
- Hirschboeck, J. S. (1946). *Blood*, 1, 247.
- Hutt, M. S. R., Richardson, J. S., and Staffurth, J. S. (1951). *Quart. J. Med.*, 20, 57.
- Jeffrey, M. R. (1952). *Annals of the Rheumatic Diseases*, 11, 162.
- Kahlmeter, G. (1922). *Acta med. scand.*, Suppl. 3 "Verh. 10 nord. Kongr. Inn. Med.", p. 265.
- Löffler, W., and Maier, C. (1947). *Cardiologia (Basel)*, 12, 195.
- Nilsson, F. (1948). *Acta med. scand.*, Suppl. 210, p. 185.
- Nyström, G. (1946). *Nord. med.*, 32, 2567.
- Rogers, H. M., and Langley, F. H. (1950). *Ann. intern. Med.*, 32, 745.
- Schlesinger, B. (1949). *Brit. med. J.*, 2, 197.
- Singer, H. A., and Levy, H. A. (1936). *Arch. intern. Med.*, 57, 576.
- Talkov, R. H., Bauer, W., and Short, C. L. (1942). *New Engl. J. Med.*, 227, 395.
- Trolle, E., and Trolle, D. (1943). *Nord. Med.*, 18, 757.
- Wiseman, B. K., and Doan, C. A. (1939). *J. clin. Invest.*, 18, 473.

Traitement du syndrome de Felty

RÉSUMÉ

On décrit trois cas de syndrome de Felty. Parmi toutes les formes de traitement essayées, la transfusion sanguine s'est montré le remède adjuvant le plus important, mais la splenectomie seule produisait un soulagement immédiat appréciable.

On discute brièvement la pathogénie de cet état.

Terapia del síndrome de Felty

SUMARIO

Se describe tres casos de síndrome de Felty. De todas las formas de tratamiento ensayadas, la trasfusión de sangre reveló su suma importancia como remedio coadyuvante, mas la esplenectomia sola produjo un alivio inmediato apreciable.

Se discute brevemente la patogenesis de esta condición.