

# UVEITIS AND RHEUMATIC DISEASES

BY

A. STANWORTH AND J. SHARP

*Departments of Ophthalmology and Rheumatology, University of Manchester*

(RECEIVED FOR PUBLICATION FEBRUARY 17, 1956)

## Historical Survey

Many isolated examples of the association of uveitis and rheumatic diseases occur in the literature, but there have been few attempts to assess the extent of this association.

**Rheumatic Diseases in Uveitis.**—Some of the series of patients with uveitis in whom the incidence of rheumatic diseases has been investigated are shown in Table I. The reported incidence of

spondylitis varies from 2.4 to 25.6 per cent., and it is probably significant that Vesterdal (1951) found that the incidence increased from 5.7 to 20 per cent. when routine radiographs of the sacro-iliac joints and spine were taken. Iritis has been reported as the initial manifestation of ankylosing spondylitis by Teschendorf (1933), Birkbeck, Buckler, Mason, and Tegner (1951), Forestier (quoted by Romanus, 1953), and Romanus (1953).

Vesterdal (1951), who found rheumatoid arthritis

TABLE I  
INCIDENCE OF RHEUMATIC DISEASE IN PATIENTS WITH UVEITIS

| Author                        | Date | Type of Investigation for Rheumatic Diseases                       | Type of Uveitis   | No. of Patients           | Rheumatic Diseases Found   |     |   |
|-------------------------------|------|--|---|---------------------------|--|-----|---|
|                               |      |  |   |                           | Disease  | No. | Per cent.                                 |
| Schley                        | 1937 | Clinical, with radiographs of great majority                       | Diffuse superficial iritis  | 73                        | Ankylosing spondylitis   | 10  | 13.7                                      |
|                               |      |  | Focal uveitis   | 32                        | Spondylosis deformans  | 40  | 55  |
| Guyton and Woods              | 1941 | No special examination   | All types   | 562 in-patients (1925-39) | Spine normal   | All |   |
|                               |      |  |   |                           | "Infectious arthritis"   | 8   | 1.4                                       |
| Berens, Rothbard and Angevine | 1942 | Not stated   | Acute or chronic uveitis  | 63                        | Acute rheumatic fever  | 3   | 0.5                                       |
|                               |      |  |   |                           | Rheumatoid arthritis   | 2   | 3.2                                       |
| Müller                        | 1949 | Not stated   | Endogenous non-purulent uveitis                                   | 861                       | Rheumatoid arthritis   | 2   | 3.2                                       |
|                               |      |  |   |                           | Chronic rheumatism   | 137 | 15.9                                      |
| Vesterdal                     | 1951 | Clinical, radiology not routine<br>Clinical with routine radiology | Acute fibrinous iridocyclitis                                     | 70                        | Von Bechterew's disease  | 21  | 2.4                                       |
|                               |      |  | Acute fibrinous iridocyclitis                                     | 50                        | Ankylosing spondylitis   | 4   | 5.7                                       |
|                               |      |  | Total   | 120                       | Ankylosing spondylitis   | 10  | 20  |
|                               |      |  | Acute fibrinous iridocyclitis                                     | 120                       | Chronic rheumatoid arthritis   | 19  | 15.8                                      |
|                               |      |  |   |                           | Acute rheumatoid arthritis   | 5   | 4.2                                       |
|                               |      |  |   |                           | Gonorrhoea   | 23  | 19.2                                      |
|                               |      |  |   |                           |  |     | (Of these at least sixteen had arthritis) |
| Schöne and Steen              | 1951 | Routine radiographs of sacro-iliac joints                          | Sample of patients with acute iridocyclitis of doubtful aetiology | 105                       | Definite or doubtful ankylosing spondylitis  | 7   | 6.7                                       |
| Bartoš                        | 1952 | Not known  | Not known   | 78                        | Definite Bechterew's disease   | 20  | 25.6                                      |
|                               |      |  |   |                           | Possible Bechterew's disease   | 6   | 7.7                                       |
| De Marchin                    | 1954 | Routine radiographs of sacro-iliac joints                          | Ocular inflammation, suspected of rheumatic origin.               | 80                        | Bilateral sacro-iliac arthritis (Of these, seven (8.7 per cent.) had spinal changes of ankylosing spondylitis) | 15  | 18.7                                      |
| Bennett                       | 1955 | Not stated   | "Primary uveitis"   | 332                       | Ankylosing spondylitis   | 34  | 10.2                                      |
|                               |      |  |   |                           | Rheumatoid arthritis   | 27  | 8.1                                       |
|                               |      |  |   |                           | Previous rheumatic fever   | 5   | 1.5                                       |

in 20 per cent. of her patients, is the only author to report any striking association of rheumatoid arthritis with uveitis.

A diagnosis of "Reiter's disease" was not made in any of the above studies, but Vesterdal found clinical or serological evidence of "gonorrhoea" in 23 (19.2 per cent.) of her patients, and sixteen of them (69.4 per cent.) had arthritis.

**Uveitis in Rheumatic Diseases.**—The reported incidence in rheumatic diseases has varied widely. In the larger reported series of cases of ankylosing spondylitis, uveitis was noted in less than 10 per cent. of cases by Fischer and Vontz (1932), Golding (1936), Scott (1942), Polley and Slocumb (1947), Parr, White, and Shipton (1951), Sharp and Easson (1954), and Michaud and Forestier (1954). Hench, Slocumb, and Polley (1947) found an incidence of 11.6 per cent., Hart (1955) 13.5 per cent., West (1949) 15 per cent., Bernstein and Broch (1949) 20 per cent., and Romanus (1953) 28 per cent. Hart (1951) found that the incidence in patients over 45 years of age whose disease was of 15 or more years duration rose to slightly more than 40 per cent.

Conjunctivitis is the commonest reported ocular manifestation of Reiter's disease, but Paronen (1948) found iritis in 21 (6.6 per cent.) of his 334 patients, and Zewi (1947) in one of his ten patients. Ford (1953) found relapsing iritis in six of 21 patients, selected as having recurrent or chronic arthritis over a period of 5 years or more, associated with venereal urethritis.

The highest reported incidence of uveitis in rheumatoid arthritis (4.7 per cent.) is that of Bauer (quoted by Berens, Rothbard, and Angevine, 1942); Duthie (1955) found that seven out of 210 patients with rheumatoid arthritis showed signs of active or old uveitis; Michaud and Forestier (1954) did not encounter uveitis in a study of 100 rheumatoid patients.

It is generally agreed that uveitis is rare in acute rheumatism (Coburn, 1931; Rudolph, 1945; Sorsby and Gormaz, 1946; Nutt, 1951). Godtfredsen (1949), however, reported iritis in 4 to 5 per cent. of patients with rheumatic fever in Denmark, but the basis for this statement was not made clear.

#### Material and Methods

This study forms part of a wider survey of the aetiological factors concerned in uveitis conducted by one of us (A.S.). The material comprised all patients attending the Out-patient Clinic of the University Department of Ophthalmology between January, 1953, and June, 1955, suffering from uveitis, excluding those with frankly purulent infections (panophthalmitis), post-operative uveitis, and kerato-uveitis in which the uveitis was rela-

tively mild and apparently dependent on the accompanying keratitis (*e.g.* uveitis associated with septic corneal ulcers). Those with kerato-uveitis in which the uveitis formed a major part of the disease picture, and appeared to progress independently of the keratitis, were included in the series. No patients had been referred directly from the Rheumatism Centre to the Eye Department.

The patients were routinely referred to the Rheumatism Centre, where a complete clinical examination of the limbs and spine was performed; almost all the patients were examined by one of two observers who were unaware of the exact type of uveitis present. Radiographs of the limbs and spine were done only when considered indicated on clinical grounds. The sheep cell differential agglutination test for rheumatoid arthritis (D.A.T.) was carried out by Dr. J. Ball (Ball, 1950); agglutination at a dilution of 1/32 or more at 18 hrs was taken as a positive result.

#### Definition of Terms

**Types of Uveitis.**—The ocular disease diagnosed at the patient's first attendance was classified as kerato-uveitis, anterior uveitis (iritis or cyclitis, alone or together), posterior uveitis (choroiditis with or without cyclitis), or pan-uveitis (iritis, cyclitis, and choroiditis). The anterior uveitis group was further sub-divided into three types:

- (i) *Granulomatous.*—This type is characterized by an insidious onset and chronic course, organic changes in the iris, a tendency to form posterior synechiae, and keratic precipitates (K.P.) on the back of the cornea which vary in size but may be "mutton fat" in type.
- (ii) *Non-granulomatous.*—This type has an acute onset and relatively short duration, the iris shows oedema without gross organic changes, there is copious exudate into the anterior chamber, but the exudate is easily absorbed and posterior synechiae are not marked except after recurrent attacks, and K.P. are small; individual attacks have a relatively good prognosis, but the uveitis tends to recur and may then lead to permanent loss of vision.
- (iii) There remained a number of cases in which the classification was in doubt.

The patients were also classified into those with and those without a known non-rheumatic cause for the uveitis. Such a subdivision would probably be made in different ways by different ophthalmologists; in the present state of our ignorance only well-substantiated causes can be accepted. We have taken uveitis to be of non-rheumatic origin when associated with herpes zoster ophthalmicus, dendritic ulceration of the cornea, interstitial keratitis, secondary syphilis, superficial punctate keratitis, sarcoidosis, sympathetic ophthalmia, rupture of the lens, heterochromic cyclitis, and Vogt-Koyanagi syndrome.

**Types of Rheumatic Disease.**—The main classifications of rheumatic disease employed were osteo-arthritis, rheumatoid arthritis, "Reiter's disease", and "spinal

arthritis". The category of osteo-arthritis was further subdivided into degenerative joint disease and "generalized" osteo-arthritis as described by Kellgren and Moore (1952); "spinal arthritis" was subdivided into ankylosing spondylitis and "atypical" spondylitis. The remaining rheumatic diseases, using the term in a broad sense, were grouped together as "other diseases".

Degenerative joint disease was diagnosed when the joint changes appeared to be due to wear and tear. Usually only a few joints such as the larger weight-bearing joints in the elderly were affected. In younger patients the changes had usually occurred in joints which were mechanically deranged or had been subjected to excessive stress. Evidence of degeneration of intervertebral disks was regarded as the analogous process in the spine.

The criteria for the diagnosis of "generalized" osteo-arthritis was a polyarthritis most commonly affecting the interphalangeal joints of the fingers, first carpo-metacarpal, knee, first metatarsophalangeal, and spinal apophyseal joints; this was usually associated with Heberden's nodes and characterized by painful and usually self-limiting episodes in the affected joints with coincident development of bony enlargement of the joints but without peri-articular soft tissue swelling or other associated features of rheumatoid arthritis.

Rheumatoid arthritis was defined as an arthritis, apparently unrelated to infection, showing a strong tendency to symmetrical involvement of distal joints of the extremities with thickening of peri-articular soft tissues of affected joints, a variable degree of constitutional upset, a tendency to formation of nodules in tendons and less frequently in subcutaneous tissues, and usually associated with vasospasm and excess sweating of the extremities and atrophy of the skin and wasting of muscles. Radiographic signs of juxta-articular porosis or articular erosions, and a positive sheep cell differential agglutination test, were considered strong evidence of rheumatoid arthritis, but were not essential for the diagnosis.

The term "Reiter's disease" was used to designate a syndrome characterized by conjunctivitis or uveitis and arthritis with a characteristic distribution and evolution following genito-urinary infection, usually urethritis (Harkness, 1950; Ford, 1953) or following dysentery

(Reiter, 1916; Fiessinger and Leroy, 1916; Paronen, 1948; Marche, 1951). In the female, severe or recurrent cystitis or a persistent vaginal discharge was accepted as the genito-urinary component. Stomatitis might occur as a less constant feature of the syndrome (Piora, 1953). In a few instances, as described in the text, Reiter's disease was diagnosed in the absence of definite arthritis, but a history of dysentery or genito-urinary infection was considered essential.

Criteria for the diagnosis of ankylosing spondylitis were based on the clinical descriptions in numerous recent publications (Polley and Slocumb, 1947; Mowbray, Latner, and Middlemiss, 1949; Hart, Robinson, Allchin, and MacLagan, 1949; Hart, 1955). A history of upward spread of the spinal involvement and of exacerbation of symptoms following immobility was almost invariably obtained and movements of the lower spine and chest expansion were usually but not invariably restricted. Bilateral radiographic sacro-iliac joint changes were considered essential for definite diagnosis.

"Atypical" spondylitis was diagnosed in patients with spinal arthritis in whom the clinical or radiographic picture differed in various ways from that of classical ankylosing spondylitis, as described in the text.

In a few patients it was not possible to make a definite differential diagnosis between Reiter's disease, rheumatoid arthritis, and ankylosing spondylitis. In some cases, osteo-arthritis coexisted with one of those conditions. If rheumatoid arthritis entered into the differential diagnosis, this was considered the "main rheumatic disease" (see Table III); similarly, Reiter's disease was given preference over ankylosing spondylitis and each of those three conditions was listed as the main diagnosis in preference to osteo-arthritis.

## Results

Table II shows the numbers of patients suffering from the various types of uveitis, subdivided into those with and those without a known non-rheumatic aetiology. Table III (opposite) shows the numbers of patients with rheumatic diseases; the corresponding age distributions are depicted in the Figure (opposite).

TABLE II  
TYPE OF UVEITIS

| Origin of Uveitis |              | Kerato-Uveitis | Anterior Uveitis |                   |          | Posterior Uveitis | Pan-Uveitis | Total |
|-------------------|--------------|----------------|------------------|-------------------|----------|-------------------|-------------|-------|
|                   |              |                | Granulomatous    | Non-granulomatous | Doubtful |                   |             |       |
| Unknown           | Male .. ..   | 6              | 10               | 55                | 17       | 9                 | 2           | 99    |
|                   | Female .. .. | 8              | 33               | 31                | 10       | 20                | 1           | 103   |
|                   | Total .. ..  | 14             | 43               | 86                | 27       | 29                | 3           | 202   |
| Non-rheumatic     | Male .. ..   | 10             | 4                | 3                 | 1        | 0                 | 0           | 18    |
|                   | Female .. .. | 11             | 4                | 1                 | 1        | 0                 | 0           | 17    |
|                   | Total .. ..  | 21             | 8                | 4                 | 2        | 0                 | 0           | 35    |
| Total .. ..       |              | 35             | 51               | 90                | 29       | 29                | 3           | 237   |

TABLE III  
TYPE OF MAIN RHEUMATIC DISEASE

| Type of Uveitis                           | Kerato-Uveitis |        | Anterior Uveitis |        |                   |        |          |        | Posterior Uveitis |        | Pan-Uveitis |        | Total |        |
|---|----------------|--------|------------------|--------|-------------------|--------|----------|--------|-------------------|--------|-------------|--------|-------|--------|
|   |                |        | Granulomatous    |        | Non-granulomatous |        | Doubtful |        |                   |        |             |        |       |        |
| Origin of Uveitis                         | U.             | Non-R. | U.               | Non-R. | U.                | Non-R. | U.       | Non-R. | U.                | Non-R. | U.          | Non-R. | U.    | Non-R. |
| Total examined for rheumatic disease ..   | 13             | 17     | 38               | 6      | 83                | 1      | 21       | 1      | 26                | 0      | 3           | 0      | 184   | 25     |
| Total found to have rheumatic diseases .. | 11             | 11     | 26               | 4      | 60                | 0      | 16       | 0      | 10                | 0      | 2           | 0      | 125   | 15     |
| Osteo-arthritis and degenerative disease  | 5              | 4      | 11               | 2      | 11                | 0      | 5        | 0      | 5                 | 0      | 1           | 0      | 38    | 6      |
| Rheumatoid arthritis ..                   | 2              | 2      | 6                | 0      | 9                 | 0      | 2        | 0      | 1                 | 0      | 0           | 0      | 20    | 2      |
| Reiter's disease ..                       | 2              | 2      | 2                | 0      | 6                 | 0      | 3        | 0      | 1                 | 0      | 0           | 0      | 14    | 2      |
| Spinal arthritis ..                       | 2              | 1      | 0                | 0      | 29                | 0      | 6        | 0      | 0                 | 0      | 1           | 0      | 38    | 1      |
| Other rheumatic diseases ..               | 0              | 2      | 7                | 2      | 5                 | 0      | 0        | 0      | 3                 | 0      | 0           | 0      | 15    | 4      |

U. = uveitis of unknown aetiology. Non-R. = uveitis of non-rheumatic aetiology.

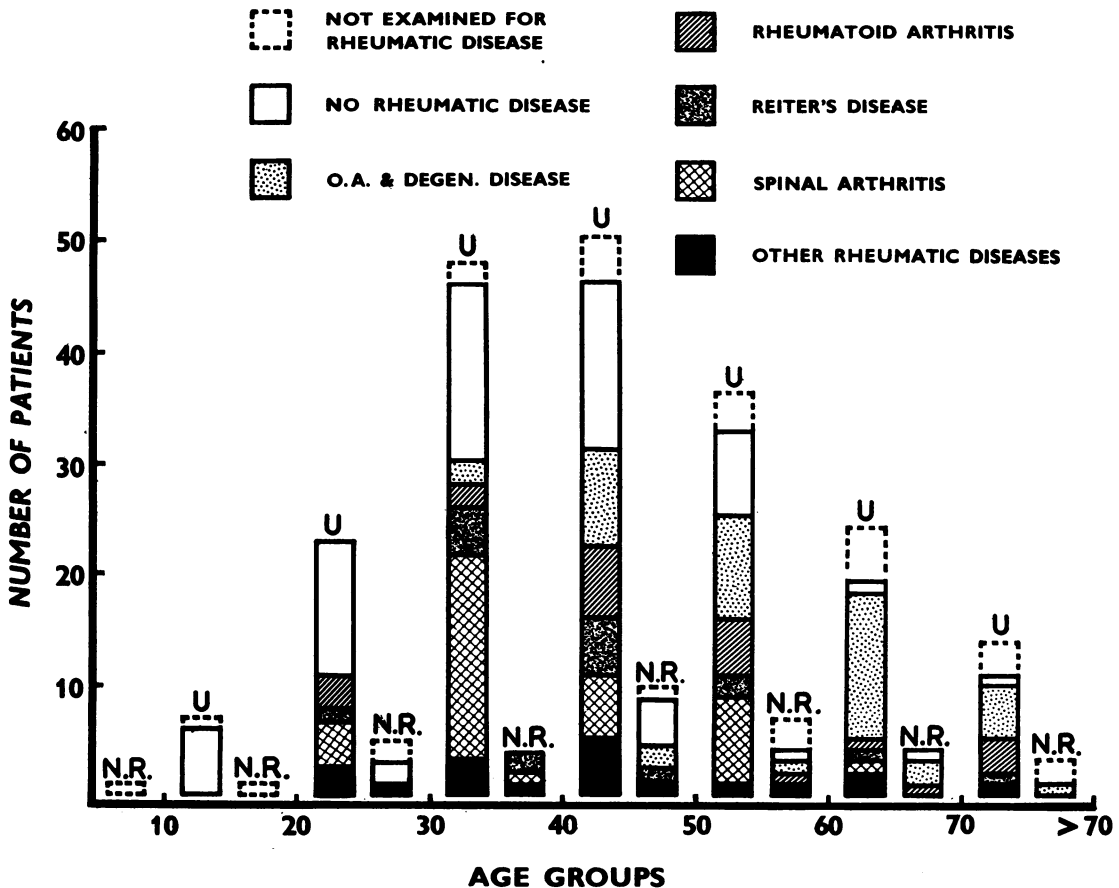


Figure.—Age distribution of patients. Each pair of columns represents one age group. The left-hand column in each pair refers to patients without a known non-rheumatic cause for uveitis (U=unknown) and the right-hand column to those with a known non-rheumatic cause. (N.R.=non-rheumatic).

The proportion of patients who failed to attend for rheumatological examination increased steadily after the fourth decade, but otherwise the patients examined formed a reasonably representative sample of the total.

**OSTEO-ARTHRITIS.**—This was the main diagnosis in 44 patients; in addition, two patients with rheumatoid arthritis and one with spondylitis also suffered from osteo-arthritis; 28 of these 47 patients had generalized osteo-arthritis. Table IV shows that there was no significant difference in the incidence of these diseases in patients with and in patients without a known non-rheumatic cause for their uveitis, and further analysis of the incidence in these groups by age and sex failed to reveal any significant differences.

It is possible to compare the incidence, in this series, of generalized osteo-arthritis in the age group 55-64 years with that in the general population of the South Lancashire town of Leigh (Lawrence, 1955). In the Leigh survey, approximately half the females and one in seven of the males had some clinical evidence of generalized osteo-arthritis; in the present series, this condition was found in eight of the twelve females and none of the thirteen males examined for rheumatic diseases. There was no significant difference between the incidence in the Leigh survey and in the present series.

**RHEUMATOID ARTHRITIS.**—Eight of the 22 patients with rheumatoid arthritis had clinical evidence of rheumatoid arthritis with bony erosions in radiographs of the hands and feet, three of these having a positive D.A.T. Strong clinical evidence was present in three cases, radiographs and D.A.T. not having been done in one case, and being negative in two cases. Seven patients had some clinical evidence of rheumatoid arthritis but a negative D.A.T. and, in two cases, negative radiographs. One patient had no clinical evidence of disease of the limbs or spine, but his D.A.T. titre was 1/32, 1/64, and <1/4 at intervals over 2½ years. The three remaining patients whose case histories are outlined

below gave positive results in the D.A.T., but the clinical picture was not that of straightforward rheumatoid arthritis, and these patients were also included in the group with "atypical" spondylitis discussed later.

**Case 1, a man aged 21 years**, with left non-granulomatous anterior uveitis, gave a history of recurrent inflammation of the eye since the age of 13 years and of a prolonged episode of arthritis in one knee starting at 14 years, subsiding in 2 years without residua apart from alteration of bone architecture in the affected region. He also had radiographic changes in his sacro-iliac joints compatible with ankylosing spondylitis but no clinical evidence of spinal involvement, and his D.A.T. titre was 1/128; late juvenile rheumatoid arthritis could not therefore be excluded.

The two other patients in this group gave agglutination in the D.A.T. at a titre of 1/32.

**Case 2, a man aged 72 years** with left granulomatous anterior uveitis, gave a history of generalized poly-arthritis lasting 3 months at the age of 43 years, following which he had no further symptoms in the limbs or spine. Examination revealed moderate restriction of movement of his whole spine but no abnormality of limb joints. The erythrocyte sedimentation rate was normal. Radiographically both sacro-iliac joints were abnormal, the disk spaces in the lumbar and cervical regions were greatly narrowed, and there was much new bone formation on the vertebral bodies; the spinal appearances were compatible with healing following an acute process mainly involving destruction of intervertebral disks. The D.A.T. result suggested that this might have been a rheumatoid episode in which the spine was principally involved, but the gonococcal complement-fixation test was also doubtfully positive so that Reiter's disease of venereal origin had to be considered a possibility, though there was no history of genito-urinary infection.

**Case 3, a man aged 49 years**, with left anterior uveitis of doubtful type, gave a history of mild low back pain in his 'teens and of pains and increasing deformity in the dorsal region for 4 years. He had a virtually rigid spine, with limited chest expansion and hypermobility of wrist tarsal and knee joints. His erythrocyte sedimen-

TABLE IV  
OSTEO-ARTHRITIS AND RHEUMATOID ARTHRITIS

| Aetiology of Uveitis              |                         | Unknown |           | Non-rheumatic |           | Total  |           |
|-----------------------------------|-------------------------|---------|-----------|---------------|-----------|--------|-----------|
|                                   |                         | Number  | Per cent. | Number        | Per cent. | Number | Per cent. |
| Examined for Rheumatic Disease .. |                         | 184     | 100       | 25            | 100       | 209    | 100       |
| Osteo-<br>Arthritis               | Generalized .. ..       | 25      | 13·6      | 3             | 12·0      | 28     | 13·4      |
|                                   | Degenerative disease .. | 16      | 8·6       | 3             | 12·0      | 19     | 9·1       |
|                                   | Total .. ..             | 41      | 22·2      | 6             | 24·0      | 47     | 22·5      |
| Rheumatoid Arthritis .. ..        |                         | 20      | 10·9      | 2             | 8·0       | 22     | 10·5      |

tation rate was 20 mm./hr (Wintrobe). He had severe valvular heart disease and no further investigations were made as he died suddenly from cardiac causes. The most probable diagnosis appeared to be ankylosing spondylitis with coincident rheumatic heart disease.

Twelve patients who were not examined for rheumatic disease had the D.A.T. performed. In two patients the test was positive. One of these gave a vague history of muscle pains, but had no trouble at the time of onset of uveitis; the other gave no history of rheumatism, but suffered from psoriasis and lupus vulgaris.

The incidence of rheumatoid arthritis in the 209 patients examined for rheumatic disease was therefore 10.5 per cent.; in the 221 patients who had some sort of investigation for rheumatoid arthritis, the incidence was 11.5 per cent.

The incidence of rheumatoid arthritis in patients with uveitis of known non-rheumatic origin is shown in Table IV; it is not significantly increased in the patients with no obvious cause for the uveitis. Further analysis, taking into account the age distribution of the patients with rheumatoid arthritis, and after exclusion of patients with spondylitis or Reiter's disease in whom the additional diagnosis of rheumatoid arthritis was unlikely to be made, also failed to reveal any significant difference in incidence of rheumatoid arthritis in the groups of patients with and without a known cause for their uveitis.

In the survey of the general population of Leigh in the age groups 55-64 years (Kellgren, 1955) the incidence of all grades of rheumatoid arthritis was found to be 5 per cent. in males and 18 per cent. in females. One of the thirteen males and two of the twelve females in this age group in the present series had rheumatoid arthritis. The numbers of uveitis patients in this age group are small but these findings do not suggest an unduly high incidence of rheumatoid arthritis.

*Sheep Cell Differential Agglutination Test.*—This test was performed in 190 patients, 178 of whom were examined for rheumatic disease. Details of these patients are given in Table V.

In the subjects tested in the Leigh survey, seven of the 256 with no clinical evidence of rheumatoid arthritis and twelve of the 94 with such evidence gave positive tests (Ball, 1955). The figures for the uveitis patients are not significantly different from these but strict comparison of these groups is not possible since the uveitis patients were on the whole younger. Three of the six uveitis patients with positive tests classed as having "clinical R.A." in Table IV had atypical spondylitis as described above and at least two of them would not have

TABLE V  
SHEEP CELL DIFFERENTIAL AGGLUTINATION TEST

| Number of Patients                               |     | Differential Agglutination Test |                 |
|--|-----|---------------------------------|-----------------|
|  |     | Number Tested                   | Number Positive |
| Whole Series .. ..                               | 237 | 190                             | 10              |
| Not Examined for Rheumatic Disease .. ..         | 28  | 12                              | 2               |
| Examined for Rheumatic Disease .. ..             | 209 | 178                             | 8               |
| Clinical Rheumatoid Arthritis (all grades) .. .. | 21  | 20                              | 6               |
| No Clinical Rheumatoid Arthritis .. ..           | 188 | 158                             | 2               |

been diagnosed clinically as rheumatoid arthritis. If these three patients are placed in the group with "No clinical R.A.", there is still no significant difference from the Leigh survey.

REITER'S DISEASE.—Some features of the sixteen patients to whom this diagnosis was applied with various degrees of assurance are set out in Table VI.

TABLE VI  
REITER'S DISEASE

| Radio-graphic Changes | Patients |        |       | Uveitis | Genito-urinary | Dysentery | Arthritis |
|-----------------------|----------|--------|-------|---------|----------------|-----------|-----------|
|                       | Male     | Female | Total |         |                |           |           |
| Present ..            | 5        | 3      | 8     | 8       | 6              | 2         | 8         |
| Absent ..             | 2        | 6      | 8     | 8       | 8              | 0         | 5         |

Table VII (overleaf) gives more detailed information regarding eight cases (Cases 4 to 11) with radiographic changes in the spine or sacro-iliac joints.

**With Radiographic Changes.**—In Cases 8 and 11 (Table VII) the three components of the syndrome had occurred simultaneously, and in five of the others, two components had occurred simultaneously at least once during the course of the illness; in Case 7 the history was unreliable. The long duration of the illness is noteworthy.

In Cases 4 to 6 the disease appeared to be of venereal origin, and there was almost certain evidence in Case 5 and suggestive evidence in the others that the original urethritis was not straightforward gonorrhoea. In two other male patients, dysentery was a possibility, though one of these had a positive gonococcal complement-fixation test.

The mode of infection in the females was less obvious. Ankylosing spondylitis was an alternative diagnosis in Case 10, as was Behcet's disease in Case 11.

The uveitis was never the initial manifestation, and was anterior in all cases. It was associated with superficial punctate keratitis in one patient, who was therefore also included in the group with uveitis of non-rheumatic origin. This finding is of interest in view of the possible virus aetiology of both Reiter's disease (Dunham, Rock, and Belt, 1947; Harkness, 1950) and some types of superficial punctate keratitis

(Braley and Alexander, 1953). Relapse of the uveitis was not associated with recurrence of the keratitis.

**Without Radiographic Changes.**—In one female patient the three components of the syndrome occurred simultaneously; she had dysuria, frequency and vaginal discharge for 4½ months, and non-granulomatous posterior uveitis and retinal perivasculitis for 4 months; she had pain in the back and one finger, and sacro-iliac joint tests were positive.

TABLE VII  
REITER'S DISEASE WITH RADIOGRAPHIC CHANGES IN SACRO-ILIAC JOINTS OR SPINE

| Case | Sex | Age   |           | Onset                               | Manifestations  |   |   | Erythrocyte Sedimentation Rate | Gonococcal Complement-fixation Test | Differential Agglutination Test | Radiographs  |
|------|-----|-------|-----------|-------------------------------------|---|---|---|--------------------------------|-------------------------------------|---------------------------------|--|
|      |     | Onset | Attending |                                     | Uveitis   | Genito-Urinary  | Arthritis   |                                |                                     |                                 |  |
| 4    | M   | 30    | 50        | Urethritis and arthritis            | Recurrent non-granulomatous anterior uveitis from age 46                | Urethritis; gross haematuria  | Feet, knees, low back at age 30; painful heel at age 46   | 5                              | —                                   | 1/4                             | Right calcaneal periostitis ++. Sacro-iliac joints abnormal  |
| 5    | M   | 25    | 33        | Urethritis                          | Anterior uveitis, doubtful type, present 3 wks. ?Previous attack age 29 | Recurrent urethritis  | "Penicillin resistant gonococcal arthritis", mainly feet and back at age 25; recurrence at age 29         | 24                             | Doubtful                            | 1/8                             | Calcaneal spurs. Arthritis great toes and right sacro-iliac joints. Early marginal bridging lower dorsal disk spaces |
| 6    | M   | 24    | 62        | Urethritis                          | Recurrent non-granulomatous anterior uveitis from age 26                | Prolonged urethritis  | Feet, ankles, knees for 18 months at age 28; feet, knees, odd fingers, and shoulders for 1 year at age 32 | 40                             | Neg.                                | 0                               | Changes in feet, knees and spine   |
| 7    | M   | 19    | 58        | Severe recurrent diarrhoea          | Anterior uveitis, doubtful type, present 10 days, first attack          | Positive gonococcal complement-fixation test                              | Feet at age 55; gross restriction lower spine   | 15                             | +                                   | 1/8                             | Arthritis feet and sacro-iliac joints; ligamentous ossification spine  |
| 8    | F   | "30s" | 53        | Pain in lumbar region and left knee | Anterior uveitis, doubtful type, present 1 month, first attack          | Vaginal discharge for 18 months; severe cystitis for 4 weeks one year ago | Lumbar spine and left knee from "30s"; left acromioclavicular joint for 7 weeks, and neck for one month   | 5                              | Neg.                                | 1/8                             | Calcaneal spurs. Changes in symphysis pubis, pelvis, and spine   |
| 9    | F   | 21    | 48        | Painful swelling of knees           | Recurrent non-granulomatous kerato-uveitis since age 21                 | Recurrent cystitis since age 21   | Recurrent transient pains (particularly back) since age 21; no objective changes                          | 28                             | Neg.                                | 0                               | Borderline abnormality of sacro-iliac joints. Pelvis, hip, knees, and feet normal                                    |
| 10   | M   | 22    | 38        | Dysentery, stiff and painful hips   | Non-granulomatous anterior uveitis at age 38                            | —   | Recurrent buttock and groin pain since age 22; back and shoulder pain since age 36                        | 26                             | Neg.                                | Neg.                            | Bilateral sacro-iliac joint sclerosis, compatible with ankylosing spondylitis  |
| 11   | F   | 25    | 31        | Sciatica; and aphthous stomatitis   | Non-granulomatous kerato-uveitis at age 31                              | Yellow intermenstrual discharge; nocturnal frequency                      | Sciatica at age 25; neuritis under one breast for one year; sacro-iliac joint tests positive              | 3                              | Neg.                                | Neg.                            | Doubtful sclerosis of one sacro-iliac joint  |

In addition to the uveitis, four of the remaining seven patients had had both genito-urinary symptoms and arthritis during the course of the illness. The group as a whole did not appear homogeneous, and it seemed possible that the various components of the syndrome might in some cases have been associated by chance.

There was no obvious association with any particular type of uveitis; in one case the uveitis began with superficial punctate keratitis.

**SPINAL ARTHRITIS**

**Ankylosing Spondylitis.**—In 35 of the 38 patients in whom spondylitis was the main diagnosis the picture was typical or suggestive of classical ankylosing spondylitis. Some features of these patients are shown in Table VIII.

Radiographic changes in both sacro-iliac joints compatible with ankylosing spondylitis were present in 22 patients. The disease picture in the patient whose serum gave a positive result in the D.A.T. was typical of advanced ankylosing spondylitis, and he had been treated by deep x rays 4 years previously with great benefit. In five patients the spondylitis, which was of many years' duration, had resulted in obvious spinal rigidity, and in ten others clinical examination strongly suggested the diagnosis. Although mild symptoms of spondylitis had been present for from 4 to 12 years in five of the seven remaining patients, in two the spinal symptoms had been so mild that they had never consulted a doctor about them, and only one had diminished spinal movements and chest expansion; in these patients the diagnosis was usually suspected from the history of recurrent "lumbago", "sciatica", or "fibrositis", particularly when these symptoms were aggravated by immobility, and was confirmed by radiography of the sacro-iliac joints. Two patients gave a history of an initial attack of uveitis that had

preceded pain or stiffness in the trunk or limbs by as long as 4 years.

It might be expected that uveitis associated with ankylosing spondylitis would occur during the active phases of the disease, but the spinal disease was judged to be inactive on clinical grounds in one-third of the 22 patients. The level of the erythrocyte sedimentation rate was poorly correlated with the clinical assessment of disease activity, being normal in one-third of the patients, including four of the seven in whom the presence of the spinal disease was least obvious; the diagnosis would have been missed in these patients if the erythrocyte sedimentation rate had been used as a screening test. Judged by either criterion, therefore, it would appear that uveitis may occur during an apparently inactive phase of the spondylitis in a substantial proportion of patients.

The uveitis in these 22 patients was anterior, without involvement of the cornea or choroid, and was non-granulomatous apart from three doubtful cases, and all the patients presented with active disease in one eye only. Eight patients (36.4 per cent.) had had previous attacks of uveitis; in two both eyes had been affected, in four the same eye, and in two the opposite eye. This incidence of previous attacks is not significantly higher than that (24.4 per cent.) in the patients with the non-granulomatous type of anterior uveitis as a whole.

The thirteen remaining patients without radiographic evidence of ankylosing spondylitis all had clinical findings suggestive of ankylosing spondylitis, but the sacro-iliac joints appeared normal in eleven of the twelve patients with radiographs, and in the remaining patient there was probable erosion of one joint only. Five had symptomless restriction of movement of the lower spine, and only two, both men aged 60 years, had had spinal pain of any note; one of them had considerable limitation of movement of his whole spine. The distribution of their

TABLE VIII  
SPINAL ARTHRITIS

| Spondylitis |                                      | No. of Patients |        |       | Erythrocyte Sedimentation Rate |          | Differential Agglutination Test |          | Type of Uveitis |                   |          | History of Previous Uveitis |
|-------------|--------------------------------------|-----------------|--------|-------|--------------------------------|----------|---------------------------------|----------|-----------------|-------------------|----------|-----------------------------|
|             |                                      | Male            | Female | Total | Done                           | Elevated | Done                            | Positive | Granulomatous   | Non-granulomatous | Doubtful |                             |
| Ankylosing  | With radiographic confirmation ..    | 19              | 3      | 22    | 20                             | 13       | 18                              | 1        | 0               | 19                | 3        | 8                           |
|             | Without radiographic confirmation .. | 10              | 3      | 13    | 13                             | 2        | 12                              | 0        | 0               | 10                | 3        | 5                           |
| Atypical    | Rheumatoid Arthritis ..              | 3               | 0      | 3     | 3                              | 2        | 3                               | 3        | 1               | 1                 | 1        | 1                           |
|             | Reiter's Disease ..                  | 5               | 3      | 8     | 8                              | 5        | 8                               | 0        | 0               | 5                 | 3        | 3                           |
|             | Miscellaneous ..                     | 2               | 2      | 4     | 3                              | 3        | 1                               | 0        | 0               | 3                 | 1        | 0                           |



ages of attendance suggested that the thirteen patients fell into two groups, one mainly in the fourth and the other mainly in the sixth decade. When these patients were seen it appeared possible from the clinical picture that the uveitis might be the presenting or initial manifestation of ankylosing spondylitis and that they might subsequently develop diagnostic changes, but this supposition is unlikely to be correct in the older patients. Although the uveitis was of the non-granulomatous variety in at least ten of these thirteen patients, in one the whole uveal tract was affected, and in three the cornea, one having a dendritic ulcer of definite virus aetiology; this is in contrast to the involvement of iris and ciliary body only in the patients with radiographic evidence of ankylosing spondylitis.

**"Atypical" Spondylitis.**—This group, further details of which are given in Table VIII, was formed by three patients who have already been described in the rheumatoid arthritis group, eight from the Reiter's disease group, and four who form a miscellaneous group. Two of the latter were males with non-granulomatous anterior uveitis in whom ankylosing spondylitis appeared a distinct possibility, but in both the radiographic appearances were unusual, and one gave a history of pain and swelling of the knee and wrist in India 7 years previously, which was suggestive of Reiter's disease, although there was no history of genito-urinary infection or dysentery. One of the two remaining patients was a female aged 46 years with right non-granulomatous anterior uveitis, clinical and doubtful radiographic evidence of arthritis of one sacro-iliac joint, and painful swelling of one ankle of 2 years' duration, in whom no definite diagnosis was established; the other is described below (Case 12).

**Case 12, a female aged 62 years,** with valvular heart disease, the second patient in the series in whom valvular heart disease was associated with spondylitis, had anterior uveitis of doubtful type. Some 20 years previously she had had a generalized polyarthritis lasting some weeks with residual pains in the feet for one year. Thereafter she had suffered recurrent pains in the limbs and spine and had developed Heberden's nodes and bony enlargement of other finger joints. The spinal curves were increased, the dorsal kyphos being fixed, and cervical and lumbar movements moderately restricted. The erythrocyte sedimentation rate was 17 mm/hr (Wintrobe) and the D.A.T. was negative. Radiographs revealed erosion and sclerosis of the sacro-iliac joints and symphysis pubis, the former being practically fused; the joint spaces in both hips were decreased, the femoral heads having a globular appearance. There was evidence of disk degeneration in the lumbar and cervical regions of the spine and of osteo-arthritis in the hands, feet, and knees. The changes in the limb joints suggested

"generalized" or secondary osteo-arthritis, but those in the sacro-iliac joints, symphysis pubis, and hip joints were of the type occasionally observed after prolonged rheumatic fever in adult life (Thomas, 1955; Sharp, 1955).

Ankylosing spondylitis could not be definitely excluded in any of the five males; the uveitis was non-granulomatous in four of these and was of doubtful type in the fifth. In the whole group of fifteen patients, the uveitis was definitely non-granulomatous in nine, and granulomatous in only one.

**OTHER DISEASES.**—Psoriasis was encountered in two patients with no disease of the limb or spine, and also in one with degenerative disease of the spine and one knee, one with rheumatoid arthritis, and another with ankylosing spondylitis. In addition there was one elderly man with psoriasis, who did not attend for examination of the joints, who also had lupus vulgaris and a strongly positive D.A.T.; he has been mentioned previously in the section on rheumatoid arthritis. The incidence of psoriasis was therefore 2.5 per cent.; Ingram (1954) has estimated that psoriasis occurs in 1 to 2 per cent. of the general population.

Two patients with valvular heart disease and spinal disease have already been described. Four other patients with valvular lesions gave a history of rheumatic fever: three had no abnormalities in the spine or limbs, and the fourth had radiographic evidence of neoplastic changes in the pelvis and spine. No suitable figures of the incidence of rheumatic heart disease in the general population in this region are available for comparison. Acute rheumatic fever was not encountered.

Polyarteritis nodosa was suspected in one elderly woman who had necrotic ulcers on her legs and feet, and in another woman, already included in the section on osteo-arthritis, who had multiple symptoms and acute arthritis of one wrist associated with degenerative disease of the spine.

A male aged 33 years and a female aged 23 years both gave a history of pain and stiffness in the knees some years previously, suggestive of Reiter's disease, but there was no history of genito-urinary infection or dysentery; the joints were clinically normal and radiographs were not available.

Finally, there were four female patients who had in common Raynaud's attacks in the extremities, but no other evidence of rheumatic disease, and six patients with spinal deformities.

#### Discussion

In this survey, there did not appear to be any particular association between uveitis and psoriasis,

acute rheumatic fever, generalized osteo-arthritis, or degenerative disease of the limbs and spine.

The failure to find any significant association of rheumatoid arthritis with uveitis is of greater interest, although undoubtedly patients may occasionally be encountered in whom the uveitis is associated with changes in the cornea and sclera similar to those in the connective tissues elsewhere in rheumatoid arthritis; one of our patients, a female aged 54 years, had intractable bilateral granulomatous uveitis and nodular sclero-keratitis associated with severe rheumatoid arthritis with multiple subcutaneous nodules and marked spinal involvement. An association between uveitis and Still's disease is also not excluded. In the majority of patients with uveitis and rheumatoid arthritis, however, the association appears likely to be coincidental.

The higher incidence of rheumatoid arthritis and the absence of Reiter's disease in the series of patients with uveitis reported in the literature may be due to differences in diagnostic criteria. The high proportion of the series of patients reported by Vesterdal (1951) who had arthritis associated with "gonorrhoea", and the association of genito-urinary infection with ankylosing spondylitis in the majority of the patients of Romanus (1953) probably indicate that many of their cases would have been placed in the category of Reiter's disease in the present study. In the older literature, rigidity of the spine (Brodhurst, 1866; Rendu, 1899; Launois, 1899) and involvement of the sacro-iliac joints (Raymond, 1899; Galliard, 1899) in a polyarthritis associated with urethritis has occasionally been mentioned. Harkness (1950) produced convincing evidence that the urethritis is in many instances non-specific and of venereal origin. Ford (1953), in a study of 21 patients with arthritis following venereal urethritis, found four who had apparently developed ankylosing spondylitis. Harkness also suggested that the same infective agent might be responsible for the very similar syndrome following dysentery (Fiessinger and Leroy, 1916; Reiter, 1916; Paronen, 1948), the portal of entry in these cases being the diseased intestinal mucous membrane. Marche (1951) has reported that the clinical picture of ankylosing spondylitis may also develop in the dysenteric form of the syndrome.

Our findings confirm the association of unilateral non-granulomatous anterior uveitis with ankylosing spondylitis of which it may be the initial symptom. In only three of the patients suffering from ankylosing spondylitis with radiographic confirmation was the uveitis of the doubtful type, and granulomatous uveitis was not seen in any of them. Ankylosing spondylitis occurred in 30.8 per cent. of the

males and in 22.6 per cent. of all the patients with non-granulomatous anterior uveitis examined for rheumatic disease; the total incidence of ankylosing spondylitis, including those patients with atypical spondylitis in whom ankylosing spondylitis could not be definitely excluded, may have been as high as 49.0 per cent. in males and 35.6 per cent. in all patients with this type of uveitis. The incidence in uveitis of the doubtful type was about half that in the non-granulomatous type. The failure of some previous observers to find a marked association of uveitis and ankylosing spondylitis might be due to the relative mildness of the rheumatic symptoms in many cases, so that the diagnosis requires full clinical and radiological examination.

Non-granulomatous anterior uveitis was found to be associated with rheumatic diseases in which involvement of the spine was a feature, namely spinal arthritis and Reiter's disease. This raises the possibility of a connexion between this type of uveitis and a factor common to these rheumatic diseases which is perhaps related to the spinal involvement. In uveitis as a whole, these diseases occurred in about one patient in four.

#### Summary

(1) 209 out of 237 consecutive patients with uveitis were examined for rheumatic diseases. The sheep cell differential agglutination test was performed on 190 of the patients, including 178 of those examined.

(2) Uveitis was found to be specially associated with Reiter's disease (often with spinal involvement), ankylosing spondylitis, and some other forms of spondylitis. The uveitis was almost entirely of the unilateral non-granulomatous anterior type, and a history of previous uveitis was no more frequent than in other patients with non-granulomatous uveitis.

(3) The association of uveitis with other rheumatic diseases appeared to be coincidental, except in one patient with nodular sclero-kerato-uveitis and severe rheumatoid disease.

(4) The ankylosing spondylitis was sometimes very mild and apparently inactive; in two patients, uveitis was the initial complaint.

Prof. J. H. Kellgren examined many of these patients, and we are indebted to him and to Mr. O. M. Duthie for much valuable advice. Dr. J. Ball performed all the sheep cell agglutination tests, and gave much help in the interpretation of the results. We are also indebted to Dr. Robert Ollerenshaw and his staff in the Medical Illustration Department for reproducing the figure.

## REFERENCES

- Ball, J. (1950). *Lancet*, 2, 520.  
 — (1955). Personal communication.  
 Bartoš, J. (1952). *Čsl. ofthal.*, 8, 28. (*Abs. in Ophthal. Lit. (Lond.)* (1952), 6, p. 63, No. 133.)  
 Bauer, W. (1938). Personal communication, quoted by Berens and others (1942).  
 Bennett, G. (1955). *Brit. J. Ophthal.*, 39, 727.  
 Berens, C., Rothbard, S., and Angevine, D. M. (1942). *Amer. J. Ophthal.*, 25, 295.  
 Bernstein, L., and Broch, O. J. (1949). *Acta med. scand.*, 135, 185.  
 Birkbeck, M. Q., Buckler, W. S. J., Mason, R. M., and Tegner, W. S. (1951). *Lancet*, 2, 802.  
 Braley, A. E., and Alexander, R. C. (1953). *A.M.A. Arch. Ophthal.*, 50, 147.  
 Brodhurst, B. E. (1866). In Reynolds, J. Russell, "A System of Medicine", vol. 1, p. 920. Macmillan, London.  
 Coburn, A. F. (1931). "The Factor of Infection in the Rheumatic State", p. 24. Baillière, Tindall and Cox, London.  
 Dunham, J., Rock, J., and Belt, E. (1947). *J. Urol.*, 58, 212.  
 Duthie, J. J. R. (1955). Personal communication.  
 Fieissinger, N., and Leroy, E. (1916). *Bull. Soc. méd. Hôp. Paris*, 3 sér., 40, 2030.  
 Fischer, A., and Vontz, O. (1932). *Mitt. Grenzgeb. Med. Chir.*, 42, 586.  
 Ford, D. K. (1953). *Annals of the Rheumatic Diseases*, 12, 177.  
 Forestier, J. Quoted by Romanns (1953).  
 Galliard, L. (1899). *Bull. Soc. méd. Hôp. Paris*, 16 (3 sér.), 408.  
 Golding, F. C. (1936). *Brit. J. Surg.*, 23, 484.  
 Godtfredsen, E. (1949). *Brit. J. Ophthal.*, 33, 261.  
 Guyton, J. S., and Woods, A. C. (1941). *Arch. ophthal. (Chicago)*, 26, 983.  
 Harkness, A. H. (1950). "Non-Gonococcal Urethritis", p. 99. Livingstone, Edinburgh.  
 Hart, F. Dudley (1951). *Trans. ophthal. Soc. U.K.*, 71, 167.  
 —, Robinson, K. C., Allichin, F. M., and MacLagan, N. F. (1949). *Quart. J. Med.*, 18, 217.  
 — (1955). *Annals of the Rheumatic Diseases*, 14, 77.  
 Hench, P. S., Slocumb, C. H., and Polley, H. F. (1947). *Med. Clin. N. Amer.*, 31, 879.  
 Ingram, J. T. (1954). *Brit. med. J.*, 2, 823.  
 Kellgren, J. H. (1955). Personal communication.  
 —, and Moore, R. (1952). *Brit. med. J.*, 1, 181.  
 Launois, P. E. (1899). *Bull. Soc. méd. Hôp. Paris*, 16, 736.  
 Lawrence, J. S. (1955). Personal communication.  
 Marche, J. (1951). "II Congr. Europeo de Reumatologia, 1951. Comunicaciones", p. 14. Barcelona, 14.  
 Marchin, P. de (1954). *Rev. Rhum.*, 21, 531.  
 Marie, P., and Léri (1899). *Bull. Soc. méd. Hôp. Paris*, 16, 237.  
 Michaud, P., and Forestier, J. (1954). *Ibid.*, 21, 487.  
 Mowbray, R., Latner, A. L., and Middlemiss, J. H. (1949). *Quart. J. Med.*, 18, 187.  
 Müller, H. (1949). *Ber. dtsh. ophthal. Ges. Heidelberg.*, 55, 113.  
 Nutt, A. B. (1951). *Trans. ophthal. Soc. U.K.*, 71, 149.  
 Paronen, I. (1948). *Acta med. scand.*, Suppl. 212.  
 Parr, L. J. A., White, P., and Shipton, E. (1951). *Med. J. Aust.*, 1, 544.  
 Piora, J. (1953). *Acta med. scand.*, 144, 284.  
 Polley, H. F., and Slocumb, C. H. (1947). *Ann. intern. Med.*, 26, 240.  
 Raymond, —. (1899). In discussion of Marie and Léri (1899).  
 Reiter, H. (1916). *Dtsch. med. Wschr.*, 42, 1535.  
 Rendu, —. (1899). In discussion of Galliard (1899), p. 411.  
 Romanus, R. (1953). *Acta med. scand.*, Suppl. 280.  
 Rudolph, C. J. (1945). *Amer. J. Ophthal.*, 28, 319.  
 Schley, H. (1937). *Klin. Mbl. Augenheilk.*, 98, 780.  
 Schöne, R., and Steen, E. (1951). *Acta ophthal. (Kbh.)*, 29, 201.  
 Scott, S. G. (1942). "A Monograph on Adolescent Spondylitis or Ankylosing Spondylitis." Oxford University Press, London.  
 Sharp, J. (1955). *Lancet*, 2, 1371.  
 —, and Easson, E. C. (1954). *Brit. med. J.*, 1, 619.  
 Sorsby, A., and Gormaz, A. (1946). *Ibid.*, 1, 597.  
 Teschendorf, H. J. (1933). *Dtsch. med. Wschr.*, 59, 1576.  
 Thomas, A. E. (1955). *Annals of the Rheumatic Diseases*, 14, 259.  
 Vesterdal, E. (1951). *Acta ophthal. (Kbh.)*, 29, 509.  
 West, H. F. (1949). *Annals of the Rheumatic Diseases*, 8, 143.  
 Zewi, M. (1947). *Acta ophthal. (Kbh.)*, 25, 47.

## L'uvéite et les maladies rhumatismales

## RÉSUMÉ

(1) 209 d'entre 237 malades consécutifs, atteints d'uvéite, furent examinés pour des maladies rhumatismales. Chez 190 malades, comprenant 178 de ceux examinés, on effectua la réaction d'agglutination différentielle des cellules de mouton.

(2) On constata que l'uvéite était particulièrement associée avec la maladie de Reiter (souvent avec des implications vertébrales), la spondylarthrite ankylosante et certaines autres formes de spondylite. L'uvéite était presque toujours du type antérieur, unilatéral et non-granulomateux et une uvéite antécédante n'était pas plus fréquente que chez d'autres malades atteints d'uvéite non-granulomateuse.

(3) L'association de l'uvéite avec d'autres maladies rhumatismales apparut être fortuite, excepté chez un des malades atteint de scléro-kérato-uvéite nodulaire et d'une sévère maladie rhumatismale.

(4) La spondylarthrite ankylosante était parfois très légère et apparemment inactive; chez deux malades l'uvéite était la maladie initiale.

## La uveitis y las enfermedades reumáticas

## SUMARIO

(1) De 237 enfermos consecutivos afectos de uveitis, 209 fueron investigados en busca de enfermedades reumáticas. En 190 enfermos, comprendiendo 178 de los investigados, se hizo la reacción de aglutinación diferencial de las células de oveja.

(2) Se halló que la uveitis fué particularmente asociada con la enfermedad de Reiter (a menudo con implicaciones vertebrales), la espondilartrosis anquilosante y ciertas otras formas de espondilitis. La uveitis fué casi siempre del tipo anterior, unilateral y agranulomatosa y una uveitis antecedente no fué más frecuente que en otros enfermos con uveitis agranulomatosa.

(3) La asociación de la uveitis con otras enfermedades reumáticas pareció ser fortuita, con la excepción de un enfermo con esclero-querato-uveitis nodular y con una enfermedad reumática grave.

(4) La espondilartrosis anquilosante fué a veces muy leve y aparentemente inactiva; en dos enfermos la uveitis fué la enfermedad inicial.