

OCULAR PRESENTATIONS OF STILL'S DISEASE AND THEIR TREATMENT

IRIDOCYCLITIS IN STILL'S DISEASE: ITS COMPLICATIONS AND TREATMENT

BY

W. K. SMILEY, E. MAY, AND E. G. L. BYWATERS

From the Special Unit for Study and Care of Juvenile Rheumatism, Canadian Red Cross Memorial Hospital, Taplow, Maidenhead, Berks, England

(RECEIVED FOR PUBLICATION MAY 14, 1957)

Although chronic arthritis of a type known later as rheumatoid has been recorded in children since the description given by Cornil (1864), the occurrence of iridocyclitis and its complications was not noted until 1910 (Ohm, 1910). Still (1897), in his classical description (the first to appear in this subject in English), makes no mention of such manifestations. More recently, numerous cases with eye lesions have been described (summarized recently by Blegvad, 1941; Franceschetti, 1946; Bonnet, 1953; Vesterdal and Sury, 1950). While the iritis itself does not differ essentially from any other non-granulomatous iritis, it leads in a proportion of children to band keratopathy, which is not seen as a complication of iritis in adults except in degenerating eyes. The present study is concerned particularly with this feature peculiar to childhood and with its treatment, and more generally with other eye manifestations as seen during a period of 7 years at a National Centre for Juvenile Rheumatism.

Material, Methods, and Definition

All children with Still's disease admitted to the Canadian Red Cross Memorial Hospital have been studied for evidence or history of eye lesions. Still's disease has been defined for this purpose as rheumatoid arthritis starting before the age of 16 years with evidence of chronic multiple joint involvement, excluding any such cases obviously belonging to different groupings such as ankylosing spondylitis, chronic rheumatic fever, or lupus erythematosus. Rarely, cases with one joint only involved have been included on biopsy evidence. No exclusions have been made on account of a negative Rose test or negative x ray, since these are

both more commonly negative in children than in adults. After discharge from hospital, almost all children have been examined clinically at yearly intervals or more frequently. The total length of general follow-up varies from 1 to 9 years. In some children with affected eyes, serum calcium, phosphorus, and alkaline phosphatase have been measured by the technique described by King and Wootton (1956).

In addition, one of us (W.K.S.) has examined the eyes of each patient in the first instance with loupe ($\times 10$ magnification) and ophthalmoscope. Any lesion suggestive of old or active inflammation has then been subjected to detailed examination with a slit-lamp microscope. Gross changes, such as corneal band opacity, irregular pupil, or advanced cataract are readily seen macroscopically, but spots of inflammatory pigment on the anterior lens capsule or keratic precipitates on the posterior corneal surface require some magnification for their detection. It should be emphasized that no special training and no elaborate equipment is required to enable one to detect these lesions. The analysis of the microscopic changes and the evaluation of the activity of the inflammation can well be left to the ophthalmologist and the specialized technique of biomicroscopy.

Incidence

We have examined the eyes of 183 cases of Still's disease during the past seven years and have found ten children with ocular manifestations (5.5 per cent.). (In all but three cases the eye changes were detected by the resident medical staff during routine examination.) This excludes one child (Case 11) specifically admitted on account of his eye lesions and mentioned later in this paper

because of his interesting history. The remaining cases were referred on account of their general condition (Table I).

TABLE I

STILL'S DISEASE PATIENTS AT END OF JANUARY, 1957,
WITH 12 MONTHS FOLLOW-UP

Sex	No. of Patients	Deaths	No. with Eye Complications	Average Age at Onset (yrs)	
				Rheumatoid Arthritis Alone	Rheumatoid Arthritis + Affected Eyes
M ..	79	4 (3 S/L ex NAD)*	4	8 $\frac{2}{12}$	7 $\frac{6}{12}$
F ..	104	4 (1 S/L ex NAD)	6	7 $\frac{1}{12}$	4 $\frac{9}{12}$
Total	183	8	10	—	—

* S/L ex NAD=Slit-lamp examination, nothing abnormal detected.

Few other authors give any indication of the incidence of eye involvement in Still's disease, with the exception of the Danish School; Godtfredson (1949) quotes 20 per cent. and Vesterdal and Sury (1950) 21 per cent. of 162 patients.

The figures for iritis complicating adult rheumatoid arthritis are 4.7 per cent. (quoted by Sorsby and Gormaz, 1946), and 3.3 per cent. (Duthie, cited by Stanworth and Sharp, 1956). The percentage obviously depends on the care with which eye lesions are searched for and on the length of time the eyes are kept under observation. Thus Hart (1951) remarks of ankylosing spondylitis that, under the age of 25 with a disease-duration of less than 5 years, cases of iritis are uncommon, but that, over the age of 45 with a disease-duration of over 15 years, some 40 per cent. of patients are found to have iritis. Our series was under detailed ophthalmic observation for a period of 1 to 7 years (mean 3.2 years), and three of our ten cases developed

under observation; in the remainder the condition was present when the patient was first seen.

The impression is formed that iritis, like pericarditis, fever, and splenomegaly, is more common in childhood than in adult rheumatoid arthritis, but it is difficult to place such comparisons on a sound statistical footing. Stanworth and Sharp (1956) are of the opinion that rheumatoid arthritis is not specifically associated with iritis in adults, since the proportion of rheumatoid arthritis found in cases of iritis of unknown origin was similar to that in iritis of known origin. It does seem certain, however, that iritis is more frequent in Still's disease than among the general child population. Thus Blegvad (1941) reviewed all the cases of iridocyclitis in Copenhagen 1929-1939 and found only four children under the age of 10 with this condition (two of whom had Still's disease) and 2.2 per cent. under the age of 15, out of a total of 886 of all ages. Bennett (1955) described 2.1 per cent. under the age of 15 in his Southampton series.

Clinical Characteristics of the Eye Lesions

Iridocyclitis.—This is the primary lesion, and in seven of our eleven cases it was bilateral or became so after a variable interval. Both eyes were not necessarily active at the same time. This iridocyclitis is commonly of a quiet sero-fibrinous non-granulomatous type (Woods, 1947), showing neither iritic nodules nor secondary iris atrophy. Fine posterior synechiae commonly develop and may be seen extending as filmy grey bands from the anterior surface of the iris near the pupil margin to the anterior lens capsule. There is a variable exudation of white cells into aqueous and vitreous which commonly aggregate and adhere to the corneal endothelium as discrete fine white keratic precipitates (Fig. 1).

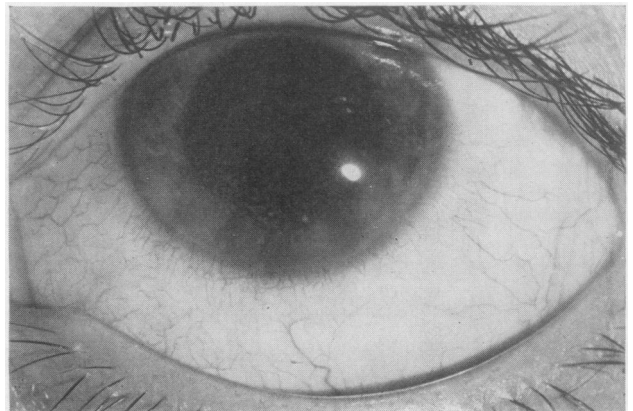

Fig. 1.—Case 1, left eye, showing keratic precipitates.

The detection with the slit-lamp microscope of these circulating white cells in the aqueous is the main method of assessing the activity of the inflammation and its response to treatment.

The quiet insidious nature of the iridocyclitis is characteristic. Injection of the eye is commonly absent or evanescent and there is no pain, so that the patient is often unaware of anything wrong until failing vision compels attention (right eye of Case 1, both eyes of Cases 2, 4, 5, and 6). The inflammation may subside for long periods—months or years (Cases 1 and 3)—and then recur. If these fleeting signs are remarked at all they are too often dismissed as “conjunctivitis” by the physician. Occasionally, the attacks are more severe and the iridocyclitis is sub-acute in nature with definite redness of the eye, photophobia and some discomfort (right eye of Case 3, and left eye of Case 8). Rarely the inflammation is acute with pain, gross exudation of white cells into aqueous and vitreous, and considerable interference with vision (the left eye of Case 1).

Vesterdal and Sury suggest that the more acute forms tend to occur in older children (12 to 17 years) and represent a transitional form between the chronic insidious type in young children and the acute recurrent type of adults. In our series the children showing this more acute type of iridocyclitis were aged 9 (Case 3), 10 (Case 1, left eye), and 15 (Case 8).

Band Keratopathy (Corneal Band Opacity).—This is a striking feature and common complication of the ocular inflammation and occurs in Still's disease only in association with iridocyclitis. In the present series five cases out of eleven (nine eyes out of eighteen with iridocyclitis) showed this phenomenon.

We were able to study the development of such a band *ab initio* in the left eye of Case 1. The first evidence was noticed 10 weeks after the commence-

ment of acute iridocyclitis and could be detected only by the technique of scleral scatter with the slit-lamp microscope, direct illumination of the cornea showing no abnormality. A faint tongue-shaped patch of opalescence could just be distinguished with its base near the limbus and its tip pointing towards the centre of the cornea. It was observed first on the temporal side of the cornea and a few days later on the nasal side, the central area being normal. The characteristic clear fenestrations could not be detected at this stage and indeed did not develop for another 4 weeks. 52 days from its inception the band was seen to extend right across the cornea, the original temporal and nasal parts having coalesced (Fig. 2).

If this is the normal mode of development of the band opacity, it is at variance with the description of Koby (1925). He described “a slight turbidity at the level of Bowman's membrane in which are distinguishable dark round holes . . . These are pathognomonic months or years before visible opacity develops”.

Kurnick (1942) suggests that this corneal change might commonly be found if all children with Still's disease were examined with the slit-lamp microscope. It should be remembered, however, that the band keratopathy only develops in association with iridocyclitis, and that the proportion of cases of juvenile polyarthritis with ocular complications is not high. Moreover, a band opacity is not peculiar to Still's disease, but can occur as a complication of any long-continued iridocyclitis in children. One of us has seen this in two children with Vogt-Koyanagi's syndrome, and Bonnet and Bonnet (1955a, b) described it in association with iritis in toxoplasmosis and with cerebrospinal meningitis. We strongly agree, however, that every case of Still's disease should be examined repeatedly for evidence of ocular involvement.

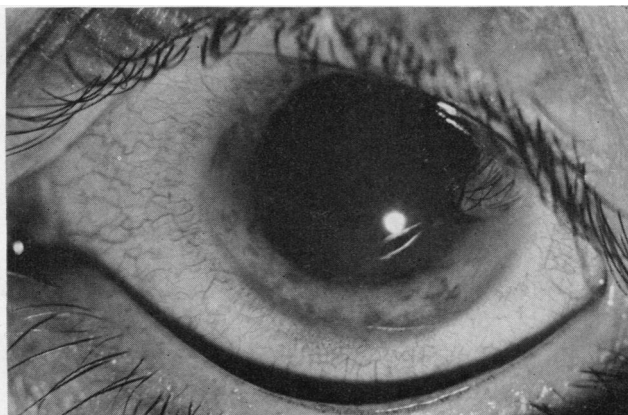


Fig. 2.—Case 1, left eye, showing band extending across cornea from temporal to nasal side.

It is of interest to note that the corneal band in the left eye of Case 1 appeared 3 weeks after the attack of iridocyclitis had been apparently controlled by subconjunctival injections of cortisone, and continued to develop steadily despite further injections. Once this type of keratopathy begins, it can apparently progress even when the causal inflammation ceases. This tendency is seen again in Case 2, in whom the corneal bands have gradually spread and become more dense although no active iridocyclitis has been detected. On the other hand, in a number of our cases, despite continued inflammation for prolonged periods of up to 3 years, either no band has appeared (Cases 4, 6, and 9) or the band has not progressed beyond the juxta-limbal stage (Case 5, Fig. 3, and Case 7). Rarely the band has decreased spontaneously (Hatherley, 1951), but this has not occurred in our series.

The anatomy of the fully-developed band has been described by a number of writers (Zeeman, 1940; Hobbs, 1949; Bonnet, 1956) and our observations agree in general with theirs.

The opacity usually extends across the cornea in the inter-palpebral area, more below than above the centre of the pupil (Case 2, Fig. 4) and is sub-epithelial at the level of Bowman's membrane (Fig. 5, opposite).

It consists of closely-grouped grey dots interspersed with clear round lacunae of varying sizes. These clear fenestrations are said to be caused by the corneal nerve filaments which perforate Bowman's membrane to form the subepithelial plexus. They are present at an early stage and are certainly not due to the sloughing of calcific plaques as suggested by Cogan, Albright, and Bartter (1948). Fissures are also seen resembling cracks in a sheet of ice. In time the older portions become white and chalky and sequestration of the calcareous incrustations may occur. The opacity is avascular and corneal sensation is not diminished except over densely calcified parts. Sisson (1934) describes the opacity as being sharply limited, the remaining cornea being clear.

That this is not always so is seen in Case 2 (Fig. 6, opposite), where diffuse bands extend almost to

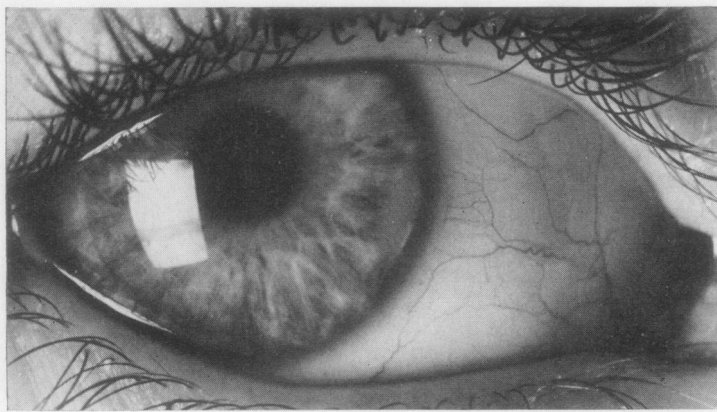
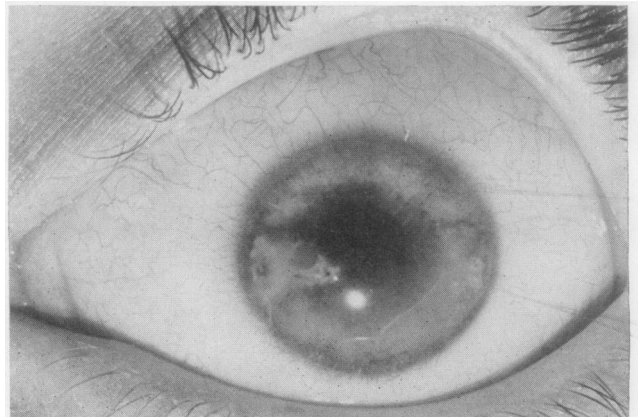

Fig. 3.—Case 5, right eye, showing band opacity at the limbus.

Fig. 4.—Case 2, left eye, showing band opacity extending across cornea and below centre of pupil.



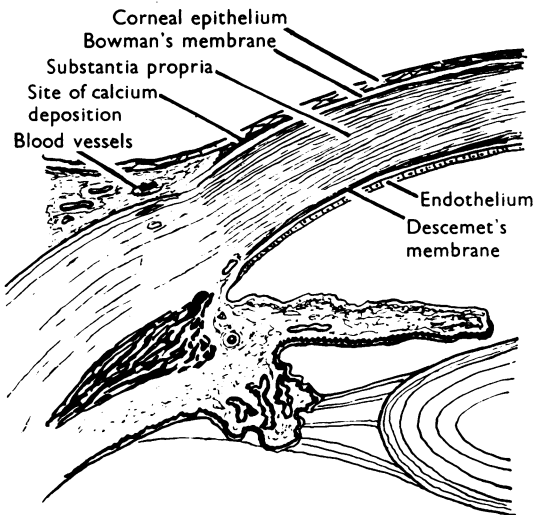


Fig. 5.—Diagram showing site of calcium deposits

including Berliner (1949) and Bonnet (1956) stress that the bands terminate sharply, leaving at each end a clear limbal zone of cornea. Vesterdal and Sury (1950) specifically state that the bulbar conjunctiva is not affected. But Cases 1, 2, 5, and 7 of our series show the bands extending right up to the limbus, and Cases 1, 2, and 11 all show slight but definite involvement of the bulbar conjunctiva. No regression of the band once formed has been seen in our series, unlike the true metastatic corneal band sometimes found in association with a high serum calcium (Howard and Meyer, 1948; Cogan, 1951).

Cataract.—This forms the third feature of what might be called the “ocular triad” of Still’s disease. It is a less common complication than the band keratopathy and occurred in only two cases (four eyes) of the present series (Case 1, Fig. 7, and Case 11). It is seen typically as a complicated cataract, usually first in the posterior lens cortex and then in the anterior cortex, and it matures rapidly, causing profound interference with vision. The fact that both the cases in this series who developed cataracts had to enter Blind Schools emphasizes the seriousness of this complication.

the limbus below and within 2 or 3 mm. above and lack any well-defined margin. This case is similar in appearance to the one depicted by Bonnet and Bonnet (1953). All previous writers,

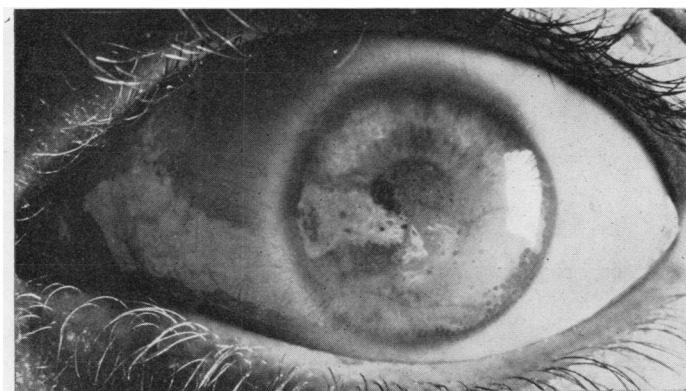
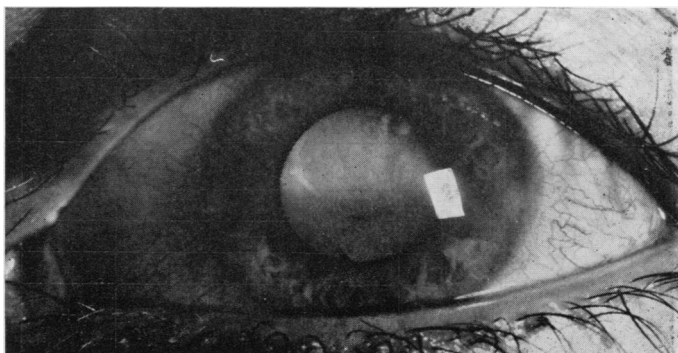


Fig. 6.—Case 2, left eye, showing diffuse band opacity extending almost to the limbus above and below.

Fig. 7.—Case 1, left eye, showing complicated cataract and band keratopathy.



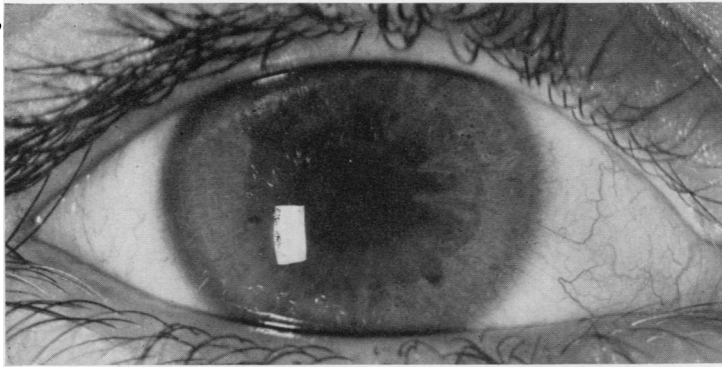


Fig. 8.—Case 9, right eye, showing posterior synechiae and capsular deposits.

Fibrinous Exudate.—This and other inflammatory deposits on the lens capsule in the pupillary area (Case 9, Fig. 8) can also cause considerable interference with vision and may be followed by localized subcapsular opacities.

Correlation with other Aspects of the Disease

In eight of our eleven patients, joint involvement preceded eye involvement by periods of 1 to 11 years (mean 3.6 years). In two cases joint and eye

inflammation virtually coincided. In one case only (Case 11) did the eye changes precede the joint changes, and this by some 2½ years. This boy was originally diagnosed as having bilateral “conjunctivitis” by his doctor in May, 1949, with a recurrence in August. One month later the condition was discovered to be iridocyclitis by a school oculist who referred the boy to the Royal Eye Hospital, London, where he was seen by one of us (W.K.S.). In February, 1950, he was admitted to

T
PARTICULARS OF ELEVEN P.

Case No.	Sex	Age (yrs)			Length of Follow-up from First Exam. to Jan. 1957	Fever + or 0	During Course			Joints at Onset of Eye Trouble		
		At Onset of R.A.	At Onset of Eye Trouble	At Cessation of Activity			Rash + or 0	Nodules + or 0	D.A.T.	Action or Inaction (A or I)	No. of Joints	Symmetric or Asymmetric (S or A)
1	M	9½	9½	11	7½	+	0	0	1:16	A	5	S
2	F	1½	12½	13	6	+	0	0	1:16	A	12	S
3	M	7½	9½	12½	5	+	+	0	1:32	A	5	A
4	F	4½	8½	—	3	+	0	0	1:8	A	6	S
5	F	2½	5½	—	3	+	0	0	1:16	I	12	S
6	F	3½	7½	—	2½	+	0	0	1:4	I	2	A
7	F	5	8½	—	2½	+	0	0	1:4	I	1	A
8	F	16½	16½	16½	1	+	0	0	1:8	A	20	A
9	M	6½	7½	—	1	+	0	0	1:32	A	1	A
10	F	1½	2½	—	1	+	0	0	1:2	A	5	A
11	M	7½	4½	5½	5	+	0	0	1:32	I	1	A

OCULAR PRESENTATIONS OF STILL'S DISEASE AND THEIR TREATMENT 377

King's College Hospital for investigation, but no evidence of Still's disease was found. At this stage the ocular triad was definitely established in both eyes. In November, 1951, he was admitted to this Unit where the right wrist joint was found to be involved. In August, 1953, the left ankle joint became affected.

This "eye-before-joint" order of involvement has been noted by other writers (Blegvad, 1941; Vesterdal and Sury, 1950; Franceschetti, Blum, and Bamatter, 1951; Hatherley, 1951), but usually the interval is one of months rather than years.

There seems to be no relation between eye involvement and the severity of the arthritis (Table II).

Course and Complications

The course of the ocular inflammation is variable and largely unpredictable. Of our eleven cases, five are still active (Cases 5, 6, 7, 9, and 10) despite more than 2 years of treatment in three instances three are quiescent with normal vision (Cases 3, 4, and 8), one is in a Blind Home with bilateral phthisis bulbi (Case 11), one has recently returned to normal life from a Blind Home after multiple

operations (Case 1), and one with evidence of old iridocyclitis and gross band opacities (Case 2) has never shown active inflammation during 6 years of observation.

It is interesting to note that, despite the absence of inflammation in Case 2, both corneal bands became gradually denser and more diffuse. Fortunately this patient did not develop cataracts and her visual acuity remained much better than one would expect with such gross corneal changes, being 6/12 in the right eye and 6/18 partly in the left eye before chelation.

The development of cataract carries a much graver visual prognosis than band keratopathy. Thus, in Case 1, the iridocyclitis in the right eye had subsided before admission to this Unit without treatment except for a few weeks on atropine 8 months before, and the inflammation has not recurred during the following 7 years of supervision. This boy developed both a complicated cataract and a band opacity, and his visual acuity was reduced to 6/60. When his cataract was later dispersed by repeated needlings a further complication was discovered: a vitreous haze so dense

TABLE II
PATIENTS WITH AFFECTED EYES

Eye Changes During Course		Type of Eye Treatment	During Course			Present Visual Acuity	
Bilateral or Unilateral (B or U)	Type of Lesion		Ca mg. per cent.	P mg. per cent.	Alkaline Phosphatase (King-Armstrong units)	Right	Left
B	Iridocyclitis, Band Keratopathy, Cataracts, Left Vitreous Haze	Subconjunctival Cortisone, Needling, ACTH, EDTA	11.0	4.7	19	Pre-operative 6/60 Post-operative 6/24	Perception of Light 6/9
B	Iridocyclitis, Band Keratopathy	EDTA	9.6	3.6	3.4	Pre-operative 6/18 Post-operative 6/12	6/18 6/12
U	Right Iridocyclitis	Subconjunctival and Systemic Cortisone	—	—	—	6/6	6/6
B	Iridocyclitis	Systemic Cortisone	—	6.1	8.6	6/6	6/6
B	Iridocyclitis, Band Keratopathy	Systemic Delta-hydrocortisone, ACTH	9.9	3.2	6.0	6/18	6/18
B	Iridocyclitis	Systemic Cortisone and Delta-hydrocortisone, Cortisone Drops	8.5	3.8	6.7	6/6	6/6
U	Iridocyclitis, Band Keratopathy	Systemic Delta-hydrocortisone, Cortisone Drops	10.5	2.7	8.8	6/6	6/6
U	Iridocyclitis	Cortisone Drops	—	—	—	6/6	6/6
B	Iridocyclitis	Systemic Cortisone	9.0	2.8	9.4	6/12	6/12
U	Iridocyclitis	Systemic Cortisone	9.0	4.0	6.8	See Text	
B	Iridocyclitis, Band Keratopathy, Cataracts	Operation for Secondary Glaucoma	10.9 and 11.9	4.7	10	No Perception of Light	

that retinal details were obscured. Vitreous opacities in cyclitis may be the cellular products of inflammation and as such may in the course of time be eliminated; they may also, however, be protein coagula and indicate an irreversible gel-sol transformation in the vitreous. A permanently cloudy vitreous can defeat all efforts to restore adequate vision despite removal of cataract and band opacity. In the case under consideration, the opacities were at least in part cellular for the haze gradually lessened and 18 months later the visual acuity in the operated eye was 6/36 with correcting lens. The inflammation in the other (left) eye of Case 1 developed in quite a different way from the usual insidious asymptomatic course. In December, 1949, the eye was normal, with a visual acuity of 6/9 without glasses. In July, 1950, a few old keratitic precipitates were noted on the cornea, but no active inflammation. In November he was readmitted to this unit with a history of 4 weeks' severe inflammation in his left eye, treated with atropine. He was found to have an acute iridocyclitis, with gross keratitic precipitates, and such a profound vitreous haze that no fundus details could be seen. The visual acuity was reduced to perception of hand movements. Two weeks later, after several subconjunctival injections of cortisone, the inflammation was controlled but the vitreous haze persisted. One month later the first signs of band keratopathy were detected and in another month a complicated cataract was seen to be developing. In June, 1951, 8 months after the acute attack had begun the visual acuity was 6/36. Some ACTH became available and, in an effort to clear the vitreous haze, 500 mg. was given in 10 days, but with only minor improvement. No further attacks of cyclitis occurred, but the cataract progressed and the corneal band thickened. In 1955 the cataract was needled and some months later the corneal band was removed by chelation. The visual acuity is now 6/9 partly with glasses.

Secondary glaucoma is another possible complication of iridocyclitis. Extensive adhesions between iris and lens result in seclusio pupilli and iris bombé which must be promptly relieved by iridectomy. Vesterdal and Sury quote several cases, and Case 11 of our series had to have a bilateral iridectomy for this reason.

Hypotony can also occur as a terminal event when the ciliary body is so disrupted by prolonged inflammation that the ciliary processes can no longer produce aqueous humour: phthisis bulbi then gradually develops. The right eye of Case 11 followed this unfortunate course after years of inflammation, perhaps precipitated by needling and subsequent curette evacuation of the lens (Fig. 9). The left eye, however, degenerated in the same way some time later without having suffered any surgical interference.

Choroiditis has not been noted in our series. Vesterdal and Sury found a choroidal focus in one of their 34 cases.

Treatment and Prognosis

Control of the iridocyclitis is of fundamental importance since this is the primary lesion from which the others develop. Mydriatics and cortisone are the most useful agents for this purpose, and are, of course, combined with therapy directed towards the illness as a whole. Neither is curative, but by suppressing inflammation and by preventing adhesions, they tide the patient's eyes over until remission occurs and the local disease "burns itself out" with minimal damage.

Cortisone and hydrocortisone 1 per cent. drops and ointment are of more value in acute iritis (Case 8) than in the more typical chronic insidious anterior uveitis of Still's disease. Drops should be instilled 2- or 4-hrly during the day and the ointment before going to sleep at night. Frequently repeated subconjunctival injections are rarely feasible in

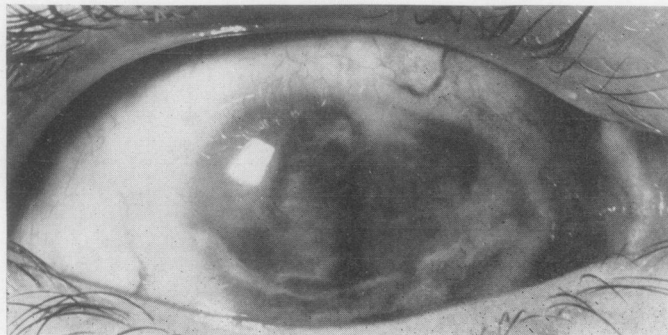


Fig. 9.—Case 11, right eye, showing phthisis bulbi.

young children because of their need for general anaesthesia, but they proved of value in one of our older children (Case 1, left eye) who showed a very acute inflammation. 0.25 to 0.5 ml. containing 25 mg./ml. is injected every 5 to 7 days beneath the bulbar conjunctiva. Systemic cortisone therefore becomes of necessity the usual mode of administration. Steroid therapy may well be indicated in any case because of joint involvement, but when the eyes alone are actively inflamed the risks of undesirable and possibly dangerous side-effects and of prolonged hospitalization are to be incurred only if local cortisone has been proved inadequate. (We have encountered osteoporosis with collapse of vertebrae in one case after long-continued treatment. Other serious dangers are hypertension and peptic ulceration.) The decision having been made, however, the aim should be to control the inflammation as rapidly as possible with a daily dosage in the order of 100-150 mg. cortisone or its equivalent of other analogues. This dosage should then be reduced by stages to the lowest daily dosage that will maintain the eye free from evidence of inflammation. The criterion of activity is the presence of inflammatory cells in the aqueous as seen by slit-lamp microscopy. This examination, often difficult and time-consuming with young children, must be repeated at least weekly until the eye is quiet, and then at longer intervals for months or years to guard against recurrence. Disappointing recurrences are the rule and then the routine of treatment must begin again. One gets the clinical impression that the more acute types of iridocyclitis respond most rapidly to treatment and may carry a better prognosis than the chronic indolent types. Thus Case 8 cleared rapidly on cortisone drops and atropine and the inflammation has not recurred during one year's observation. Case 3 has had two attacks in 5½ years each lasting for less than 4 weeks, the first clearing on atropine and systemic cortisone, the second on atropine and

subconjunctival cortisone. Case 1 has already been detailed: it seems possible that the inflammation would have been rapidly controlled if cortisone had been available at the onset to control the inflammation, and that the vitreous exudation, complicated cataract, and band opacity might then never have developed.

Although five of our eleven cases still show a variable amount of active inflammation despite treatment for periods of from 2½ years to 6 months, none of these children has developed a complicated cataract or a progressive band opacity, and in four of the cases the vision of even the worse eye is 6/18 or better. The sixth child (Case 10) is too young for her vision to be accurately assessed, although the appearance of her affected eye suggests a vision of certainly not worse than 6/18.

Cataract is the complication causing the greatest visual deterioration. It can be removed by repeated needling operations (Fig. 10), but only when the iridocyclitis has been fully controlled and the eye has been free from inflammation for some months. The trauma of operation may precipitate a further attack and local cortisone should be used routinely after surgery to forestall this complication. Vesterdal and Sury (1950) noted that the surgical treatment of cataract in their series was not particularly successful. In our series of three eyes needled, one is blind, the second has a visual acuity of 6/24, and the third of 6/9. It is perhaps significant that only this last eye had the benefit of cortisone therapy to control its iridocyclitis. Secondary glaucoma from seclusio pupilli will require iridectomy for its control (Case 11, both eyes).

Corneal band opacity does not need treatment unless it obscures the pupillary area. With a sufficiently gross opacity, lamellar keratoplasty might seem to be indicated (Bonnet, 1956), but this operation is not without risk and requires specialized surgical and nursing facilities only available in large

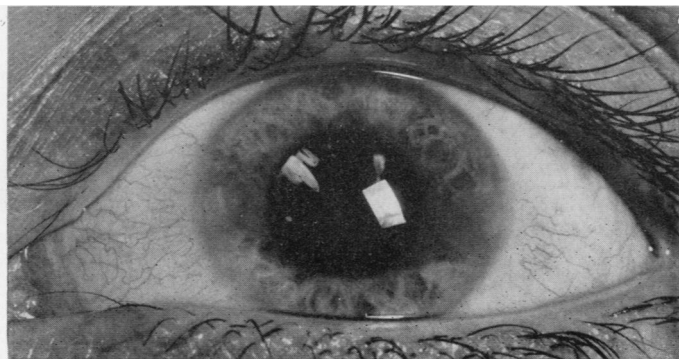


Fig. 10.—Case 1, left eye, after removal of cataract by repeated needling.

ophthalmic units. An alternative more recent method of removing the worst of the opacity by chelation is much simpler and involves negligible risk. Chelating agents are compounds which form soluble complexes with various metallic ions and thus remove them from their chemical environment. Grant (1952) reported on the use of disodium dihydrogen versenate in the removal of calcium from a cornea with band opacity. Breinin and De Voe (1954) treated six eyes with this condition with gratifying results. Quinn and Crookes (1955) reported similarly on one case.

In this Unit four eyes (Cases 1 and 2) have been treated, and the results encourage further trial. After thorough curettage of the corneal epithelium overlying the opacity, a bath of the chelating agent (0.37 g. E.D.T.A. in 100 ml. distilled water adjusted to neutral pH) is applied to the cornea for 15 minutes. Calcium salts are readily removed thus from the cornea within this period and the cosmetic appearance a few days later, when the corneal epithelium has regenerated, suggests that a lamellar keratoplasty is not only unnecessary but unjustifiable. The photographs of Case 2 before treatment

(Fig. 11) and after treatment (Fig. 12) illustrate the improvement. Because of old inflammatory deposits on the lens capsules, which could be clearly seen after the treatment, this patient's visual acuity only improved from approximately 6/18 to 6/12 in each eye. She herself, however, was in no doubt about the general improvement in definition and was particularly delighted with her enhanced colour perception. Chelation removal, however, would leave behind any matrix for calcium deposition, such as the polysaccharide-rich ion-exchange medium posited elsewhere by Sobel and Burger (1954). It is, however, by no means clear whether such a matrix exists in this condition and in this place. Thus, in Boeck's sarcoidosis with iritis, correction of the underlying hypercalcaemia has led to complete disappearance of band opacity (Mather, 1957).

Mechanism of Band-Shaped Opacities

Primary band-shaped opacity is mainly an affection of old age (Duke-Elder, 1940) and was first described as such by Dixon (1848). The type secondary to severe iridocyclitis usually occurs in

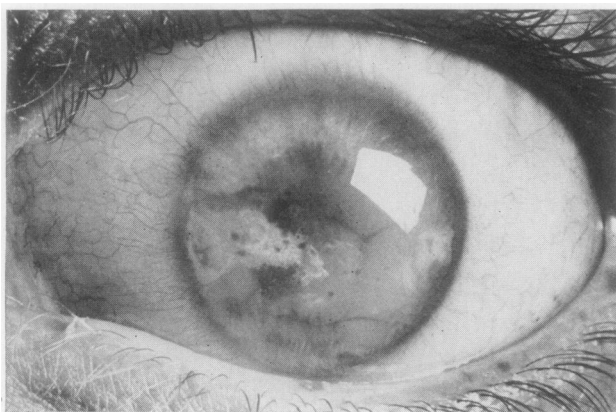
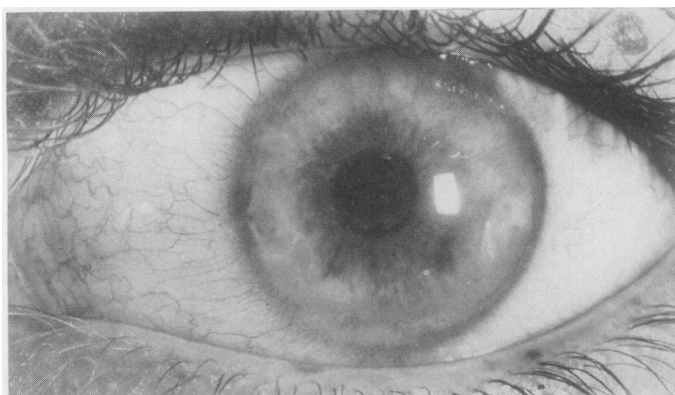

Fig. 11.—Case 2, left eye before chelation, showing calcium deposits in corneal band.

Fig. 12.—Case 2, left eye 6 days after chelation, showing cleaning of the cornea (pupillary area only treated). Note old inflammatory deposits on anterior lens capsule.



adults only when the eye is so disorganized by prolonged inflammation that it is blind and degenerating. In children with iridocyclitis from whatever cause, a band-shaped opacity tends to appear at a much earlier stage in a functioning and viable eye. Another secondary type, hypercalcaemic in origin, occurs mainly in adults and is apparently indistinguishable from the type secondary to iritis. Pathologically, granules are seen on the outer side of Bowman's membrane just beneath the epithelium (Nettleship, 1873, 1879; Usher, 1893). These have been identified in hypercalcaemic cases as tricalcium phosphate (Gartner and Rubner, 1955, cited by Wagener, 1956), and calcium and phosphorus have also been identified (Duke-Elder, 1940) in the type secondary to iritis. It is uncertain in this latter type whether calcium is deposited in normal tissue or in an area of hyaline degeneration such as that described by Gifford (1924).

The description by Walsh and Howard (1947) of band-shaped opacity due to hypercalcaemia, associated with Vitamin D intoxication (Howard and Meyer, 1948), immobilization (Cogan and others, 1948), sarcoidosis (Haldimann, 1941), hyperparathyroidism, alkaline powder intoxication (Snapper, Bradley, and Wilson, 1954), or renal insufficiency, leads one to think that this lesion could be entirely due to metastatic calcification, *i.e.* that it could occur in normal tissue because of a raised blood calcium level. However, in our cases, the serum calcium was within normal limits in the eight cases where it was measured: and only one was noted to have had Vitamin D treatment (although this was a popular treatment for rheumatoid arthritis some years ago in the U.S.A.). It seems more likely to be a mechanism associated with inflammation of the uveal tract, although there is little need to posit dystrophic calcification (calcification on a basis of abnormal degenerative material).

Calcium in this position must have diffused in from the limbus, since the deposit occurs first peripherally. Diffusion from the aqueous humour (with a calcium content of 5 mg. per cent.) directly across an injured endothelial layer, Descemet's membrane, and substantia propria seems unlikely, since it would affect the centre as much as the periphery. It may be that the increased vascular permeability of the acute phase allows more protein-bound calcium and ionized calcium to diffuse centripetally, and that subsequent loss of carbon dioxide allows precipitation to occur in the superficial layers. This mechanism would then be similar to that postulated in metastatic calcification to account for calcium deposition under the nails, in the tracheae and lungs, in the arteries, and at sites

of acid formation such as the stomach and kidneys. Cogan (1951) has thought the process in hypercalcaemic band-shaped opacity to be one of precipitation from a supersaturated solution, due perhaps partially also to loss of water vapour as well as to carbon dioxide loss.

Assuming therefore that this is metastatic calcification, with normal blood levels but increased vascular exudation, and similar in many ways to that occurring in hypercalcaemia, this leaves unexplained its occurrence in childhood iritis and its rarity in adults. It may be that the higher serum inorganic phosphorus of children may conduce to this, since this is the most important factor next to the serum calcium level in controlling calcium deposition. Another possible factor in some cases is a temporary increase of serum calcium due to immobilization (Albright, Burnett, Cope, and Parson, 1941). This increase would not of course be detected by a serum calcium estimation performed perhaps years later, in hospital, with the lesion already developed, but we think it unlikely to be a very important factor for two reasons. Firstly, band keratopathy was seen in Case 2, who had no immobilization and no arthritis, and in Case 1, who had had arthritis but no immobilization by the time band keratopathy appeared: furthermore, no band keratopathy was seen in two patients immobilized during the active phase of iritis. Secondly, the hypercalcaemia of immobilization occurs in previously healthy patients with well calcified bones and not in bones osteoporotic with relative disuse such as most of these immobilized children possessed.

If the theory outlined above on calcium deposition is correct, possible lines of prevention would include attempts to lower the blood phosphorus level and to prevent carbon dioxide loss from the eye until the inflammatory attack was well under control with steroid.

Summary

183 children with Still's disease admitted to the Canadian Red Cross Memorial Hospital have been examined for ocular abnormalities, with a duration of follow-up from first attendance ranging from 1 to 9 years. Ten cases (5.5 per cent.) of ocular involvement were found amongst those admitted for their joint condition, and one further case was specifically admitted on account of his eye condition which had appeared 2½ years before the onset of joint involvement.

The clinical characteristics of the iridocyclitis and its complications are described. In particular, the insidious nature of the iridocyclitis is stressed,

since this often leads to progressive impairment of vision unless detected and treated. Band keratopathy occurred in nine eyes out of the eighteen with iridocyclitis, and began while under observation in one case. Early stages of development are described, and the course leading to calcific plaque formation is illustrated. Complicated cataract, vitreous opacities, secondary glaucoma, and hypotony leading to phthisis bulbi were also seen.

Treatment with mydriatics, with systemic and local cortisone and its analogues, and with ACTH was used in this series with some success. Three eyes were needled for cataract and in two of these useful vision resulted. Established band opacity was treated with a chelating agent in four eyes with improvement in vision and in appearance.

The mechanism of formation of the band-shaped opacity is discussed and it is suggested that it may be similar in nature to that seen in hypercalcaemia. In our cases the serum calcium levels were within normal limits.

We wish to thank Mr. P. J. Fiske, Medical Photographer at the Canadian Red Cross Memorial Hospital, for the illustrations in this paper.

REFERENCES

- Albright, F., Burnett, C. H., Cope, O., and Parson, W. (1941). *J. clin. Endocr.*, 1, 711.
- Bennett, G. (1955). *Brit. J. Ophthalm.*, 39, 727.
- Berliner, M. L. (1949). "Biomicroscopy of the Living Eye", vol. 1, p. 343. Hoeber, New York.
- Blegvad, O. (1941). *Acta ophthalm. (Kbh.)*, 19, 219.
- Bonnet, I. (1953). "Les manifestations oculaires dans les rhumatismes chroniques de l'enfance". Bosc, Lyons.
- Bonnet, P. (1956). *Arch. Ophthalm.*, 16, 12.
- and Bonnet, I. (1953). *Ibid.*, 13, 127.
- (1955a). *Rev. Oto-neuro-ophthal.*, 27, 482.
- (1955b). *Bull. Soc. Ophthalm. Fr.*, No. 9, p. 703.
- Breinin, G. M., and De Voë, A. G. (1954). *A.M.A. Arch. Ophthalm.*, 52, 846.
- Cogan, D. C. (1951). *Amer. Practit. (Philad.)*, 2, 980.
- , Albright, F., and Barter, F. C. (1948). *Arch. Ophthalm. (Chicago)*, 40, 624.
- Cornil, V. (1864). *Mém. Soc. Biol. (Paris)*, Sér. 4, 1, 3 (Pubd. 1865).
- Dixon, J. (1848). "Diseases of the Eye". London. (Cited by Duke-Elder, 1938).
- Duke-Elder, S. (1938). "Text-book of Ophthalmology", vol. 2, p. 2012. Kimpton, London.
- (1940). *Ibid.*, vol. 3, p. 2155.
- Franceschetti, A. (1946). *Ophthalmologica (Basel)*, 111, 242.
- , Blum, J. D., and Bamatter, F. (1951). *Trans. ophthalm. Soc. U.K.*, 71, 17.
- Gartner, S., and Rubner, K. (1955). *Amer. J. Ophthalm.*, 39, 658.
- Gifford, S. R. (1924). *Klin. Mbl. Augenheilk.*, 73, 346.
- Godtfredsen, E. (1949). *Brit. J. Ophthalm.*, 33, 261.
- Grant, W. M. (1952). *A.M.A. Arch. Ophthalm.*, 48, 681.
- Haldimann, C. (1941). *Ophthalmologica (Basel)*, 102, 138.
- Hart, F. Dudley (1951). *Trans. ophthalm. Soc. U.K.*, 71, 167.
- Hatherley, E. (1951). *Proc. roy. Soc. Med.*, 44, 978.
- Hobbs, H. E. (1949). *Ibid.*, 42, 755.
- Howard, J. E., and Meyer, R. J. (1948). *J. clin. Endocr.*, 8, 895.
- King, E. J., and Wootton, I. D. P. (1956). "Micro-Analysis in Medical Biochemistry", 3rd ed. Churchill, London.
- Koby, F. E. (1925). "Slit-Lamp Microscopy of the Living Eye", trans. C. Goulden and C. L. Harris. Blakiston, Philadelphia.
- Kurnick, N. B. (1942). *Amer. J. Dis. Child.*, 63, 742.
- Loewenstein, A. (1946). *Brit. J. Ophthalm.*, 30, 317.
- Mather, G. (1957). *Brit. med. J.*, 1, 248.
- Nettleship, E. (1873). *Roy. Lond. ophthalm. Hosp. Rep.*, 7, 528.
- (1879). *Arch. Ophthalm. (N.Y.)*, 8, 293.
- Ohm, J. (1910). *Klin. Mbl. Augenheilk.*, 48 (2) [n.s. 10], 243.
- Quinn, C. A., and Crookes, G. P. (1955). *Trans. ophthalm. Soc. U.K.*, 75, 705.
- Sisson, R. J. (1934). *Amer. J. Ophthalm.*, 17, 222.
- Snapper, I., Bradley, W. G., and Wilson, V. E. (1954). *Arch. Intern. Med.*, 93, 807.
- Sobel, A. E., and Burger, M. (1954). *Proc. Soc. exp. Biol. (N.Y.)*, 87, 7.
- Sorsby, A., and Gormaz, A. (1946). *Brit. med. J.*, 1, 597.
- Stanworth, A., and Sharp, J. (1956). *Annals of the Rheumatic Diseases*, 15, 140.
- Still, G. F. (1897). *Med-chir. Trans.*, 80, 47 (reprinted in *Arch. Dis. Child.*, 1941, 16, 156).
- Usher, C. H. (1893). *Roy. Lond. ophthalm. Hosp. Rep.*, 13, 508.
- Vesterdal, E., and Sury, B. (1950). *Acta ophthalm. (Kbh.)*, 28, 321.
- Wagener, H. P. (1956). *Amer. J. med. Sci.*, 231, 218.
- Walsh, F. B., and Howard, J. E. (1947). *J. clin. Endocr.*, 7, 644.
- Woods, A. C. (1947). *Amer. J. Ophthalm.*, 30, 257.
- Zeeman, W. P. C. (1940). *Ned. T. Geneesk.*, 84, 134.

Présentations oculaires de la maladie de Still et leur traitement

RÉSUMÉ

Cent-quatre-vingt-trois enfants atteints de maladie de Still et admis au *Canadian Red Cross Memorial Hospital* ont été examinés pour anomalies oculaires. L'observation continue depuis le premier examen allait de 1 à 9 ans. Dix cas (5,5 pour cent) d'implications oculaires furent découverts parmi les malades admis pour leur état articulaire; un autre cas fut admis spécifiquement en raison de son affection oculaire qui s'était manifestée deux ans et demi avant le début de l'implication articulaire.

On décrit les caractères cliniques de l'iridocyclite et ses complications. On souligne le caractère insidieux de cette affection qui, à moins qu'on ne la décèle et traite, mène à l'affaiblissement progressif de la vue. Des bandes de kératopathie se sont produites dans neuf des dix-huit yeux atteints d'iridocyclite, commençant dans un cas durant la période d'observation. On en décrit les premières étapes et on illustre le processus conduisant à la formation des plaques de calcification. On a noté aussi des cataractes compliqués, des opacités vitreuses, un glaucome secondaire et une hypotonie conduisant à la contraction du globe oculaire.

Le traitement à l'aide des mydriatiques, de la cortisone et de ses analogues localement et généralement et de l'ACTH fut employé avec quelques succès. Trois cataractes furent opérées à l'aiguille et dans deux yeux on obtint une vision utile. Les bandes d'opacité établies furent traitées par *chélation* (application d'une solution d'un composé chimique ayant le pouvoir d'enlever les ions de calcium) dans 4 yeux, avec amélioration de la vue et de l'apparence.

On discute le mécanisme de formation des opacités en bande et on suggère qu'il serait de même nature que celui dans l'hypercalcémie. Dans nos cas les chiffres du calcium sanguin se trouvaient dans des limites normales.

Presentaciones oculares de la enfermedad de Still y su tratamiento

SUMARIO

Ciento ochenta y tres niños afectos de enfermedad de Still y hospitalizados en *Canadian Red Cross Memorial Hospital* fueron investigados respecto a anomalías oculares. El tiempo de observación continua desde el primer examen fue de uno a nueve años. Diez casos (5,5 por ciento) de implicación ocular fueron encontrados entre los enfermos hospitalizados por su afección articular; un otro caso fue admitido específicamente por su afección ocular que se había manifestado dos años y medio antes del comienzo de la implicación articular.

Se describen los rasgos clínicos de la iridocyclitis y sus complicaciones. Se subraya el carácter insidioso de esta afección que, a menos de observarla y tratar, lleva

a la debilitación progresiva de la vista. Fajas de queratopatía produjéronse en nueve de los diez-y-ocho ojos afectados de iridociclitis, empezando en un caso durante el período de observación. Se describen las primeras fases y se ilustra el proceso que conduce a la formación de las placas de calcificación. Se notaron también cataratas complicadas, opacidades vitreas, un glaucoma secundario y una hipotonía conduciendo a la contracción del globo ocular.

El tratamiento con midriáticos, cortisona y sus análogos local y generalmente y con ACTH se empleó

con resultados bastante buenos. Tres cataratas fueron tratadas con aguja y en dos ojos se obtuvo una visión útil. Las fajas de opacidad establecidas fueron tratadas por *chelation* (aplicación de una solución de un compuesto químico dotado del poder de extraer los iones de calcio) en 4 ojos, con mejoría de la visión y apariencia.

Se discute el mecanismo de formación de las fajas de opacidad y se sugiere que su naturaleza sería la misma que la en la hipercalcemia. En nuestros casos las cifras de calcio en el suero encontrábanse dentro de los límites normales.