

SARCOIDOSIS PRESENTING WITH POLYARTHRITIS

BY

MICHAEL J. WILLIAMS

Aberdeen Royal Infirmary

Polyarthritis is a frequent presenting symptom in patients with sarcoidosis (Scadding, 1956; James, 1956). It is especially common in association with erythema nodosum; the combination of polyarthritis, erythema nodosum, and bilateral hilar adenopathy forming one of the distinctive syndromes of this disease (Löfgren, 1953; James, Thomson, and Willcox, 1956).

Thus, Löfgren, in his series of 212 cases of bilateral hilar adenopathy believed to be due to sarcoidosis, found 113 cases with erythema nodosum, of whom 101 (89 per cent.) had articular symptoms. Of those without erythema nodosum, eighteen (18 per cent.) had articular symptoms (Löfgren, 1953). Similarly, James (1959) found associated polyarthralgia in 64 per cent. of a series of 62 cases of histologically proven sarcoidosis presenting with erythema nodosum. Despite the marked frequency of polyarthritis in these and other large series, little attention has been given to the pattern or duration of the joint involvement apart from mention of its similarity to acute rheumatism (James, 1958). The striking systemic upset accompanying the polyarthritis has also received little stress.

Löfgren (1953) stated that the articular symptoms are mild in type, generally subsiding within a couple of weeks with reversion to normal of the sedimentation rate; apart from fever at the onset he did not mention systemic symptoms.

This report concerns seven patients seen within a period of 18 months in a general medical unit in all of whom polyarthritis was the presenting symptom. Typical skin changes of erythema nodosum developed subsequently in five cases. The diagnosis of sarcoidosis was confirmed in six cases by the Kveim Test.

Clinical Findings

Age and Sex.—As shown in Table I (opposite), the seven patients consisted of six women and one man, their ages ranging from 28 to 57 years. Six of the patients lived in the country. None of the females had had recent pregnancies. James (1958), working in London, noted that sarcoidosis presenting with erythema nodosum was especially common in

women, and mentioned its development coinciding with lactation.

Polyarthritis.—This was the presenting manifestation in all cases, preceding the development of skin lesions (Table I). The average duration of symptoms was 5 weeks (range 2 to 10 wks). In all cases, ultimate resolution occurred without specific therapy and no residual effects have been observed.

Joint involvement was manifested by pain and stiffness, the latter usually being worst in the morning and improving with use. It was chiefly the large joints that were affected (Table II, opposite).

Involvement of the ankle joints, which occurred in six patients, appears to be a striking feature of this form of polyarthritis; the ankles were the first joints involved in five cases and the only joints involved in two. Joint effusions were not present in any case and joint swelling and discoloration were also absent, except in the ankle joints, where marked peri-articular oedema, unrelated to overlying skin changes, was noted in all six cases in which the ankles were affected. The striking incidence of ankle-joint involvement and the presence of peri-articular oedema was noted by Löfgren (1953), but has not been mentioned by workers in Great Britain.

Many workers have stressed the similarity between the polyarthritis in this condition and acute rheumatism. In the present cases, however, the fitting arthralgia of acute rheumatism was never observed, although there was often an interval of 24 to 48 hours between the involvement of successive joints. Furthermore, salicylates had no significant effect on the joint pains in the four cases in which they were given, despite adequate dosage.

In addition to actual arthralgia, four patients complained of marked muscular pain and stiffness, usually in the calves and thighs, but also, in one patient, in the back and shoulders. In two patients, these symptoms preceded the onset of arthralgia by 2 weeks and 3 days respectively, and in the others they developed simultaneously, although they preceded the appearance of skin lesions in all cases.

TABLE I
CLINICAL FINDINGS

Case No	Age (yrs)	Sex	Polyarthrits		Skin Lesions		Systemic Upset	
			Relation to Skin Lesions	Duration (wks)	Nature	Duration (wks)	Nature	Duration (wks)
1	36	M	2 wks before	5	Erythema nodosum	3	Tiredness, anorexia, weight loss, sweating, fever up to 101° F.	5
2	53	F	1 wk before	6	Erythema nodosum	3 "crops" over 5 wks	Tiredness, sweating, generalized aches, fever up to 100° F.	8
3	39	F	10 days before	7	Erythema nodosum	2	Tiredness, sweating, weight loss, generalized aches, fever up to 99·5° F.	9
4	55	F	3 days before	2½	Erythema nodosum	2 Recurrence after 6 wks lasting 1 wk	Tiredness, sweating, weight loss, pains in arms, fever up to 100° F.	18
5	28	F	4 wks before	10	Erythema nodosum	2 "crops" over 4 wks	Tiredness, sweating, anorexia, weight loss, diffuse pains, no fever	11
6	57	F	No skin lesions	2	None		Tiredness, sweating, fever up to 99° F.	12
7	43	F	1 wk before	3	Erythema multiforme	1	Tiredness, anorexia, weight loss, no fever	3

TABLE II
INCIDENCE OF JOINT INVOLVEMENT

Joints Involved	No. of Cases
Ankles	6
Knees	4
Hips	1
Hands	3
Wrists	3
Elbows	3
Shoulders	2

Skin Lesions.—Erythema nodosum developed in five patients. The lesions, which were typical in appearance, were always present on the legs, but also occurred on the arms in two cases. In three cases, successive "crops" of lesions appeared, two having two "crops" and one three "crops". There was no apparent relationship in these patients between joint symptoms and the "crops" of skin lesions. In one other patient, erythema multiforme developed, and the last showed no skin lesions at all. The duration of the skin lesions and their relationship in time of onset to the joint symptoms is shown in Table I. Transient papular or vesicular rashes, as described by James (1959) in this type of case, were not seen.

Systemic Symptoms.—These were present in every case, with accompanying persistent fever in five

cases. The relevant symptoms and their duration are shown in Table I.

In four cases, the development of systemic symptoms coincided with the onset of joint symptoms, but in three cases, they preceded the onset of joint symptoms by several weeks. In the majority of cases, the two groups of symptoms subsided simultaneously.

Two patients gave a history of sore throat, but this followed the onset of arthralgia in both instances, although it preceded the appearance of erythema nodosum by 2 and 3 days respectively. Sulphonamides had not been given in either case.

Superficial lymph-gland enlargement and hepatosplenomegaly were never found and examination of the eyes and other systems failed to reveal evidence of sarcoidosis. None of the patients had clinical evidence of cardiac involvement.

Electrocardiograms were taken in four cases and two showed non-specific myocardial changes, maximal in the left ventricular leads. The time of persistence of these changes is unknown, but both had reverted to normal 3 months later. Similar transient electrocardiographic changes were noted by Löfgren (1953) in ten of 69 cases of sarcoidosis presenting with hilar adenopathy.

Radiographic Findings

Only one patient (Case 7) has maintained a normal chest x ray throughout the period of obser-

vation. Bilateral hilar lymph-gland enlargement is the typical initial finding in this type of case and was noted in five cases (Fig. 1a) with associated enlargement of the right paratracheal glands in three. One patient (Case 6) initially showed unilateral glandular enlargement, but this later became bilateral. This is a rare mode of presentation and this case has been reported in greater detail elsewhere (Williams, 1961). With the exception of this case, the hilar lymph-gland enlargement has always been maximal when the patients were first seen, slow resolution thereafter occurring.

In two patients (Cases 1 and 2), complete clearing occurred within one year without other changes developing (Fig. 1b), and in one patient (Case 5) followed for 4 months gradual resolution is occurring.

In three patients (Cases 3, 4, and 6), pulmonary infiltration developed between 4 and 6 months after the onset whilst the hilar lymph glands were resolving (Fig. 2a, b, opposite) and has persisted unchanged over a period of observation of 6 months.

X rays of involved joints in four cases showed no abnormalities.

Other Investigations

Erythrocyte Sedimentation Rate (E.S.R.).—This was always raised and, with one exception, the initial readings were greater than 40 mm./hr (Westergren) (Table III). In this one patient (Case 2), the initial reading was 24 mm./hr and this

had fallen to normal within 2 weeks. The elevation persisted for several months in the other patients and in one (Case 6) is still elevated at 40 mm./hr, 9 months after the onset.

TABLE III

INITIAL ERYTHROCYTE SEDIMENTATION RATE (mm./hr Westergren) AND DURATION OF ELEVATION

Case No.	Initial Reading	Duration of Elevation (mths)
1	40	4
2	24	0.5
3	108	4
4	100	5
5	48	3
6	70	9*
7	70	5

Intradermal Reaction.—The reaction to old tuberculin was tested in all patients. Four cases showed no reaction at 1:100 and one no reaction at 1:1,000, greater dilutions not being used. Two cases gave positive reactions at 1:1,000.

Rose-Waaler Test.—This was negative in all cases and the antistreptolysin titre was always normal. This latter test is useful in distinguishing cases of erythema nodosum due to sarcoidosis from cases due to streptococcal infection.

Estimation of serum proteins showed some elevation of the globulin fraction in all cases.

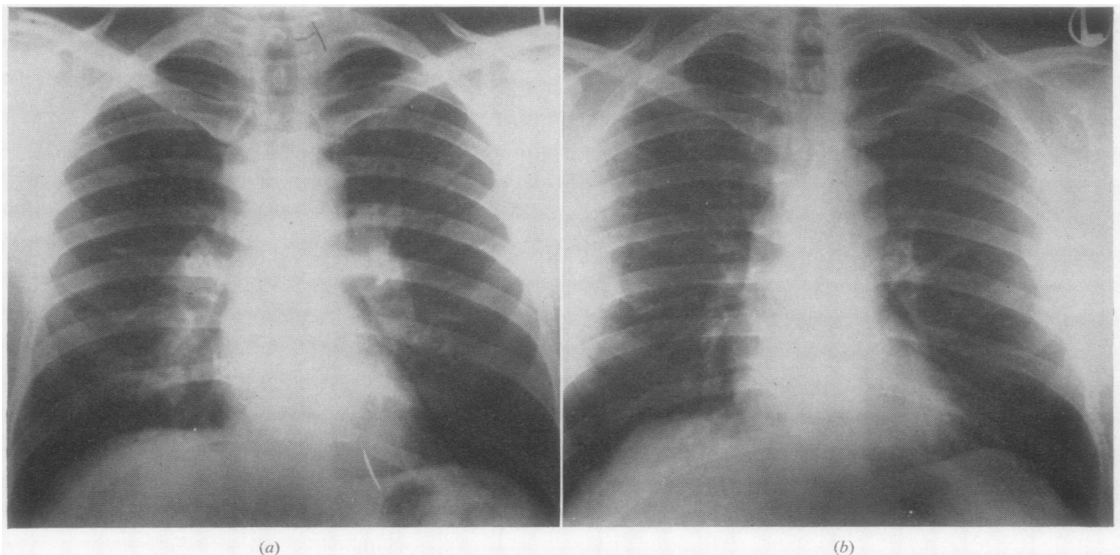


Fig. 1.—Case 1, chest x ray.
 (a) March, 1959, bilateral hilar lymph-gland enlargement, and enlargement of right paratracheal glands.
 (b) April, 1960, glandular enlargement resolved, and lung fields clear.

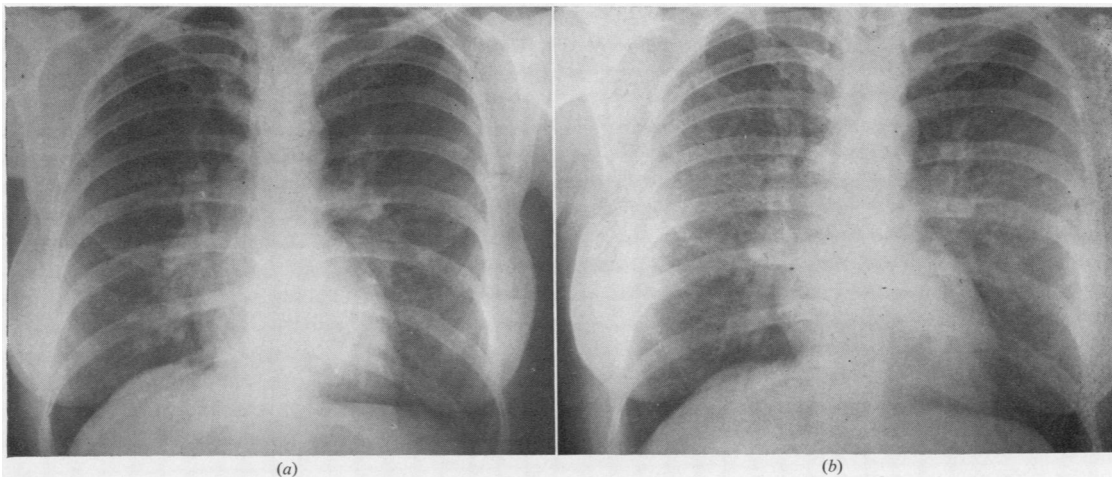


Fig. 2.—Case 3, chest x ray.

- (a) December, 1959, bilateral hilar lymph-gland enlargement, and lung fields clear.
 (b) September, 1960, slight resolution of hilar lymph-glands, and marked pulmonary infiltration.

Electrophoretic analysis showed this to be due to increase in the alpha-2 and gamma fractions, especially the latter.

Kveim Test.—Histological evidence of sarcoid tissue is necessary to establish a diagnosis of sarcoidosis. The Kveim test is eminently suitable in the present type of case where there were no super-

ficial lymph-glands or suitable skin lesions available for biopsy. This test was performed in all seven patients, a sarcoid antigen of known potency being used. Positive results were obtained in six patients, an indolent nodule developing at the site of the injection. This was biopsied 4 weeks after injection and histological evidence of sarcoid tissue was found in all six cases (Fig. 3).

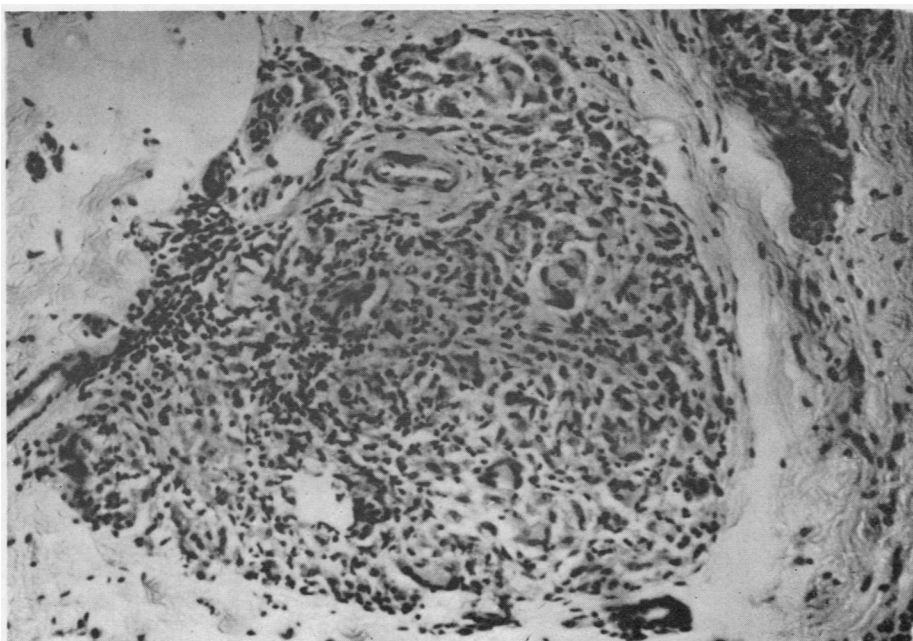


Fig. 3.—Case 3, biopsy of Kveim test, showing typical positive result. Infiltration of dermis with epithelioid cells, lymphocytes, and giant cells. No necrosis or caseation. Haematoxylin and eosin $\times 480$.

In the one case in this series giving a negative test, prednisone had been given during the "latent" period and this is known to influence the response (James and Thomson, 1959).

Treatment

Since the polyarthritis, skin lesions, and systemic upset ultimately settle spontaneously, specific treatment is rarely necessary for these features. Salicylates were given to four of the present patients without apparent effect. Prednisone was given to two patients (Cases 1 and 6) with persistent systemic upset and fever, with rapid response; both were given prednisone in an initial dose of 20 mg. daily, the dose being "tapered off" after 4 weeks. As expected, this had no beneficial effect on the course of the radiological changes and no apparent effect on the erythrocyte sedimentation rate. It is now suggested that these drugs are better avoided at this stage of the disease in view of the theoretical risk of their interfering with immune mechanisms (James, 1959).

Discussion

Polyarthritis was the feature common to all the cases in this series and the joint symptoms conformed to a fairly distinctive pattern. It was chiefly the large joints which were affected with a high incidence of involvement of the ankle joints. Pain and stiffness resulted, but joint swelling was not seen, although periarticular oedema of the ankles was common. These symptoms were usually accompanied by fever, general systemic upset, and striking elevation of the erythrocyte sedimentation rate. In a large proportion of cases, erythema nodosum and hilar adenopathy also occurred, the combination of polyarthritis, erythema nodosum, hilar adenopathy, and systemic upset constituting the fully-developed syndrome.

The course appears to be benign, the joint symptoms and systemic upset subsiding spontaneously after a few weeks and the E.S.R. after several months. The prognosis with regard to the pulmonary lesions in sarcoidosis presenting with these features also appears to be good (James and others, 1956; Scadding, 1956).

Hilar adenopathy is believed to represent the onset phase of pulmonary sarcoidosis (Löfgren, 1953), but the precise cause of the associated skin and joint lesions is uncertain. It is generally believed that erythema nodosum represents a non-specific allergic reaction (Scott, 1956), and the polyarthritis and systemic symptoms may have a similar causation. This would readily explain the occurrence of these features with erythema nodosum irrespective of its aetiology (Scott, 1956). In

sarcoidosis presenting with this syndrome, however, sarcoid tissue has been found on biopsy of striated muscle (Myers, Gottlieb, Mattman, Eckley, and Chason, 1952) and on biopsy of the nodal skin lesions (James and others, 1956). This suggests that actual tissue involvement may be responsible for many of the symptoms rather than a non-specific reaction. In only one reported case has synovial biopsy been performed in the acute phase in this syndrome, and this showed only a mild infiltration of mononuclear cells around blood vessels and in the synovial tissue (Ferguson and Paris, 1958).

When polyarthritis, erythema nodosum, hilar adenopathy, and systemic symptoms occur together, the diagnosis of sarcoidosis presents little difficulty, but in incomplete forms (such as Case 7 in this series) diagnosis is more difficult. In cases with associated erythema nodosum the absence of a history of preceding sore throat and a normal antistreptolysin titre are valuable in excluding preceding streptococcal infection, whilst drug sensitivity and primary tuberculous infection will also have to be considered. In doubtful cases the Kveim test appears to provide a fairly reliable diagnostic procedure, positive results being expected in about 80 per cent. of cases (Siltzbach and Ehrlich, 1954; James and others, 1956). Early diagnosis is important, so that, with knowledge of the good prognosis, unnecessary hospitalization and treatment may be avoided.

In view of the good prognosis it is probably advisable to avoid the use of cortisone or its analogues in the early phases of this condition (James, 1959), and to restrict their use to cases in which persistent pulmonary infiltration develops (James, 1956).

Summary

Seven patients with sarcoidosis are reported, all of whom presented with polyarthritis. The clinical features are reviewed with particular emphasis on the pattern of joint involvement and its duration. Fever and systemic symptoms persisting for several weeks accompanied the polyarthritis and the erythrocyte sedimentation rate was usually elevated for several months. Erythema nodosum was present in five patients and pulmonary changes in six. Attention is drawn to the value of the Kveim test in diagnosis. In all cases, symptoms subsided spontaneously in several weeks and specific treatment appeared to be unnecessary. The possible cause of the various symptoms is discussed.

I should like to thank Dr. Ian Gordon for advice during the preparation of the paper and for permission

to report these cases, all of whom were admitted under his care. I should also like to thank Dr. A. W. Branwood for the histological interpretation of the Kveim tests and Mr. A. Topp for the photographs.

REFERENCES

- Ferguson, R. H., and Paris, J. (1958). *Arch. intern. Med.*, **101**, 1065.
 James, D. G. (1956). *Brit. med. J.*, **2**, 900.
 — (1958). *Postgrad. med. J.*, **34**, 240.
 — (1959). *Quart. J. Med.*, **52** (n.s. **28**), 109.
 — and Thomson, A. D. (1959). *Lancet*, **1**, 1057.
 —, —, and Willcox, A. (1956). *Ibid.*, **2**, 218.
 Löfgren, S. (1953). *Acta med. scand.*, **145**, 424.
 Myers, G. B., Gottlieb, A. M., Mattman, P. E., Eckley, G. M., and Chason, J. L. (1952). *Amer. J. Med.*, **12**, 161.
 Scadding, J. G. (1956). *Proc. roy. Soc. Med.*, **49**, 799.
 Scott, T. F. McNair (1956). *Pediat. Clin. N. Amer.*, Aug., 1956, p. 771.
 Siltzbach, L. E., and Ehrlich, J. C. (1954). *Amer. J. Med.*, **16**, 790.
 Williams, M. J. (1961). *Scot. med. J.*, **6**, 18.

Sarcoïdose débutant par une polyarthrite

RÉSUMÉ

On rapporte sept cas de sarcoïdose débutant tous par une polyarthrite. On passe en revue les traits patho-

logiques, avec mention spéciale de l'implication articulaire et de sa durée. Une fièvre et des symptômes généraux accompagnaient la polyarthrite pendant plusieurs semaines et la vélocité de sédimentation érythrocytaire était habituellement élevée pendant plusieurs mois. L'érythème noueux était présent chez cinq malades et des lésions pulmonaires chez six d'entre eux. On attire l'attention à la valeur diagnostique de la réaction de Kveim. Dans tous les cas, les symptômes se sont abattus spontanément en quelques semaines et aucun traitement spécifique n'avait semblé nécessaire. On discute la cause possible de différents symptômes.

Sarcoïdose presentándose con poliartrosis

SUMARIO

Se presentan siete enfermos con sarcoïdosis, todos ellos manifestando poliartrosis. Se revisan los rasgos patológicos, con especial mención del tipo de afectación articular y su duración. La poliartrosis iba acompañada de fiebre y sintomatología general que persistió durante varias semanas y la velocidad de sedimentación eritrocitaria alta se mantuvo por varios meses. Cinco enfermos presentaron eritema nudoso y en seis se vieron alteraciones pulmonales. Se llama atención hacia el valor diagnóstico de la reacción de Kveim. En todos los casos los síntomas regresaron espontáneamente en varias semanas y el tratamiento específico fué innecesario. Se discute la posible causa de varios síntomas.