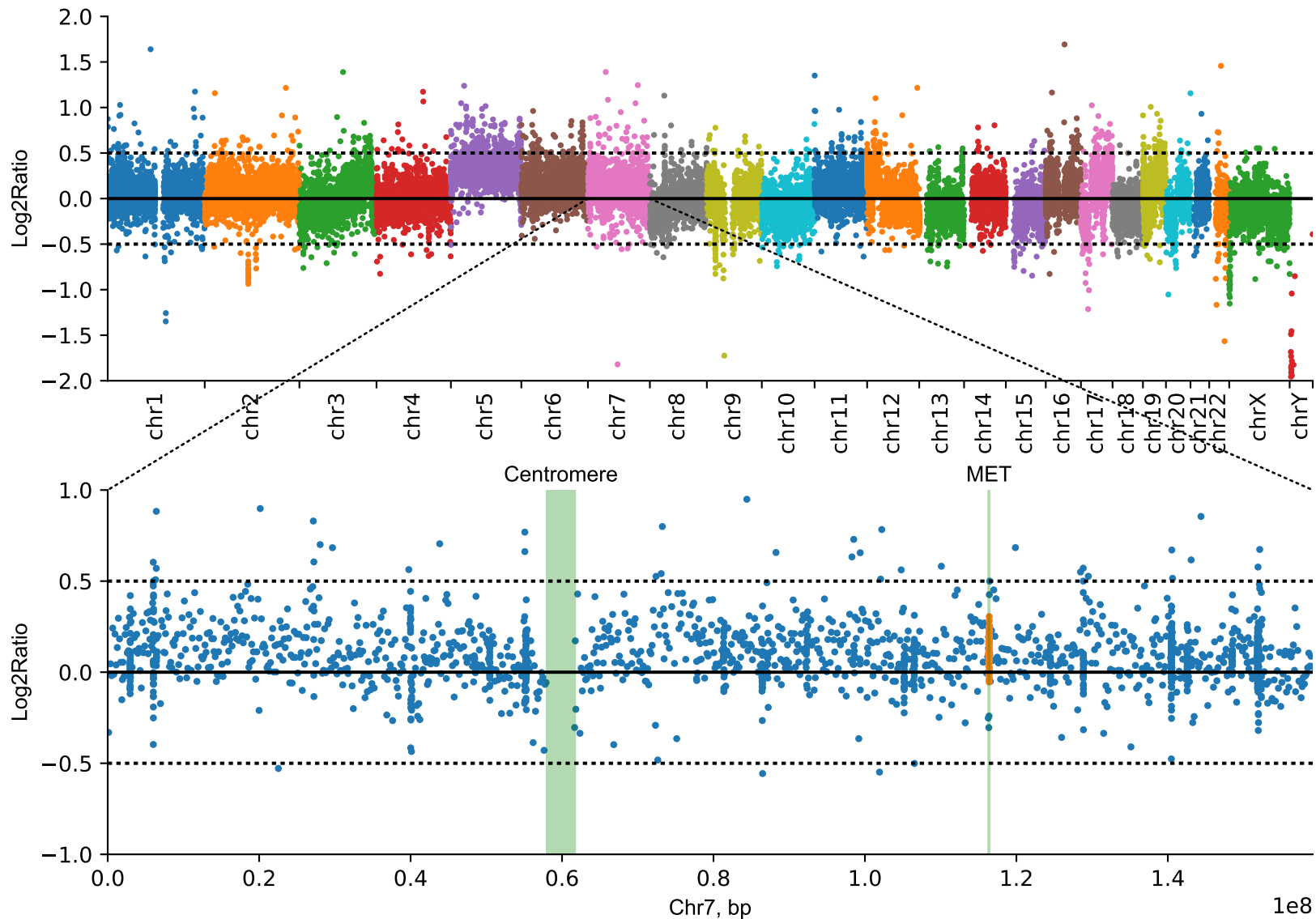


Figure S3



One MET-FISH-positive tumor was identified as negative by NGS