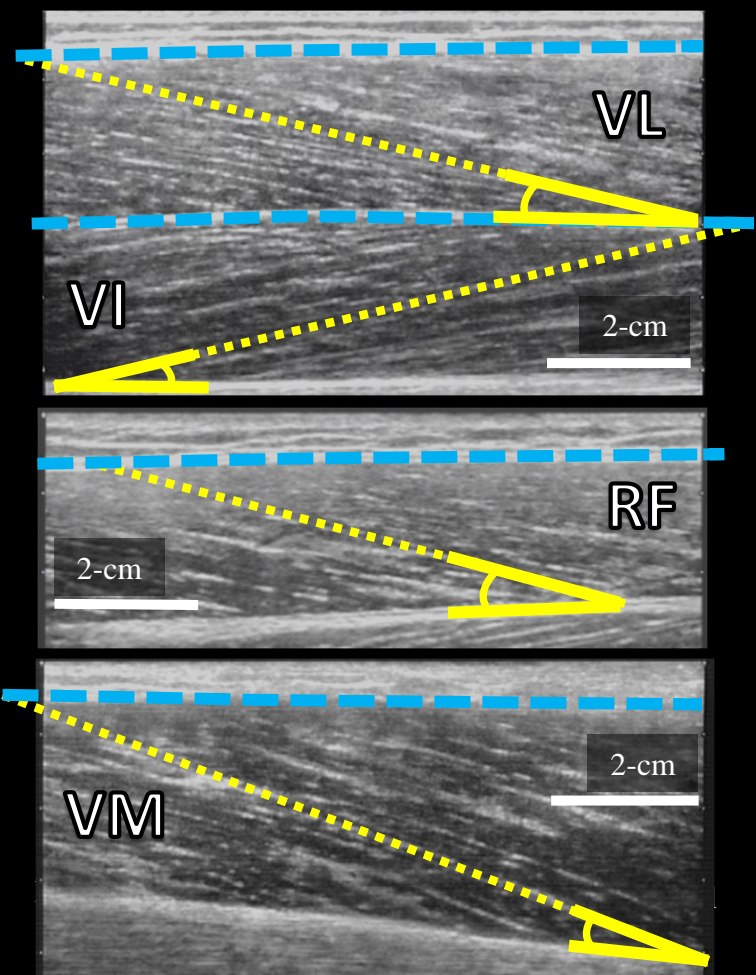
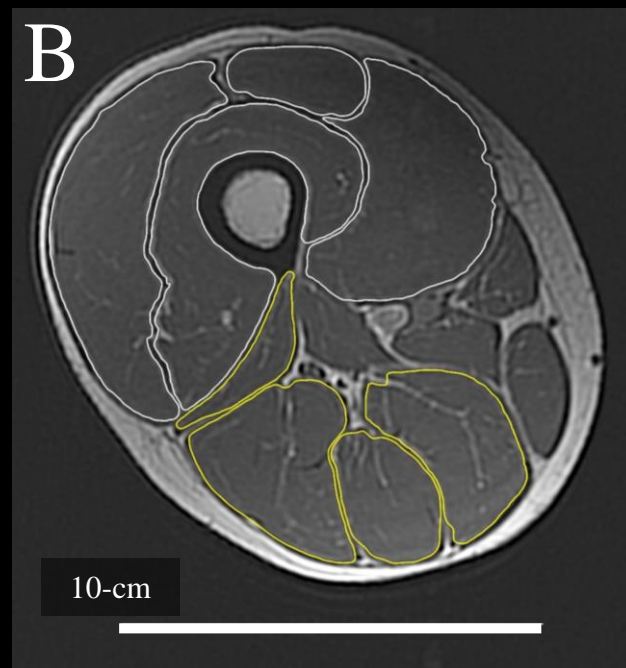
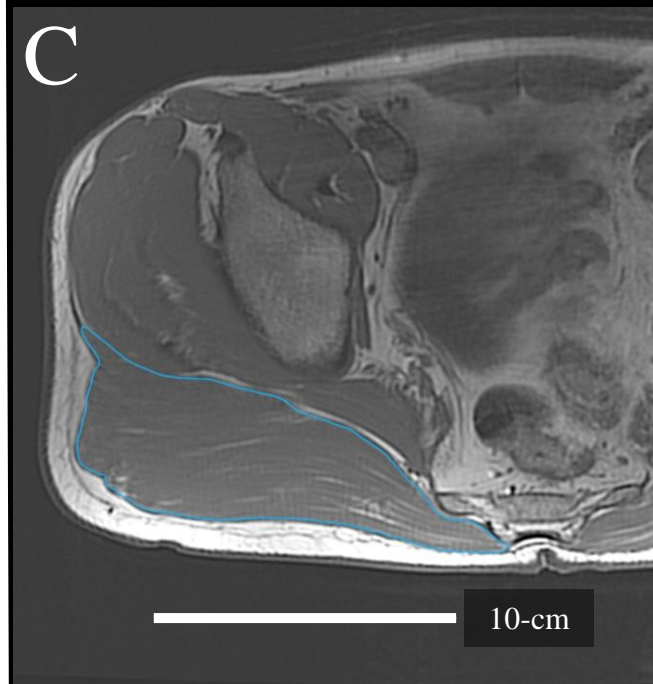


AProximal Distal

Key: — — — Superficial aponeurosis
· · · Fascicle length
A Pennation angle

B**C**

Supplementary material 4. Representative: (A) ultrasound images of vastus lateralis (VL; 50% of femur length), vastus intermedius (VI; 50% of femur length), rectus femoris (RF; 55% of femur length), and vastus medialis (VM; 40% of femur length; 0% is knee joint space); (B) axial magnetic resonance image of the thigh with constituent muscles of the quadriceps (white borders) and hamstrings (yellow borders) segmented; and (C) axial magnetic resonance image of the hip with the gluteus maximus (light blue border) segmented.