

# RADIOLOGICAL CHANGES IN THE CERVICAL SPINE IN ANKYLOSING SPONDYLITIS

BY

K. A. E. MEIJERS\*, S. F. C. HEERMA VAN VOSS†, AND R. J. FRANÇOIS‡

*From the Departments of Rheumatology\* and Radiology†, University Hospital, Leyden, Holland*

Ankylosing spondylitis is not limited to the sacroiliac joints and the lumbar and dorsal spine, but may also affect the cervical spine. Forestier, Jacqueline, and Rotes-Quérol (1951) considered that the intervertebral joints were first affected, osteoporosis being followed by narrowing and ankylosis, and later by the formation of syndesmophytes on the vertebral bodies.

Romanus and Ydén (1955) said that the first lesions were small erosions at the anterior corners of the vertebral bodies.

Martel, Holt, and Robinson (1962) observed a resorption of bone on the anterior surface of the cervical spine in late cases. Atlanto-axial subluxations, which may occur in rheumatoid arthritis, may also occur in ankylosing spondylitis (Sharp, 1958; Sharp and Purser, 1961; Wilkinson and Bywaters, 1958; Martel and Page, 1960; Martel, 1961).

## Present Investigations

We have examined a series of lateral films of the cervical spine in patients with ankylosing spondylitis (AS), rheumatoid arthritis (RA), and generalized osteo-arthritis (GOA) to see whether any particular lesions are specific for ankylosing spondylitis in this region.

**Ankylosing Spondylitis.**—73 out-patients seen in the Department of Rheumatology at the Leyden University Hospital from March, 1963, to March, 1964, were studied. Films were taken of the pelvis and of the lumbar and cervical spine.

The criteria used for the diagnosis were those formulated at the symposium on population studies in Rome (Kellgren, 1963). All showed bilateral sacro-iliitis. Patients with psoriasis (Sharp, 1957) or Still's disease (Carter, 1962, 1963) were excluded. There were 58 males and fifteen females. The average age of the males was 44

years, and of the females 50 years (mean 44·8; range 20 to 80). The duration of disease was 15·9 years for males and 16·2 years for females (Table I).

TABLE I  
DURATION OF DISEASE IN 73 CASES OF ANKYLOSING SPONDYLITIS, BY SEX

Sex . . . . .		Male	Female
Duration of Disease (yrs)	Range Average	1-38 15·9	6-32 16·2

**Rheumatoid Arthritis.**—49 patients with definite or classical RA were seen at the Rheumatological Unit at Noordwijk. There were eleven males and 38 females: average age 55·2 years, and average duration of disease 10·8 years.

**Generalized Osteo-Arthrosis.**—48 out-patients were suffering from sero-negative osteo-arthritis in various joints. There were twenty males and 28 females: average age 59·2 years.

Table II shows the expected variation in sex distribution between the three groups.

TABLE II  
DIAGNOSIS AND AVERAGE AGE OF PATIENTS STUDIED

Type of Disease	Total Patients	Male	Female	Average Age (yrs)
Ankylosing Spondylitis	73	58	15	44·8
Rheumatoid Arthritis	49	11	38	55·2
Generalized Osteo-arthritis	48	20	28	59·2

## Findings

### (I) Radiological Changes in Ankylosing Spondylitis

Lateral views taken with the cervical spine flexed forwards and backwards enabled abnormalities to be detected in three places:

- (1) The C1-C2 area.
- (2) The vertebral bodies and intervertebral disks.
- (3) The intervertebral (apophyseal) joints. As the evaluation of these joints can be very difficult in

†Temporary member of the Department of Rheumatology. Present address: 9 Avenue de Sumatra, Bruxelles 18, Belgium.

dubious cases, only marked changes were recorded (Sharp, 1963).

These abnormalities occurred singly or in combination. The changes below the C1-C2 level in our 73 cases could be divided into four groups:

(i): None or minimal	.. ..	6 cases	} Total 73
(ii): Vertebral bodies and disks only	.. ..	42 cases	
(iii): Intervertebral joints only	.. ..	1 case	
(iv): (ii) and (iii) combined	.. ..	24 cases	

The changes grouped under (ii) are syndesmophytes, anterior spondylitis, and bone resorption. Syndesmophytes have been described by Forestier and others (1951) as new bone formations connecting two adjacent vertebrae, arising from the upper and lower thirds of the vertebral bodies. These ossifications are located in the outer layers of the disks or the perivertebral connective tissue, never in the anterior longitudinal ligament.

Various types of ossification observed in our series are shown in Fig. 1:

(a) Very thin bridges running from one corner of a vertebral body to the adjacent corner of the next. These changes were examined microscopically by van Swaay (1949). The bridges are located in the outer layers of the disks, as a result of an enchondral ossification. We have designated this type the "bridge of van Swaay".

(b) Very thick bridges starting at the upper third of one vertebra and inserting onto the lower third of the next vertebra. Radiologically these syndesmophytes contain cancellous bone, which appears to be continuous with the cancellous bone of the adjacent vertebra. This we designated "F3". Forestier and Rotes-Quérol (1950) found these syndesmophytes in particular on the lateral surface of the lumbar spine; the bridges of van Swaay were found more often on the anterior surface.

Besides these two types of syndesmophyte, small new bone formations on the upper and lower thirds

of the vertebrae could be detected regularly. Two types could be differentiated:

(c) A very thin bone formation starting at one third of a vertebral body and running for some distance parallel to it. This we designated "F1".

(d) A somewhat thicker bone formation completely fused with the vertebra. This we designated "F2".

Forestier emphasized that syndesmophytes always grow vertically and considered F1 and F2 to be the first stages of F3. Osteophytes, on the other hand, take a horizontal course.

Examples of these various formations are shown in Figs 2 to 5. Fig. 2 shows extensive bridging on

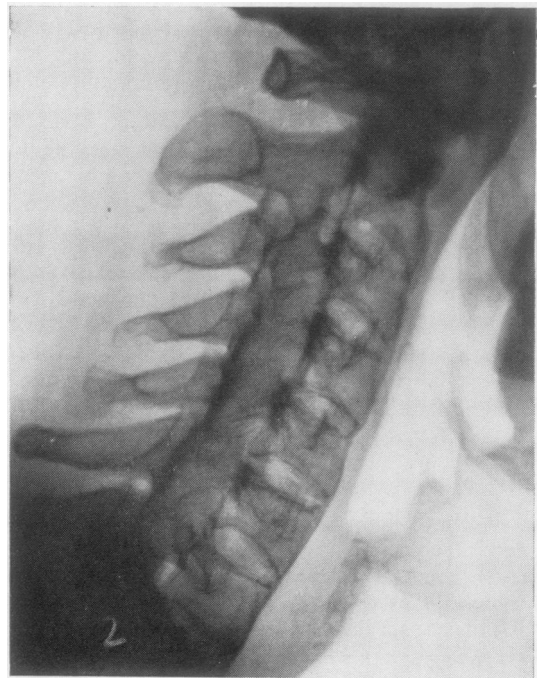

Fig. 2.—Complete fusion of intervertebral joints and extensive bridging on anterior surface in an advanced case of ankylosing spondylitis.




Fig. 1.—Diagrams of syndesmophytes (vertical) and osteophyte (horizontal).

the anterior surface of the cervical spine. In the lower part of the picture thin bridges of van Swaay are visible, and in the upper part the thicker bridges, type F3. At the same time the intervertebral joints are fused. This example is taken from a very advanced case. The normal disk height is noteworthy as disk narrowing occurs in some cases (Fig. 3).

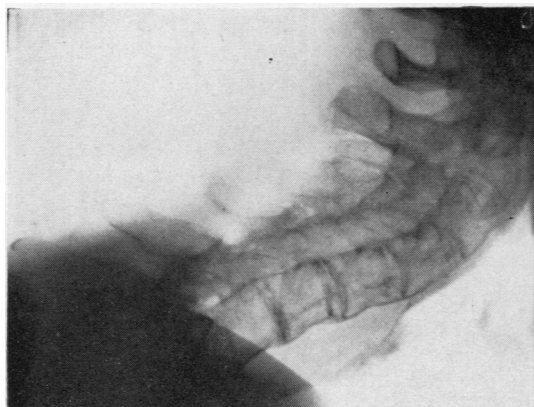

Fig. 3.—Narrowing of disk spaces in advanced ankylosing spondylitis.

A variety of syndesmophytes can sometimes be detected in one spine, as for example, in Fig. 4, where a bony bridge type F3 is seen between C4 and C5, and syndesmophytes type F2 can be seen at C3, C5, and C6. Small bone formations are visible on

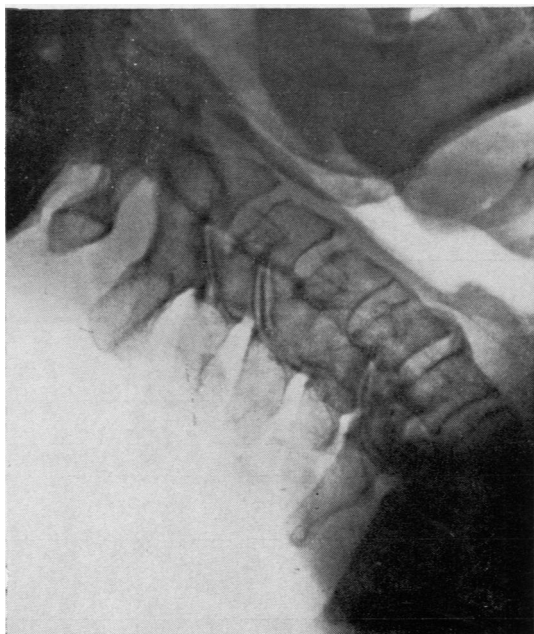


Fig. 4.—Example of various kinds of new bone formation in the cervical spine with atlanto-axial subluxation.

the lower part of C2 and the upper part of C3. There is ankylosis of the intervertebral joints C4-C5 and atlanto-axial subluxation.

Romanus and Ydén (1955) described the occurrence of anterior spondylitis, but we did not detect this lesion in the erosive phase. We did, however, observe extensive new bone formation with a fluffy anterior border (Fig. 5), which may be due to anterior spondylitis with secondary new bone formation.

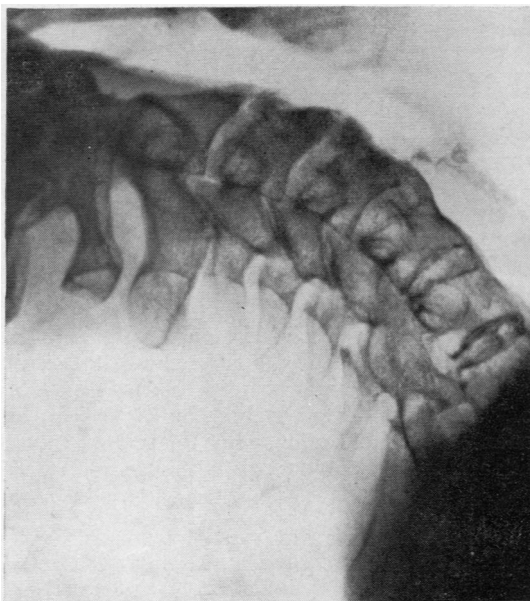


Fig. 5.—Extensive new bone formation with fluffy anterior surface.

Bone resorption on the anterior surface of the vertebrae, as described by Martel and others (1962), was observed in three cases only.

## (II) Analysis of Lesions and Comparison with Cases of RA and GOA

To determine whether these lesions were typical for AS, films from patients suffering from RA (49) and GOA (48) were added, making a total of 170 sets of films.

These were first read by the two rheumatologists (R.F. and K.M.) and one radiologist (H.v.V.) all working together looking for the following signs:

- Osteophytes
- Narrowed disks
- Anterior spondylitis
- Syndesmophytes (F1, F2, F3, Bridges of van Swaay)
- Intervertebral joint changes
- Atlanto-axial subluxations

The three observers were in firm agreement on the identification of these signs.

Thereafter all the films were read by two observers (K.M. and H.v.V.) separately, with names and other identifying features obscured. A sign was marked as present if observed at least on one level in the cervical spine. There was now interobserver disagreement on several signs (Table III).

TABLE III  
SCORING OF SIGNS BY TWO OBSERVERS  
(K.M. AND H.v.V.) WHEN ALL FILMS WERE READ  
BLINDLY AND SEPARATELY

Observers		K.M. (I.)	H.v.V. (II.)
Osteophytes		78	62
Narrowed disk spaces		86	81
Anterior spondylitis		8	8
Syndesmophytes	F1	2	22
	F2	12	38
	F3	7	11
	van Swaay	30	25
Intervertebral joint changes		21	26
Atlanto-axial subluxation		19	19

Statistical analysis showed that this interobserver error, as expressed by the correlation coefficient  $r$ , was small for osteophytes, disk narrowing, bridges of van Swaay, intervertebral joint changes, and atlanto-axial subluxation, while for anterior spondylitis and syndesmophytes type F3  $r$  = approximately

0.5. The discrepancies for syndesmophytes F1 and F2 were very marked (Table IV).

The incidence of the various signs in the three groups of films (AS, RA, and GOA) as read by each observer, is shown in Table V.

In spite of these interobserver differences in detailed interpretation, the overall impression on which a diagnosis is based was in close agreement. A similar result was reported by Bland, Van Burskirk, Tampas, Brown, and Clayton (1965) in a study of the radiological criteria for RA.

### Specificity of Radiological Changes

(1) For the osteophytes and narrowed disks a small interobserver error was noted. These signs could be found in all three groups, as was to be expected, and their specificity for AS appears to be small.

(2) The bridges of van Swaay and marked changes in the intervertebral joints, where the interobserver error was small, were nearly all detected in the AS group only, so that these signs may be considered as highly specific for AS. The bridges of van Swaay were found in only a third of our cases, and the intervertebral joint changes were even less frequent, so that the sensitivity of these signs is about 30 per cent.

TABLE IV  
DISTRIBUTION OF SCORING BY TWO OBSERVERS AND STATISTICAL ANALYSIS

Observer	Scoring	I		II		Percentage	$r$
		+	+	+	-		
Osteophytes		52	26	10	82	21.2	0.58
Narrowed disks		66	20	15	69	20.6	0.59
Anterior spondylitis		4	4	4	158	4.7	0.48
Syndesmophytes	F1	1	1	21	147	12.9	0.12
	F2	7	5	31	127	21.2	0.24
	F3	4	3	7	156	5.9	0.43
	van Swaay	22	8	3	137	6.5	0.69
Intervertebral joint changes		19	2	7	142	5.3	0.78
Atlanto-axial subluxation		13	6	6	145	7.1	0.64

TABLE V  
INCIDENCE OF SIGNS IN EACH GROUP SEPARATELY, AS READ BY TWO OBSERVERS, K.M. (I) AND H.v.V. (II)

Diagnosis	Observer	Anterior Spondylitis		Rheumatoid Arthritis		Generalized Osteo-arthritis	
		I	II	I	II	I	II
Osteophytes		20	18	27	19	31	25
Narrowed disks		26	25	28	27	32	29
Anterior spondylitis		8	6	-	1	-	1
Syndesmophytes	F1	1	11	1	4	-	7
	F2	11	21	1	9	-	8
	F3	7	10	-	1	-	-
	van Swaay	29	24	-	1	1	-
Intervertebral joint changes		21	25	-	-	-	1
Atlanto-axial subluxation		5	4	14	15	-	-

(3) For anterior spondylitis and syndesmophytes type F3 the interobserver error was moderate. These signs were nearly all detected in the AS group, and may therefore be regarded as highly specific for AS, but they were seen in only about 10 per cent. of our cases, and are therefore less sensitive indicators.

(4) For syndesmophytes F1 and F2 the interobserver error was large, observer (H.v.V.) marking them in all three groups, so that their specificity appears to be low. This observer detected these syndesmophytes more frequently in all three groups; he not only detected small new bone formations earlier but was also inclined to interpret them sooner as syndesmophytes than the other observer (K.M.). This may be because H.v.V. is a radiologist while K.M. is a rheumatologist, but similar wide differences of interpretation were also reported by Bland and others (1965) between fellow radiologists.

#### Summary

In 73 patients suffering from ankylosing spondylitis of varying duration (average 16 years), films of

the cervical spine were studied for osteophytes, narrowed disk spaces, anterior spondylitis, syndesmophytes (F1, F2, F3, bridges of van Swaay), intervertebral (apophyseal) joint changes, and atlanto-axial subluxation.

Narrowing and ankylosis of the intervertebral joints alone were encountered only rarely in our series. It therefore seems unlikely that these changes are the first signs of ankylosing spondylitis in the cervical region.

Bridges of van Swaay and marked intervertebral joint changes are specific for ankylosing spondylitis, being seen in 30 per cent. of cases.

Syndesmophytes type F3 and anterior spondylitis in the reparative phase are thought to be specific for ankylosing spondylitis in about 10 per cent. of cases.

Syndesmophytes type F1 and F2, atlanto-axial subluxation, osteophytes, and narrowing of the disk spaces do not appear to be specific for ankylosing spondylitis.

The authors are indebted to Prof. Dr. J. Goslings for his helpful criticism, to Drs. H. M. Hazevoet, M. Haverkorn van Rijsewijk, and H. A. Valkenburg for statistical help, to Mrs. F. S. J. Heerma van Voss-Dantuma for technical assistance, and to Mr. Ruychrock for preparing the photographs.

#### REFERENCES

- Bland, J. H., Van Buskirk, F. W., Tampas, J. P., Brown, E., and Clayton, R. (1965). *Amer. J. Roentgenol.*, **95**, 949 (A study of roentgenologic criteria for rheumatoid arthritis of the cervical spine).
- Carter, M. E. (1962). *Ann. rheum. Dis.*, **21**, 105 (Sacro-iliitis in Still's disease).
- (1963). "International Study Centre for Rheumatic Diseases, Amsterdam, Symposium", p. 279 (Sacro-iliac joints in juvenile rheumatoid arthritis).
- Forestier, J., Jacqueline, F., and Rotes-Quérol, J. (1951). "La spondylarthrite ankylosante". Masson, Paris.
- and Rotes-Quérol, J. (1950). *Ann. rheum. Dis.*, **9**, 321.
- Fraenkel, E. (1903). *Fortschr. Röntgenstr.*, **7**, 62 (Über chronische ankylosierende Wirbelsäulenversteifung).
- Kellgren, H. J. (1963). "Proceedings of the Rome Symposium on Population Studies." Blackwell, Oxford.
- Martel, W. (1961). *Amer. J. Roentgenol.*, **86**, 223 (The occipito-atlanto-axial joints in rheumatoid arthritis and ankylosing spondylitis).
- , Holt, J. F., and Robinson, W. D. (1962). *Ann. rheum. Dis.*, **21**, 199 (A late effect on the cervical spine in ankylosing spondylitis).
- and Page, J. W. (1960). *Arthr. and Rheum.*, **3**, 546 (Cervical vertebral erosions and subluxations in rheumatoid arthritis and ankylosing spondylitis).
- Oppenheimer, A. (1943). *Amer. J. Roentgenol.*, **49**, 49 (Development, clinical manifestations, and treatment of rheumatoid arthritis of the apophyseal intervertebral joints).
- Romanus, R., and Ydén, S. (1955). "Pelvo-spondylitis Ossificans." Munksgaard, Copenhagen.
- Sharp, J. (1957). *Bull. rheum. Dis.*, **7**, 125 (The differential diagnosis of ankylosing spondylitis

- (1963). "International Study Centre for Rheumatic Diseases, Amsterdam, Symposium," p. 219 (Cervical spine).
- and Purser, D. W. (1961). *Ann. rheum. Dis.*, **20**, 47 (Spontaneous atlanto-axial dislocation in ankylosing spondylitis and rheumatoid arthritis).
- , —, and Lawrence, J. S. (1958). *Ibid.*, **17**, 303 (Rheumatoid arthritis of the cervical spine in the adult).
- Sivén, V. O. (1903). *Z. klin. Med.*, **49**, 343 (Zur Kenntniss der sogenannten chronischen ankylosierenden Entzündung der Wirbelsäule).
- Swaay, H. van (1949). "Spondylitis Ankylopoetica." Thesis, Leyden.
- Wilkinson, M., and Bywaters, E. G. L. (1958). *Ann. rheum. Dis.*, **17**, 209 (Clinical features and course of ankylosing spondylitis).

#### Les altérations radiologiques du rachis cervical au cours de la spondylarthrite ankylosante

##### RÉSUMÉ

Chez 73 malades présentant une spondylarthrite ankylosante pendant 16 ans en moyenne on a étudié sur des clichés du rachis cervical les ostéophytes, le pincement discal, l'atteinte vertébrale antérieure, les syndesmophytes (F1, F2, F3), les ponts (de van Swaay), les altérations interapophysaires et la subluxation atloaxoïdienne.

Le pincement et l'ankylose des articulations vertébrales isolés furent rarement trouvés dans notre série. Il paraît peu vraisemblable que ces altérations soient les premiers signes de la spondylarthrite ankylosante au niveau du rachis cervical.

Les ponts de van Swaay et des altérations accentuées des articulations intervertébrales sont spécifiques de la spondylarthrite ankylosante, car ils ont été trouvés dans 30 pour cent des cas.

On considère que les syndesmophytes de type F3 et l'atteinte vertébrale antérieure au stade de reconstruction sont spécifiques de la spondylarthrite ankylosante dans environ 10 pour cent des cas.

Les syndesmophytes de type F1 et F2, la subluxation atloaxoïdienne, les ostéophytes et le pincement discal ne semblent pas être spécifiques de la spondylarthrite ankylosante.

#### Alteraciones radiológicas de la espina cervical en la espondilartrosis anquilosante

##### SUMARIO

En 73 enfermos con espondilartrosis anquilosante de duración variable (un promedio de 16 años) se estudiaron radiografías de la espina cervical en busca de osteofitos, del estrechamiento discal, de la espondilartrosis anterior, de sindesmofitos (F1, F2, F3), de puentes (de van Swaay), de alteraciones interapofisarias y de la subluxación atlanto-axil.

El estrechamiento y la anquilosis de las articulaciones intervertebrales solamente se vieron en nuestra serie con poquísima frecuencia. Es pues poco probable que estas alteraciones formen el primer signo de la espondilartrosis anquilosante al nivel de la espina cervical.

Los puentes de van Swaay y las alteraciones accentuadas de las articulaciones intervertebrales constituyen lesiones específicas de la espondilartrosis anquilosante, ya que las encontramos en un 30 por ciento de los casos.

Se considera que los sindesmofitos de tipo F3 y la espondilartrosis anterior en su fase de reconstrucción son específicos en la espondilartrosis anquilosante en cerca de un 10 por ciento de los casos.

Los sindesmofitos de tipo F1 y F2, la subluxación atlanto-axil, los osteofitos y el estrechamiento discal no parecen representar lesiones específicas de la espondilartrosis anquilosante.