

BONE AND JOINT CHANGES IN HAEMOCHROMATOSIS

BY

E. N. WARDLE* AND J. T. PATTON

University Department of Clinical Haematology and the Radiology Department, Manchester Royal Infirmary

There has been little mention in the British literature of the bone and joint changes that may be associated with haemochromatosis. These changes consist of osteoporosis, opacification of menisci identical with chondrocalcinosis, and an arthropathy (Delbarre, 1960, 1964) which can affect the larger joints but which afflicts, in particular, the proximal interphalangeal and metacarpophalangeal joints of the hands. Although clinical cases of polyarthritis thought to be due to haemochromatosis are on record (Schumacher, 1964), the patients often have only joint symptoms, and these are attributed to osteoarthritis until a radiograph demonstrates the features which we wish to emphasize. In a similar fashion the osteoporosis is said to be latent. Chondrocalcinosis has acquired a specific connotation—

namely as a feature of “pseudogout” (McCarty, Kohn, and Faires, 1962)—but in reality may be due to many causes (Moskowitz and Katz, 1967).

This study reports the bone and joint findings in fourteen cases of haemochromatosis. All were studied by x rays of the hands, knees, hips, pelvis and lumbar spine, and had concurrently various pertinent chemical investigations, the results of which are recorded in the Table for twelve cases. The essential clinical features can be illustrated by reference to the case histories of four of the fourteen patients.

(1) Clinical Features

Case 5, a man aged 59 years, has “joint changes in the hands and chondrocalcinosis”. Since 1940 he has had periodic attacks of pain in the right hypochondrium. In 1950 a diagnosis of haemochromatosis was established

*Now at Royal Victoria Infirmary, Newcastle upon Tyne, 1.

TABLE
BIOCHEMICAL DETAILS IN TWELVE PATIENTS

Case No.	Diabetes	Serum Iron (µg./100 ml.)	Body Iron (µg./kg.)	Per cent. BSP Retention at 60 min.	Serum Uric Acid (mg./100 ml.)	24-hr Urinary Uric Acid (mg.)	Serum Calcium (mg./100 ml.)	Serum Phosphorus (mg./100 ml.)	Alkaline Phosphatase (K.A. units)	24-hr Urinary Calcium (mg.)	24-hr 17-oxo-Steroids (mg.)	24-hr 17-oxo-steroids (mg.)
1	+	220	1,800	1.25	3.7	610	9.8	3.9	10.5	118	2.6	6.6
2	+	220	930	6.9	2.9	390	9.5	3.1	23.0	150	2.8	6.3
3	+	290	1,920	4.0	3.5	560	10.8	3.2	15.0	65	3.3	6.2
4	0	60	0	0	5.5	620	10.2	2.8	9.0	252	7.0	9.9
5	+	230	715	8.2	2.8	760	9.9	3.1	13.0	384	3.0	8.8
6	0	180	1,520	7.0	6.6	500	9.2	3.0	12.0	41	2.5	7.1
7	+	60	100	1.0	4.5	610	10.6	4.3	17.0	113	8.3	13.2
8	+	40	54	1.0	4.5	450	9.2	2.3	42.0	428	2.6	5.9
9	0	220	—	6.4	4.1	480	10.0	3.3	25.0	51	1.9	4.6
10	0	170	376	—	4.7	400	10.0	2.3	7.5	269	8.4	11.0
11	+	220	950	—	2.9	—	10.7	4.8	13.0	—	1.6	15.2
12	+	205	—	0	—	—	—	—	—	—	—	—

by liver biopsy. His mother died of diabetes at the age of 41 and his brother has haemochromatosis. In 1954 he himself developed diabetes and he has since been maintained on P.Z.I. with soluble insulin. He has a striking grey-brown pigmentation and the liver is four fingers enlarged and is firm. His only complaint is of pain in the right hypochondrium: he has no joint symptoms. At the time of assessment the serum iron was 230 $\mu\text{g.}$ per cent. and the chelatable body iron 715 $\mu\text{g./kg.}$ body weight.

Case 7, a man aged 66 years, has "joint changes in the hands". In 1957, when he developed diabetes, he was noted to have brown pigmentation and hepatomegaly. He responded well to venesection and at the time of assessment the serum iron was 60 $\mu\text{g.}$ per cent. and the chelatable body iron 100 $\mu\text{g./kg.}$ The diabetes is controlled on IZS lente 60 units daily. He has no joint symptoms.

Case 8, a man aged 58 years, has "opacification of menisci of the knees and arthropathy of the hips and hands". In 1947 he first noticed episodic pains over the right greater trochanter and had difficulty in walking. The pain usually lasted a few days and he was then all right for periods of 2 to 3 weeks, but gradually the pain became more persistent and he developed stiffness in the right hip. In the meantime in 1957 the left eye was enucleated because of persistent inflammation and a retinal vein thrombosis. At that time he was found to have diabetes which could be controlled by diet alone. The haemochromatosis was confirmed by liver biopsy but it is remarkable that he has never had any skin pigmentation. His alcohol consumption is high.

In 1963 the increasing pain in the right hip led to a diagnosis of osteoarthritis and he had an osteotomy of the right femur. Since that time the serum iron has been maintained at a low level by venesection, being at the time of assessment 40 $\mu\text{g./100 ml.}$ with a chelatable body iron of 54 $\mu\text{g./kg.}$ Although the right hip has improved he has since developed pains in the ankles, knees, and hands, which like the original hip pain were at first episodic and have more recently become continuous; he now has morning stiffness lasting one hour. There is no family history of arthritis or of psoriasis. In 1966, he developed florid symptoms of diabetes and has been stabilized on Rapitard insulin.

Examination.—There is pain and limitation of movement of the elbows and wrists; in both hands the metacarpophalangeal joints, especially the second and third, show pronounced bony enlargement, and movement in these joints is limited and painful: similar less marked changes are present in the carpo-metacarpal and interphalangeal joints.

In the lower limbs, both knees are swollen and painful with crepitus and limitation of movement. Pain, stiffness, and a reduced range of movement are also present in the hips, ankles, sub-talar, mid-tarsal, and metatarsophalangeal joints.

The spine shows loss of normal curvature and painful restriction of movement in all places. Straight leg raising is restricted to 60° on either side. Chest expansion is 2½ in.

ESR 10 mm. hour (Westergren); Hb 102 per cent.; white blood count 5,600 /c.mm. Sheep cell agglutination test for rheumatoid arthritis (< ¼) and latex-fixation test (< 1/20) both negative.

The patient presents the picture of an unusual form of secondary osteoarthritis and although the x rays show calcinosis in the knees he has not had any attacks of pseudo-gout.

Case 11, a man aged 50 years, is a case of osteoporosis. In 1956, during an attack of pneumonia, he was noted to have an enlarged, firm liver and a bronze colour. His alcohol consumption had been high during the second world war. In 1963 he developed diabetes. He was adverse to venesection and at the time of investigation had a serum iron of 220 $\mu\text{g./100 ml.}$, and a chelatable body iron of 950 $\mu\text{g./kg.}$ At that time he complained of pains in the pelvis and knees. X rays showed the joints to be normal but the bones were porotic. A few weeks later he collapsed and died during an abdominal crisis.

The clinical features of the patients are those of a relatively silent multiple osteoarthrosis with an unusual pattern of distribution, which is not accounted for by their occupations or by trauma, in which there is bony enlargement and limitation of motion in many joints. None shows any signs of synovial thickening or effusions and none has tendon lesions. The ESR, SCAT, and latex-fixation tests are all negative.

(2) Biochemical Features

The details of the investigations are given in the Table for twelve patients, of whom eight had clinical diabetes. At the time of the study some were poorly treated, with high serum iron and chelatable body iron values, but others had been adequately depleted of their iron by venesection. All had normal liver function tests except for some degree of bromosulphthalein retention at one hour. It is of interest that three patients have serum uric acid values below the expected normal for their ages, and moreover five of the group have a daily uric acid excretion of over 500 mg. One patient with a serum uric acid of 2.8 mg. per cent. has a 24-hour urine output of 760 mg. Serum calcium and phosphorus values are normal but some have raised alkaline phosphatase which is felt to be of hepatic origin as no evidence of osteomalacia has been found. The occasional case (5 and 8) shows hypercalciuria. The excretion of both 17-oxosteroids and 17-oxogenic steroids are certainly low for this group of patients who are all leading active normal lives.

(3) Pathology

We have had the opportunity to examine material from one case only. As shown by other authors there can be a profound deposition of iron in the synovial membrane (Fig. 1). Regrettably this patient did not have opacified menisci nor could iron or calcium be found histologically.

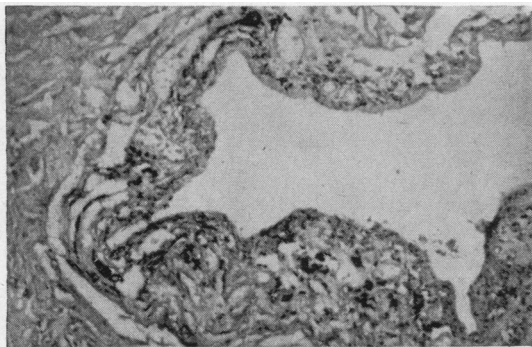


Fig. 1.—Iron deposition in synovial membrane of one patient in the series.

(4) Radiological Features

(A) Arthropathy

The joint changes fall into two major categories—those in the small joints of the hands and wrists and those in the larger joints such as the hips and knees. Changes may perhaps be found in other areas such as the feet, but in this survey only selected views of the hands, knees, hips, pelvis, and lumbar spine were studied.

In the hands and wrists the main features are cysts and erosions with loss of joint space and osteophytes in the metacarpophalangeal and proximal interphalangeal joints, and cysts and erosions in the carpal bones and inferior radio-ulnar joints. Subarticular cysts were found in one or more metacarpophalangeal joints in nine of fourteen patients (Fig. 2). Of these nine patients the proximal interphalangeal joints were affected in five (Fig. 3) and the terminal interphalangeal joints in three. The cysts were usually situated on the proximal side of the joint.

Although serial examinations have not yet been made, there seems little doubt that the initial lesion is the subarticular cyst appearing typically in a metacarpal head. These vary from 1 to 3 mm. in diameter, are round or ovoid, and bounded by a well-demarcated zone of sclerosis (Figs 2 and 3). The joint itself appears to be involved only secondarily when a cyst communicates with the joint cavity presumably either by infraction or simple enlargement

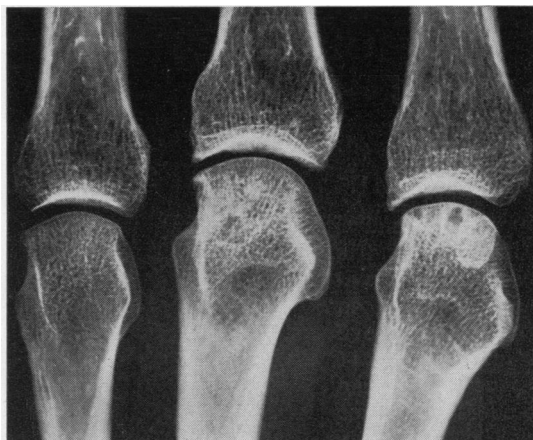

Fig. 2.—Subarticular cysts in head of second metacarpal showing well-defined margins and local sclerosis. Sclerosis affecting head of third metacarpal but cystic change not marked. Osteophytosis of both joints without loss of joint space.

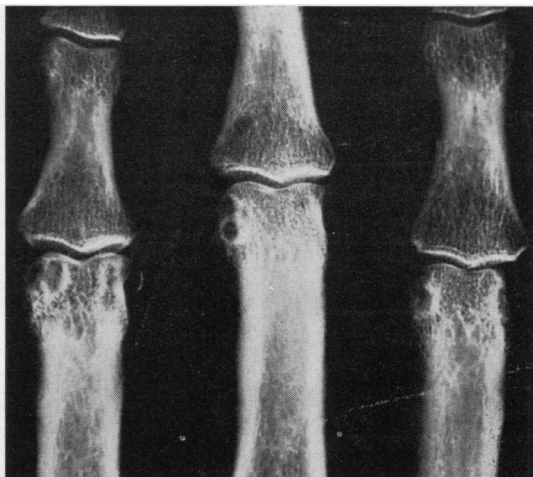


Fig. 3.—Well-defined cysts in head of proximal phalanges; mainly marginal or para-articular in this site.

through the subarticular zone. This is followed by loss of joint space and osteophyte formation (Fig. 4). Reduction of joint space is not necessarily uniform and is frequently most marked at the site of an erosion (Fig. 5). It should be noted, however, that the joint space may well be preserved even in the presence of several subarticular cysts (Fig. 2), and conversely, considerable loss of joint space may be present in the absence of observable cysts (Fig. 6). In one instance widening of an M.P. joint space was observed without other evidence of arthropathy (Fig. 7). Osteophytes were generally a feature of those joints most severely affected, but they were not necessarily associated with marked loss of joint space (Fig. 5). Well-defined cysts were

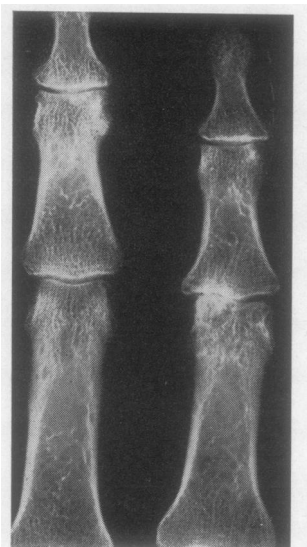


Fig. 4.—Loss of joint space and eburnation affecting ulnar half of P.I.P. joint with slight subluxation.

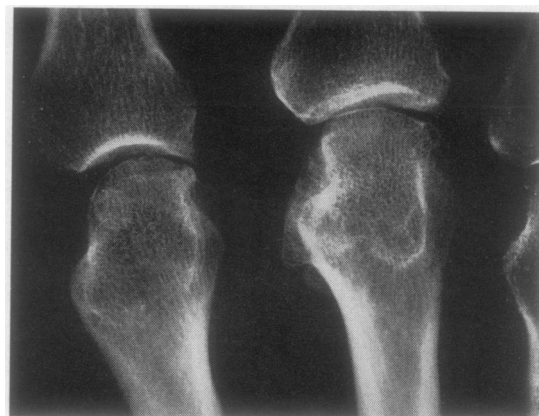

Fig. 5.—Asymmetrical loss of joint space in third and fourth M.C.P. joints with early osteophyte formation.

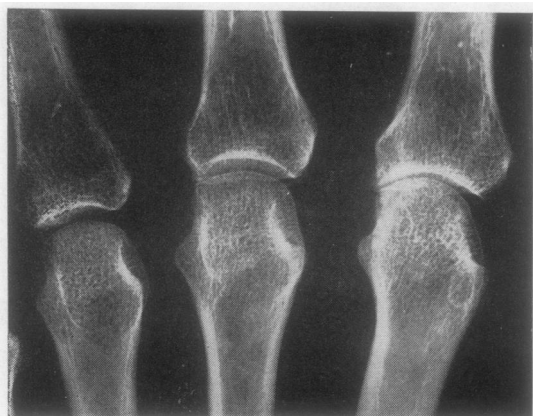

Fig. 6.—Generalized loss of joint space without cyst formation in second M.C.P. joint.

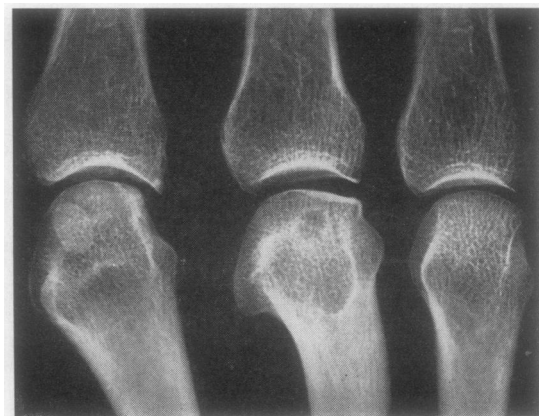

Fig. 7.—Widening of third M.C.P. joint space with minimal sclerosis and lipping of metacarpal head, but large "cyst" visible apparently deep in metacarpal head. Oblique views not obtained to exclude volar erosion.

also present in one or more of the carpal bones in seven of the fourteen patients. These were 5-6 mm. in size and usually multiple with two or three in the same bone. The bones most commonly involved were the capitate, hamate, scaphoid, and lunate (Fig. 8).

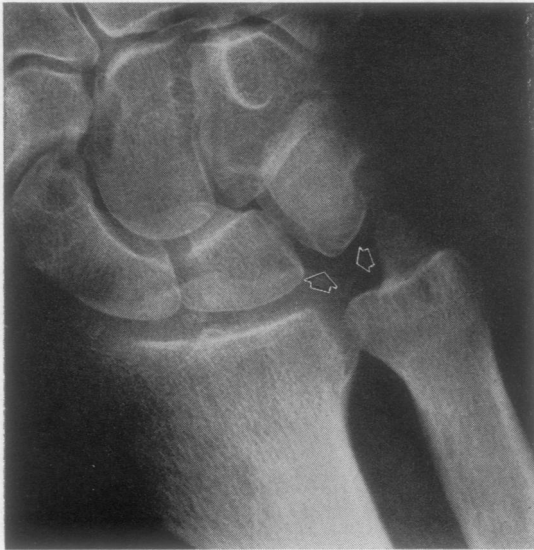

Fig. 8.—Typical appearance of carpal cysts. Generally larger than in other sites with sclerosis not prominent. Note changes also in distal end of ulna, and opacification between lunate and triquetrum.

Changes were present in the radio-ulnar joint and distal end of the ulna in three patients and minor changes were noted in a fourth. In two patients bilateral multiple cysts or erosions were present in the distal end of the ulna and ulnar styloid (Fig. 9a). In one of these patients cysts were also present on

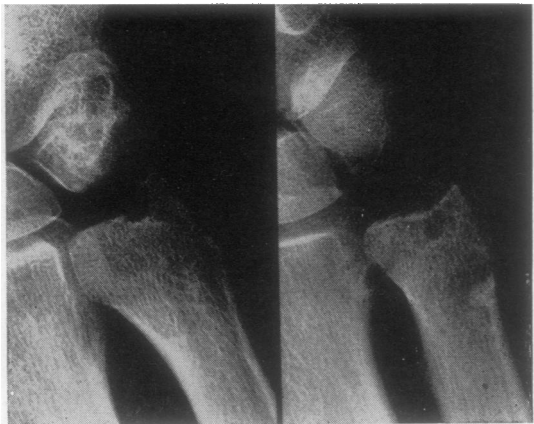

Fig. 9.—Cysts and erosion in head of ulna and ulnar styloid. (b) shows opacification in region of triangular ligament of inferior radio-ulnar joint and cystic change on radial side of joint.

the radial side of the joint and there was opacification in the region of the triangular ligament (Fig. 9b). This was the patient in which meniscal opacification was most marked (*v. infra*). A third patient showed reduction of the inferior radio-ulnar joint space with osteophyte formation. The cystic and erosive changes were similar to those found in rheumatoid disease and gout, but these conditions have been excluded (*v. supra*).

The larger joints were the site of cartilaginous opacification. Thirteen patients had views taken of the knees, and opacity of the meniscal cartilage was present in three of these; in the most florid case there was opacity of the articular cartilage also, in both the hips and the knees (Figs 10 and 11). Two of these three patients and one other showed opaque material deposited in the pubic symphysis (Fig. 12). In several of the patients there were faint punctate opacities in the lateral view of the knees which may represent synovial iron deposition in the region of the infra-patellar fat pad.

(B) Osteoporosis

In this series there was little generalized osteoporosis. It was present in two of thirteen spines and doubtful in two others. The criteria for diagnosis were the presence of endosteal cortical thinning, loss of bone density and of small trabeculae, "pencil-like" of outline of vertebral bodies, and widened disc spaces with biconcave deformity of vertebral bodies with or without evidence of frank compression fracture. Osteoporosis was therefore less apparent than in other series (Schumacher, 1964).

However, the situation in the hands was different, osteoporosis being evident in seven cases and doubtful in one other. Although there was no obvious periarticular accentuation in the small joints of the hands, this was a feature in the wrist where, in the radius and ulna, a zone of patchy porosis separated bone of normal density in the shaft from a markedly porotic distal end in *eight of eleven* cases.

Discussion

Haemochromatosis is more common in France, where it was first described by Trousseau (1865), and also in the United States of America. In Great Britain many cases tend to fit into the concept of a familial disease transmitted by a dominant or intermediate gene. In France and the United States there seems to be more alcoholic cirrhosis complicated by iron overload. Discussion of the concept is topical (Crosby and Macdonald, 1966).

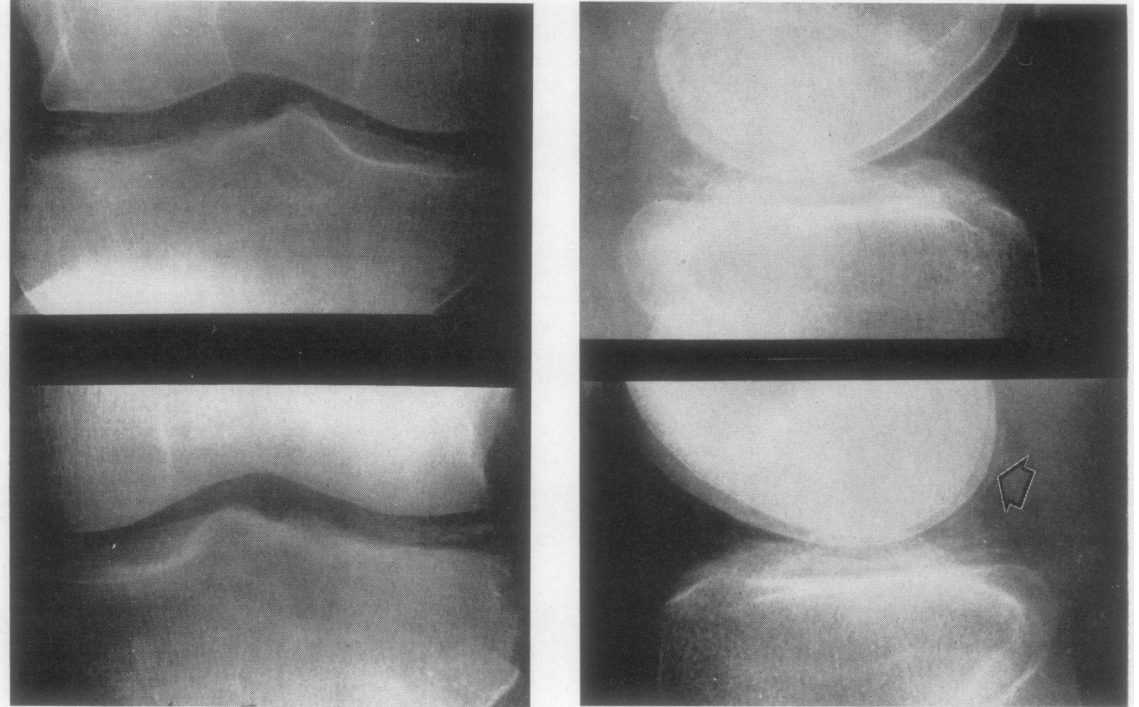


Fig. 10.—Opacification of semilunar (fibro- and articular (hyaline) cartilage. Articular cartilage opacification well shown in femoral condyle posteriorly (arrow).

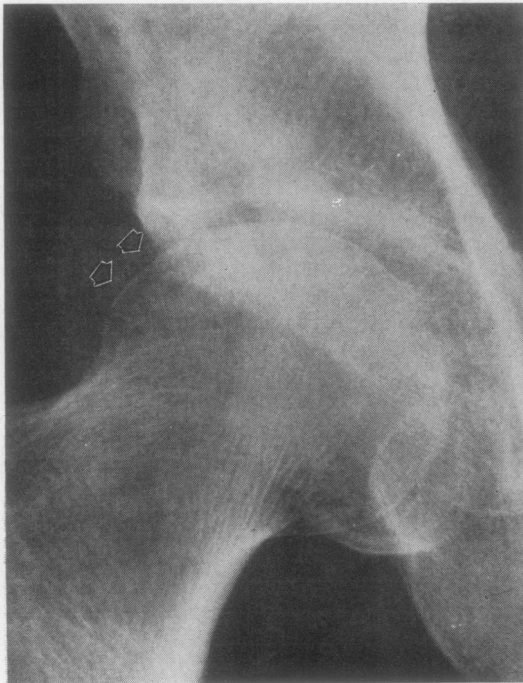


Fig. 11.—Opacification of articular cartilage of femoral head

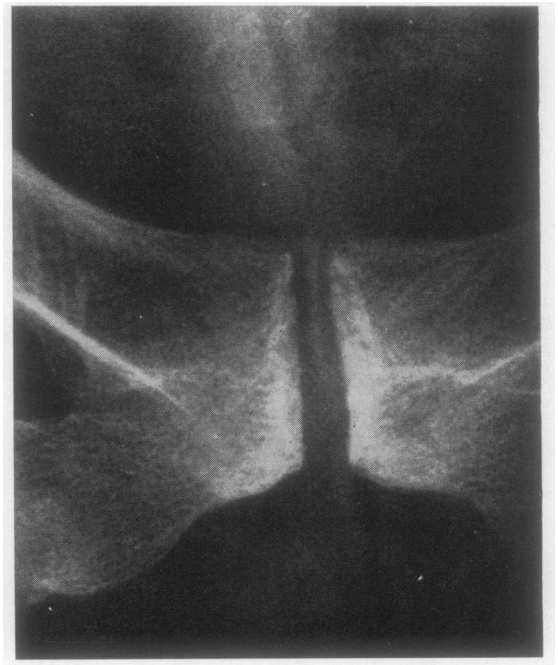


Fig. 12.—Opacification of fibro-cartilage of pubic symphysis.

This may explain why the bone and joint changes have not been described in Great Britain. Nevertheless, the occurrence of the same changes, albeit in a lesser form in our cases, points to iron deposition as the determining factor.

The three theories that to-day contest the field as explanations for the iron accumulation in haemochromatosis are: the theory of Mazur and Sackler (1967) of deficiency of hepatic xanthine oxidase, the theory of tissue protein variants with an unusual affinity for iron as elaborated by Nissim (1966), and the theory of gut protein secretions promoting or opposing the absorption of iron (Davis, Luke, and Deller, 1966).

Mazur's theory can account for both the familial and the cirrhotic types of haemochromatosis. It is of interest that the serum uric acid is low for their ages in some of our cases although it may also be the result of renal tubular leak of uric acid (Table). A search has been made in these patients for urinary xanthine by high voltage electrophoresis of silver salts but without success.

The bromosulphthalein retention reflects the degree of liver cirrhosis. It may be noted that there is no correlation between this and the chelatable body iron. Such fibrosis as has been established is probably not reversed by removal of iron, although there have been descriptions to the contrary. In the same way joint changes, if they are the direct result of iron load, do not correlate with the chelatable body iron but probably reflect again the degree of damage that was established before venesection therapy, there being evidence that multiple venesections will result in removal of haemosiderin from joint tissues (Hamilton, Williams, Barlow, and Smith, 1968). Case 7 would support this view.

The occurrence of diabetes is also probably related to the amount of iron that has been deposited in the pancreas.

The patients have normal serum calcium and phosphorus values. The raised alkaline phosphatase in a few patients is probably of hepatic origin, since there is no theoretical, clinical, or radiographic suspicion of osteomalacia. The only plausible reason for the osteoporosis is androgen deficiency. 17-oxosteroid and 17-oxogenic steroid values are low in many of these active patients, but these figures relate to adrenal rather than testicular function. Indeed, as emphasized by Nissim (1966), both the testis and the adrenal show a high affinity for iron. The finding in some patients of hypercalciuria (Case 5 and 8), which may be episodic, gives some insight into how the osteoporosis is established. The possibility that gut mucosal iron

overload reduces calcium absorption remains to be investigated. Seftel, Malkin, Schuman, Abrahams, Lynch, Charlton, and Bothwell (1966) described osteoporosis co-existing with both scurvy and siderosis in the Bantu. Schumacher (1964) found "significant osteoporosis" in radiographs of the spine of six out of thirty of his patients, but does not mention their ages. Delbarre (1960) certainly found cases with severe osteoporosis and confirmed his findings by bone biopsy and metabolic studies. We, however, in this English series have found very little.

The arthropathy in our patients was clinically unobtrusive and yet discernible on examination as an atypical osteoarthritis. Schumacher (1964) pointed out that there were some similarities to osteoarthritis and rheumatoid arthritis, but certain factors suggest that this arthropathy is indeed a distinct entity. The age at onset and the distribution of the lesions in the hands is different from generalized osteoarthritis, the terminal interphalangeal joints being involved less than the more proximal ones, without evidence of para-articular ossicles. None of this series showed serological evidence of rheumatoid arthritis nor were there any clinical indications of this condition. Although osteoporosis was present in the hands of seven patients, there was no periarticular accentuation.

The presence of opaque material in hyaline and fibro-cartilage in three of fourteen patients is interesting and is a diagnostically significant feature. The nature of this material has hitherto been speculative, but Hamilton and others (1968), in a series of 32 patients suffering from haemochromatosis, have shown the presence of calcium pyrophosphate in the menisci and articular cartilage of the knees of two patients who came to autopsy. In neither case was there any increase in the haemosiderin content over normal controls, although it must be remembered that one of these, and presumably the other also, had been treated by multiple venesections. In an untreated case the possibility that iron deposition, *i.e.* chondrosiderosis, contributes to the radiological picture should at least be considered. The appearances are similar to those of pseudogout, but are also found in gout itself (Dodds and Steinbach, 1966), in primary hyperparathyroidism (Bywaters, Dixon, and Scott, 1963), and in old age (Bocher, Mankin, Berk, and Rodnan, 1965). In fact in seventeen of 31 patients with chondrocalcinosis, McCarty, Gatter, and Brill (1965) noted either overt diabetes or diabetic glucose tolerance curves, although of course glucose tolerance is impaired with age. It is suggested that the opacification of the cartilage could also be a reflection of premature ageing, and in this respect it

is of interest that several of the patients had calcification of the lumbar aorta. Certainly it would be of interest to know the incidence of chondrocalcinosis in diabetes.

Summary

In patients with haemochromatosis there may be a clinically unobtrusive arthropathy, chondrocalcinosis, and perhaps premature osteoporosis. Fourteen patients have been studied for evidence of these features.

(1) There is a relatively silent multiple osteoarthritis with an unusual pattern of distribution. X ray features are found in the small joints of the hands and wrists and in larger joints such as the hips and knees. In three of thirteen patients there was chondrocalcinosis.

Undoubtedly there is deposition of iron in the synovium of the joints, as in the liver, pancreas, and adrenal, but the relationship of this to the

arthropathy is not clear; a high local concentration of iron may affect the ionic balance of calcium.

(2) In this English series, allowing for the ages of the patients, it was difficult to find convincing evidence of osteoporosis, although it did occur in a localized form in the hands. Patients with haemochromatosis may have subnormal adrenal and testicular function, and a degree of androgen deficiency could lead to premature osteoporosis.

(3) Taken in conjunction, the x-ray features are distinctive and should be used in the differential diagnosis of an arthropathy.

We are very grateful for the assistance and advice of Prof. J. H. Kellgren who saw the patients and for his encouragement in preparing the paper, to Dr. M. C. G. Israels under whose care many of the patients are, and to Dr. R. Ollerenshaw of the Department of Medical Illustration for the excellent reproductions. In addition, we would thank Mr. H. Varley for the biochemical findings and Dr. C. Warrick of the Royal Victoria Infirmary, Newcastle upon Tyne, for the loan of some of the radiographs.

REFERENCES

- Bocher, J., Mankin, H. J., Berk, R. N., and Rodnan, G. P. (1965). *New Engl. J. Med.*, **272**, 1093 (Prevalence of calcified meniscal cartilage in elderly persons).
- Bywaters, E. G. L., Dixon, A., St. J., and Scott, J. T. (1963). *Ann. rheum. Dis.*, **22**, 171 (Joint lesions of hyperparathyroidism).
- Crosby, W. H., and MacDonald, R. A. (1966). "Is Hemochromatosis Inherited or Acquired", in "Controversy in Internal Medicine", ed. F. J. Ingelfinger, A. S. Relman, and M. Finland, chap. 10, p. 259. Saunders, Philadelphia.
- Davis, P. S., Luke, C. G., and Deller, D. J. (1966). *Lancet*, **2**, 1431 (Reduction of gastric iron-binding protein in haemochromatosis).
- Delbarre, F. (1960). *Sem. Hôp. Paris*, **36**, 3279 (L'ostéoporose des hémochromatoses).
- , (1964). *Presse méd.*, **72**, 2973 (Les manifestations ostéo-articulaires de l'hémochromatose).
- Dodds, W. J., and Steinbach, H. L. (1966). *New Engl. J. Med.*, **275**, 745 (Gout associated with calcification of cartilage).
- Hamilton, E., Williams, R., Barlow, K. A., and Smith, P. M. (1968). *Quart. J. Med.*, n.s. **37**, 171 (The arthropathy of idiopathic haemochromatosis).
- Mazur, A., and Sackler, M. (1967). *Lancet*, **1**, 254 (Haemochromatosis and hepatic xanthine oxidase).
- McCarty, D. J., Gatter, R. A., and Brill, J. M. (1965). *G. P. (Kansas)*, **31**, No. 6 (June), p. 96 (Crystal deposition diseases: gout and pseudogout).
- , Kohn, N. N., and Faires, J. S. (1962). *Ann. intern. Med.*, **56**, 711 (The significance of calcium phosphate crystals in the synovial fluid of arthritic patients: the pseudogout syndrome).
- Moskowitz, R. W., and Katz, D. (1967). *Amer. J. Med.*, **43**, 322 (Chondrocalcinosis and chondrocalcsynovitis (pseudogout syndrome)).
- Nissim, J. A. (1966). *Guy's Hosp. Rep.*, **115**, 183 (The role of protein in iron metabolism: a clue to primary haemochromatosis).
- Schumacher, H. R. (1964). *Arthr. and Rheum.*, **7**, 41 (Haemochromatosis and arthritis).
- Seftel, H. C., Malkin, C., Schmaman, A., Abrahams, C., Lynch, S. R., Charlton, R. W., and Bothwell, C. H. (1966). *Brit. med. J.*, **1**, 642 (Osteoporosis, scurvy, and siderosis in Johannesburg Bantu).
- Trousseau, A. (1865). "Clinique médicale de l'Hôtel-Dieu de Paris", 2nd ed. Baillière, Paris.

Les changements dans les os et les articulations dans l'hémochromatose**Cambios óseos y articulares en la hemocromatosis****RÉSUMÉ**

Chez les malades atteints d'hémochromatose il peut y avoir cliniquement une arthropathie discrète, une chondrocalcinose, et peut-être une ostéoporose prématurée. Quatorze malades ont été étudiés afin de relever la présence de ces signes.

(1) Il y a une ostéoarthrose multiple relativement silencieuse ayant une distribution peu commune. Les signes radiologiques sont trouvés dans les petites articulations de la main et du poignet et aussi dans les grosses articulations telles que la hanche et le genou. Chez trois des treize malades il y avait une chondrocalcinose.

Indubitablement il y a un dépôt de fer dans la synoviale des articulations, comme aussi dans le foie, le pancréas et les glandes surrénales, mais la relation de ce dépôt à l'arthropathie n'est pas claire; une forte concentration locale de fer peut affecter la balance ionique du calcium.

(2) Dans ce groupe de malades anglais, en tenant compte de leur âge, il est difficile de trouver des preuves convaincantes d'ostéoporose, malgré qu'elle apparaissait sous une forme localisée dans les mains. Les malades atteints d'hémochromatose peuvent avoir un fonctionnement surrénal et testiculaire au-dessous de la normale, et un degré d'insuffisance androgène qui pourrait conduire à une ostéoporose prématurée.

(3) Pris en conjonction, les signes radiologiques sont distinctifs et devraient être employés dans le diagnostic différentiel d'une arthropathie.

SUMARIO

En pacientes con hemocromatosis pueden existir clínicamente una artropatía, una condrocalcinosis y tal vez una osteoporosis prematura. Se ha estudiado a catorce pacientes en busca de estos signos.

(1) Existe una osteoartrosis múltiple relativamente silenciosa con una distribución poco común. Los rasgos radiológicos se encuentran en pequeñas articulaciones de las manos y las muñecas y también en las articulaciones grandes, como las caderas y rodillas. En tres de trece pacientes se descubrió condrocalcinosis.

Evidentemente hay acumulación de hierro en la sinovia de las articulaciones, así como en el hígado, el páncreas y las glándulas suprarrenales, pero la relación de esto con la artropatía no es clara; una alta concentración de hierro podría afectar el equilibrio iónico del calcio.

(2) En este grupo de enfermos ingleses, tomando en cuenta la edad de los pacientes, fue difícil hallar pruebas convincentes de osteoporosis, si bien ocurría en forma localizada en las manos. Los pacientes con hemocromatosis pudieran tener funcionamiento suprarrenal y testicular subnormal, y cierto grado de deficiencia androgénica podría conducir a una osteoporosis prematura.

(3) Tomados en conjunto, los rasgos radiológicos son inconfundibles y deberían ser usados en el diagnóstico diferencial de una artropatía.