

Subchondral vascularity in the human femoral head

C. G. WOODS, A. S. GREENWALD, AND D. W. HAYNES

Nuffield Orthopaedic Centre, Headington

The integrity of articular cartilage is dependent upon the maintenance of an adequate exchange of metabolites. Much of the data from studies on laboratory animal joints has been interpreted as indicating that the exchange of metabolites occurs solely between cartilage and synovial fluid (Brower, Akahoshi, and Orlic, 1962; Maroudas, Bullough, Swanson, and Freeman, 1968; Hodge and McKibbin, 1969). Other investigators, however, have inferred that metabolites not only reach the cartilage *via* the synovial fluid but also supplied from the medullary cavity of the bone supporting the articular cartilage. This has been suggested from studies in rabbits (Ekholm, 1951; Holmdahl and Ingelmark, 1950) and lambs (McKibbin and Holdsworth, 1966). It has recently been reported that such a medullary pathway exists in normal adult human joints (Greenwald and Haynes, 1969). Bullough (unpublished data) has made counts of vascular defects in the subchondral plate of the femoral head after stripping the articular cartilage.

Observations on pathological states of human joints indicate that articular cartilage may be separated from synovial fluid and still survive with chondrocytes and matrix which appear normal in histological sections. The best example of this is the residual articular cartilage left when central osteophyte formation occurs in osteoarthritis. Another example is the fibrous tissue covering which develops over the joint surface, with digestion of cartilage but without necrosis, as in rheumatoid arthritis and chronic haemarthrosis.

In these diseases there are defects in the subchondral plate which form channels which are filled by vascularized medullary soft tissue and extend into the base of the articular cartilage. Vascularization is not always associated with calcification of the cartilage and a solumnar proliferation of chondrocytes. To appreciate whether the degree of vascular invasion observed in the diseased joint is abnormal, comparison with normal joints is necessary.

This paper is concerned with a quantitative description of vascular penetrations in the normal adult human femoral head. Microscopical examination of the subchondral plate showed that the vascularized defects were not of uniform type, and the different morphological types and their possible significance is also discussed.

Materials and methods

Fifteen complete human hip joints were removed *post mortem* from subjects in the age range 20 to 86 years. After thawing and disarticulation, the joints were subjected to a load contact area experiment, where contact and non-contact areas of the hip were determined (Greenwald, 1969). On completion of this study the femoral head was fixed in 10 per cent. neutral formalin. A slice 5 mm. thick was sawn from the femoral head after 24 hours' fixation. The plane of sawcut passed through the fovea and the least and greatest arc of the inferior and superior surfaces respectively. In some of the femoral heads further slices were taken at right-angles to this plane. After a further 24 hours fixation, the slices were radiographed to obtain contrast between cartilage and bone. This was done by using *x* rays at 40 kv and Kodolith sheet film.

The slices of bone were decalcified in 5 per cent. nitric acid, decalcification being controlled radiographically. When decalcification was complete the specimens were subdivided into pieces of convenient size for paraffin embedding and mounting on to 3" × 1" microscope slides. 5- μ sections were cut and stained with Ehrlich's haematoxylin and eosin. Utilizing the radiograph, the histological specimens were orientated and subdivided into arcs of $\frac{1}{8}$ ". Each arc was identified by a number and examined in transmitted and polarized light. The latter method enables one to distinguish clearly between articular cartilage, calcified cartilage, and subchondral bone. On a print of the radiograph the numbered arcs of articular cartilage and the contact and non-contact zones were marked (Fig. 1, opposite).

The thickness of the articular cartilage was measured at the intersections of the specified arcs using the radiograph negative viewed through a binocular dissecting microscope. A comparison was made of defects in the contact and non-contact areas with age.




FIG. 1 A print from a radiograph of a slice of a 30-year-old human femoral head. Arcs of $\frac{3}{8}$ " are marked on the print. Non-contact areas are noted by arcs 1, 2, and 6. Arcs 3, 4, and 5 are contact areas.

A statistical analysis was carried out on the differential counts fitting 'least square' straight lines to the data. For these regression lines, correlation coefficients were obtained to test the significance of the fit and, using the 't' test, confidence levels were predicted.

Results

Histological examination shows the basic structure of the subchondral plate to be composed of lamellar bone in which the lamellae lie parallel to the joint surface. The Haversian canals within this structure are enclosed in complete rings of bone lamellae. Within this pattern there are breaks which affect the relationship between bone and cartilage which are of three types.

Complete breaks in the junction between bone and cartilage which are occupied by vascularized fibrous tissue were designated as a Type 'A' struc-

ture (Fig. 2). Occasionally the defect in the bone extends through the full thickness of the subchondral plate, but more often the defect appears incomplete because of the plane of sectioning. A constant finding in these defects is the extension of soft tissue into the cartilage. Invasion extends into the basal cartilage only, or into the hyaline cartilage causing a discontinuity in the basophilic line. This 'A' type of defect is not further subclassified as the essential characteristic is the direct contact between soft tissue and cartilage. Other defects in bone filled by vascularized soft tissue which projected into the cartilage differed from the Type 'A' structure in having a shell of bone separating soft tissue from cartilage. This bone is sometimes clearly identifiable as having a woven type of matrix, but often the shell is too thin for certain recognition of the bone type. It is possible that some of these structures represent a Type 'A' structure cut as it approaches its definitive relationship with cartilage.

Woven bone was assumed to indicate new bone formation within the soft tissue. As there was no means of specifying the relationship of the bone to the soft tissue in every case, it was decided to group all the bone-invested structures together and to designate them as Type 'B' (Fig. 3, overleaf).

Also projecting from the external surface of the lamellar bone into the cartilage there are small pieces of woven bone. These structures may have a very tiny vascular channel within them or may appear to be unvascularized. These structures were classified as Type 'C' (Fig. 4, overleaf).

There were no abnormalities of chondrocyte orientation or matrix structure in any of the femoral

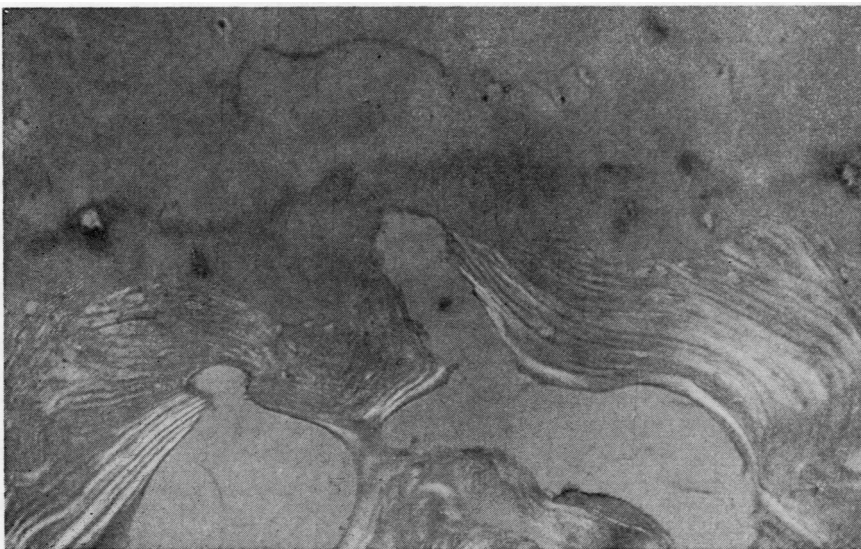


FIG. 2 Type 'A' structure. $\times 160$.

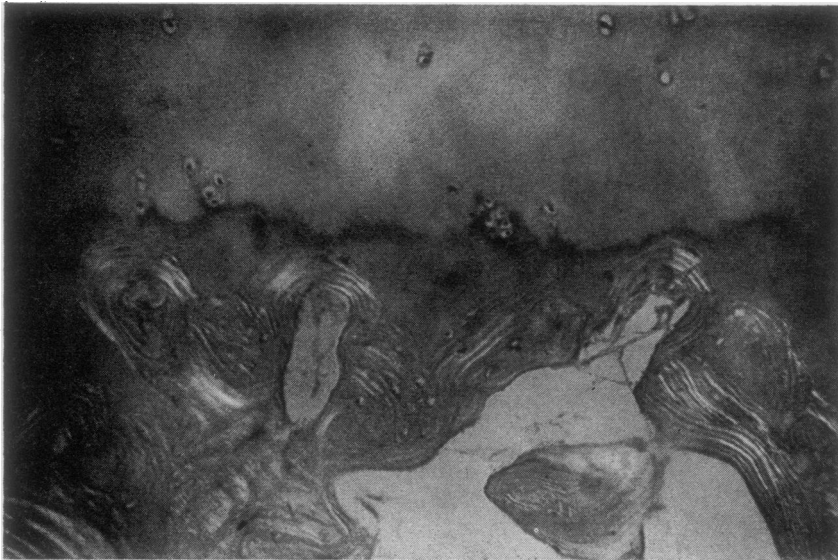

FIG. 3 *Type 'B' structure. × 160.*



FIG. 4 *Type 'C' structure. × 160.*

heads included in the statistical analysis. Differential counts were made of the 'A', 'B', and 'C' type structures in each specified arc. The Table gives the figures relating to the bone slice depicted in Fig. 1. It will be seen that there are more defects of all types at the centre of the articular surface than at the periphery, and this is true of all the specimens.

Comparison of the density of the defects beneath articular cartilage of different thickness indicates that they are more numerous where the cartilage is thicker. There is also a greater density of vascular channels beneath the contact than beneath the non-contact areas.

To test the hypothesis that the Type 'C' structure represents ossification of an initially vascularized defect, graphs were constructed (Figs. 5 and 6, opposite).

The proportion of vascularized defects (A + B) to total defects (A + B + C) was plotted against age for

Table *Subchondral defects per $\frac{3}{8}$ " arc length of a 30-year-old femoral head. Arcs 3, 4, and 5, are contact areas*

Arc No.	Defect			Average arc thickness (mm.)
	Type A	Type B	Type C	
1	6	0	2	1.797
2	1	4	9	2.109
3	6	12	10	3.922
4	7	7	20	2.828
5	6	3	17	2.516
6	1	0	2	1.916

equal portions of contact and non-contact areas. For convenience this ratio is termed the index of vascularity. The correlation analysis performed on the regression lines ($r = -0.952$; $P < 0.01$ (Fig. 5) and $r = -0.924$; $P < 0.01$ (Fig. 6)) indicates that a significant correlation exists between the parameters plotted. The equations of the lines were determined with 99 per cent. confidence limits. Both graphs show a steady decline in the vascular ratio with advancing age in both contact and non-contact areas. The negative slopes are for all practical purposes identical.

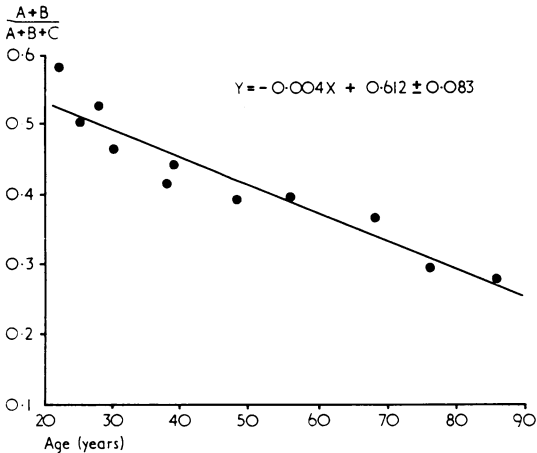


FIG. 5 Relative vascularity against age in contact areas.

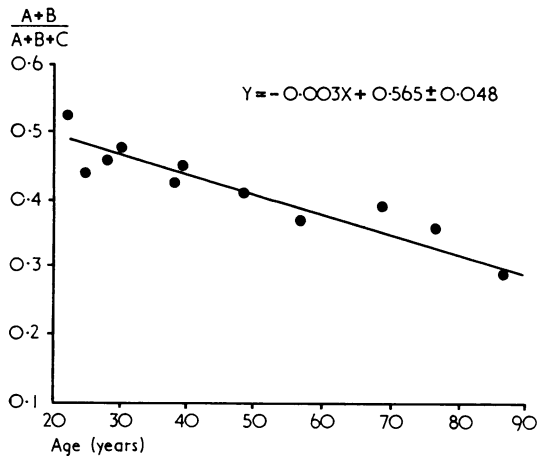


FIG. 6 Relative vascularity against age in non-contact areas.

Further graphs (Figs 7 and 8) were plotted showing the total number of defects present (A + B + C) against age for equal portions of the contact and non-contact areas. These graphs indicate that in both contact and non-contact areas the total number of defects present show no change throughout adult life.

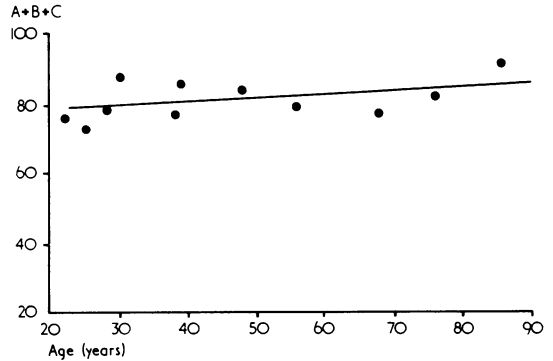


FIG. 7 Total defects against age in contact areas.

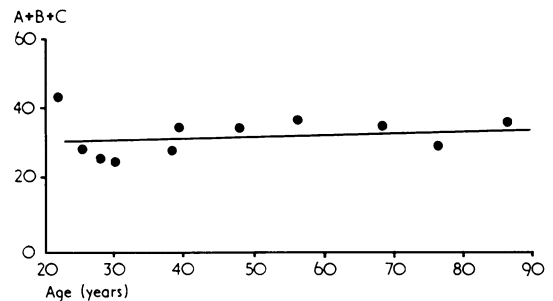


FIG. 8 Total defects against age in non-contact areas.

Discussion

Observations of the defects suggest that they represent different phases in the natural history of the subchondral plate.

The graphs (Figs 7 and 8) of the total defects plotted against age indicate that the total number of these structures remains virtually constant throughout adult life and are more numerous in the weight-bearing areas. The vascular channels are sites of bone deposition and some become completely ossified with advancing years.

The other graphs (Figs 5 and 6) show that the index of useful vascularity decreases with age in the same proportion in both the weight-bearing and non-weight-bearing areas. Since non-weight-bearing areas have fewer defects, they would be depleted of useful vascular channels before the weight-bearing areas. It is interesting to note from clinical observations (Harrison, Schajowicz, and Trueta, 1953; Goodfellow and Bullough, 1967) that initial degenerative changes in the articular surface occur in the non-weight-bearing areas. The possible relationship between this changing vascularity and the sites of earliest degeneration in osteoarthritis merits further study.

In the weight-bearing areas, where the number of vascular defects were greatest, the cartilage was

thicker. This observation may suggest that the nutrition of the cartilage is influenced by the number of points of contact which exist between cartilage and soft tissue.

Summary

Three types of defects in the subchondral plate of normal human femoral heads are described. The

data of the distribution of these defects in different parts of the femoral head in the age range 20 to 86 years are presented and the possible relationship to thickness and function of the articular cartilage is discussed.

This work was supported by a grant from the Arthritis and Rheumatism Council. We wish to thank the technical, photographic, and secretarial staff at the Nuffield Orthopaedic Centre for invaluable assistance.

References

- BROWER, T. D., AKAHOSHI, Y., AND ORLIC, P. (1962) *J. Bone Jt Surg.*, **44A**, 456 (The diffusion of dyes through articular cartilage *in vivo*).
- EKHOLM, R. (1951) 'Articular Cartilage Nutrition'. *Acta anat. (Basel)*, **11**, Suppl. 15.
- GOODFELLOW, J. W., AND BULLOUGH, P. G. (1967) *J. Bone Jt Surg.*, **49B**, 175 (The pattern of ageing of the articular cartilage of the elbow joint).
- GREENWALD, A. S. (1969) D. Phil. Thesis, Department of Engineering Science, Oxford University.
- AND HAYNES, D. W. (1969) *J. Bone Jt. Surg.*, **51B**, 747 (A pathway for nutrients from the medullary cavity to the articular cartilage of the human femoral head).
- HARRISON, M. H. M., SCHAJOWICZ, F., AND TRUETA, J. (1953) *Ibid.*, **35B**, 598 (Osteoarthritis of the hip: a study of the nature and evolution of the disease).
- HODGE, J. A., AND MCKIBBIN, B. (1969) *Ibid.*, **51B**, 140 (The nutrition of mature and immature cartilage in rabbits).
- HOLMDAHL, D. E., AND INGELMARK, B. E. (1950) *Acta orthop. scand.*, **20**, 156 (The contact between the articular cartilage and the medullary cavities of the bone).
- MARODAS, A., BULLOUGH, P., SWANSON, S. A. V., AND FREEMAN, M. A. R. (1968) *J. Bone Jt Surg.*, **50B**, 166 (The permeability of articular cartilage).
- MCKIBBIN, B., AND HOLDSWORTH, F. W. (1966) *Ibid.*, **48B**, 793 (The nutrition of immature cartilage in the lamb).

RÉSUMÉ

La vascularisation sous-chondrale de la tête fémorale chez l'homme

Trois types de défauts dans la plaque sous-chondrale de la tête fémorale normale de l'homme sont décrits. Les données de la distribution de ces défauts dans les différentes parties de la tête fémorale entre l'âge de 20 et 86 ans sont présentées et leur relation possible à l'épaisseur et à la fonction du cartilage articulaire est discutée.

SUMARIO

Vascularidad subcondral en la cabeza femoral humana

Se describen tres tipos de defectos en la placa subcondral de cabezas femorales humanas normales. Se exponen los detalles de la distribución de estos defectos en diferentes partes de la cabeza femoral en personas de entre 20 y 86 años de edad, y se discute la posible relación con el grosor y la función del cartilago articular.