

Scleritis and aortic incompetence

Two manifestations of connective tissue disease

D. A. PITKEATHLY, G. HOWITT, AND A. J. LYNE*

From the Departments of Rheumatism Research and Cardiology, Manchester Royal Infirmary, and the Manchester Royal Eye Hospital

Scleritis is known to occur as a manifestation of connective tissue disease, particularly rheumatoid arthritis and polyarteritis nodosa (Manschot, 1961). In a recent study of 31 patients with scleritis (Lyne and Pitkeathly, 1968), evidence of connective tissue disease was found in fourteen (45 per cent.). Since this study was completed, we have encountered a further three patients presenting with scleritis in whom aortic incompetence was found. Two had severe aortic regurgitation and complete atrioventricular (AV) block. The third had a diffuse arteritis, and the aortic incompetence was only a minor feature of this illness.

Case reports

Case 1, a 56-year-old housewife, gave a 5-year history of almost continuous inflammation affecting the left eye with severe pain at times. The right eye had never been involved. For 2 years she had complained of breathlessness, weakness, tiredness, and light-headedness on exertion. During the previous few months, she had experienced episodes of dizziness and had lost consciousness on several occasions.

Examination The abnormalities were confined to the left eye and the cardiovascular system.

The perilimbal sclera of the left eye showed diffuse thinning for about 2 mm. all round. The sclera elsewhere was thickened by a subconjunctival granulomatous-like infiltration. A fairly severe uveitis was present. There was elevation of the retina on the temporal side subjacent to the site of the most intense inflammation.

The pulse was regular, collapsing in type, and the rate 38/min. The blood pressure was 220/40 mm. Hg. A hyperdynamic left ventricular impulse was palpable. There was a short aortic ejection systolic murmur and a moderately long aortic diastolic murmur. The aortic second sound was diminished.

INVESTIGATIONS Haemoglobin (Hb) 13.7 g./100 ml. Erythrocyte sedimentation rate (ESR) 3 mm./hr (Westergren). Sheep cell agglutination test (SCAT) negative

< 4. Latex-fixation test (LFT) negative (< 20). Antinuclear factor (ANF) test negative. LE-cells negative. Serological tests for syphilis (STS) negative. Serum albumin 4.2 g./100 ml. Serum globulin 2.6 g./100 ml.

X-RAY APPEARANCES Chest: cardiac enlargement, cardiothoracic ratio (CTR) 0.56; aortic shadow normal; lung fields normal. Lumbar spine and sacro-iliac joints: normal. Hands and feet: osteoarthritic changes only. Calcanea: bony spurs posteriorly.

ELECTROCARDIOGRAM (ECG) Complete AV block. QRS duration 0.14/sec. QRS configuration: right bundle branch block.

Progress She was admitted urgently shortly after the diagnosis of aortic incompetence was made on account of a Stokes-Adams attack. The ventricular rate was 28/min. and after a few days of observation with a temporary pacemaker, a permanent axillary pacemaker with an endocardial pacing electrode was inserted.

For the past 18 months her cardiac condition has been satisfactory, but a further severe attack of scleritis has occurred in the left eye and the development of secondary uveitis has resulted in blindness in this eye.

Case 2, a 43-year-old labourer, gave a history of left-sided scleritis of 3 years' duration. An exacerbation of symptoms in November, 1967, was associated with a secondary anterior uveitis, and it had been necessary to give a course of systemic corticosteroids in the form of prednisolone. The course lasted for 6 months, the dose of prednisolone being gradually reduced from 20 mg. daily to zero. Apart from discomfort in the left eye, the only other symptom of note was Raynaud's phenomenon, which had been present for about 2 years. He had no symptoms related to the heart.

He had an episode of acute inflammatory polyarthritis 6 years previously, and had been confined to bed for 4 months on account of generalized pain and stiffness, but had become symptom-free at the end of 6 months.

Examination Perilimbal scleral thinning was present in the left eye, and the conjunctiva was diffusely elevated by

*Present address: Peterborough and District Memorial Hospital

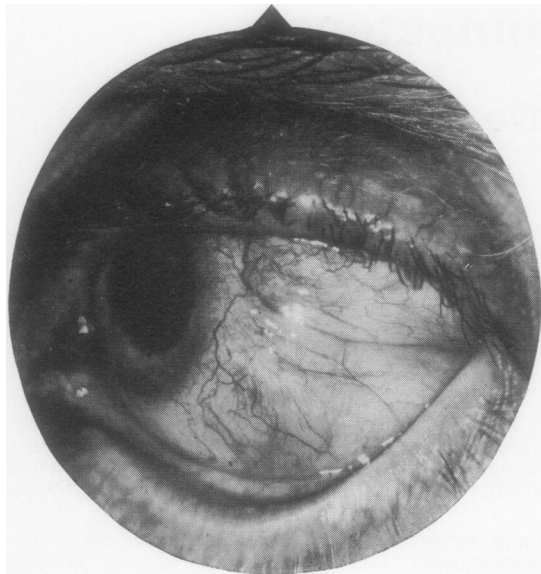


FIG. 1 *Appearance of affected eye in Case 2.*

granulomatous tissue (Fig. 1). A severe anterior uveitis with flare in the anterior chamber and multiple posterior synechiae were observed. An area of choroiditis was seen on the temporal side.

The pulse was regular, collapsing in type, and the rate was 38/min. The blood pressure was 190/40 mm. Hg. The cardiac impulse was left ventricular in type. There were aortic systolic and diastolic murmurs and the aortic second sound was diminished.

Minimal flexion deformities of the proximal interphalangeal and metacarpophalangeal joints were present. The right wrist was slightly limited in dorsiflexion. Spinal movement was full.

INVESTIGATIONS Hb 14 g./100 ml. ESR 35 mm./hr (Westergren). SCAT negative (16). LFT negative (80). ANF negative. LE-cells negative. STS negative. Serum albumin 3.9 g./100 ml. Serum globulin 3.5 g./100 ml. Electrophoresis showed a normal globulin pattern.

X-RAY APPEARANCES Chest: considerable cardiac enlargement (CTR 0.66); aortic shadow normal; lung fields normal. Hands and feet: normal. Sacro-iliac joints: normal.

ECG Complete AV block. QRS duration 0.14 sec. nds QRS configuration: right bundle branch block.

Course Local treatment was continued for the left-sided scleritis. The cardiac lesion was symptomless and no treatment was given. 2 months after the aortic incompetence and AV block were discovered, the patient died suddenly at home. An autopsy was not carried out.

Case 3, a 63-year-old woman, presented with scleritis of the right eye. She gave a history of admission to another hospital 12 months previously on account of tiredness and loss of weight. A moderately severe anaemia had been found and she had been given several courses of parenteral iron over the next 6 months with little effect. No cardiac murmurs were observed at that time. She then developed scleritis and during the next few months the eye was continuously inflamed. For a time the left eye was also inflamed. In addition, she complained of tightness in the calves after walking and paraesthesiae and numbness in the left foot.

Examination There was obvious weight loss and pallor. Scleritis and scleral thinning were present in both eyes. A secondary uveitis was noted in the right eye. Extensive livedo reticularis was present on all four limbs. The pulse was regular, normal in character, 80/min. The blood pressure was 140/85 mm. Hg. The cardiac impulse was left ventricular in type. There was a short soft aortic systolic murmur and also a short aortic diastolic murmur.

INVESTIGATIONS Hb 10.1 g./100 ml. ESR 102 mm./hr. SCAT negative (< 8). LFT negative (< 20); ANF negative; LE-cells not seen. Blood urea 154 mg./100 ml. Urinary protein 40 mg./100 ml. Mid-stream specimen of urine leucocytes and red blood cells present; no growth on culture. Urinary urea 660 mg./100 ml. Serum albumin 3.5 g./100 ml. Serum globulin 3.2 g./100 ml. STS negative.

X-RAY APPEARANCES Chest: cardiac contour suggested left ventricular enlargement (CTR < 0.5); aortic shadow normal; lung fields normal.

ECG Within normal limits (PR interval = 0.16 second).

SKIN BIOPSY No abnormality detected.

MUSCLE BIOPSY Slight muscle atrophy and a few inflammatory cells in relation to a small blood vessel.

Course Treatment was started with prednisolone 100 mg. daily.

The scleritis subsided and the other symptoms improved. The blood urea fell to 102 mg./100 ml. The prednisolone dose was accordingly reduced gradually to 37.5 mg. daily and she was discharged. She was re-admitted 2 months later because of the sudden onset of severe dyspnoea. She was in congestive cardiac failure. There was widespread T wave inversion on the ECG. The rhythm was mainly sinus with occasional paroxysms of atrial fibrillation. Although there was an initial response to treatment, she deteriorated again and died suddenly 4 days after admission.

Autopsy The relevant findings (Dr. J. Ball) were as follows:

VASCULAR LESIONS: Healed minor and moderately severe lesions of polyarteritis nodosa (PAN) were found in the right submandibular gland, both kidneys, the liver, the ileum, the left ventricular myocardium, the thymus, the bladder, both peroneal nerves, the adipose tissue surrounding the ascending aorta, and the para-articular ligamentous tissues of the right proximal interphalangeal joint of the index finger. PAN was not found in lung, pancreas, skin, spleen, or right median nerve. In most

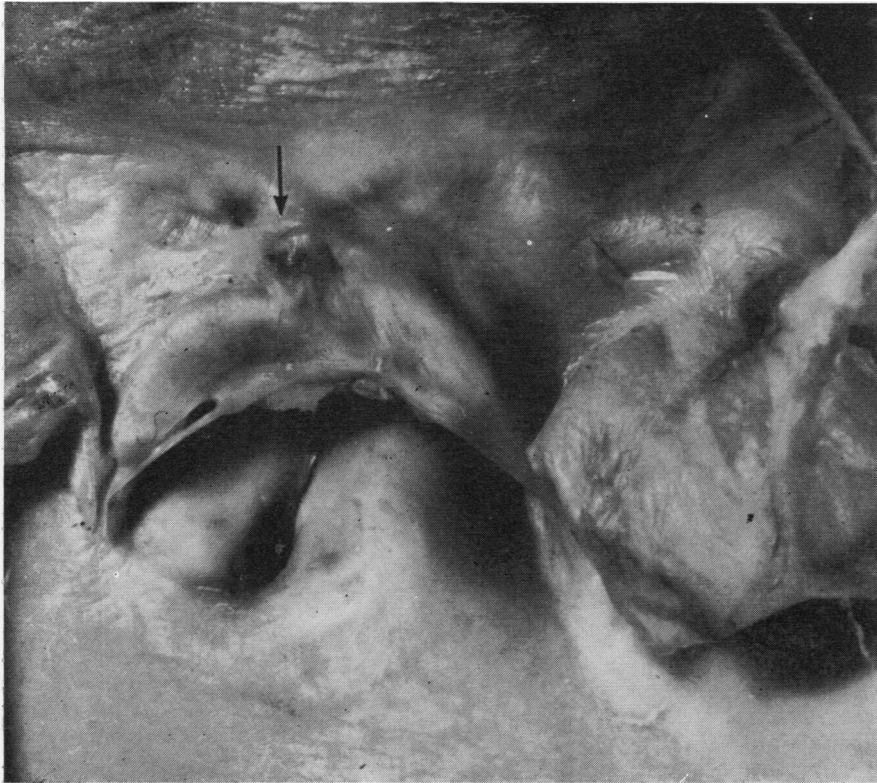

FIG. 2 *Autopsy appearance of calcific nodule on central cusp in Case 3.*

cases the lumen of affected arteries was patent, if reduced in diameter. Inflammatory cell infiltration was minimal or absent. In one vessel in the renal pelvis the wall was calcified.

LIVER AND LUNGS Congestive changes present.

HEART The pericardium was adherent throughout but just separable. The epicardial surface of the heart was roughened and hyperaemic. The heart was enlarged (560 g.) because of left ventricular hypertrophy. The myocardium was healthy apart from very rare microscopic foci of fibrosis.

AORTIC VALVE The mitral and septal cusps were healthy. The central (anterior) cusp was smaller than the others owing to a vertical scar running from the central point of attachment towards the free border. At the central point of attachment, the cusp was swollen by a calcific nodule (Fig. 2, overleaf), the matrix of which was a homogenous structureless material lacking collagen and elastic fibres.

The distal part of the valve was healthy. Scanty lymphocytes and haemosiderin containing phagocytes were present around the calcific focus. The aorta in the plane of the calcific nodule was healthy. Sections of the cusp near the calcific nodule showed small collections of lymphocytes localized to the root of the valve but no vascular lesion was seen; the aorta in this region was healthy and not dilated.

CORONARY ARTERIES Slight atheroma, but widely patent.

KIDNEYS Both were similar. In addition to healed PAN of arcuate and smaller vessels, there was widespread focal or complete necrosis of glomerular tufts, involving about half the glomeruli. Some foci of tubular degeneration and fibrosis were also present. The pelves were healthy. The parenchymal lesions were those of PAN.

Microscopic examination of the right eye (Dr. A. Garner) revealed the following:

'The cornea is essentially healthy with intact Bowman's and Descemet's membranes, though on one side there is a little non-specific chronic inflammatory pannus invading the subepithelial zone at the periphery. The anterior episclera and bulbar conjunctiva on both sides also show some diffuse lymphocytic and plasma cell infiltration associated with scarring and some attenuation of the anterior sclera on the side showing the corneal pannus. The iris and ciliary body are both normal but the lens shows some early subcapsular cataractous change. There is no evidence of retinal or choroidal disease and the optic nerve appears healthy apart from a few calcified corpora amylacea in the region of the nerve sheath and posterior episclera'.

Discussion

The sclera has a purely supportive function in the eye. It consists of interlacing collagen fibres with only

occasional elastic fibres and an amorphous ground substance (Swan, 1951). As the structure is almost acellular and avascular, disease of the sclera is comparatively rare (Duke-Elder and Leigh, 1965). However, the sclera together with other connective tissue structures, is often affected in the 'collagen' diseases, the lesion being a fibrinoid necrosis of the protein-polysaccharide of the ground substance (Klemperer, Pollack, and Baehr, 1942).

The episclera differs from the sclera in having greater vascularity and superficiality. Inflammation can be due to minor trauma or 'allergic' factors causing a vascular insult, for example, erythema nodosum (Duke-Elder and Leigh, 1965). Episcleritis is also seen in the group of connective tissue diseases (Stillerman, 1951; Manschot, 1961), but among patients presenting with episcleritis the incidence of these diseases is low (Lyne and Pitkeathly, 1968). The uveal tract (composed of the iris, ciliary body, and choroid) is also highly vascular. It readily shares in systemic disease and participates violently in hypersensitivity states (Duke-Elder and Perkins, 1966).

Inflammation of the sclera in contrast to the episclera and uveal tract implies true non-vascular connective tissue involvement, usually chronic in character, and often leading to severe destruction of the tissue. Deep scleritis may affect the uveal tract secondarily and this can mask the true origin of the inflammation. Because the two structures have differing relationships to systemic disease, it is of great importance to identify the tissue which is primarily involved.

Scleritis has been described in a variety of connective tissue diseases, but it occurs principally in polyarteritis nodosa and rheumatoid arthritis (Manschot, 1961). The third patient had sclerokeratitis and this condition was also found in our two previously reported patients with polyarteritis (Lyne and Pitkeathly, 1968). In rheumatoid arthritis several types of scleritis have been described, including scleromalacia perforans, necrotizing nodular scleritis, and massive granuloma of the sclera (Duke-Elder and Leigh, 1965). Although Sevel (1967) has criticized these terms on the basis that they merely represent different phases of the same process, it is noteworthy that the first and second patients were very similar as regards their cardiac lesion, and both had massive granuloma of the sclera. This type of scleritis has a characteristic clinical picture. The cornea is encircled by a diffuse tumour-like inflammation with a gelatinous appearance. Histologically there is lymphocyte and plasma cell infiltration forming a granulomatous mass in which fibrinoid necrosis is evident (Wolter and Landis, 1958; Cernea and Nicolau, 1961).

Both Manschot (1961) and Duke-Elder and Leigh, (1965) state that massive granuloma of the sclera occurs principally in patients with rheumatoid arthritis. The only link with the disease in our two patients is the history of a self-limiting polyarthritis in the second patient. It cannot be denied that this illness could have been acute rheumatoid arthritis, which went into complete remission and left only minimal residua. If this was the course of events, then the disease was entirely different from that described by Weintraub and Zvaifler (1962) in five patients with rheumatoid arthritis and aortic incompetence. All five had severe continuing disease with destruction of joint surfaces, subcutaneous nodules, and high titres of rheumatoid factor. Of particular interest, however, was the presence of nodular episcleritis or scleromalacia perforans in three of them.

Massive granuloma of the sclera has also been described in syphilis (Verhoeff, 1913), but serological tests for this disease in both our patients were negative.

The aortic incompetence in the third patient was due to a valvular lesion, the cause of which is not entirely clear. The presence of foci of inflammatory cells near the root of the central cusp and in relation to the calcific nodule suggests that the polyarteritis may have been contributory. In this context it must be borne in mind that high dosage steroid therapy has a profound effect on the inflammatory response. Marquis, Richardson, Ritchie, and Wigle (1968) reviewed the literature concerning non-syphilitic aortitis and discussed the role of this condition in causing aortic incompetence. They pointed out that aortitis could be found in association with ankylosing spondylitis, Reiter's disease, and giant cell arteritis, and stressed the common histological picture of patchy destruction of elastic and muscle fibres of the media with secondary fibrosis of the intima and sometimes also of the adventitia. If the disease involves the root of the aorta, the aortic valve may be involved. In such cases, the valve cusps are thickened with rolled free margins and there is thickening and separation of the commissures (Ansell, Bywaters, and Doniach, 1958). Marquis described five patients with aortitis of unknown cause, three of whom presented with aortic incompetence. One of these three, a 19-year-old male, also had Grade 1 heart block (PR interval 0.26 sec.), scleritis, and transient swelling of the knees. He was admitted in left ventricular failure and failed to respond to all measures employed. At autopsy the proximal 5 cm. of the aorta was thickened and dilated and the media in this area was almost completely destroyed. The aortic valve cusps were grossly thickened and shortened.

Electrocardiographic changes may occur alone or in association with aortic incompetence in ankylosing spondylitis (Ansell and others, 1958; Sobin and Hagstrom, 1962), Reiter's disease (Csonka, Litchfield, Oates, and Willcox, 1961; Rodnan, Benedek, Shaver, and Fennell, 1964), and rheumatoid arthritis (Gowans, 1960; Hoffman and Leight, 1965). The usual abnormality is prolongation of the PR interval; complete heart block is rare (Julkunen and Luomanmäki, 1964). Complete heart block occurs in a wide range of diseases affecting the myocardium and coronary vessels (Siddons and Sowton, 1967). Because of the proximity of the aortic ring to the atrio-ventricular conduction system, diseases of the root of the aorta would be expected to affect cardiac conduction, and it is most probable that the aortic incompetence and complete heart block in the first two of our cases were manifestations of an inflammatory lesion at the root of the aorta.

Contardo (1956) discussed the significance of eye conditions, such as scleritis and uveitis, as presenting signs of disease processes in other body tissues. He emphasized that eye disease of a certain nature often implied repetition of the same type of lesion in other organs. The presence of a spreading granulomatous inflammation in the aortic wall adjacent to the aortic valve could account for the severe valvular insufficiency and complete heart block in the first

and second patients. While it is necessary to screen all patients with scleritis for connective tissue disease, it would seem particularly desirable to investigate patients with massive granuloma of the sclera for evidence of aortic valve disease and disorders of atrio-ventricular conduction.

Summary

Three patients with scleritis and aortic incompetence are described. One patient had sclerokeratitis and mild aortic regurgitation, both occurring in the course of a diffuse arteritis.

The other two patients had massive granuloma of the sclera, severe aortic regurgitation, and complete atrio-ventricular block; one had a past history of polyarthritis. It is suggested that these features were due to a localized form of connective tissue disease.

We should like to thank the consultant surgeons of the Manchester Royal Eye Hospital for allowing us to study these patients. The third patient was admitted under the care of Prof. J. H. Kellgren, whom we thank for allowing us to publish the case report and for his interest and encouragement. We gratefully acknowledge the assistance of Drs. J. Ball and A. Garner in supplying the pathological data in Case 3.

References

- ANSELL, B. M., BYWATERS, E. G. L., AND DONIACH, I. (1958) *Brit. Heart J.*, **20**, 507 (The aortic lesion of ankylosing spondylitis).
- CERNEA, P., AND NICOLAU, C. (1961) *Oftalmologia (Buc.)*, **5**, 235 (Malignant gelatinous scleritis).
- CONTARDO, R. (1956) *A.M.A. Arch. Ophthalm.*, **56**, 568 (Evolution of the collagen diseases).
- CSONKA, G. W., LITCHEFIELD, J. W., OATES, J. K., AND WILLCOX, R. R. (1961) *Brit. med. J.*, **1**, 243 (Cardiac lesions in Reiter's disease).
- DUKE-ELDER, S., AND LEIGH, A. G. (1965) "System of Ophthalmology", vol. 8, part 2, pp. 995, 1106. Kimpton, London.
- AND PERKINS, E. S. (1966) "System of Ophthalmology", vol. 9, p. 60. Kimpton, London.
- GOWANS, J. D. C. (1960) *New Engl. J. Med.*, **262**, 1012 (Complete heart block with Stokes-Adams syndrome due to rheumatoid heart disease).
- HOFFMAN, F. G., AND LEIGHT, L. (1965) *Amer. J. Cardiol.*, **16**, 585 (Complete atrio-ventricular block associated with rheumatoid disease).
- JULKUNEN, H., AND LUOMANMÄKI, K. (1964) *Acta med. scand.*, **176**, 401 (Complete heart block in rheumatoid (ankylosing) spondylitis).
- KLEMPERER, P., POLLACK, A. D., AND BAEHR, G. (1942) *J. Amer. med. Ass.*, **119**, 331 (Diffuse collagen disease; acute disseminated lupus erythematosus and diffuse scleroderma).
- LYNE, A. J., AND PITKEATHLY, D. A. (1968) *Arch. Ophthalm. (Chicago)*, **80**, 171 (Episcleritis and scleritis. Association with connective tissue disease).
- MANSCHOT, W. A. (1961) *Advanc. Ophthalm.*, **11**, 1 (The eye in collagen diseases).
- MARQUIS, Y., RICHARDSON, J. B., RITCHIE, A. C., AND WIGLE, E. D. (1968) *Amer. J. Med.*, **44**, 939 (Idiopathic medial aortopathy and arteriopathy).
- RODNAN, G. P., BENEDEK, T. G., SHAVER, J. A., AND FENNELL, R. H. (1964) *J. Amer. med. Ass.*, **189**, 889 (Reiter's syndrome and aortic insufficiency).
- SEVEL, D. (1967) *Amer. J. Ophthalm.*, **64**, 1125 (Necrogranulomatous scleritis. Clinical and histologic features).
- SIDDONS, H., AND SOWTON, E. (1967) "Cardiac Pacemakers", p. 7. Thomas, Springfield, Ill.
- SOBIN, L. H., AND HAGSTROM, J. W. C. (1962) *J. Amer. med. Ass.*, **180**, 1 (Cardiac conduction tissue in rheumatoid aortitis).

- STILLERMAN, M. L. (1951) *A.M.A. Arch. Ophthal.*, **45**, 239 (Ocular manifestations of diffuse collagen disease).
- SWAN, K. C. (1951) *Ibid.*, **45**, 630 (Some contemporary concepts of scleral disease).
- VERHOEFF, F. H. (1913) *Ophthalmoscope*, **11**, 2 (Brown's scleritis).
- WEINTRAUB, A. M., AND ZWEIFLER, N. J. (1962) *Arthr. and Rheum.*, **5**, 327 (Rheumatoid heart disease—a clinical as well as pathologic entity).
- WOLTER, J. R., AND LANDIS, C. B. (1958) *Klin. Mbl. Augenheilk.*, **132**, 59 (Clinical aspect and pathology of massive granuloma of the sclera).