

Genetic heterogeneity in osteogenesis imperfecta

D. O. SILLENCE, ALISON SENN, AND D. M. DANKS

From the Department of Paediatrics and Genetics, University of Melbourne; and the Genetics Research Unit, Royal Children's Hospital, Victoria, Australia

SUMMARY An epidemiological and genetical study of osteogenesis imperfecta (OI) in Victoria, Australia confirmed that there are at least four distinct syndromes at present called OI.

The largest group of patients showed autosomal dominant inheritance of osteoporosis leading to fractures and distinctly blue sclerae. A large proportion of adults had presenile deafness or a family history of presenile conductive hearing loss.

A second group, who comprised the majority of newborns with neonatal fractures, all died before or soon after birth. These had characteristic broad, crumpled femora and beaded ribs in skeletal x-rays. Autosomal recessive inheritance was likely for some, if not all, of these cases.

A third group, two thirds of whom had fractures at birth, showed severe progressive deformity of limbs and spine. The density of scleral blueness appeared less than that seen in the first group of patients and approximated that seen in normal children and adults. Moreover, the blueness appeared to decrease with age. All patients in this group were sporadic cases. The mode of inheritance was not resolved by the study, but it is likely that the group is heterogeneous with both dominant and recessive genotypes responsible for the syndrome.

The fourth group of patients showed dominant inheritance of osteoporosis leading to fractures, with variable deformity of long bones, but normal sclerae.

Osteogenesis imperfecta (OI) is a heritable syndrome characterised by one or more of the features of osteoporosis leading to fractures, blue sclerae, impaired hearing, defective dentition, and hyperlaxibility present throughout life (Smars, 1961). There is wide variability in the presence and severity of the features among patients. Some patients have considerable skeletal deformity with normal sclerae, others have little deformity with very blue sclerae, while a small proportion of cases die in the newborn period.

It has been argued that these diverse presentations represent the variable penetrance and expression of a single mutant dominant gene (Caniggia *et al.*, 1958; Smars, 1961), or a closely linked dominant gene complex (Seedorf, 1949). However, pedigrees with autosomal recessive inheritance have been reported, including those by Kaplan and Baldino (1953), Rohwedder (1953), Goldfarb and Ford (1954), Adaita (1957), Awwaad and Reda (1960), Chawla (1964), Maloney (1969), Remigio and Grinvalsky (1970), McKusick (1972), Wilson (1974), Horan and Beighton (1975), and Tsuruta and Sugiura (1977).

In recent years, it has been proposed that there are

several varieties of OI (Cocchi, 1964; Ibsen, 1967; Francis *et al.*, 1975; McKusick, 1975). Biochemical studies on cultured fibroblasts (Penttinen *et al.*, 1975) and skin collagen (Bauze *et al.*, 1975; Francis *et al.*, 1975) from patients with OI support the proposed heterogeneity. Accordingly, a review of osteogenesis imperfecta was undertaken in Victoria, to look for genetic heterogeneity and to clarify the relationship between surviving and lethal cases.

Methods

Victoria, Australia, has a population of 3 746 000 (Census, 1976) and an annual birth rate of approximately 60 000 live births. A large proportion of the population lives in Melbourne and its satellite cities. Country people with rare conditions such as OI are likely to travel to Melbourne at least once in a lifetime for specialist opinion and treatment. Therefore, a case-finding study based upon Melbourne and its satellite population centres would be likely to ascertain the majority of cases in the state.

Most babies are delivered in maternity hospitals, and the majority of babies with congenital defects and children with chronic disorders are referred to two children's hospitals for diagnosis and manage-

ment. The state has a Consultative Committee on Perinatal Mortality, established in 1961, to which all stillbirths and neonatal deaths are reported. Since 1965, the majority of, if not all, babies who died in the perinatal period with OI have been reported to this Committee.

Patients were ascertained from a search of hospital records of 10 Melbourne metropolitan hospitals and the central hospitals of its satellite cities. For newborn lethal cases, the search was concentrated on the years 1965 to 1977. For other cases, patient diagnosis registrations were searched for the years 1955 to 1977. Several hospitals had a disease index established before 1955, but the majority did not. Therefore, ascertainment before 1955 was unreliable. Further cases were ascertained from colleagues in orthopaedic and radiological practice and from the registers of organisations for handicapped children and adults. The cases of perinatal death ascertained due to OI were verified by the Consultative Committee on Perinatal Mortality. A number of patients, mainly adults, were identified solely through relatives previously ascertained and interviewed.

When names of patients were found, permission was sought from their usual doctor to interview them and their parents. No patient ascertained through public hospitals refused interview and examination, though a number of mildly affected individuals ascertained through a more severely affected family member refused interview. Hospital case notes, *x*-rays, and histopathology sections and reports, when available, were reviewed for all patients studied. Non-familial cases of OI were especially sought out and all except one case ascertained were examined. The minimum dominant mutation rate calculations assumed that non-familial cases were highly likely to have been ascertained, since their parents would have sought referral to a specialist centre for opinion and management.

A pedigree was constructed for each family. Information bearing on the symptoms of OI was sought concerning all family members. Affected individuals were examined and data were recorded on a protocol sheet for computer analysis. The range of the data collected is summarised in Table 1. Computer analysis was performed using the Statistical Package for the Social Sciences (Nie *et al.*, 1975).

A scale of blue-grey hue of varying densities, graded from 1 to 6, was constructed by a paint manufacturer. The hue was matched directly to the sclera of one of the patients. It was found to be consistent in hue with the blue sclerae of all patients examined.

Scleral hue and density were assessed in daylight, though not in direct sunlight or shade. An estimate

Table 1 *Data collected on patients with OI*

- | | |
|-----|---|
| (1) | Age of patient, parental age at birth, length and weight at birth, present weight, height, and head circumference. |
| (2) | Age of onset of fractures, number of fractures in varying age periods, total fractures. |
| (3) | Deformity at birth and at present in limbs, skull, and spine. |
| (4) | Degree of handicap, past and present. |
| (5) | Presence and degree of other features of the syndrome of OI: scleral blueness, deafness, laxness of the joints, frequency of sprains and dislocations, dentinogenesis imperfecta. |
| (6) | Radiographic features in skull, ribs, and long bones at various ages. |

of grade was made by recording the density which was most representative of the eyeball. Patients and their sibs, parents, and where possible other relatives, were examined and the results recorded.

Reliable fracture data were obtained for many cases by comparing medical records and radiographic reports. In the patients with fractures at birth, skeletal *x*-rays taken at birth were examined and the number of fractures counted. For the majority of adult patients with large numbers of fractures, no reliable total estimate could be obtained.

Deformity of the skeleton was assessed by inspection and palpation. Scoliosis was assessed with the patient bending forward (Blount, 1969). It was graded as mild, moderate, and severe on clinical grounds. Standing or sitting anterior-posterior *x*-rays were performed where possible on all those with clinical scoliosis. As experience accumulated, it was appreciated that most patients assessed clinically with moderate scoliosis had curves which would be regarded radiographically as severe or progressive if the patients were prepubertal.

Hearing was not formally tested during the interview with patients and parents, but a history of hearing impairment was sought from patients and their relatives. Some patients had had formal audiometric evaluation and the results of testing were obtained for confirmation of hearing status. Other patients had frank hearing impairment. The frequency reported in the study, therefore, underestimates the true frequency of hearing loss in the patients studied. A follow-up audiometric study is being undertaken to assess the hearing status of patients and their parents ascertained in the study.

Birthweights and lengths for the patients examined were obtained. Centiles appropriate to gestation were derived by comparison with intrauterine growth charts (Kitchen, 1968a, b). Height or length and head circumferences were measured in centimetres and weight in kilograms. Centiles were derived from curves prepared by Tanner *et al.* (1966). As satisfactory centile charts do not exist for adults, adult measurements were compared with centiles available for individuals aged 19 years for weight and height, and 15 years for head circumference.

Results

One hundred and fifty-four individuals living in Victoria, and two patients from other states who were regularly receiving treatment in Victoria, were ascertained. Ninety-one were personally examined and a most striking observation was made. A group of patients with generally the most severe progressive deformities had sclerae whose density of blueness approximated normal (discussed as group 3). This was in contrast to a much larger group of patients with usually stationary disease but distinctly blue sclerae (discussed as group 1), whose physical findings are compared with the former group in Fig. 1 and Tables 3, 4, and 5. A further group of patients (two families) in whom the inheritance pattern (dominant), physical findings, and natural history seemed to differ from groups 1 and 3 were separated as group 4.

Twenty-two babies with fractures at birth, who died in the perinatal period or during childhood, were ascertained. It might be thought appropriate to separate these patients who died from all other cases. However, analysis of the radiological changes in these patients suggested that they formed two distinct categories. One group of 8 babies had radiological changes indistinguishable from those patients with progressively deforming disease. Since many of

this latter group had multiple fractures at birth, it seems that these lethal cases might merely represent the most severe end of the spectrum of this syndrome. The remaining 14 lethal cases had in common low

Table 2 Distribution of patients ascertained with OI in Victoria in proposed groups

<i>Dominantly inherited OI with blue sclerae</i>	
Familial cases personally examined	56
Familial cases not examined**	59
Sporadic cases personally examined	11
Sporadic case diagnosed from records	1
<i>Lethal perinatal OI, crumpled femora</i>	
Familial cases, primary ascertainment	4
Familial cases, secondary ascertainment	2
Sporadic cases	10
<i>Progressively deforming OI with normal sclerae</i>	
Sporadic cases personally examined*	20
Familial case, infant death	1
Sporadic cases, infant deaths	7
<i>Dominantly inherited OI with normal sclerae</i>	
Familial cases personally examined	3
Familial cases not examined**	5
Sporadic case personally examined	1

*, includes 2 patients living interstate, but receiving medical treatment in Victoria; **, diagnosed from records, x-rays, and family history.

Table 3 Birth and physical characteristics in 86 patients with OI who survived the newborn period

	<i>Dominantly inherited OI with blue sclerae (n=65)*</i>		<i>Progressively deforming OI with normal sclerae (n=21)**</i>	
	No	Frequency	No	Frequency
<i>Birthweight centiles</i>				
< 10	8	15.7	11	52.4
10-50	18	35.3	5	23.8
50-90	19	37.3	3	14.3
> 90	6	11.8	2	9.5
Unknown	14		0	
<i>Birth length centiles</i>				
< 10	3	8.6	6	40
10-50	15	42.9	6	40
50-90	13	37.1	2	13.3
> 90	4	11.4	1	6.7
Unknown	30		6	
<i>Weight centiles</i>				
< 3	15	23.8	19	90.5
3-50	26	41.3	1	4.8
50-98	20	31.7	0	
> 98	2	3.2	1	4.8
Unknown	2		0	
<i>Stature centiles</i>				
< 3	32	49.2	20	95.2
3-50	27	41.5	1	4.8
> 50	6	9.2	0	
<i>Head circumference</i>				
< 2	0		1	4.8
2-50	16	25	10	47.6
50-98	36	56.3	7	33.3
> 98	12	18.8	3	14.3
Unknown	1		0	
<i>Triangular facial appearance</i>				
	21	32.3	18	85.7

*, 2 patients seen were omitted from the analysis because of inadequate documentation; **, 1 patient who died at 3 months of age was very well documented and the findings are included with 20 patients personally examined.

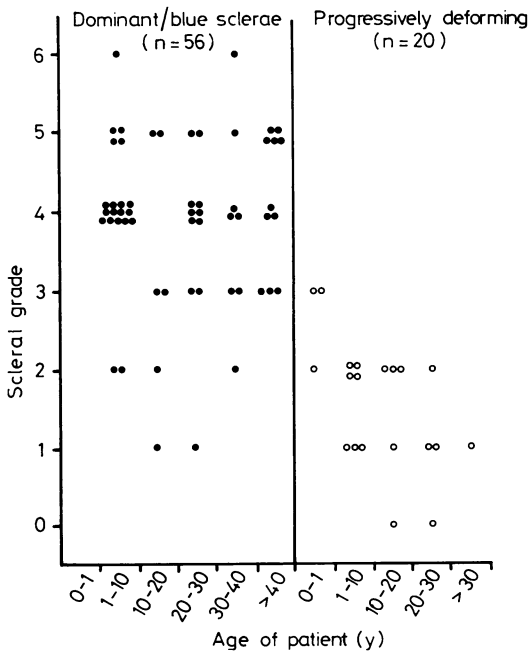


Fig. 1 Distribution of density of scleral blueness with age in patients personally examined.

birthweight, osteoporotic bones, with the radiographic appearance of marked platyspondyly, beaded ribs, and crumpled long bones (accordion-like appearance of the femora). One family had produced 2 other infants with this syndrome ascertained through their affected sib. Thus, there were 16

Table 4 *Skeletal complications in 86 patients with OI who survived the newborn period*

	Dominantly inherited OI with blue sclerae (n=65)*		Progressively deforming OI with normal sclerae (n=21)**	
	No	Frequency	No	Frequency
No fractures	5	7.7	0	0
Age of first fracture				
Birth	5	7.7	14	66.7
First year	15	23.1	6	28.6
Preschool	29	44.6	1	4.8
School	11	16.9	0	
Deformity of				
Upper limbs at birth	0	0	13	61.9
Lower limbs at birth	0	0	14	66.7
Upper limbs	7	10.8	18	85.7
Lower limbs	12	18.5	17	81.0
Kyphosis				
None	52	80	12	57.0
Mild-moderate	12	18.4	8	38.0
Severe	1	1.6	1	5.0
Scoliosis				
None	52	80	7	33.3
Mild-moderate	11	17.0	11	52.4
Severe	2	3.0	3	14.3

*, 2 patients seen were omitted from the analysis because of inadequate documentation; **, 1 patient who died at 3 months of age was very well documented and the findings are included with 20 patients personally examined.

Table 5 *Extraskeletal manifestations of OI in 86 patients who survived the newborn period*

	Dominantly inherited OI with blue sclerae (65)*		Progressively deforming OI with normal sclerae (21)**	
	No	Frequency	No	Frequency
Hyperlaxity				
Unknown	0		1	
Upper limbs	42	64.6	10	50
Lower limbs	24	36.9	8	40
Hearing impairment				
Using hearing aid	14	21.5	0	
Not using aid	5	7.7	1	5.3
Suspected	4	6.2	0	
Dentinogenesis imperfecta	0		11	55
Teeth				
discoloration	22	41.5	10	50***
Abnormal wear	10	18.9	12	60
Bruising	50	78.1	5	26.3
Unknown	1		2	

*, 2 patients seen were omitted from the analysis because of inadequate documentation; **, 1 patient who died at 3 months of age was very well documented and the findings are included with 20 patients personally examined; ***, 1 patient excluded in whom the teeth were not erupted.

babies with lethal perinatal OI (discussed as group 2) for analysis.

Altogether, 180 patients with osteogenesis imperfecta were ascertained and studied (Table 2). Three additional patients with non-familial, infancy-onset osteoporosis, in whom the diagnosis of OI had been entertained, were excluded from the analysis since they had atypical features. One had marked short stature, mental retardation, hypotelorism, blue sclerae, and discoloration of her teeth. Peripheral blood chromosome analysis was normal. Another, a mentally retarded boy, had osteoporosis, ligamentous laxity, normal sclerae, and normal teeth. A third boy, the product of related parents, had idiopathic osteoporosis in early infancy, but the sclerae were normal. Urine amino acid chromatogram was normal. Skeletal x-rays at several years of age showed a marked improvement in bone texture.

GROUP 1. DOMINANTLY INHERITED OI WITH BLUE SCLERAE

One hundred and twenty-seven individuals were believed to have this syndrome of osseous fragility, blue sclerae, and presenile deafness or a family history of presenile deafness. Of 67 cases examined, 56 had a family history of OI. Pedigree analyses in these cases were consistent with autosomal dominant inheritance. In 13 pedigrees, complete information was available on 46 sibships, in which there were 79 with OI and 62 unaffected. The deviation from the expected dominant proportion of 50% affected was not statistically significant. A further 11 cases with negative family history had clinical and radiographic findings identical to those of familial cases. Their disease was believed to have arisen from new dominant mutation. Sixty cases who were not examined personally were assigned to this group on the basis of information obtained from medical records, x-rays when available, and family history.

The patients personally interviewed were generally born at term with a mean gestation of 39 weeks (range 34 to 43 weeks). Clinical findings are summarised in Tables 3, 4, and 5, and Fig. 1. Birthweight and length centiles plotted against gestational age showed a normal distribution.

Five patients had not suffered a fracture (age range from 21 months to 29 years). The majority of patients had their first fracture in the preschool period (Table 4). In 5, the first fracture was present at birth, and in all instances this may have occurred at delivery. No parent had recognised limb deformity (bowing in the newborn baby), though review of the x-rays of 3 babies who had fractures at birth showed mild bowing of the femora. At the time of assessment, less than one-fifth of all affected individuals had clinical deformity of upper or lower limbs.

Deformity of the lower limbs was most common and usually consisted of anterior or lateral bowing of the femora or anterior bowing of the tibiae. Angulation deformities as a result of fracture malunion were present in some older individuals. Kyphosis and scoliosis were seen in approximately one-fifth of the patients. In nearly all cases, clinically recognised scoliosis was not diagnosed until the end of the first decade. Scoliosis was progressive during puberty and several adults had severe curves. In one sibship with 6 affected individuals, 5 sibs (4 females and 1 male) had mild to moderate scoliosis. One sib successfully underwent a Dwyer procedure for stabilisation of her scoliotic curve at 14 years of age. In another sibship, 2 adult females had severe kyphoscoliosis. Their brother did not have clinical kyphoscoliosis and a sister was dead and unavailable for study. The pattern in these 2 families was similar to that seen in adolescent idiopathic scoliosis superimposed on osteogenesis imperfecta.

Although only 7% of affected individuals were less than the 10th centile in length at the time of birth, by adult life almost 50% were less than the 3rd centile in height. Though lower limb and spinal deformity contributed to some extent to adult short stature, deformity alone did not account for their postnatal growth failure. Adults complained of progressive loss of stature in adult life. This was presumably the result of progressive platyspondyly and kyphosis secondary to spinal osteoporosis. Head circumferences were usually large for age and 18% of individuals had head circumferences greater than the 98th centile. This feature was clinically striking when seen against their generally reduced height. The triangular facial appearance commonly associated with textbook descriptions of OI patients was seen in 30% of cases. Temporal bossing and a large head contributed to this appearance.

A remarkable finding was that 75% of patients claimed that they or affected children bruised easily. Many would display bruises at the time of interview and relate them to trivial trauma.

Hearing impairment was a common finding. Of the adults, 40% had severe hearing impairment requiring hearing aid or surgery for otosclerosis. Overall, 35% of patients had proven or suspected hearing impairment. The observation of hearing loss was usually noticed first in the third decade, but in 20% of those with severe hearing impairment, it was evident before 20 years of age. The earliest onset of appreciable hearing defect requiring audiometric assessment and a hearing aid was in a patient 10 years of age.

Virtually all patients were walking independently. Only 3 patients (2 children and 1 adult) were using a wheelchair at the time of the study. The adult was able to walk with crutches and used the wheelchair

for convenience. A further 7 patients had a gait disturbance or limited mobility because of recent or past injury to legs. No patient at any age was permanently in hospital or bedridden. No individual had arm or hand deformity limiting their ability to feed and clothe themselves. On the whole, families made light of their personal suffering and handicaps, but were concerned for their children's future. Where deafness occurred in families, this was thought to be by far the greatest handicap.

Frequency

Based on the 1976 census population, the minimum frequency in Victoria was estimated to be 127/3 746 000, that is, 3.4/100 000 population. Between 1955 and 1974, inclusive, there were 1 313 101 live births registered and 46 children were born with this syndrome. The minimum incidence was thus 3.5/100 000 or 1/28 500 live births.

Dominant mutation rate

This was calculated directly for the years 1955 to 1974. Based on 10 individuals examined, in whom examination of the parents reasonably excluded familial OI, the minimum new dominant mutation rate was 0.26×10^{-5} . Two other individuals born in the same period, one of whom was adopted and the other not available for examination, are likely to represent sporadic cases of this syndrome and represent new dominant mutation. Therefore, an upper limit for the direct estimate would be 0.3×10^{-5} . The minimum new dominant mutation was between 0.26 and 0.3×10^{-5} .

The mean paternal age at the birth of the 10 sporadic cases was 31.70 years (SD 8.11 years) with a range from 20 to 42 years. This can be compared with the mean age of fathers in Victoria in 1970 of 29.59 years (SD 6.2).

GROUP 2. LETHAL PERINATAL OI WITH RADIOGRAPHICALLY CRUMPLED FEMORA AND BEADED RIBS

Fourteen babies from 12 families, who were born and died in Victorian hospitals between 1965 and 1977, were ascertained. One family had 2 other infants, one born in 1964 and the other born in another state. Neither case was, therefore, primarily ascertained. Ascertainment of patients through hospital medical charts and the Consultative Committee on Perinatal Mortality was unreliable for cases before 1965 for a number of reasons: the inclusion of OI cases in other diagnostic categories was common, diagnostic registers were not as well kept, and referral of newborns with congenital abnormalities for necropsy examination and consideration by the Consultative Committee gradually increased in efficiency between 1961 and 1965.

Review of these 16 cases showed that they had many features in common. In 19 instances they were born prematurely and 5 were stillborn. The majority had low birthweight and all had low birth crown-wheel length. All showed shortening and bowing of upper and lower limbs. In 7 of 8 cases where the scleral findings were recorded, the sclerae were noted to be blue. In 2 cases examined personally, the sclerae had a deep blue-black hue. Female offspring (12) were in excess of male offspring (4). Of the 16, 14 had a necropsy and skeletal tissue was preserved for histopathological examination.

Skeletal x-rays showed crumpled (concertina-like or accordion-like) femora (Fig. 2), marked angulation of tibiae and sometimes the femora, fractures and deformity of the shafts of bones of the upper limbs, platyspondyly, and a beaded appearance of the ribs (Fig. 3). The skull showed uniformly poor ossification of the vault and base with thin discontinuous plaques of calcification in the vault.

Frequency

Between 1965 and 1975, there were 749 851 live births recorded in Victoria. There were 12 infants with this syndrome born in this period so that the minimum frequency was 12/749 851, 1/62 487, or an incidence of 1.6/100 000 live births.

Pedigree analysis

Twelve families produced 16 affected sibs. In each of 2 families there were 3 affected sibs with normal parents (Fig. 4 and 5). In one of these, the parents were first cousins and had produced 3 stillborn OI offspring and 3 normal offspring (Fig. 5). The remaining 10 cases were sporadic.

In the segregation analysis, 3 hypotheses were considered: that these cases had arisen by autosomal dominant inheritance, autosomal dominant new mutation, or autosomal recessive inheritance. None of the parents of affected infants showed osseous

fragility, blue sclerae, or deafness. This was good evidence that there was not a dominant gene inherited by the probands with reduced penetrance in the parent. However, in 4 pedigrees, there was an individual in a previous generation with a hearing

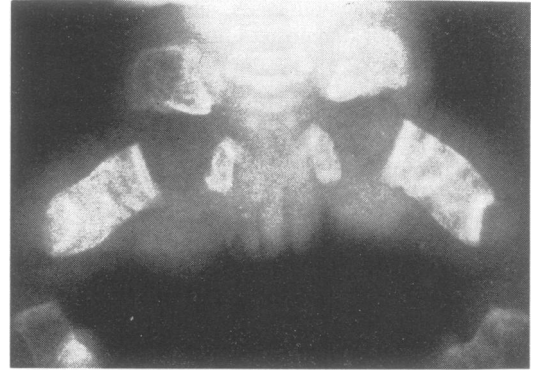


Fig. 2 Lethal perinatal OI. X-ray of lower limbs showing a crumpled accordion-like appearance of the femora.

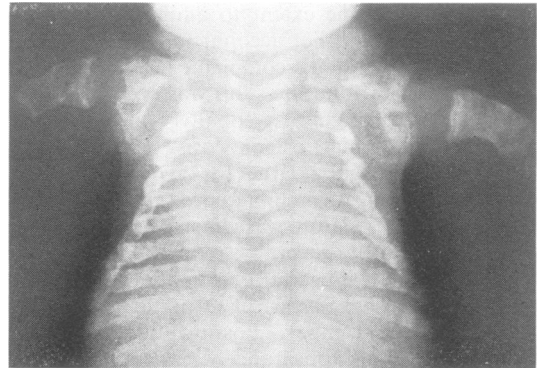


Fig. 3 Lethal perinatal OI. X-ray of the chest showing beaded or 'rosary' appearance.

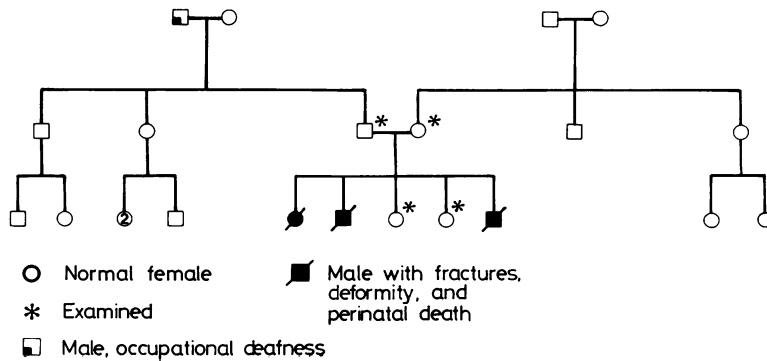


Fig. 4 Lethal perinatal OI. Pedigree showing autosomal recessive inheritance.

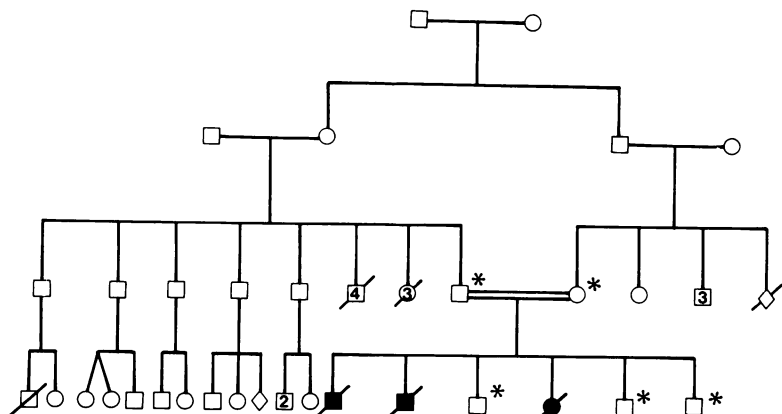


Fig. 5 Lethal perinatal OI. Pedigree showing autosomal recessive inheritance.

deficit with onset in the fifth decade or later. In one pedigree, the maternal great-grandmother of the proband was reported to have had hearing impairment in the third decade. A possible explanation of these instances of senile and presenile deafness is that they may be associated with the heterozygous state for lethal perinatal OI genes.

If a new dominant mutation were assumed, then it would be difficult to correlate the 2 families, each with 3 affected offspring. It is the authors' opinion that these familial cases are identical clinically and radiologically to the 10 sporadic cases. Furthermore, one might expect an association with increased paternal age at the birth of these babies, as can be observed for sporadic cases manifesting disorders resulting from autosomal dominant mutation. This clearly was not the case since the mean paternal age was 28.63 (SD 4.96) years, compared with the mean paternal age for Victoria for the year 1970 of 29.59 (SD 6.20).

As we did not have complete ascertainment in pedigrees, the proband method (Danks *et al.*, 1965; Emery, 1976) was employed for segregation analysis of the pedigrees assuming the recessive hypothesis. The proportion of index cases who were affected was derived by excluding the proband from analysis and deriving the segregation ratio from the remaining members of the pedigree. The numbers of affected and unaffected in each sibship are presented in Table 6. The segregation ratio was $P = 0.22$ (SD 0.07). This estimate is consistent with the recessive hypothesis.

GROUP 3. PROGRESSIVELY DEFORMING OI WITH NORMAL SCLERAE

Of this group of 21 patients, 14 were children and one died in the newborn period but was well documented. All had pale grey-blue or white, that is normal, sclerae. Their bones were both twisted and bowed

as well as fragile. Deformity progressed with age and all adults had severe spinal deformity. Scleral hue appeared less dense the older the patient (Fig. 1). Values between 0 and 2 for scleral hue were encountered in some normal children and adults. The relatively normal sclerae seen in these patients with severe deformity of the skeleton in striking contrast to the findings in group 1 patients.

The majority of individuals were born at term. The mean gestation was 39 weeks and ranged from 37 to 42 weeks. Clinical data are summarised in Tables 2, 3, and 4. Birthweights were usually appropriate for gestation. Birth length also was usually in the normal range, though those babies with marked deformity and fractures were not measured. However, with increasing age, longitudinal growth deviated further below the normal centiles, so that all adults were profoundly dwarfed.

Two babies personally examined had wide anterior and posterior fontanelles, wide cranial sutures, and multiple Wormian bones, palpable particularly in the posterior part of the skull. The triangular facial appearance and temporal and occipital bossing gave

Table 6 Proband method for segregation analyses

Pedigree no	No of probands (i)	No of sibs of probands affected (r-1)	Total (s-1)
50	1	2	4
51	1	0	2
52	3	2*	5*
53	1	0	1
54	1	0	1
55	1	0	2
57	1	0	4
58	1	0	1
59	1	0	0
60	1	0	5
61	1	0	2
62	1	0	0
	$\Sigma i(r-1)$	8	$\Sigma i(s-1)$ 37

* counted three times. r = total number of affected in each sibship, s = total number of affected plus unaffected in each sibship.

these patients a markedly similar facies. Head sizes seemed disproportionately large when judged against their severe short stature and slender build.

Fractures with deformity of the limbs were recognised at birth in 14 of 21 patients. The other 7 patients had all had fractures by 15 months of age. The majority had had multiple fractures involving long bones and ribs. There appeared to be a marked reduction in the frequency of fractures beginning between 5 and 10 years of age. Skeletal deformities, however, progressed during puberty. Severe kyphoscoliosis and chest deformity were seen in 5 of 6 adult patients. One patient, a male with severe deformity of the upper limbs, had no clinical or radiological abnormality of the spine.

Marked ligamentous laxity, particularly in the metacarpophalangeal joints and interphalangeal joints, was noted in 50% of patients, all children. Ligamentous laxity was less marked in adult patients. The teeth showed transparent dentinogenesis imperfecta in 45% of the patients. In several who had received large doses of fluoride, incisor teeth were white without evidence of translucency and yet they showed the wear and discoloration in molar teeth consistent with dentinogenesis imperfecta (Bixler, 1976).

Easy bruising was related by only 5 of 19 (26.3%), in contrast with 75% of patients in group 1. Of the 6 patients over 14 years of age, hearing defect was detected in only 1. This 30-year-old woman had moderately severe progressive hearing loss in the third decade, and required a hearing aid for normal conversation.

Of the 17 patients who were over 2 years of age when studied, 15 (88%) were markedly handicapped and had considerable difficulty with walking. A wheelchair was required by 12, and 3 used a walking frame for stability. Of 6 adults, 2 had independent mobility. One drove a car and used crutches and wheelchair occasionally, and the other used a walking frame largely to protect herself against body contact accidents and falling. Straightening of limbs with intramedullary rodding had been performed in 65% of patients. Two adults had not had any corrective surgery for deformity. One was severely handicapped with difficulty in dressing and in moving about in bed; the other was an independent walker but used a walking frame.

Radiology

Neonatal *x*-rays were available for 13 of 21 patients. In all cases, *x*-rays were obtained because of fractures or deformity at birth. The mean number of fractures at birth was 8, with a range from 0 to 80. Femora and ribs were the bones most commonly fractured. The femora varied in appearance; some were normal in

appearance, others were short and broad. A few patients had angulation of the femora but most showed marked angulation of the tibiae. Some patients showed multiple fractures of the ribs, but in no patient was there continuous beading.

Serial *x*-rays were available on 19 of 21 patients. Patients with initially short, broad femora showed this marked thickening of the shafts of the femora only in the first few years. After 10 years of age, there was progressive narrowing of the shafts of long bones, so that in all older patients in this group the femora appeared characteristically thin.

The metaphyseal zone of the lower femur and upper tibia showed progressive radiological abnormality. The first changes, increasing density and irregularity in the metaphyseal zone, were seen in patients aged 3 to 5 years. This density increased in amount during the first decade, so that by 10 years of age the metaphyseal and epiphyseal zones were replaced by whorls of radiodensity. These changes continued to progress through puberty. *X*-rays of the knees of one 25-year-old patient showed replacement of the radiodense appearance at the expanded ends of the long bone with large radiolucent areas. This produced a cystic appearance of the ends of the long bones. The skull *x*-rays at all ages showed multiple Wormian bones.

Deaths

Between 1955 and 1975, 8 babies were born with fractures and deformity of upper and lower limbs, with clinical and radiographic findings similar to those of the patients in this group. One infant on whom the clinical and radiographic findings were very thoroughly documented has been discussed with the previous 21 patients. In one case, the *x*-rays were unusual in that punctate epiphyseal calcification was also present in limbs and spine. These infants died from cardiac or pulmonary failure, 2 at birth, 5 during infancy, and 1 at 8 years, 7 months.

Frequency

There were 18 cases living in Victoria in 1976, when the census population was 3 746 000. Therefore, the minimum prevalence of this syndrome was 18/3 746 000, that is, 0.48/100 000 or 1/208 000 persons. Between 1955 and 1976 inclusive, there was a total of 1 444 716 live births registered in Victoria. During this 22-year period there were 21 affected newborns, 13 of whom survived and 8 of whom died. Therefore, the minimum incidence was 21/1 444 716, that is, 1.45/100 000 live births or 1 case in 68 800 live births.

Pedigree analysis

All patients in this group were sporadic cases. In 2

families the parents were related. In one family, 2 brothers had married 2 sisters who were their first cousins (Fig. 6). Each couple produced an infant with multiple neonatal fractures and limb deformity at birth. In the other family, a marriage between first cousins had produced 2 children. The second child had his first fracture at 5 months. Radiographic findings were consistent with OI and were similar to some other patients in this group. The sclerae were not particularly blue.

Complete pedigree data were available for 24 families. In 11 families, a parent or other relative had significant hearing impairment. This was of presenile onset and in several instances was related to occupational sound trauma. None of these deaf individuals had had fractures, deformity, or blue sclerae. In one family, both the father and maternal grandfather had presenile deafness.

The mean age for the 21 fathers was 32.00 (SD 7.54) years, range 23 to 50 years, compared to the mean father's age in Victoria for the year 1970 of 29.59 (SD 6.20) years.

GROUP 4. DOMINANTLY INHERITED OI WITH NORMAL SCLERAE

Two families were ascertained in which 8 individuals had osteoporosis, with or without a history of fractures, with variable skeletal deformity but without blue sclerae. In both families there were affected individuals in 2 generations, and the pedigrees were consistent with autosomal dominant inheritance. There was no hearing impairment in patients or in family members. In one pedigree, the proband had opalescent dentin. Her father was not examined by the authors, but by report had osseous fragility and discoloration of the teeth. In the other family, the teeth of 2 individuals showed yellow-brown discoloration, abnormal wear, and vertical cracks in the enamel, but did not show the transparency of typical hereditary opalescent dentin.

One woman with normal sclerae, osteoporosis, and a history of fractures, congenital dislocation of the hips, and triangular facial appearance did not have a family history of osteogenesis imperfecta. It was not possible to examine her parents and confirm that they did not have manifestations of OI.

Discussion

The existence of more than one genetic variety of OI is well accepted (McKusick, 1975). On the other hand, the hypothesis that all extremes of the syndrome most probably represent different degrees of expression of a dominantly inherited single gene defect (Caniggia *et al.*, 1958; Smars, 1961) is no longer tenable. The present study suggests that there are at least four syndromes currently described as 'osteogenesis imperfecta'. In some previous studies of OI, the patients described can be separated into these four types. Moreover, many of the eponyms for OI can be related to specific syndromes when applied in the sense originally employed by their authors. These will be discussed below.

The typical scleral hue in the majority of patients was grey-blue. It was, therefore, surprising that some adult patients with marked deformity of long bones had sclerae of normal colour. Serial x-rays and case notes were available on some of these adult patients. A number of children, all sporadic, with identical clinical and radiological findings to these adult cases, also had sclerae which were only slightly blue and relatively normal for their age.

Two babies personally examined in the Victorian study, with fractures at birth, micromelia, crumpled bones, and beaded ribs, had particularly blue sclerae. These varying observations can be explained because different pathogenetic mechanisms exist in the production of blue sclerae. It is generally agreed that the blueness of the sclerae results from its increased translucency. Diffraction, that is, light scattering

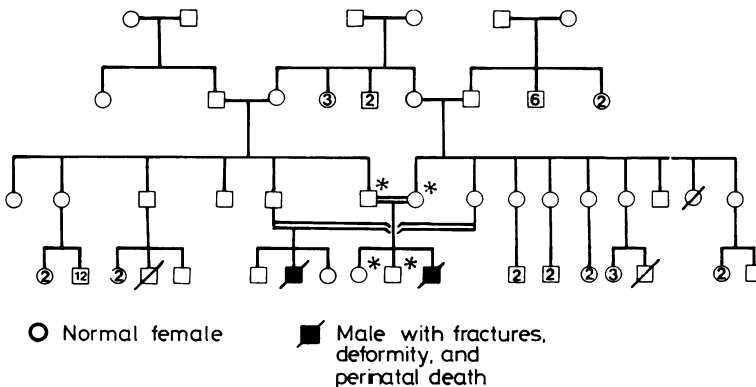


Fig. 6 Progressively deforming OI (newborn cases). Pedigree showing autosomal recessive inheritance.

through an abnormal arrangement of molecules in the sclerae, probably also contributes, just as the blueness of the sky results from diffraction of light in the earth's outer atmosphere. The blueness might be due to thin sclerae, and evidence exists that in newborn lethal cases (Follis, 1952; Haebara *et al.*, 1969; Bluemcke *et al.*, 1972), and non-lethal congenital cases (Buchanan, 1903; Casanovas, 1934), the sclerae were abnormally thin. On the other hand, in patients with dominantly inherited OI with blue sclerae, the sclerae were reported to be of normal thickness (Eichholtz, 1971; Eichholtz and Mueller, 1972), but there was an abnormal arrangement of the collagen molecular framework in the scleral lamellae accounting for the increased translucency.

GROUP 1. DOMINANTLY INHERITED OI WITH BLUE SCLERAE

This is also known as Eddowes's syndrome (Eddowes, 1900), Van der Hoeve's syndrome (Van der Hoeve and de Kleyn, 1918), and Trias Fragilitas Ossium (Cocchi, 1964). Most cases of OI tarda levis (Seedorf, 1949), OI tarda type II (Falvo *et al.*, 1974), and OI with mild long bone disease (Francis *et al.*, 1975) also appear to have this variety of OI. The first report was probably that of Axmann (1831) who described blue sclerae, osseous fragility, and a tendency to dislocations in himself and his 2 brothers. In contrast, in the family reported by Ekman (1788), blue sclerae and deafness were not mentioned, though osseous fragility with severe deformity was reported in 3 generations. It is possible that this latter family had one of the syndromes associated with normal sclerae. Spurway (1896) stressed the occurrence of blue sclerae in patients with bone fragility, and Van der Hoeve and de Kleyn (1918) emphasised the association with presenile deafness. Bell (1928) thoroughly documented the dominant pattern of inheritance of blue sclerae and osseous fragility. Furthermore, she stressed that otosclerotic deafness was a common association. The studies of Seedorf (1949), Komai *et al.* (1956), Caniggia *et al.* (1958), Smars (1961), and Schröder (1964) have confirmed the dominant inheritance seen in this syndrome. Bauze *et al.* (1975) showed that a group of patients with mild disease, blue sclerae, and dominant family history of OI had a decreased amount of collagen extractable from the skin by *in vitro* chemical procedures. This polymeric (aggregated or highly cross-linked) collagen (Francis *et al.*, 1973) reacted like normal collagen in its stability to depolymerising agents such as pronase and cold alkali. This was in contrast to their findings in a group of sporadic cases with normal sclerae and severe deformity of long bones, in whom there was a normal amount of polymeric collagen extractable from the skin, but in whom the extracted collagen

showed marked instability when treated with depolymerising agents.

In the Victorian study and the study by Caniggia *et al.* (1958) of 3 large Italian pedigrees, a number of affected individuals, who on genetic grounds should have carried the OI gene, had sclerae of normal colour. These patients did not have a significant fracture history or severe deformity. The experience from these cases suggests that a markedly reduced expression of blueness of the sclerae may be correlated with absence or marked reduction of the fracture tendency in patients with this type of fracture tendency in patients with this type of osteogenesis imperfecta. The significance of presenile arcus corneae, seen in many adult patients, is unknown. A similar observation was made by Smars (1961).

Hearing impairment is a major burden and is considered by many patients to be their major problem. In the Victorian series, 35% of patients overall had hearing impairment. Among adults, 40% had severe hearing impairment necessitating a hearing aid, and many had had one or more ossicular chain reconstruction operations to improve their hearing. These findings are comparable to those of Bell (1928), who found 60% of patients overall in reported dominant pedigrees, and Smars (1961), who found 50% of adult cases in Sweden between 40 and 50 years of age, had hearing impairment. Hearing impairment can also be a significant problem before 20 years of age, since one-fifth of our patients had severe hearing loss before the end of the second decade. The earliest age of onset was 10 years.

Although scoliosis was a common finding, severe curves were rarely seen. In one case, surgical intervention may have arrested the progression of the deformity during puberty. Aggressive medical and surgical management of scoliosis in this syndrome offers the promise that it will reduce the morbidity from spinal deformity in future generations.

Similarly, severe long bone deformity was seen infrequently. Much of that seen in adults could have been largely preventable with currently available orthopaedic techniques for fracture reduction and fixation and for correction of fixed deformity by multiple osteotomies and intramedullary rodding (Williams, 1965).

Classical dentinogenesis imperfecta was not observed in our patients; however, some discoloration, wearing, and chipping of teeth was commonly found. Levin *et al.* (1978) have observed that when a clinical and radiological assessment of the teeth is made, dominant pedigrees of OI tarda fall into 2 groups: those families which have hereditary opalescent dentin, and those which do not. On this basis they have proposed a classification of families into 2 types. Our failure to observe dentino-

genesis imperfecta in our dominant pedigrees with blue sclerae may reflect the fact that the families closely examined fell into the group of those who do not have dental abnormalities. Alternatively, it may reflect the fact that clinical assessment may miss those patients with obliterated pulp cavities and abnormally constricted coronal-radicular junctions, in whom dentinogenesis imperfecta can be diagnosed radiographically (Bixler, 1976).

The estimate of the minimum frequency of this syndrome in Victoria, 3.4 per 100 000 persons, is substantially in agreement with that for Japan of 2.35 per 100 000 (Komai *et al.*, 1956). For all cases (including those with blue sclerae and sporadic cases with normal sclerae), Smars (1961) estimated a frequency of 3 to 4 per 100 000 in Sweden, and in Munster, Germany, Schröder (1964) estimated that the frequency was 4.7 per 100 000.

The direct estimate of the dominant mutation rate of 0.3×10^{-5} for the Victorian population is lower than the estimates of Smars (1961) of 0.7×10^{-5} . However, these latter studies included sporadic cases of OI, some with normal and others with blue sclerae. Our estimate, on the other hand, is closer to the calculated rate for Van der Hoeve's syndrome in Japan of 0.14×10^{-5} (Komai *et al.*, 1956).

GROUP 2. LETHAL PERINATAL OI WITH RADIOGRAPHICALLY CRUMPLED FEMORA AND BEADED RIBS

These patients have generally been designated OI congenita or OI letalis Vrolik (Cocchi, 1964). Seedorf (1949) observed that the credit for the radiological description of the femoral appearances should go to Winkler (1871), who described a newborn with 'rachitis foetalis annularis'. However, though the clinical description agrees with OI to some extent, the illustrations which accompany the report suggest some other variety of short-limbed, campomelic dwarfism. Seedorf (1949) clearly recognised the lethal perinatal type of OI, as can be seen from his description of lethal congenital cases in which the ribs had a 'rosary' appearance and the long bones 'seem to have been pressed together axially, like harmonica bellows'. Examination of the photographic plate from Vrolik's text, 'Tabulae ad illustrandum embryogenesis in hominis et mammalium, tam naturalem quam abnormem', reproduced in Bell's (1928) monograph (Plate E), shows that Vrolik's patient did not have this syndrome, but rather the skeletal findings identical to those of patients with progressively deforming OI with congenital presentation.

It is proposed that in the lethal perinatal type, the radiographic changes (Fig. 2 and 3) reflect not just the severity, but are also unique to these patients.

These distinctive radiographic findings were common to all patients in this group. There were slight differences in the x-ray (Danks, 1975; Fig. 4) of a baby from the pedigree with consanguineous parents and 3 affected sibs (Fig. 5), the bones appearing thinner than other cases. However, allowing for the prematurity and macerated state of the fetus, the appearance was very similar to those of other babies in the group.

Crumpled femora, beaded ribs, and marked platyspondyly were not observed in x-rays of 3 babies with neonatal fractures, the offspring of parents with dominantly inherited OI associated with blue sclerae (group 1). Nor were these appearances noted in the newborn x-rays of individuals with progressive deformity and normal sclerae (group 3). Though cases of dominant inheritance of OI with congenital presentation have been reported (Suen *et al.*, 1974), the radiographic features were quite different.

Pedigrees showing affected sibs with normal parents, consistent with autosomal recessive inheritance, have been reported by Remigio and Grinvalsky (1970), Wilson (1974), and Tsuruta and Sugiura (1977). Parental consanguinity, resulting in the birth of one or more affected individuals, has also been observed by Tsuruta and Sugiura (1977). Taken together with the families ascertained in the Victorian study, this is strong evidence that the usual mode of inheritance for these cases is autosomal recessive. The mean paternal age for our cases of 28.63 (SD 4.96) years does not support the hypothesis that these cases arose from new dominant mutation. However, a series of cases studied in Britain contains far fewer instances of affected sibs than the present study (R. Wynne-Davies, 1978, personal communication). We must, therefore, allow the possibility that this group is also genetically heterogeneous.

There are 2 reports which either may challenge the invariable newborn lethality of the syndrome, or may point to allelic forms of the disorder which are not immediately fatal. Chawla (1964) reported 4 sibs with fractures at birth and normal parents. One infant survived to 3 years of age. Here again, it is difficult to be certain whether these infants had crumpled femora and beaded ribs. On the other hand, the radiological features are consistent in the sibs reported by McKusick (1972; Fig. 8-18) where one of them survived until 10 months of age.

The frequency of the syndrome was 1 in 62 000 live births and accounts for approximately 1 baby born in Victoria each year. Comparable estimates could not be found in previously published reports. Freda *et al.* (1961) suggested a frequency of 1 in 20 000 live births for OI where babies have fractures

at birth. Their estimate included babies with several varieties of OI. Only 2 cases in their series of 16 were lethal in the perinatal period.

The biochemical findings of a disproportionately small ratio of type I to type III collagen, produced by cultured fibroblasts (Penttinen *et al.*, 1975) from a stillborn baby with OI, reported from Baltimore (Heller *et al.*, 1975), refer to this variety of OI. This observation has been substantiated by the finding of an abnormally decreased proportion of type I to type III collagen in the skin of 2 lethal congenital cases of OI (Francis and Smith, 1975). However, the clinical and radiological features of these latter babies were not reported, so the possibility that they may have had one of the other OI syndromes with congenital presentation cannot be ruled out with certainty. The clinical and radiological features of the Baltimore case (Heller *et al.*, 1975) were identical to those of the babies in our experience (R. H. Heller, 1978, personal communication). In one baby in the Victorian series, there was decapitation during delivery just as in the Baltimore case. This is not surprising when one considers the gross deficiency in the skin collagen seen in babies with this syndrome (Follis, 1953, case 2).

GROUP 3. PROGRESSIVELY DEFORMING OI WITH NORMAL SCLERAE

These patients have been variously described as having OI congenita (Looser, 1906), OI tarda gravis (Seedorf, 1949), OI tarda type I (Falvo *et al.*, 1974), severe deforming OI (Bauze *et al.*, 1975), Vrolik's disease, OI congenita type Vrolik, periosteal dysplasia of Porak and Durante (Kaplan and Baldino, 1953), and osteopsathyrosis of Lobstein and Ekman-Lobstein disease. Several previous studies have drawn attention to the possible significance of patients with normal sclerae (Cocchi, 1964; Ibsen, 1967; King and Bobechko, 1971; Bauze *et al.*, 1975).

The most striking feature of this group of patients with normal sclerae is that they all have had progressive deformities of the limbs during childhood and of the spine during late childhood or adolescence. The spinal curvature seen in adult patients was generally of a marked degree. Dentinogenesis imperfecta was a frequent finding and was particularly noted in the primary dentition. On the other hand, hearing impairment occurred infrequently. Dwarfing among this group of patients was unusually severe, and scoliosis and limb deformity contributed to the decreased stature. Moreover, it appears that the progressive cystic metaphysial and epiphysial dysplasia seen in many of these patients also contributed to their short stature.

Neonatal x-rays showed some cases with 'thin' long bones (Fairbank, 1951), while others had a

'thick' bone appearance (Fairbank, 1951). No patient had broad, crumpled bones identical to those seen in patients from group 2. Furthermore, cases in group 3 with a 'thick' bone appearance at birth, showed progressive narrowing of the shafts of the long bones, so that by the time of puberty the width of the diaphysis was indistinguishable from other cases with 'thin' bones at birth. We conclude that the descriptions 'thick' bone and 'thin' bone OI have limited usefulness from the point of view of genetic classification.

Two newborn cases were observed during the period of the present study. Their sclerae appeared blue at birth, and at 3 months of age it was difficult to distinguish these cases from some patients with dominantly inherited OI and blue sclerae (group 1). By 12 months of age, there seemed to be a distinct fading of the blueness. Some adults had a faint blueness of the sclerae, but compared to group 1 patients and a large number of normal adults examined during the study, the sclerae appeared relatively normal. We propose, therefore, that these be called 'normal sclerae' rather than 'white sclerae', the term which has been used by other authors (Bauze *et al.*, 1975).

Although all cases in the Victorian study were sporadic, the evidence suggests that some had autosomal recessive inheritance. There were 2 families in which the parents were consanguineous, and in one there were affected individuals born into separate sibships (Fig. 6). There are a large number of reports of patients with OI with features similar to those in this group, all of which point towards autosomal recessive inheritance. These include those of Hein (1928), Kaplan and Baldino (1953), Rohwedder (1953), Goldfarb and Ford (1954), Adaita (1957), Lièvre (1959, Obs. 23), Awwaad and Reda (1960), Smars (1961, sibships 94 and 96), Zeitoun *et al.* (1963), Maloney (1969), Horan and Beighton (1975), and Tsuruta and Sugiura (1977). Parental consanguinity was present in pedigrees reported by Hein (1928), Kaplan and Baldino (1953), Rohwedder (1953), Lièvre (1959), Zeitoun *et al.* (1963), Maloney (1969), and Tsuruta and Sugiura (1977). The clinical features in these reported patients varied. There were some with fractures and deformity at birth with lethal outcome, whereas others had onset of fractures at birth or infancy and later developed marked deformity. The sclerae were commonly reported to be of normal hue in those affected.

It had generally been believed that sporadic cases with this syndrome represented new dominant mutations. The data presented here do not exclude this possibility for some cases. In fact, the family reported by Holcomb (1931) included several individuals whose skeletal deformity was of a

similar degree to that observed among patients in the present study. Holcomb's observation that one of the most severely affected individuals had relatively normal upper limbs is interesting, in that this feature was noted in 4 adults in the present study, who had had fractures but had no deformity of the upper limbs, in contrast to the marked deformity in the main weight-bearing bones of their skeleton, their spine and lower limbs. The remainder of the patients had progressive deformity of upper limbs, as well as spine and lower limbs, and these were the most severely dwarfed, and also had dentinogenesis imperfecta. It is very likely, then, that group 3 is genetically heterogeneous and that it includes cases with both dominantly and recessively inherited progressively deforming OI with normal sclerae.

In Victoria, Australia, this syndrome of osteogenesis imperfecta with progressive deformity and normalisation of scleral hue with age was approximately one-eighth as common as dominantly inherited OI with blue sclerae. However, these patients were disproportionately represented in excess in the experience of hospital orthopaedic units. A report attempting to quantify the frequency of this syndrome in the population could not be found. The estimated incidence in our study was relatively high, 1.45 per 100 000 live births, compared to the frequency in the community of 0.45 per 100 000 population. This must surely be because of the high mortality both in infancy and childhood and in the fourth decade (through cardiopulmonary complications).

The clinical and biochemical studies of Bauze *et al.* (1975) and Francis *et al.* (1975) support the existence of a separate syndrome or syndromes of OI, in which patients have normal sclerae and severe deformity. Those patients studied by them had polymeric skin collagen which was abnormally unstable in depolymerising agents. It seems likely that this reflects a defect in collagen cross-linking (Francis *et al.*, 1973). Such a defect could explain many of the clinical signs in these patients, such as the bone fragility and joint hyperlaxability.

GROUP 4. DOMINANTLY INHERITED OI WITH NORMAL SCLERAE

This syndrome probably includes some cases previously described as Ekman-Lobstein disease or osteospathyrosis idiopathica of Lobstein. Only 2 families were identified in the Victorian study. The family reported by Holcomb (1931) with osseous fragility but normal sclerae included affected individuals in 5 generations. In the third generation of the family, a woman aged 55 years had no recorded fractures, but was small and badly deformed. Further-

more, a skipped generation was recorded in this pedigree.

The family reported by Omenn *et al.* (1977, Case 3, page 226) documented 9 affected individuals in 4 generations with OI associated with normal hearing and white sclerae. An infant was born to an 18-year-old affected mother following intrauterine diagnosis of OI at 37 weeks' gestation. The infant suffered his first fracture at 7 days of age and had a total of 4 spontaneous fractures in the first 3 years of life.

In an extensive account of the family reported by Ekman (Seedorf, 1949), there is no mention of blue sclerae or deafness. Furthermore, Lobstein (1835) in his description of idiopathic osteospathyrosis did not stress an association between bone fragility and blue sclerae or deafness. Cocchi (1964), in fact, considers that Ekman-Lobstein disease is a distinct syndrome characterised by a liability to fractures without other symptoms.

Lièvre (1959, Obs. 25) reported osseous fragility with normal sclerae in 3 generations of a French family. Other families with normal sclerae and bone fragility, both with or without progressive deformity of long bones and spine, have been observed in North America (Levin and Thompson, 1975; J. Hall, 1978, personal communication). It is likely that this syndrome is more common than the few published reports would lead us to believe.

It could be argued that these individuals have a genetic defect identical to that of cases with blue sclerae, bone fragility, and presenile deafness. If so, the absence of blue sclerae could be explained by failure of penetrance of that feature. However, the presence of individuals with bone fragility in several generations without blue sclerae is the strongest argument against this supposition. Furthermore, our current concept of this group of connective tissue disorders is that the manifestations result from a wide-spread connective tissue defect, and one would expect that individuals with the most severe bone disease would have the most markedly blue sclerae. However, in those families with dominant inheritance of bone fragility and normal sclerae there does not appear to be an increase in blueness of the sclerae with increasing severity.

Why presenile deafness has not been a reported feature is not clear. It most likely reflects our limited experience with description of these patients as a separate syndrome. On the other hand, it may indicate that the pathological process in the middle ear does not involve an overabundant callus formation with ossicular chain fixation, as occurs in group 1 patients. Experience suggests that dentinogenesis imperfecta, on the other hand, is a feature of most or all group 4 patients, but only of some pedigrees of group 1 patients.

The reported experience of patients with dominantly inherited OI but normal sclerae is very limited. The full heterogeneity will need to be determined by further studies.

Conclusion

During the 190 years since Ekman (1788) described a family with hereditary bone fragility and probably normal sclerae, the observation has been made by a number of authors that genetic heterogeneity accounts for much of the extreme variability in the presentations of osteogenesis imperfecta. The present study has confirmed that such is the case.

Our observations confirm that the designations 'thick' and 'thin' bone types do not clearly separate patients with osteogenesis imperfecta into genetic categories. The terms congenita and tarda are also descriptive and do not distinguish the 4 groups of patients we have observed.

An alternative descriptive nomenclature based on scleral hue was chosen to report findings in this study. This was found to be just as cumbersome as the confusing array of synonyms and eponyms for osteogenesis imperfecta in published reports. Therefore, in Table 7, we have summarised the results of our studies and of reported cases of OI and proposed a numerical classification based on clinical and genetic findings.

Type I OI corresponds to the syndrome shared by group 1 patients in this study. The present evidence suggests that there may be further heterogeneity in

this group based on the presence or absence of dentinogenesis imperfecta in families.

Type II OI refers to those cases with lethal perinatal OI, group 2 in the present study, in which autosomal recessive inheritance is highly likely, based on pedigree findings. The present evidence does not allow us to classify sporadic cases with this phenotype for certain.

Type III OI refers to cases with the progressively deforming OI phenotype, in which the sclerae become less blue with age, where autosomal recessive inheritance can be shown. A proportion of patients in group 3 in the present report almost certainly have this phenotype. However, an unknown proportion probably represents sporadic cases of the fourth syndrome defined in these studies.

Type IV OI refers to cases with dominantly inherited OI with normal sclerae. Some cases in reported families have had the progressively deforming OI phenotype, so it is likely that some sporadic cases with normal sclerae and severe progressive deformity of long bones and spine represent this OI type arising by new dominant mutation.

We propose that suffixes such as congenita and tarda, if used at all, describe the age at presentation only. For example, a child or adult with fractures at birth, sclerae of normal hue after several years of age, parental consanguinity or affected sibs with normal parents, and severe long bone deformity would be classified as OI type III (congenita). On the other hand, a child or adult with fractures at birth, distinctly blue sclerae, and an affected parent with bone fragility, blue sclerae, and presenile deafness (or family history of the same) would be classified as OI type I (congenita).

It is as yet impossible to classify sporadic cases of OI with certainty. However, consideration of the clinical and radiological findings, natural history, and family history in a particular sporadic case may allow a cautious presumptive diagnosis to be made. Even so, genetic counselling in a particular case should be based on a complete pedigree analysis, as well as clinical and radiological assessment of the patient and any affected family members.

With this provision, this new classification of OI syndromes will be most useful. It will focus the attention of clinical and laboratory research efforts on the known syndromes of osteogenesis imperfecta. Furthermore, it will provide a framework for relating the large number of fundamental studies of OI to specific syndromes. Until the biochemical characterisation of these syndromes is completed, the extent of the heterogeneity cannot be known. A final classification and characterisation of the defect in sporadic cases and individual families will then be possible.

Table 7 *A nomenclature for OI syndromes*

<i>Suggested numerical type</i>	<i>Qualifying suffixes</i>	<i>Mode of inheritance</i>	<i>Reported synonyms and eponyms</i>
I	Congenita tarda	Autosomal dominant	Dominantly inherited OI with distinctly blue sclerae, Van der Hoeve's syndrome, Trias fragilitas ossium, OI tarda levis, OI tarda type II, OI (mild long bone deformity), Eddowes's syndrome
II	Congenita (always)	Autosomal recessive	Lethal perinatal OI, OI letalis Vrolik, Lethal OI congenita
III	Congenita (tarda)	Autosomal recessive	Progressively deforming OI with normal sclerae, OI congenita, OI tarda gravis, OI (severe long bone deformity), OI congenita type Vrolik, Periosteal dysplasia of Porak and Durante, Osteopsathyrosis idiopathica of Lobstein
IV	Congenita tarda	Autosomal dominant	Dominantly inherited OI with normal sclerae, Osteopsathyrosis idiopathica of Lobstein, Ekman-Lobstein disease

The heterogeneity which we have observed demands a critical reassessment of current objectives and methodology in prenatal diagnosis of OI (Solomons and Armstrong, 1976). There is a high probability that patients with dominantly inherited OI and blue sclerae are not at risk for producing an infant who will die in the newborn period with lethal perinatal OI.

The authors gratefully acknowledge the co-operation of physicians, medical record librarians, handicapped children's services, and the Consultative Committee on Perinatal Mortality in Victoria, Australia. Collie and Son, North Melbourne, Victoria, made an invaluable contribution to this study through their construction of the blue scales. DOS was supported by a Research Training Grant from The Royal Children's Hospital Research Foundation.

We thank Drs Jennifer Ault and Maureen Bocian for their detailed review of the manuscript and constructive criticism.

This work was presented in part at the Australian Pediatric Society Meeting, April 1977, the Fifth International Conference on Birth Defects, August 1977 (*Excerpta Medica*, 426, 43, Abst. 95, 1977), and the Western Society for Pediatric Research, February 1978 (*Clinical Research*, 26 (2), 178A, 1978).

References

- Aadaita, M. D. (1957). Osteogenesis imperfecta—a case report. *Journal of the Indian Medical Profession*, 4, 1810–1812.
- Awwaad, S., and Reda, M. (1960). Osteogenesis imperfecta; a review of literature and report on three cases. *Archives of Pediatrics*, 77, 280–290.
- Axmann, E. (1831). Merkwürdige Fragilität der Knochen ohne dyskrasische ursache als Krankhafte Eigenthümlichkeit dreier Geschwister. *Annalen Geschichte Heilkunde*, 4, 58–68, (quoted from McKusick, V. A., 1972).
- Bauze, R. J., Smith, R., and Francis, M. J. O. (1975). A new look at osteogenesis imperfecta. A clinical, radiological and biochemical study of forty-two patients. *Journal of Bone and Joint Surgery*, 57B, 2–12.
- Bell, J. (1928). Blue sclerotics and fragility of bone. In *Treasury of Human Inheritance*, Vol. 2, part 3. Cambridge University Press, Cambridge and London.
- Bixler, D. (1976). Heritable disorders affecting dentin. In *Oral-Facial Genetics*. Ed. by R. E. Stewart and G. H. Prescott. Mosby, St. Louis.
- Blount, W. P. (1969). Early recognition and evaluation of spinal deformity. *Wisconsin Medical Journal*, 68, 245–249.
- Bluemcke, S., Niedorf, H. R., Thiel, H. J., and Langness, U. (1972). Histochemical and fine structural studies on the cornea in osteogenesis imperfecta. *Virchows Archiv für Pathologische Anatomie und Physiologie und für Klinische Medizin*, 11, 124–132.
- Buchanan, L. (1903). Case of congenital maldevelopment of the cornea and sclerae. *Transactions of the Ophthalmological Society of the United Kingdom*, 23, 267–269.
- Caniggia, A., Stuart, C., and Guideri, R. (1958). Fragilitas ossium hereditaria tarda. *Acta Medica Scandinavica*, 162, Suppl. 340, 1–172.
- Casanovas, J. (1934). Blue scleras and fragilitas osseum. *Archivos de Oftalmologia Hispano-Americanos*, 34, 133. (*American Journal of Diseases of Children*, 50, 1298–1299 (Abst.), 1935.)
- Chawla, S. (1964). Intrauterine osteogenesis imperfecta in four siblings. *British Medical Journal*, 5375, 99–101.
- Cocchi, U. (1964). Osteogenesis imperfecta. In *Humangenetik*, Vol. 2, pp. 151–159. Ed. by P. E. Becker. Thieme, Stuttgart.
- Danks, D. M. (1975). Generalized dysplasias of bone: some practical considerations. In *Progress in Pediatric Surgery*, Vol. 8, pp. 135–165. Urban and Schwarzenberg, München.
- Danks, D. M., Allan, J., and Anderson, C. M. (1965). A genetic study of fibrocystic diseases of the pancreas. *Annals of Human Genetics*, 28, 323–340.
- Eddowes, A. (1900). Dark sclerotics and fragilitas ossium. *British Medical Journal*, 2, 222.
- Eichholtz, W. (1971). Osteogenesis imperfecta. Electron-microscopische Befunde an Sklera und Cornea. Bericht über die 71. Zusammenkunft der Deutschen Ophthalmologie. Gesellschaft in Heidelberg, 1971, 116–120.
- Eichholtz, W., and Mueller, D. (1972). Electron microscopy findings on the cornea and sclera in osteogenesis imperfecta. *Klinische Monatsblätter für Augenheilkunde*, 161, 646–653.
- Ekman, O. J. (1788). Descriptionem et casus aliquot osteomalacia sistens. *Dissertatio Medica, Uppsala*. Quoted from Seedorf, K. S. (1949).
- Emery, A. E. H. (1976). *Methodology in Human Genetics*. Churchill Livingstone, Edinburgh.
- Fairbank, T. (1951). *An Atlas of General Affections of the Skeleton*. Livingstone, Edinburgh.
- Falvo, K. A., Root, L., and Bullough, P. G. (1974). Osteogenesis imperfecta: clinical evaluation and management. *Journal of Bone and Joint Surgery*, 56A, 783–793.
- Follis, R. H., Jr. (1952). Osteogenesis imperfecta congenita; a connective tissue diathesis. *Journal of Pediatrics*, 41, 713–721.
- Follis, R. J., Jr. (1953). Development of the corium in the osteogenesis imperfecta syndrome. *Bulletin of the Johns Hopkins Hospital*, 93, 225–233.
- Francis, M. J. O., Bauze, R. J., and Smith, R. (1975). Osteogenesis imperfecta: a new classification. *Birth Defects: Original Article Series*, 11 (6), 99–102. The National Foundation—March of Dimes, New York.
- Francis, M. J. O., and Smith, R. (1975). Polymeric collagen of skin in osteogenesis imperfecta, homocystinuria and Ehlers-Danlos and Marfan syndromes. *Birth Defects—Original Article Series*, 11(6), 15–21. The National Foundation—March of Dimes, New York.
- Francis, M. J. O., Smith, R., and MacMillan, D. C. (1973). Polymeric collagen of skin in normal subjects and in patients with inherited connective tissue disorders. *Clinical Science*, 44, 429–438.
- Freda, V. J., Vosburgh, G. J., and Di Liberti, C. (1961). Osteogenesis imperfecta congenita. A presentation of sixteen cases and review of the literature. *Obstetrics and Gynecology*, 18, 535–547.
- Goldfarb, A. A., and Ford, D. (1954). Osteogenesis imperfecta in consecutive siblings. *Journal of Pediatrics*, 44, 264–268.
- Haebara, H., Yamasaki, Y., and Kyogoko, M. (1969). An autopsy case of osteogenesis imperfecta. *Acta Pathologica Japonica*, 19, 377–394.
- Hein, B. J. (1928). Osteogenesis imperfecta with multiple fractures at birth: an investigation with special reference to heredity and blue sclera. *Journal of Bone and Joint Surgery*, 10, 243–247.

- Heller, R. H., Winn, K. J., and Heller, R. M. (1975). The prenatal diagnosis of osteogenesis imperfecta congenita. *American Journal of Obstetrics and Gynecology*, **121**, 572-573.
- Holcomb, D. Y. (1931). A fragile-boned family. Hereditary fragilitas ossium. *Journal of Heredity*, **22**, 105-115.
- Horan, F., and Beighton, P. (1975). Autosomal recessive inheritance of osteogenesis imperfecta. *Clinical Genetics*, **8**, 107-111.
- Ibsen, K. H. (1967). Distinct varieties of osteogenesis imperfecta. *Clinical Orthopaedics and Related Research*, **50**, 279-290.
- Kaplan, M., and Baldino, C. (1953). Dysplasia périostale paraissant familiale et transmise suivant le mode mendélien récessif. *Archives Françaises de Pédiatrie*, **10**, 943-950.
- King, J. D., and Bobechko, W. P. (1971). Osteogenesis imperfecta. An orthopedic description and surgical review. *Journal of Bone and Joint Surgery*, **53B**, 72-89.
- Kitchen, W. H. (1968a). The relationship between birth-weight and gestational age in an Australian hospital population. *Australian Pediatric Journal*, **4**, 29-37.
- Kitchen, W. H. (1968b). Head circumference, length and placental weight of infants in an Australian hospital population. *Australian Pediatric Journal*, **4**, 105-112.
- Komai, T., Kunii, H., and Ozaki, Y. (1956). A note on the genetics of Van der Hoeve's syndrome, with special reference to a large Japanese kindred. *American Journal of Human Genetics*, **8**, 110-119.
- Levin, L. S., Salinas, C. F., and Jorgensen, R. J. (1978). Classification of osteogenesis imperfecta by dental characteristics. *Lancet*, **1**, 332-333.
- Levin, L. S., and Thompson, R. G. (1975). Osteogenesis imperfecta tarda presenting with short stature. *Birth Defects—Original Article Series*, **9** (6), 103-105. The National Foundation—March of Dimes, New York.
- Lièvre, J. A. (1959). La fragilité osseuse constitutionnelle. Étude de 25 familles comportant 53 malades. *Revue de Rhumatisme et des Maladies Ostéo-Articulaires*, **26**, 420-432.
- Lobstein, J. G. C. F. M. (1835). *Lehrbuch der Pathologischen Anatomie*, Bd. 2, p. 179. Stuttgart. (Quoted from Seedorf, K. S., 1949).
- Looser, E. (1906). Zur Kenntnis der osteogenesis imperfecta congenita und tarda. *Mittellungen aus der Grenzgebieten Medizin und Chirurgie*, **15**, 161-207.
- McKusick, V. A. (1972). *Heritable Disorders of Connective Tissues*. Mosby, St. Louis.
- McKusick, V. A. (1975). The classification of heritable disorders of connective tissue. *Birth Defects—Original Article Series*, **11**, (6), 1-9. The National Foundation—March of Dimes, New York.
- Maloney, F. P. (1969). Osteogenesis imperfecta of early onset in three members of an inbred group; recessive inheritance. In *Skeletal Dysplasias. Clinical Delineation of Birth Defects*, Vol. IV, pp. 219-224. The National Foundation—March of Dimes, New York.
- Nie, N. H., Hull, C. H., Jenkins, J. A., Steinbrenner, K., and Bent, D. H. (1975). *Statistical Package for the Social Sciences*. McGraw-Hill, New York.
- Omenn, G. S., Hall, J. G., Graham, B., and Karp, L. E. (1977). The use of radiographic visualization for prenatal diagnosis. *Birth Defects—Original Article Series*, **12** (3D), 217-229. The National Foundation—March of Dimes, New York.
- Penttinen, R. P., Lichtenstein, J. R., Martin, G. R., and McKusick, V. A. (1975). Abnormal collagen metabolism in cultured cells in osteogenesis imperfecta. *Proceedings of the National Academy of Sciences of the U.S.A.*, **72**, 586-589.
- Remigio, P. A., and Grinvalsky, H. T. (1970). Osteogenesis imperfecta congenita. *American Journal of Diseases of Children*, **119**, 524-528.
- Rohwedder, von H. J. (1953). Ein Beitrag zur Frage des Erbganges der Osteogenesis Imperfecta Vrolik. *Archiv für Kinderheilkunde*, **147**, 256-262.
- Schröder, G. (1964). Osteogenesis imperfecta. Eine klinisch-erbbiologische Untersuchung des Krankengutes in Westfalen. Schätzung der Mutationsraten für den Regierungsbezirk Münster (Westfalen). *Zeitschrift für Menschliche Vererbung und Konstitutionslehre*, **37**, 632-676.
- Seedorf, K. S. (1949). *Osteogenesis Imperfecta: A Study of Clinical Features and Heredity Based on 55 Danish Families Comprising 180 Affected Members*. Universitetsforlaget I Arhus, Copenhagen.
- Smars, G. (1961). *Osteogenesis Imperfecta in Sweden*. Scandinavian University Books, Stockholm.
- Solomons, C. C., and Armstrong, D. A. (1976). Prenatal testing for osteogenesis imperfecta. *Proceedings of the 22nd Orthopedic Research Society*, Abst. 88.
- Spurway, J. (1896). Hereditary tendency to fracture. *British Medical Journal*, **2**, 844.
- Suen, V. F., Hams, V., and Berman, J. L. (1974). Osteogenesis imperfecta congenita. Report of a mother and son. *Clinical Genetics*, **5**, 307-311.
- Tanner, J. M., Whitehouse, R. H., and Takaishi, M. (1966). Standards from birth to maturity for height, weight, height velocity, and weight velocity: British children, 1965. *Archives of Disease in Childhood*, **41**, 454-471, 613-635.
- Tsuruta, T., and Sugiura, Y. (1977). Lethal short-limbed dwarfism in Japan. *Proceedings of the Fifth International Conference of Birth Defects*. Excerpta Medica (Congress Series), **426**, 118 (Abst.).
- Van de Hoeve, J., and de Kleyn, A. (1918). Blaue Sclerae Knochenbrüchigkeit und Schwerhörigkeit. *Archiv für Ophthalmologie*, **95**, 81-93.
- Williams, P. F. (1965). Fragmentation and rodding in osteogenesis imperfecta. *Journal of Bone and Joint Surgery*, **47B**, 23-31.
- Wilson, M. G. (1974). Congenital osteogenesis imperfecta. *Birth Defects—Original Article Series*, **10** (12), 296-298. The National Foundation—March of Dimes, New York.
- Winkler, N. F. (1871). Ein Fall von foetaler Rachitis mit Mikromelie. *Archiv für Gynakologie*, **2**, 101-111.
- Zeitoun, M. M., Ibrahim, A. H., and Kassem, A. S. (1963). Osteogenesis imperfecta congenita in dizygotic twins. *Archives of Disease in Childhood*, **38**, 289-291.

Requests for reprints to Dr D. O. Sillence, Division of Medical Genetics, Harbor-UCLA Medical Center, 1000 West Carson Street, Torrance, California 90509, USA.