

this case and that of Gripenberg *et al* (1972) resemble syndrome I more than syndrome II. An infant recently reported to have monosomy 22 had congenital heart disease but lacked the epicanthus and syndactyly of syndrome II (DeCicco *et al*, 1973). Hence these distinctions need further refinement and correlation with karyotypes if they are to prove useful for clinical diagnosis.

KATHERINE H. HALLORAN, W. ROY BREG, and  
MAURICE J. MAHONEY

*Departments of Human Genetics and Pediatrics,  
Yale University School of Medicine, 333 Cedar  
Street, New Haven, Connecticut 06510, USA*

#### REFERENCES

- Bobrow, M., Collacott, H. E. A. C., and Madan, K. (1972). Chromosome banding with acridine orange. *Lancet*, **2**, 1311.
- Cohen, M. M. and Putnam, T. I. (1972). An 18p21q translocation in a patient with presumptive 'Monosomy G'. *American Journal of Diseases of Children*, **124**, 908-910.
- Cooksley, W. G. E., Firouz-Abadi, A., and Wallace, D. C. (1973). Monosomy of a 'G' autosome in a 22-year-old female. *Medical Journal of Australia*, **2**, 178-180.
- DeCicco, F., Steele, M. W., Pan, S., and Park, S. C. (1973). Monosomy of chromosome No. 22: a case report. *Journal of Pediatrics*, **83**, 836-838.
- Dutrillaux, B., Jonasson, J., Laurén, K., LeJeune, J., Lindsten, J., Petersen, G. B., and Saldaña-García, P. (1973). An unbalanced 4q/21q translocation identified by the R but not by the G and Q chromosome banding techniques. *Annales de Génétique*, **16**, 11-16.
- Gripenberg, U., Elfving, J., and Gripenberg, L. (1972). A 45,XX,21- child: attempt at cytological and clinical interpretation of the karyotype. *Journal of Medical Genetics*, **9**, 110-115.
- Richmond, H. G., MacArthur, P., and Hunter, D. (1973). A 'G' deletion syndrome, anti-mongolism. *Acta Paediatrica Scandinavica*, **62**, 216-220.
- Wyandt, H. E., Hecht, F., Louvrien, E. W., and Stewart, R. E. (1971). Study of a patient with apparent monosomy 21 owing to translocation: 45,XX,21-,t(18q+). *Cytogenetics*, **10**, 413-426.

## Karyotype 45,XX,-21/46,XX,21q- in an infant with symptoms of G-deletion syndrome I

**Summary.** An infant with anti-mongoloid eye slants, achalasia, broad nose, one low-set large and one rudimentary ear lobe, and rudimentary nails with a retarded psychomotor development showed an 45,XX,-21/46,XX,21q- karyotype. By fluorescence and Giemsa staining it was shown that the missing or deleted chromosome 21 was of paternal origin.

Since Lejeune *et al* (1964) first reported a case with a mosaic of cells with 45 chromosomes and a missing G chromosome and cells with 46 chromosomes with a deleted G, a number of such mosaic

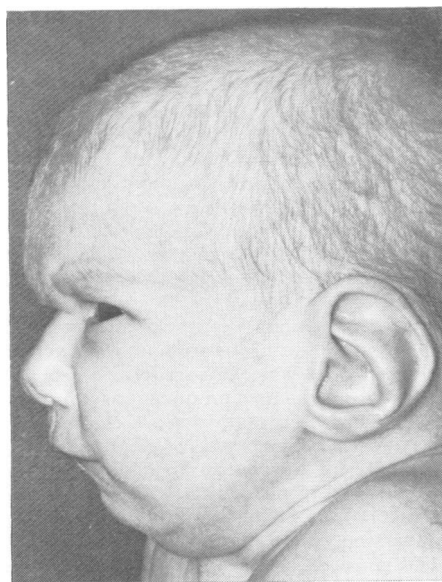


FIG. 1. The proposita at 6 weeks of age. Note large low-set hypoplastic ear and receding chin.

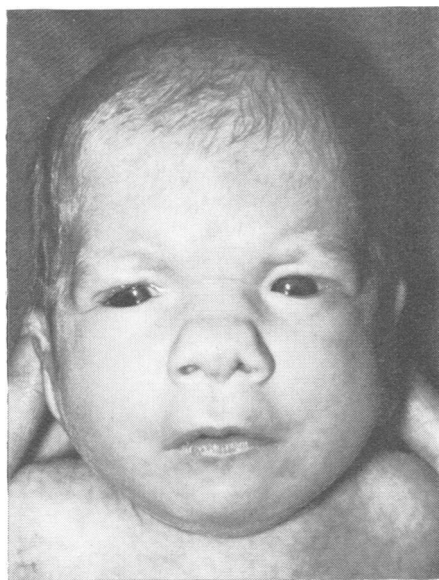


FIG. 2. The proposita at 6 weeks of age. Note antimongoloid slants, blepharochalasia, and broad nose bridge.

cases have been reported (Greenwood and Sommer, 1971; Berger, 1972). This report presents another infant with a similar chromosome abnormality and a 45,XX,-21/46,XX,21q- karyotype.

### Case report

The proposita was born in April 1973. She is the second child of unrelated parents. The first child is a healthy 7-year-old girl. The father is 36 years old. He had mumps half a year before conception and worked with radar for a period of five years until 1962. The mother is 31 years old and has hay fever. She had been vaccinated during the pregnancy and had been treated with ephedrine. The pregnancy was normal.

The child was born one week before term. She weighed 1650 g and was 41 cm long. The head circumference was 29 cm. The Apgar score was 2/1 min and 4/2 min.

Physical examination revealed a premature infant with a rudimentary right ear lobe without any external auditory meatus, and a large, low-set left ear lobe (Fig. 1). The nose was broad with a prominent nasal bridge. On the tip of the nose a dimple was seen and from this dimple a light streak ran downwards in the midline to the philtrum. There was an antimongoloid slant of the eyes and bilateral blepharochalasia (Fig. 2); ophthalmoscopy was normal. The mouth was broad; a cleft palate was seen in the midline, and the mandible was small and receding. The hands and fingers were very slender; on the right hand, the second and fourth finger overlaid the third finger. The left foot was in a calcaneovalgus position and the right foot was inverted. The nails on all fingers and toes were rudimentary (Fig. 3). A rough systolic murmur was heard to the left of the sternum.

Skeletal radiology revealed 13 ribs on the left side and hemivertebrae at the 10th and 11th thoracic vertebrae.

Psychomotor development has been very slow. At 4 months she weighed only 3000 g and was severely retarded.

The peculiar appearance of the infant prompted a chromosome analysis shortly after birth.

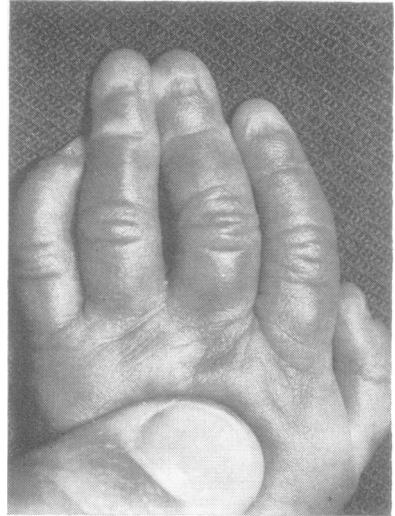


FIG. 3. Hypoplastic finger nails in the proposita.

### Cytogenetic studies

Cultured lymphocytes and skin fibroblast were examined from the proposita. The chromosome count distribution is given in Table I. Fluorescence studies were performed using a modification of the method described by Caspersson *et al* (1970) and Giemsa banding by the method routinely used in our laboratory (Mikkelsen and Dyggve, 1973). Lymphocytes from the parents and the proposita's sister were also studied.

A mosaic of cells with 46 chromosomes and a deletion of the long arm of one chromosome No. 21 and cells with 45 chromosomes with only one chromosome No. 21 were found in the proposita; the karyotype was 45,XX,-21/46,XX,21q-. The 45 line was predominant in lymphocytes, while in skin

TABLE I  
CHROMOSOME COUNT DISTRIBUTION

	44	45	46	47	Total No. of Cells Examined	Karyotype
<i>Proposita</i>						
Blood	2	47	11		60	45,XX,-21/46,XX,21q-
Skin	1	3	46		50	45,XX,-21/46,XX,21q-
<i>Mother</i>						
Blood			20		20	46,XX
<i>Father</i>						
Blood		1	54	2*	57	46,XY
<i>Sister</i>						
Blood			50		50	46,XX

\* 47,XXY and 47,XY,+G.

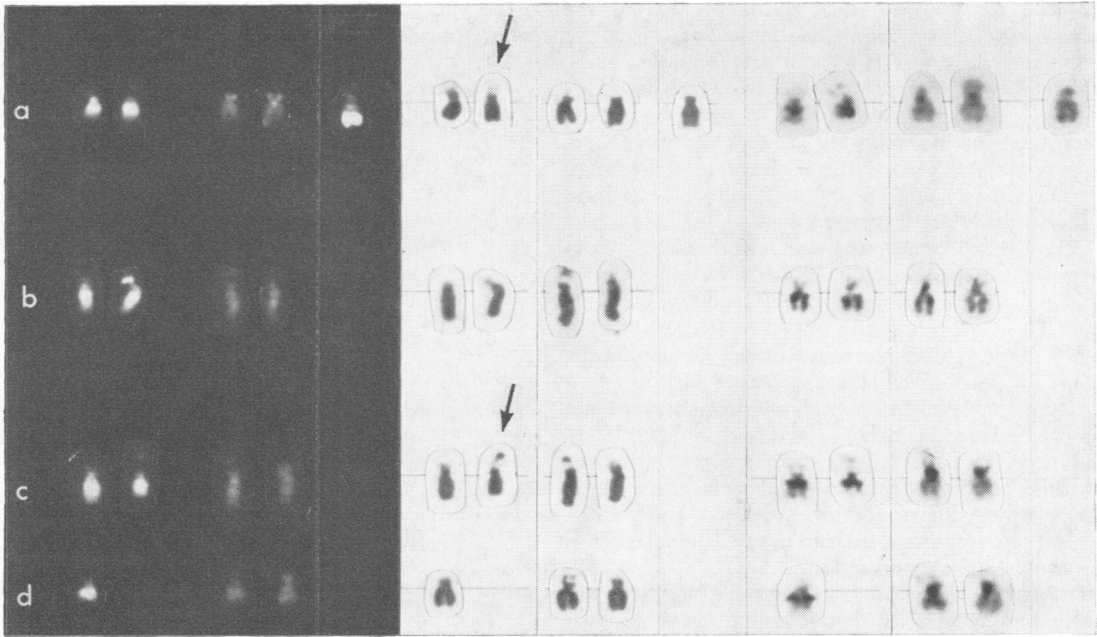


FIG. 4. Fluorescence and Giemsa-stained G-group chromosomes from the same cell and Giemsa banding from another cell. Line a: the proposita's father; line b: the proposita's mother; line c: the proposita's 46,XX,21q- cell line; line d: the proposita's 45,XX,-21 cell line. Note the non-fluorescing Giemsa-stained marker chromosome 21 from the father (arrow). The same chromosome is deleted or missing in the proposita.

fibroblasts the 46 line with the deleted G was the predominant line (Table I). The breakpoint of the deleted 21 chromosome was determined by fluorescence and Giemsa banding to be located at q22 close to the medium intense band. The deleted chromosome had non-fluorescing satellites which were well-stained by Giemsa.

The mother and the sister had normal karyotypes. The father had two hyperdiploid cells, one with an XXY karyotype and one with a supernumerary G chromosome (Table I). A comparison of parental cells with the two cell lines from the proposita showed that the respectively missing, or deleted 21 chromosome was of paternal origin. One of the father's 21 chromosomes showed non-fluorescing but Giemsa stained marker satellites. This chromosome was missing in the proposita's cell line with 45 chromosomes and it was deleted in the 46 cell line (Fig. 4).

### Discussion

Only few G-deletion cases have so far been analysed by banding methods. They have shown a variety of chromosome abnormalities. Mosaics,

deletions, and rings of both chromosome 21 and chromosome 22 were found (Table II). There is a considerable difference in the amount of chromosome material lost and the clinical pictures are widely different. However, two clinical syndromes

TABLE II  
BANDING STUDIES IN DELETION SYNDROMES

Reference	Karyotype	Deletion Syndrome
Crandall <i>et al</i> (1972)		
Case 1	46,XY,r21	I
Case 2	46,XY,r22	II
Case 3	46,XY,r22	II
Gripenberg <i>et al</i> (1972)	45,XX,-21	?
Magenis <i>et al</i> (1972)		
Case 1	46,XY,r21	I
Case 2	46,XX,r22	II
Richmond <i>et al</i> (1973)	46,XX/45,XX,-21 (blood) 46,XX/46,XX,rG (skin)	I
Shibata <i>et al</i> (1973)	45,XX,-21/46,XX,r21	I
Stoll <i>et al</i> (1973)	46,XX,r22	II
Warren <i>et al</i> (1973)		
Case 1	46,XY,r21	I
Case 2	46,XX,r22	II
Case 3	46,XY,r22	II

may be recognized: the clinical picture of the 'antimongolism syndrome' (Lejeune *et al.*, 1964) or deletion syndrome I (Warren and Rimoin, 1970) which shows hypertonia, blepharochalasia, antimongoloid slants, large poorly lobulated ears, microretrognathia, retarded growth, and mental retardation. All cases with a clear cut deletion of chromosome 21 or a mosaic with a missing 21 have shown most of these symptoms.

The clinical symptoms were less characteristic in cases where chromosome 22 was affected. Hypotonia, epicanthus, ptosis, syndactyly, and mental retardation were frequently observed (Reisman *et al.*, 1967; Berger 1972; Warren, Rimoin, and Summitt, 1973). Complicated rearrangements with G chromosomes with additional or missing chromosome material were reported (Rethoré *et al.*, 1972; Koivisto *et al.*, 1973). As well as a missing chromosome 21 an unidentified small metacentric chromosome was also found in Koivisto's case. The clinical picture, therefore, can not be compared with the two deletion syndromes.

Only a few cases of apparently pure monosomy G are known (Thorburn and Johnson, 1966; Al-Aish *et al.*, 1967; Hall, Fredga, and Svenningsen, 1967; Böhm and Fuhrmann, 1969; Gripenberg, Elfving, and Gripenberg, 1972). Only in Gripenberg *et al.*'s case was the missing chromosome identified by special staining as chromosome 21. The other cases were examined before special staining methods were available. Only lymphocytes were examined in the cases of Thorburn and Johnson and of Böhm and Fuhrmann. In Böhm's and Fuhrmann's case 4% normal cells were found in blood culture. In both cases, mosaicism with a normal cell line might have been present. The clinical picture of these cases showed considerable variability. The minor symptoms found in the cases of Al-Aish and Gripenberg might be explained by a hidden translocation of a small part of chromosome 21 material onto another chromosome. Such a case was demonstrated by Rethoré *et al.* (1972); unfortunately no clinical description was given stating only that the symptoms were different from the deletion syndrome I. In Rethoré's case the distal end of a chromosome 21 was translocated onto the short arm of chromosome 9. While in deletion syndrome I, the distal part of chromosome 21 is missing, in the translocation case the proximal part of chromosome 21 was missing. This type of anomaly is impossible to detect with conventional chromosome techniques.

A thorough clinical examination with a comparison of cytogenetic findings with special staining methods may add to our knowledge of phenotype-

genotype association and may establish with certainty two or even more G-deletion syndromes.

The expert technical assistance of Mrs Hanne Poulsen and Mrs Birthe Jespersen is gratefully acknowledged. This study has been supported by a grant from the Research Committee of the Danish Mental Retardation Service.

MARGARETA MIKKELSEN and S. VESTERMARK

*The John F. Kennedy Institute, Gl. Landevej 7  
and the Department of Pediatrics, Glostrup  
Hospital, DK 2600 Glostrup, Denmark*

#### REFERENCES

- Al-Aish, M. S., De La Cruz, F., Goldsmith, L. A., Volpe, J., Mella, G., and Robinson, J. C. (1967). Autosomal monosomy in man. Complete monosomy G (21-22) in a four-and-one-half-year-old mentally retarded girl. *New England Journal of Medicine*, **277**, 777-784.
- Berger, R. (1972). Monosomies G. *Nouvelle Presse Médicale*, **1**, 1033-1034.
- Böhm, R. and Fuhrmann, W. (1969). Lebensfähigkeit bei Monosomie G. *Monatsschrift für Kinderheilkunde*, **117**, 184-187.
- Caspersson, T., Zech, L., Johansson, C., and Modest, E. J. (1970). Identification of human chromosomes by DNA-binding fluorescent agents. *Chromosoma*, **30**, 215-227.
- Crandall, B. F., Weber, F., Muller, H. M., and Burwell, J. K. (1972). Identification of 21r and 22r chromosomes by quinacrine fluorescence. *Clinical Genetics*, **3**, 264-270.
- Greenwood, R. D. and Sommer, A. (1971). Monosomy G: case report and review of the literature. *Journal of Medical Genetics*, **8**, 496-500.
- Gripenberg, U., Elfving, J., and Gripenberg, L. (1972). A 45,XX,21- child: attempt at a cytological and clinical interpretation of the karyotype. *Journal of Medical Genetics*, **9**, 110-115.
- Hall, B., Fredga, K., and Svenningsen, N. (1967). A case of monosomy G? *Hereditas Genetiskt Arkiv*, **57**, 356-364.
- Koivisto, M., Schröder, J., Phil, L., and de la Chapelle, A. (1973). Probable monosomy-21 and partial trisomy. *American Journal of Diseases of Children*, **125**, 426-428.
- Lejeune, J., Berger, R., Rethoré, M.-O., Archambault, L., Jérôme, H., Thieffry, S., Aicardi, J., Broyer, M., Lafourcade, J., Cruveiller, J., and Turpin, R. (1964). Monosomie partielle pour un petit acrocentrique. *Comptes Rendus Hebdomodaires des Séances de l'Académie des Sciences*, **259**, 4187-4190.
- Magenis, R. E., Armendares, S., Hecht, F., Weleber, R. G., and Overton, K. (1972). Identification by fluorescence of two G rings: (46,XY,21r) G deletion syndrome I and (46,XX,22r) G deletion syndrome II. *Annales de Génétique*, **15**, 265-266.
- Mikkelsen, M. and Dyggve, H. (1973). (6;15) Translocation with loss of chromosome material in the patient and various chromosome aberrations in family members. *Humangenetik*, **18**, 195-202.
- Reisman, L. E., Darnell, A., Murphy, J. W., Hall, B., and Kasahara, S. (1967). A child with partial deletion of a G-group autosome. *American Journal of Diseases of Children*, **114**, 336-339.
- Rethoré, M.-O., Dutrillaux, B., Baheux, G., Gerveaux, J. and Lejeune, J. (1972). Monosomie pour les régions juxtacentromériques d'un chromosome 21. *Experimental Cell Research*, **70**, 455-456.
- Richmond, H. G., Macarthur, P., and Hunter, D. (1973). A 'G' deletion syndrome; anti-mongolism. *Acta Paediatrica Scandinavica*, **62**, 216-220.
- Shibata, K., Waldenmaier, C., and Hirsch, W. (1973). A child with a 21-ring chromosome, 45,XX,21- /46,XX,21r investigated with the banding technique. *Humangenetik*, **18**, 315-319.
- Stoll, C., Rohmer, A., and Sauvage, P. (1973). Chromosome 22 en anneau r(22): Identification par dénaturation thermique ménagée. *Annales de Génétique*, **16**, 193-198.

Thorburn, M. J. and Johnson, B. E. (1966). Apparent monosomy of a G autosome in a Jamaican infant. *Journal of Medical Genetics*, **3**, 290-292.

Warren, R. J. and Rimoin, D. L. (1970). The G deletion syndromes. *Journal of Pediatrics*, **77**, 658-663.

Warren, R. J., Rimoin, D. L., and Summitt, R. L. (1973). Identification by fluorescent microscopy of the abnormal chromosomes associated with the G-deletion syndromes. *American Journal of Human Genetics*, **25**, 77-81.

## The trisomy 8 syndrome: two additional mosaic cases\*

**Summary.** Two patients with trisomy 8 mosaicism, confirmed by trypsin-Giemsa banding are described. While the majority of patients with this aneuploidy have been mosaics, the phenotypes of the complete and mosaic trisomies closely resemble each other. Mosaic trisomy 8 results in specific clinical findings which include skeletal dysplasia, particularly absent patellae, deep furrowing of the soles of the feet, and periarticular changes resulting in camptodactyly and progressive limitation of joint mobility.

Trisomy C has been described in approximately 30 patients and as expected, the phenotypes have shown considerable variation. Identification of the particular C-group chromosome involved was not possible until the advent of the chromosome banding techniques. With these techniques, a specific trisomy 8 syndrome has emerged and eight patients with this syndrome have been described (de Grouchy, Turleau, and Léonard, 1971; Bijlsma, Wijffels, and Tegelaers, 1972; Caspersson *et al.*, 1972; Kakati, Nihill, and Sinha, 1973). We would like to report two additional cases of trisomy 8 mosaicism, confirmed with trypsin-Giemsa banding, both of whom showed specific physical changes.

## Case reports

**Case 1.** This patient, born 5 March 1953, is now 20 years of age and has been followed since the age of 12 years. He was the third child born to a 27-year-old mother and 26-year-old father. There was no history of abortions or infertility. The mother reported intermittent vaginal bleeding and cramps during the first trimester of the pregnancy. The delivery was spontaneous at 37 weeks' gestation and the infant weighed 2050 g and length was 44.5 cm. His development was slow and he did not walk until 2 years of age or talk until he was 4 years old. He attended classes for the retarded and still is unable to read and write. His IQ (Stanford-Binet and Wechsler) is between 40-50. His tonsils and adenoids were removed at age 5 years and a bilateral herniorrhaphy and orchiopexy was performed at 10 years. Because of an increasing equinus deformity at both ankles, Achilles tendon lengthening procedures were performed at age 10 years. Progressive flexion contractures have been noted at both hips, wrists and interphalangeal joints. At 11-12 years of age he developed severe cystic

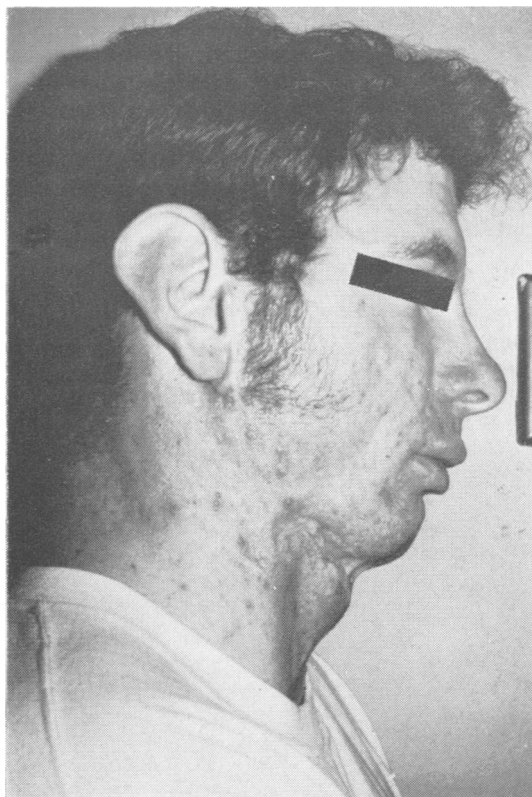

FIG. 1. Case 1. Note dysplastic ear, minimal micrognathia, and severe acne.

Received 18 February 1974.

\* This research was supported in part by University of California at Los Angeles; Mental Retardation Program and Child Psychiatry Program, NPI, UCLA, MCH-927; Interdisciplinary Training in Mental Retardation, HD-04612; Mental Retardation Research Center, UCLA, HD-00345; Research Training in Mental Retardation, HD-05615; Developmental Biology in Mental Retardation.

Reprint requests to: Barbara F. Crandall, MD, MR Unit/NPI, 760 Westwood Plaza, Los Angeles, California 90024, USA.