

- Jacobs, P. A., Harnden, D. G., Buckton, K. E., Court-Brown, W. M., King, M. J., McBride, J. A., MacGregor, T. N., and Maclean, N. (1961). Cytogenetic studies in primary amenorrhoea. *Lancet*, **1**, 1183-1189.
- Schellhas, H. F. (1974). Malignant potential of the dysgenetic gonad Part II. *Obstetrics and Gynecology*, **44**, 455-462.
- Taylor, A. I. (1968). Cell selection *in vivo* in normal and G trisomic mosaics. *Nature*, **219**, 1028-1030.
- Trowell, H. R., and Hamilton, G. J. L. (1965). XO/XXY mosaicism in a phenotypic male. *The Human Chromosome Newsletter*, **16**, 32.

Requests for reprints to Dr Marie T. Mulcahy, The Cytogenetics Unit, State Health Laboratory Services, Box F312, G.P.O., Perth, Western Australia 6001.

## Reproduction in a woman with low percentage t(21q21q) mosaicism

**SUMMARY** The birth of a child is described with Down syndrome followed by the conception of a fetus bearing the t(21q21q) chromosome in 100% of their cells in a woman mosaic for the translocation in less than 10% of 2 of her examined tissues and in none of the cells in her peripheral blood. Various hypotheses for explaining the above findings are discussed. The importance of examining as many parental tissues as possible for the detection of low percentage mosaicism is stressed.

Dallaire and Fraser (1964) reported a family in which 3 children in succession had Down syndrome caused by primary trisomy 21. Lymphocyte cultures of the parents were cytogenetically normal, but other tissues were not studied. Recently Nuzzo *et al.* (1975)

reported a similar family. Lymphocyte cultures on the parents were likewise normal, but long-term cultures of maternal skin fibroblasts revealed 0.87% mosaicism for trisomy-21.

Maternal mosaicism (46,XX/47,XX,+21) as a cause of Down syndrome was first reported by Smith *et al.* in 1962 and other cases have since been described (see for example Aarskog, 1969; Kaffe *et al.*, 1974).

Paternal mosaicism for trisomy-21 has also been described (Hsu *et al.*, 1971; Méhes, 1973).

G/G translocation in Down syndrome (Wilroy *et al.*, 1969) has occurred in two sibs. Both parents had normal karyotypes in their peripheral lymphocytes, but no other tissue was examined. Waxman and Arakaki (1966) also reported familial occurrence of G/G translocation. The mother had a normal karyotype in all of her peripheral lymphocytes examined and a 46,XX/46,XX,+F,-G karyotype in 8 out of 27 cells from her skin. She had one normal child and 3 children with clinical Down syndrome. Studies on 2 of the children with Down syndrome showed a G/G translocation. No banding study was performed.

We wish to report a family in which the mother is a low percentage mosaic for a t(21q21q). Blood, skin, ovary, and amniotic fluid were studied. Banding technique was successful in clearly identifying the marker as either an isochromosome for 21q or a t(21q21q) chromosome.

### Case report

A 24-year-old gravida II para I phenotypically normal woman was referred for amniocentesis in her 19th week of pregnancy because of a previous delivery of a male infant with Down syndrome. In her second pregnancy chromosomal analysis of cells derived from an amniotic fluid culture revealed a 46,XY,-G,+?(GqGq) karyotype subsequently shown to be 46,XY,-G,+t(21q21q) by trypsin-Giemsa staining technique. The patient, therefore, elected to undergo

Table

Patient	Tissue	Total no. of metaphases	No. of metaphases with marker	Cytogenetic diagnosis
Proband	Peripheral blood	30	0	46,XX
	Skin	50	4	46,XX/46,XX, -G,+?(GqGq)
	Right ovary	30	1	46,XX/46,XX -G,+?(GqGq)
Proband's husband	Peripheral blood	100	0	46,XY
Proband's first offspring	Peripheral blood	30	30	46,XY,-21,+t(21q21q)
	Amniotic fluid	50	50	46,XY,-G,+?(GqGq)
Proband's fetus	Cord blood	30	30	46,XY,-G,+?(GqGq)
	Heart blood	30	30	46,XY,-G,+?(GqGq)
	Skin	30	30	46,XY,-G,+?(GqGq)
	Frozen skin	(Banded identification)		46,XY,-21,+t(21q21q)

hysterotomy and tubal ligation. Karyotypes on the patient and her spouse's lymphocytes were normal. Skin and ovarian tissue cultures obtained at the time of surgery revealed a low percentage mosaicism for 46,XX,-G,t(GqGq). Cytogenetic studies of fetal skin confirmed the original diagnosis of 46,XY,-G,+t(GqGq).

CYTOGENETIC STUDIES

The results of cytogenetic studies are presented in the Table. Results of chromosome studies in cultures derived from fetal skin showed a missing G-sized chromosome and an extra F-sized chromosome in all cells examined. G- and R-banding techniques showed this extra chromosome to be the result of a

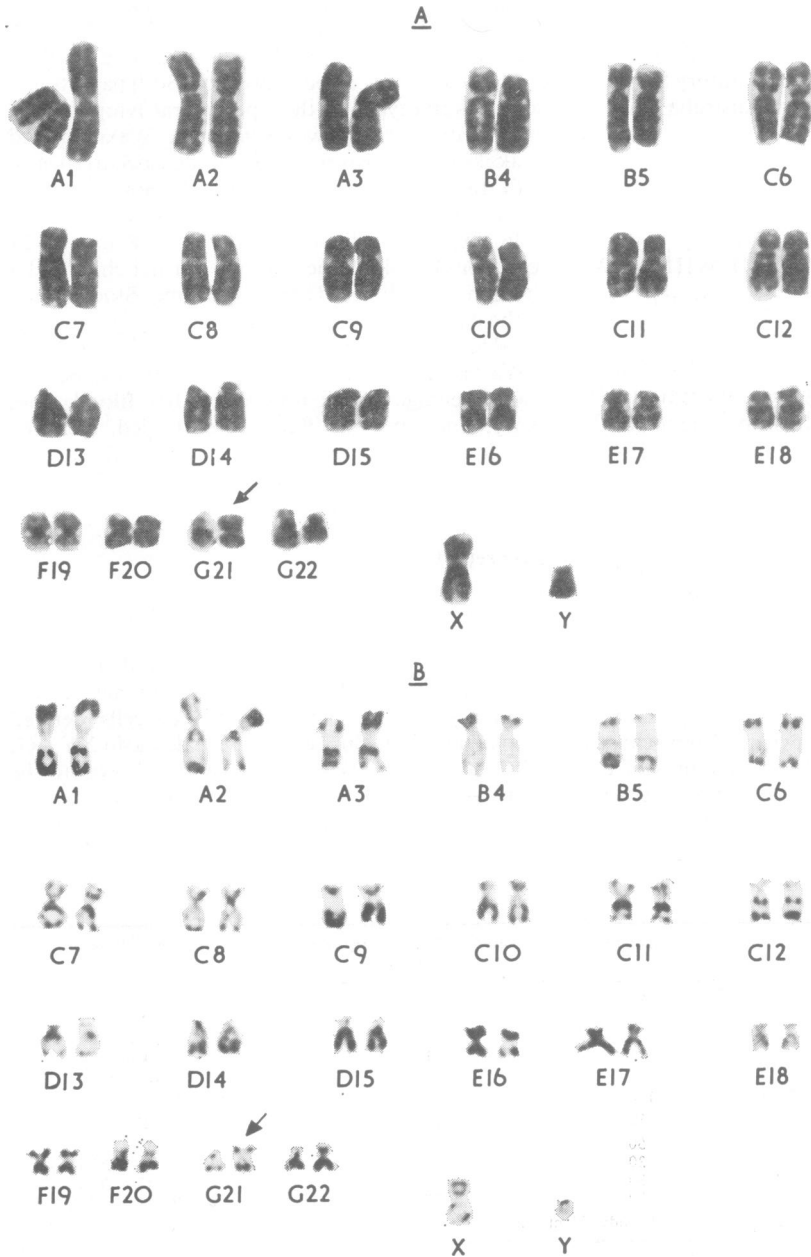


Fig. 1 (a) G-banded karyotype of the proband's fetus. (b) R-banded karyotype of the proband's fetus.

translocation between the long arms of two no. 21 chromosomes. The possibility of an isochromosome for the long arms of chromosome no. 21 cannot be excluded. A G-banded karyotype of the fetus is presented in Fig. 1a and an R-banded karyotype in Fig. 1b.

### Discussion

From results of chromosomal analyses derived from tissue culture of skin and ovary, the frequency of maternal cells carrying the translocation in these tissues is estimated to be less than 10%. Assuming the true frequency of mosaicism in the gonadal cells to be 10%, the probability of any oogonium bearing the translocation would be 0.10. The probability of an egg carrying the translocation at the completion of meiosis is 0.05. Therefore, the probability of having two randomly sampled gametes from the mother both carrying the translocation is very low  $0.05 \times 0.05 = 0.0025$ .

The finding of two affected sibs concordant for the karyotype in the present case is unexpected. Some of the possible hypotheses that can be postulated to explain the results are presented below.

First, we may not have determined the true frequency of mosaicism in the gonadal cells. The cells growing in culture were fibroblast-like cells and may or may not reflect the chromosomal constitution of the oogonial cells. The frequency of translocation in oogonial cells may be much higher than 10%. Second, even though the frequency of mosaicism in the oogonial cells may be the same as the frequency of mosaicism in the ovarian and skin cells *in vivo*, there may be a growth advantage of normal over abnormal cells *in vitro* so that the frequencies of 3 and 8%, respectively, for ovary and skin would be underestimated. Third, the possibility of meiotic drive, even though speculative, cannot be excluded. This can occur either through the preferential maturation of oogonia bearing the translocation abnormality or through the preferential inclusion of the translocation in the functional gametes, or both.

Finally, it should be mentioned that the above possibilities are by no means exhaustive, nor are they mutually exclusive events. One possibility that has not been mentioned is chance. The event of two Down offspring occurring in this family, given a low percentage mosaic parent, though rare, nevertheless, occurs with a finite probability of about 25 chances in 10 000.

In most medical centres when a child with Down syndrome is born to young parents who desire more children, amniocentesis is offered for fetal karyotyping in future pregnancies. Routine cytogenetic

studies on most of these parents are usually normal. However, in those families in which Down syndrome has recurred despite normal parental blood karyotypes, or in those cases in which amniocentesis does show recurrence, parental mosaicism becomes a likely possibility. We feel, on the basis of our experience, that chromosome studies of tissues in addition to blood should be performed in an effort to detect low percentage mosaicism.

We would like to thank Ms S. Collins and Ms B. Skavron for the typing of the manuscript, Dr S. Pueschel for valuable comments, and the following persons for their excellent technical assistance: Mr M. Sullivan, Mr D. Dunwoodie, Ms E. Hann, and Ms E. Airall.

H. F. L. MARK, T. MENDOZA, D. ABUELO,  
L. J. BEAUREGARD<sup>1</sup>, J. B. MAY AND  
P. H. LAMARCHE<sup>1</sup>

*Departments of Pathology and Pediatrics,  
Rhode Island Hospital, and Division of Biological  
and Medical Sciences, Brown University,  
Providence, RI, USA*

### References

- Aarskog, D. (1969). Down's syndrome transmitted through maternal mosaicism. *Acta Paediatrica Scandinavica*, **58**, 609-614.
- Dallaire, L., and Fraser, F. C. (1964). Two unusual cases of familial mongolism. *Canadian Journal of Genetics and Cytology*, **6**, 540-547.
- Hsu, L. Y. F., Gertner, M., Leiter, E., and Hirschhorn, K. (1971). Paternal trisomy 21 mosaicism and Down's syndrome. *American Journal of Human Genetics*, **23**, 592-601.
- Kaffe, S., Hsu, L. Y. F., and Hirschhorn, K. (1974). Trisomy 21 mosaicism in a woman with two children with trisomy 21 Down's syndrome. *Journal of Medical Genetics*, **11**, 378-379.
- Méhes, K. (1973). Paternal trisomy 21 mosaicism and Down's anomaly. *Humangenetik*, **17**, 297-300.
- Nuzzo, F., Stefanini, M., Simoni, G., Larizza, L., Mottura, A., Reali, E., and Franceschini, P. (1975). A family with three sibs carrying trisomy 21. *Annales de Génétique* **18**, 111-116.
- Smith, D. W., Therman, E. M., Patau, K. A., and Inhorn, S. L. (1962). Mosaicism in mother of two mongoloids. *American Journal of Diseases of Children*, **104**, 534.
- Waxman, S. H., and Arakaki, D. T. (1966). Familial mongolism by a G/G mosaic carrier. *Journal of Pediatrics* **69**, 274-278.
- Wilroy, R. S., Jr., Summit, R. L., and Atnip, R. L. (1969). *De novo* G/G translocation Down's syndrome in two siblings. *Lancet*, **2**, 438.

Requests for reprints to Dr Hon Fong Mark, Genetics Laboratory, APC Building Rm. 1131, Rhode Island Hospital, 593 Eddy Street, Providence, Rhode Island 02902, U.S.A.

<sup>1</sup>Present address: Genetics Laboratory, Eastern Maine Medical Center, Bangor, ME 04401.