

SHORT REPORT

Pineal cysts: an incidental MRI finding?

A Di Costanzo, G Tedeschi, F Di Salle, F Golia, R Morrone, V Bonavita

Abstract

The incidence of pineal cysts (PC) in "standard" MRI was reviewed. Seven cases of PC were found from 400 consecutive MRI examinations. PC did not produce clinically relevant symptoms in any of the patients. Our data, as well as those emerging from a critical review of the literature, suggest that PC are often asymptomatic and represent an incidental MRI finding.

(*J Neurol Neurosurg Psychiatry* 1993;56:207-208)

Pineal cysts (PC) are a common finding at necropsy.¹⁻³ Nevertheless, since the cyst fluid can have density similar to CSF, PC can escape detection on CT examination of the brain and be confused with the quadrigeminal cistern.⁴

Since the introduction of MRI, PC have been identified more frequently and considered as a normal variant without clinical relevance.⁴⁻⁶

Recently, however, Klein and Rubinstein⁷ in a clinicopathological study reported seven cases of symptomatic PC from 1500 consecutive examinations. We reviewed 400 consecutive brain MRIs and evaluated the clinical relevance of PC in the seven cases identified.

Material and methods

MRIs were carried out with a 0.5 T GE system. The images were obtained by T1 weighted sequences (Spin Echo 500/20, Fast Scan 500/90/15) in the sagittal plane: proton density and T2 weighted sequences (Spin Echo multi-

echo 2000/35-120) on the frontal plane; T1 weighted (inversion recovery 1350-1500/400/20) and T2 weighted (fast scan 500/23/28-30) in the axial plane. Section thickness was 5 mm with a 2 mm gap in the sagittal plane and 7 mm with a 3 mm gap in the frontal and axial planes.

The seven patients with MRI signs of PC had clinical examination.

Results

Clinical and MRI findings of the seven selected patients are reported in the table.

No patient had symptoms and/or signs of an expansive lesion in the pineal region. Patient 1, affected by retrobulbar neuritis, was studied by MRI three times over a period of 18 months, and no variation in dimension and signal characteristics of PC were found.

PC had a maximum diameter of 5-15 mm, and a thin wall (≤ 2 mm) with smooth margins. The cystic content appeared homogeneous and compared with CSF, isointense or slightly hyperintense in T1-weighted images and hyperintense in proton density and moderately T2-weighted images. PCs were best detected by sagittal T1 weighted images, which gave a good assessment of pineal morphology and regional anatomy (figure).

Discussion

In necropsy cases, mostly small cysts have been reported in 20-40% of normal pineal glands.^{2,3}

In none of our patients was the PC resected and histologically examined, nevertheless their

University of Naples,
Naples, Italy
Institute of
Neurological Sciences,
First School of
Medicine
A Di Costanzo
G Tedeschi
V Bonavita

Institute of
Radiological Sciences
Second School of
Medicine
F Di Salle
F Golia
R Morrone

Correspondence to:
Dr Tedeschi, Institute of
Neurological Sciences, First
School of Medicine,
University of Naples, Via
Pansini 5, 80131 Naples,
Italy.

Received 18 December 1991
and in revised form
17 February 1992.
Accepted 24 February 1992

Table Clinical characteristics and MRI findings in the seven patients with pineal cysts (PC)

Patient	Age (yrs)	Sex	Symptoms	Diagnosis	Maximum diameter of PC	Other MRI findings
1	20	F	Loss of visual acuity in left eye	Retrobulbar optic neuritis	10 mm	None
2	70	M	Mental deterioration, hemiparesis	Multi-infarct dementia	15 mm	Cortical cerebral atrophy, multiple white matter lesions
3	54	F	Headache, mood depression, anxiety	Tension-type headache	12 mm	None
4	25	M	Tonic clonic generalised seizures	Epilepsy	5 mm	None
5	9	F	Absence seizures	Epilepsy	13 mm	Frontal lobes atrophy, white matter alteration
6	16	F	Severe mental retardation	Neonatal encephalopathy	8 mm	Right frontal and parietal lobes atrophy, white matter alteration
7	29	F	Complex partial seizures	Epilepsy	9 mm	None

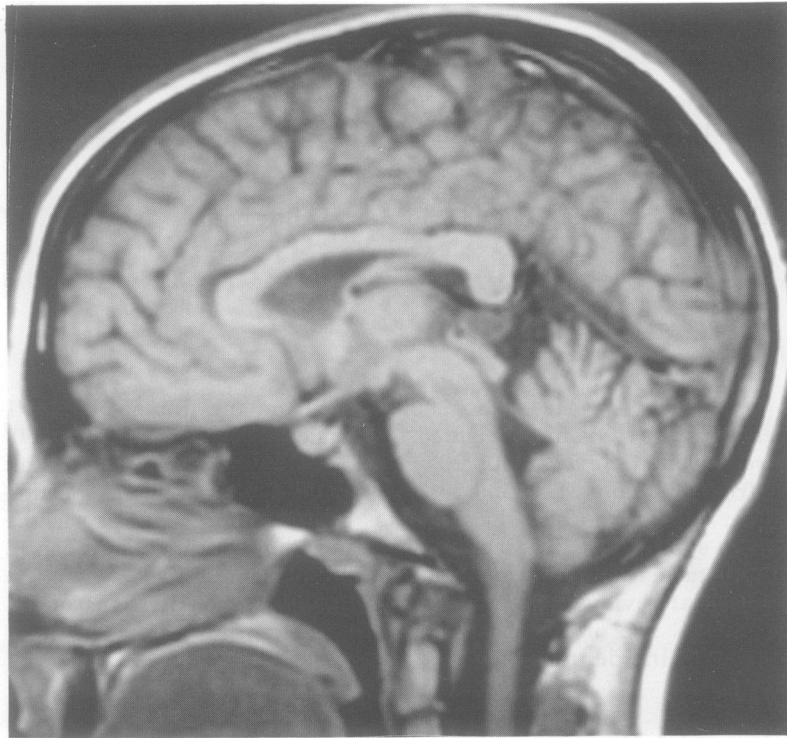


Figure Typical MRI appearance of a pineal cyst on T1-weighted sagittal images.

MRI characteristics overlapped with those described by other authors who carried out pathological examinations.⁵⁻⁷

The incidence of PCs found in our study (7 cases of 400 MRIs) agrees with the one reported by Lee *et al*⁵ in a retrospective study. In a prospective study, Mamourian and Towfighi⁴ reported a considerably high incidence (29 cases of 678 MRIs). Their specific imaging study of the pineal region, is likely to have been more sensitive. However, the incidence reported was lower than has been found at necropsy which means that most PCs are below the resolution of current routine imaging techniques.

In agreement with previous reports⁴⁻⁶, PCs observed in our seven patients were a purely incidental finding, without any clinical expres-

sion. Moreover, the absence of damage in the three successive MRI examinations of patient 1, suggests an unchanging condition. Lee *et al*⁵ repeated MRI examinations after twelve months in one patient and, as in our case, ruled out an evolving lesion damage.

From a review of the literature, it appears that cases of symptomatic PC have been over-emphasised. Of the seven cases reported by Klein and Rubinstein,⁷ only three showed symptoms and/or signs which could be related to an expansive process of the pineal region. In their two cases with headache, the lack of clinical details does not establish a clear relation between headache and PC. In their 12 year old patient, the acute onset of symptoms with headache, photophobia, asthenia, dysarthria, peripheral deficit of the right facial nerve, incoordination of the left hand and impaired walking, does not seem to be related to the PC found at CT (1 cm diameter). In their other patient with positional headache, "slight visual disturbances" and negative neurological examination, it is possible that the PC, in particular positions of the head, compressed the vein of Galen and/or the aqueduct of Sylvius, causing headache. Nevertheless, the patients with compression of the vein of Galen and quadrigeminal lamina, reported by Mamourian and Towfighi,⁴ were completely asymptomatic.

We conclude that PCs are almost always asymptomatic and represent an incidental MRI finding.

- 1 Arieti S. The pineal gland in old age. *J Neuropathol Exp Neurol* 1954;13:482-9.
- 2 Tapp E, Huxley M. The histological appearance of the human pineal gland from puberty to old age. *J Pathol* 1972; 108:137-144.
- 3 Hasegawa A, Ohtsubo K, Mori W. Pineal gland in old age; quantitative and qualitative morphological study of 168 human autopsy cases. *Brain Res* 1987;409:343-9.
- 4 Mamourian AC, Towfighi J. Pineal Cysts: Magnetic Resonance Imaging. *AJNR* 1986;71081-6.
- 5 Lee DH, Norman D, Newton TH. Magnetic resonance imaging of pineal cysts. *J Comput Assist Tomogr* 1987; 11:586-90.
- 6 Sandhu JS, McLaughlin JR, Gomez CR. Characteristics of incidental pineal cysts on Magnetic Resonance Imaging. *Neurosurgery* 1989;25:636-40.
- 7 Klein P, Rubinstein LJ. Benign symptomatic glial cysts of the pineal gland: a report of seven cases and review of the literature. *J Neurol Neurosurg Psychiatry* 1989;52:991-5.