

# Autosomal recessive inheritance of Nager acrofacial dysostosis

JUAN CHEMKE\*, BENJAMIN M MOGILNER†, ILAN BEN-ITZHAK‡, LORETA ZURKOWSKI§, AND DOV OPHIR||

From \*the Clinical Genetics Unit, †Neonatology Unit, ‡Department of Orthopedics, §Department of Radiology, and ||Department of Otolaryngology, Kaplan Hospital, Rehovot (affiliated to the Hebrew University-Hadassah Medical School), Israel.

**SUMMARY** Nager acrofacial dysostosis is a variant of mandibulofacial dysostosis with severe micrognathia, malar hypoplasia, and radial limb defects. Most cases are sporadic, but autosomal recessive inheritance has been suggested. A family is reported in which two sibs are affected by this syndrome, presenting further evidence for autosomal recessive inheritance. The recognition of this syndrome as a distinct entity has important implications. After the birth of a child with orofacial malformations suggestive of mandibulofacial dysostosis, an exact diagnosis is essential before genetic counselling can be offered.

The association of mandibulofacial dysostosis and radial limb defects is known as Nager acrofacial dysostosis.<sup>1-4</sup> Approximately 20 patients have been described and the clinical characteristics and differential diagnosis were recently reviewed by Halal *et al.*<sup>4</sup> Most cases are sporadic, but the recurrence of the syndrome in sibs and in offspring of consanguineous parents suggests autosomal recessive inheritance.<sup>1 5 6</sup> The possibility of genetic heterogeneity arises considering the phenotypic variability of reported patients.

This report concerns two sibs with typical Nager acrofacial dysostosis. This family presents further evidence for the autosomal recessive inheritance of this syndrome and emphasises the importance of recognising this syndrome as a distinct entity.

## Case reports

The sibs were born to healthy, unrelated parents of Ashkenazi-Jewish origin. There is one additional normal daughter. The family history is otherwise non-contributory.

### CASE 1

This male infant was born after an uneventful term pregnancy and delivery, with a birth weight of 3130 g. Severe maxillofacial malformations were diagnosed after birth, including marked micrognathia and malar hypoplasia, dysplastic ear lobes, atresia of

the external ear canals, antimongoloid slanting of the eyes without coloboma of the eyelids, a short soft palate with a hypoplastic epiglottis, and a small tongue. The neck was wide as if webbed. The nipples were widely spaced along the anterior axillary lines. Radial axis anomalies included mild radial deviation of the forearms, a rudimentary right thumb, and a hypoplastic left thumb. There was striking radial deviation of the index fingers and clinodactyly (figs 1 and 2). The infant died on the 19th day after aspiration. Chromosome analysis showed a normal 46,XY karyotype. Necropsy did not reveal any internal malformations.

### CASE 2

This was a female sib of patient 1, born after 41 weeks' gestation with a birth weight of 3800 g. Pregnancy and delivery were normal. At birth, a similar phenotype was evident. There was marked micrognathia, malar hypoplasia, small auricles with stenotic ear canals, antimongoloid slanting of the eyes, a high arched hard palate and a very short soft palate, and a small tongue (fig 3).

An ophthalmological examination was normal. The Denver Developmental Screening Tests showed normal psychomotor development for her age, except for auditory response. Auditory evoked response audiometry showed a maximum conductive hearing loss with thresholds of 50 and 60 dB in the right and left ears respectively. Bone conduction was normal (10 dB on both sides). Head circumference is progressing along the 50th centile for her age. The neck was short with redundant skin. The

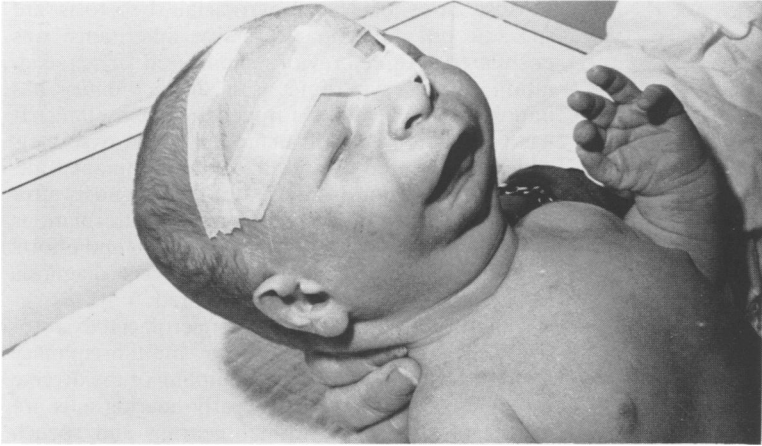

FIG 1 Facial appearance of case 1. Note micrognathia, malar hypoplasia, and dysplastic ear lobes.

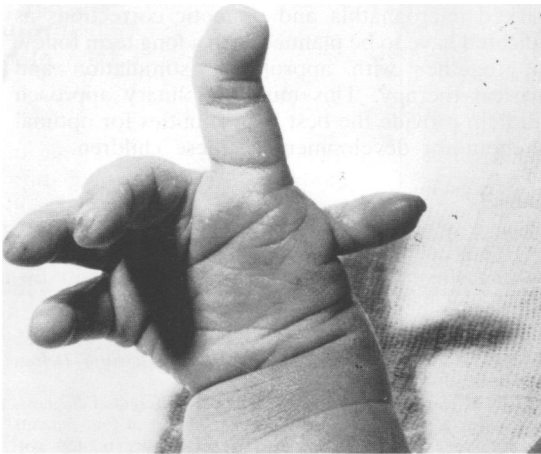

FIG 2 Right hand of case 1. Note hypoplastic thumb and deformity of index finger.

thumbs were hypoplastic and proximally inserted, and there was moderate radial deviation of the hands and clearly limited extension of the elbows. Both index fingers were radially deviated with clinodactyly. The heart was normal. There was mild overlapping of the toes. The rest of the physical examination was within normal limits.

Chromosome analysis revealed a normal female karyotype. Radiographical findings included a normal calvaria except for some Wormian bones. The face was small owing to marked micrognathia with a maxillary overbite (fig 4). The tongue was very small. The upper limbs showed shortening of both radial bones and hypoplasia of the radial heads, with contractures of the elbows. The middle phalanges of the second and fifth fingers were short. There was agenesis of the 12th ribs and an irregularity of the lower border of the left clavicle. Ultrasonography of the brain and kidneys was normal.

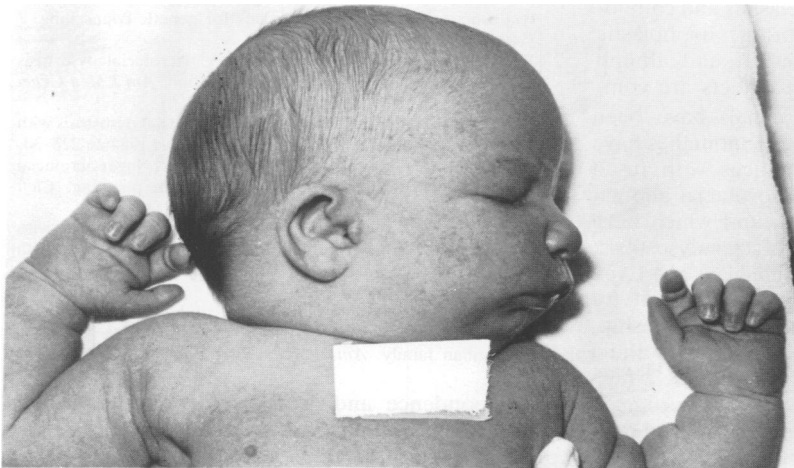

FIG 3 Facial appearance of case 2.

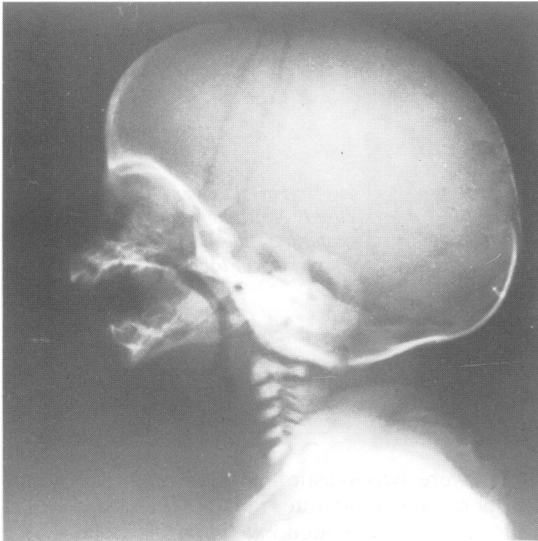


FIG 4 Radiograph of skull of case 2. Note marked micrognathia with maxillary overbite.

During the first few months after birth, there were some feeding problems because of sucking and swallowing difficulties and nasal regurgitation, which improved gradually.

### Discussion

Nager acrofacial dysostosis is a variant of mandibulofacial dysostosis, characterised mainly by severe micrognathia, malar hypoplasia, and radial limb defects.<sup>1-4</sup> Preaxial limb anomalies manifest as hypoplastic or absent thumbs and radial aplasia; radioulnar synostosis and other radial ray anomalies may also be found. Additional features which have been described include absent eyelashes and coloboma of the lower lids, a high nasal bridge, hypoplastic maxilla, genitourinary anomalies,<sup>4,7</sup> and thumb duplication.<sup>8</sup> Conductive hearing defects are common and stenotic external ear canals have been observed in all patients.<sup>9</sup> Middle ear anomalies have been described, such as absent incus with fused ossicles.<sup>2</sup> Several syndromes with orofacial anomalies with or without limb defects, and which have some resemblance to Nager acrofacial dysostosis, have recently been reviewed by Halal *et al.*<sup>4</sup> Even though there may be varying degrees of severity of the spectrum of the syndrome within a given sibship, Nager acrofacial dysostosis is a distinct entity and a well defined syndrome. Other syndromes which 'resemble' Nager acrofacial dysostosis may represent different types of craniofacial maldevelopment.<sup>7 10 11</sup>

Most cases of Nager acrofacial dysostosis are sporadic but autosomal recessive inheritance was postulated in three previous families.<sup>1 6 7</sup> The recognition of this syndrome as a distinct entity has important implications for genetic counselling. It has been confused with mandibulofacial dysostosis which is inherited as an autosomal dominant trait. Therefore, caution is advised in the diagnosis after the birth of a child with craniofacial malformations suggestive of mandibulofacial dysostosis, and efforts should be made to arrive at an exact diagnosis before genetic counselling is offered.

The overall prognosis of Nager acrofacial dysostosis is good, but obviously a multidisciplinary approach is necessary for the handling of the diverse problems of these children. Early hearing aids are important to ensure normal hearing and speech development. Surgical intervention to correct the marked micrognathia and cosmetic corrections as indicated have to be planned with a long term follow up, together with appropriate stimulation and physical therapy. This multidisciplinary approach will help provide the best opportunities for optimal psychomotor development of these children.

### References

- Burton BK, Nadler HL. Nager acrofacial dysostosis. *J Pediatr* 1977;**91**:84-6.
- Lowry RB. The Nager syndrome (acrofacial dysostosis). Evidence for autosomal dominant inheritance. *Birth Defects* 1977;**XII**(3C):195-220.
- Bowen P, Harley F. Mandibulofacial dysostosis with limb malformations (Nager's acrofacial dysostosis). *Birth Defects* 1974;**X**(5):109-15.
- Halal F, Herrmann J, Pallister PD, *et al.* Differential diagnosis of Nager acrofacial dysostosis syndrome: report of four patients with Nager syndrome and discussion of other related syndromes. *Am J Med Genet* 1983;**14**:209-24.
- Walker FA. Apparent autosomal recessive inheritance of the Treacher Collins syndrome. *Birth Defects* 1974;**X**(8):135-9.
- Fineman RM. Recurrence of the postaxial acrofacial dysostosis syndrome in a sibship: implications for genetic counselling. *J Pediatr* 1981;**98**:87-8.
- Kawira EL, Weaver DD, Bender HA. Acrofacial dysostosis with severe facial clefting and limb reduction. *Am J Med Genet* 1984;**17**:641-7.
- Giugliani R, Heller Pereira C. Nager's acrofacial dysostosis with thumb duplication: report of a case. *Clin Genet* 1984;**26**:228-30.
- Meyerson MD, Jensen KM, Meyers JM, *et al.* Nager acrofacial dysostosis: early intervention and long-term planning. *Cleft Palate J* 1977;**14**:35-40.
- Kelly TE, Cooke RJ, Kesler RW. Acrofacial dysostosis with growth and mental retardation in three males, one with simultaneous Hermansky-Pudlak syndrome. *Birth Defects* 1977;**XIII**(3B):45-52.
- Richieri-Costa A, Gallop TR, Colletto GMDD. Syndrome of acrofacial dysostosis, cleft lip/palate, and triphalangeal thumb in a Brazilian family. *Am J Med Genet* 1983;**14**:225-9.

Correspondence and requests for reprints to Dr Juan Chemke, Clinical Genetics Unit, Kaplan Hospital, Rehovot 76100, Israel.