

Interstitial deletion of distal 13q associated with Hirschsprung's disease

M A LAMONT*, M FITCHETT†, AND N R DENNIS*

From *the Department of Child Health, Southampton General Hospital, Southampton SO9 4XY; and †Wessex Regional Cytogenetics Unit, Salisbury Infirmary, Salisbury SP2 7SX.

SUMMARY Three cases of interstitial deletion of chromosome 13 involving the common segment 13q22.1→q32.1 are reported. In addition to the recognised clinical features of this deletion, two had Hirschsprung's disease.

Clinical features associated with deletions of the long arm of chromosome 13 distal to q22 have been described in several reports and are reviewed by Carnevale *et al.*¹ These dysmorphic features are sufficiently consistent in case reports to suggest a clinical syndrome for distal interstitial deletions of 13q21→q32.² Abnormalities of the gastrointestinal tract have been described in some cases but are not included in the syndrome. We report three patients with interstitial deletion of 13q, two of whom had Hirschsprung's disease, an association that has not, as far as we are aware, previously been described.

Case reports

CASE 1

Case 1, a female, was born at 38 weeks' gestation, the third child of healthy parents. At the time of her birth the father was 30 years old and the mother 32. The pregnancy was uneventful and delivery was by elective caesarian section. Her birth weight was 2032 g. There was mild birth asphyxia and early breathing difficulty. Meconium was passed normally, but constipation, requiring frequent enemas, was present from an early age.

A rectal biopsy done at 15 months suggested Hirschsprung's disease; a repeat biopsy at two years showed aganglionosis in the distal sigmoid colon. Bowel symptoms improved after resection of the affected segment.

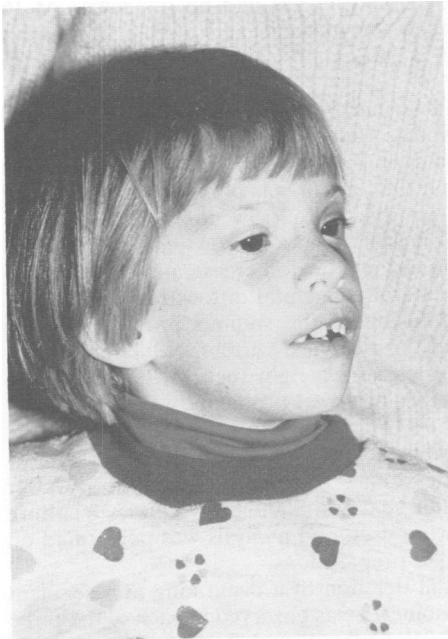When seen at seven years of age (fig 1a) the patient was very small. Her height (92 cm), weight (11.25 kg), and head circumference (46.5 cm) were all well below the 3rd centile. She was alert and responsive and could count up to five, but had

indistinct speech. She had a flat occiput, narrow forehead, ptosis, low set ears, high arched palate and protruding upper incisors, hyperextensible proximal interphalangeal joints, tapering terminal phalanges, bilateral simian creases, and a single transverse crease on the fourth and fifth fingers of the right hand, and on the fifth finger of the left hand (fig 1b). She had a waddling, somewhat unsteady gait with bilateral dislocation of the hips. The second, third, and fourth toes of both feet had partial syndactyly. There was a small umbilical hernia, but no abdominal distension. She had no control over micturition; a micturating cystogram was normal. Intravenous pyelography showed a bifid collecting system in both kidneys, but single ureters with no delay in drainage.

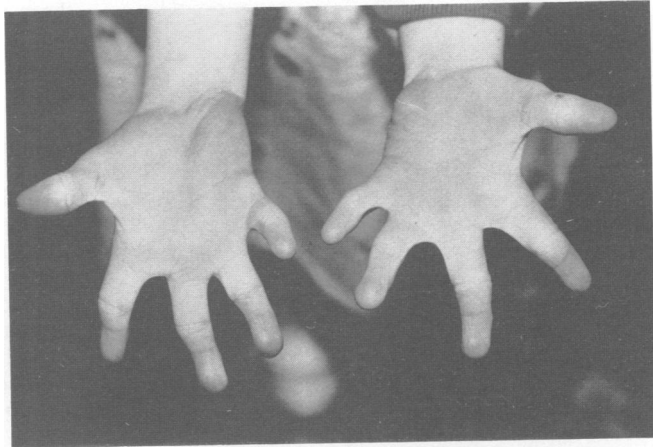
CASE 2

Case 2, a male, was born to healthy parents after 11 years of primary infertility. His mother was aged 33 years and his father 37 years when he was born, after an uneventful pregnancy, at 39 weeks' gestation. A caesarean section was performed because of transverse lie. His birth weight was 2400 g. He cried feebly at birth and was intubated for the first seven minutes. At 18 hours he was admitted to the special care nursery after a grey, possibly apnoeic, episode. Passage of meconium was delayed and Hirschsprung's disease and malrotation of the gut were diagnosed clinically when he was four days old. A biopsy of the distal sigmoid colon at 10 days showed aganglionosis of the submucosa. At correction of the malrotation and a colostomy, performed at two weeks of age, a universal mesentery was noted. After closure of the colostomy seven months later he has had continuing bowel problems with frequent loose stools, episodes of infection, and severe perianal excoriation.

Received for publication 28 March 1988.
Revised version accepted for publication 6 June 1988.

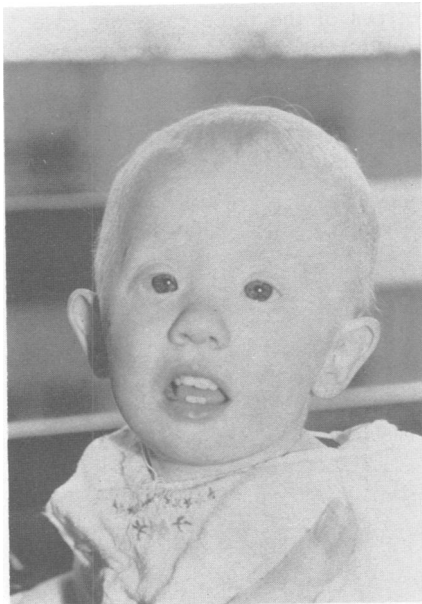


(a)

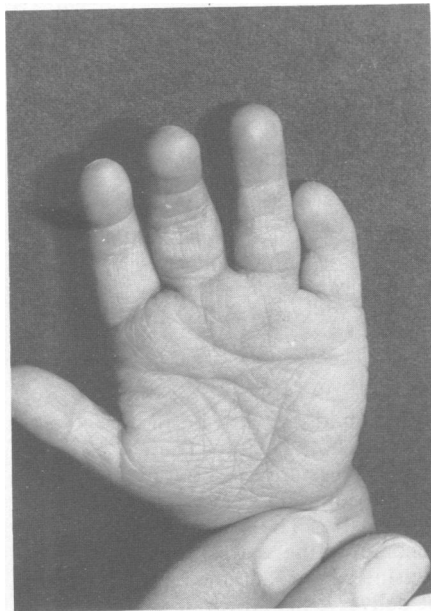


(b)

FIG 1(a,b) Case 1 at seven years.

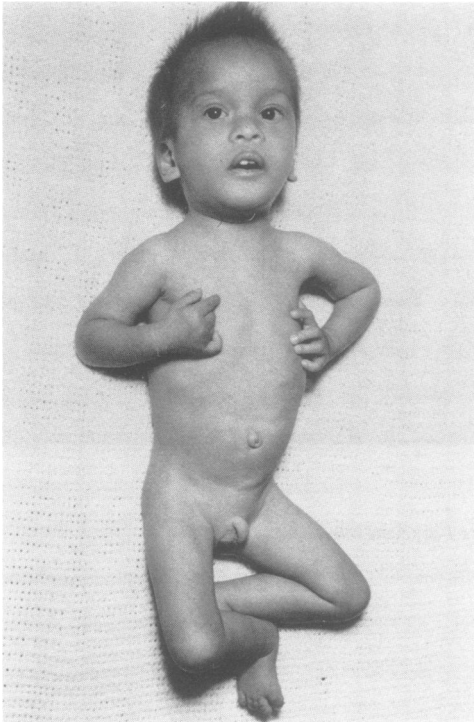


(c)



(d)

FIG 1(c,d) Case 2 at 34 months.



(e)

FIG 1(e) Case 3 at 16 months.

His progress has been slow, with gross failure to thrive and global retardation. At two years ten months the weight (7 kg), height (72 cm), and head circumference (44.5 cm) were all well below the 3rd centile. He could stand with a little support, but was markedly hypotonic. He had a bulging forehead (fig 1c), hypertelorism, a broad nasal bridge, low set, posteriorly rotated ears, and prominent upper incisors. His fifth fingers were short with clinodactyly (fig 1d). The right fifth toe was placed proximally and overlapped the fourth. Neither testis was palpable.

CASE 3

Case 3, a male, was the first child of a 28 year old mother and a 30 year old father, both healthy. There was slight bleeding at 12 weeks' gestation; labour at term was spontaneous and presentation vertex. The patient's birth weight was 2300 g. The liquor was thickly stained with meconium, there was some aspiration of meconium during labour, and the baby was pale and shocked at delivery; his Apgar score was 6 at five minutes and 6 at ten minutes. He was ventilated until day three. He had left sided jerking movements over the next two or three days, but

these settled, and he has had no fits since. At 16 months he was hypotonic and unable to support himself in a sitting position, but was starting to speak.

He had a narrow forehead (fig 1e), ridged metopic suture, telecanthus with epicanthic folds, ptosis, and depressed nasal bridge. His right ear was normal, but the left ear was posteriorly rotated and low set. He had a narrow upper dental arch, prominent incisors, and a narrow palate. Both fifth fingers had a single flexion crease and clinodactyly. He had bilateral congenital dislocation of the hips, congenital fusion of the spinous processes of the second and third cervical vertebrae, bilateral undescended testes, and a right inguinal hernia. There was no history of bowel problems.

CYTOGENETICS

Cytogenetic studies were carried out shortly after birth in all three cases. Standard lymphocyte culture methods were used and analysis was performed on GTL banded preparations.³

Interstitial deletion of a distal long arm segment of chromosome 13 was observed in each of the three cases (fig 2). Cases 1 and 3 showed apparently identical deletions (13q22.1→q32.1). In case 2 the region involved extended beyond these limits both proximally and distally (13q21.2→q32.3) (fig 3). The parents of these three children had normal karyotypes.

The karyotypes of the three cases are case 1: 46,XX,del(13)(pter→q22.1::q32.1→qter), case 2:

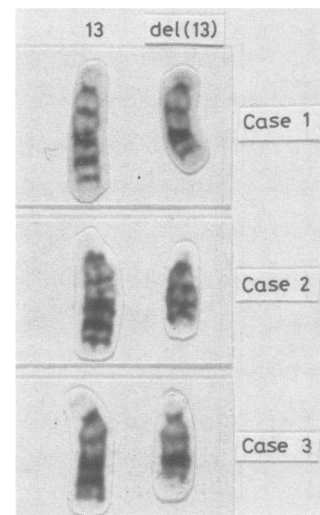


FIG 2 GTL banded partial karyotypes showing interstitial deletion of chromosome 13 in the three patients.




FIG 3 Idiogram of chromosome 13 showing the extent of the deleted segment in the three patients.

46,XY,del(13)(pter→q21.2::q32.3→qter), and case 3: 46,XY,del(13)(pter→q22.1::q32.1→qter).

Discussion

All three patients showed a deletion of a common chromosome segment 13q22.1→q32.1; this deletion extended both proximally and distally in one patient, to 13q21.2 and 13q32.3 respectively.

All three patients showed intrauterine and post-natal growth retardation and were similar in appearance with prominent upper incisors, low set ears, and minor abnormalities of their hands and feet, all features accepted as part of the 13q- syndrome.¹ They all had fairly severe psychomotor retardation, but perinatal asphyxia, which occurred in all three, could have contributed to this. While all cases of 13q31 deletion reviewed by Carnevale *et al*¹ had psychomotor retardation, a six year old girl with the same deletion⁴ is reported as having near normal psychomotor development.

Anomalies of the gastrointestinal tract have not featured prominently in 13q deletions. Anterior displacement of the anus was noted in two patients with ring chromosome 13 with breakpoint at q32,⁵ and in another child with 13q21→q31 deletion.⁶ Internal anomalies of the bowel or mesentery have been reported with other 13q deletions (table).

TABLE Anomalies of the gastrointestinal tract in 13q deletions.

Reference	Deletion	Gastrointestinal anomaly
7	del(13)(q14→q21)	Jejunal atresia
8	del(13)(q14→q31)	Agensis of mesentery of ascending and descending colon.
9	del(13)(q31→qter)	Hypoplastic gall bladder Unattached mesentery. Meckel's diverticulum
10	del(13)(q14)	Absent jejunum, ileum, mesentery
Present cases	del(13)(q22.1→q32.1) del(13)(q21.2→q32.3)	Hirschsprung's disease Hirschsprung's disease. Universal mesentery

Deletions involving 13q14 have been associated with agensis or atresia of the small or large bowel and of the mesentery.^{7 8 10} An unattached mesentery was present in one child with a distal deletion 13q31→q33.⁹

Of the three children reported here, one had no bowel problems and two had short segment Hirschsprung's disease with aganglionosis confirmed histologically; one of these children (case 2) had an anomaly of the mesentery.

Hirschsprung's disease, with a population incidence of 1 in 5000 has been noted in association with Down's syndrome, where the incidence has been estimated at 2%, with other chromosome aneuploidies, and in association with various Mendelian syndromes, such as achondroplasia and Waardenburg's syndrome.^{11 12} From these diverse associations, it seems probable that there are several genetic loci involved in innervation of the large bowel. The occurrence of bowel aganglionosis in two children with deletions involving bands 13q22.1→q32.1 suggests that one locus may be situated in this region.

We are grateful to the families for their willing cooperation. We thank Mr J D Atwell, Mr N V Freeman, and Dr D Hide for permission to report patients under their care.

References

- 1 Carnevale A, Frias S, Alcantar R. Interstitial deletion of long arm of chromosome 13. *Ann Genet (Paris)* 1984;27:49-52.
- 2 Niebuhr E. Partial trisomies and deletions of chromosome 13. In: Yunis JJ, ed. *New chromosomal syndromes*. New York: Academic Press, 1977:273-99.
- 3 Seabright M. A rapid banding technique for human chromosomes. *Lancet* 1971;ii:971-2.
- 4 Brondum Nielsen K, Bjorner H, Mikkelsen M. Clinical and psychological follow-up of two children with the 13q- karyotype. *Clin Genet* 1981;20:380A.
- 5 Martin NJ, Harvey PJ, Pearn JH. The ring chromosome 13 syndrome. *Hum Genet* 1982;61:18-23.

- ⁶ Serena Lungarotti M, Calabro A, Marinotti G, *et al.* Interstitial deletion 13q syndromes: a report on two unrelated patients. *Hum Genet* 1979;**52**:269–74.
- ⁷ Yunis JJ, Ramsay N. Retinoblastoma and subband deletion of chromosome 13. *Am J Dis Child* 1978;**132**:161–3.
- ⁸ Yunis E, Zuniga R, Ramirez E. Retinoblastoma, gross internal malformations and deletion 13q (14→31). *Hum Genet* 1981;**56**:283–6.
- ⁹ Carmichael A, Addy DP, Shortland-Webb WR, Cameron AH, Davis ICS. 13q– syndrome. Family study. *Arch Dis Child* 1977;**52**:972–4.
- ¹⁰ Nishikawa A, Mitimori T, Matsura A, Imore A, Mori H, Takahashi M. The 13q– syndrome with extensive intestinal atresia. *Acta Paediatr Scand* 1985;**74**:305–8.
- ¹¹ Passarge E. Genetic heterogeneity and recurrence risk of congenital aganglionosis. *Birth Defects* 1972;**VIII**(2):63–7.
- ¹² Branski D, Dennis NR, Neale JM, Brookes LJ. Hirschsprung's disease and Waardenburg's syndrome. *Pediatrics* 1979;**63**:803–5.

Correspondence and requests for reprints to Dr M A Lamont, Department of Child Health, Southampton General Hospital, Southampton SO9 4XY.