

dermatoglyphics, Mrs H Lawton for typing the manuscript, and the Audiovisual Unit of the Wellington Clinical School for help with the illustrations.

#### References

- <sup>1</sup> Schauman B, Alter M. *Dermatoglyphics in medical disorders*. New York: Springer-Verlag, 1976:169-72.
- <sup>2</sup> Rodewald A, Zankl H, Wischerath H, Borkowsky-Fehr B. Dermatoglyphic patterns in trisomy 8 syndrome. *Clin Genet* 1977;12:28-38.
- <sup>3</sup> Sanchez O, Yunis JJ. Partial trisomy 8(8q24) and the trisomy 8 syndrome. *Humangenetik* 1974;23:297-303.
- <sup>4</sup> Soudek D, Hunter P, O'Shaughnessy S, Simpson NE, Soudek V. Familial translocation t(8;14) with a case of tertiary trisomy, +14q. In: Summitt RL, Bergsma D, eds. *Sex differentiation and chromosome abnormalities*. New York: Alan R Liss. For the National Foundation—March of Dimes. Birth Defects 1978; XIV(6C):309-15.
- <sup>5</sup> Gödde-Salz E, Oesinghaus S, Grote W. Meiotic segregation in familial reciprocal translocation t(8q;2q). *Am J Med Genet* 1982;11:241-7.
- <sup>6</sup> Barnes ICS, Kumar D, Bell RJM. A child with a recombinant of chromosome 8 inherited from her carrier mother. *J Med Genet* 1985;22:67-70.
- <sup>7</sup> Schinzel A. Partial trisomy 8q in half-sisters with distinct dysmorphic patterns not similar to the trisomy 8 mosaicism syndrome. *Hum Genet* 1977;37:17-26.
- <sup>8</sup> Walker AP, Bocian M. Partial duplication 8q12-q21.2 in two sibs with maternally derived insertional and reciprocal translocations. Case reports and review of partial duplications of chromosome 8. *Am J Med Genet* 1987;27:3-22.

Correspondence and requests for reprints to Dr D R Romain, Cytogenetics Laboratory, Laboratory Services, Wellington Hospital, Wellington, New Zealand.

## Is there an autosomal recessive form of the split hand and split foot malformation?

JOEL ZLOTOGORA\* AND NAFEZ NUBANI†

From \*the Department of Human Genetics, Hadassah Medical Centre, Hebrew University; and †Sheikh Jarrah Clinic, Kupat Holim-Workers' Sick Fund of the General Federation of Labour in Israel, Jerusalem, Israel.

**SUMMARY** A family is described in which four subjects in two sibships had typical split hand/foot malformation. The possibility of the existence of a rare autosomal recessive form of the malformation is discussed, as well as a two locus model. In the two locus model the dominant mutation leading to the split hand/foot malformation is controlled by a gene at another locus. A dominant mutation at the controlling locus leads to non-penetrance of the split hand/foot mutation.

Isolated split hand/split foot malformation is well known but rare. Many cases are sporadic, presumed to be new dominant mutations, since in most families with more than one affected subject autosomal dominant inheritance can be shown.<sup>1</sup> We present a family with four patients in two related sibships affected with the split hand/foot malformation.

#### Case report

The family (fig 1) originates from a small, very

inbred Muslim community. The parents of the proband are double first cousins and are healthy with no malformations. The maternal grandfather of the proband (III.4) as well as two of his sisters (III.2 and III.11) were also affected.

The proband was born after a pregnancy in which the mother suffered from depression and was treated with Halidol (haloperidol), Artane (trihexyphenidyl), and Largactil (chlorpromazine). The delivery was normal and the girl was normally developed for her age. At examination in our clinic at the age of 10 months, the only malformations were a left typical split hand and bilateral split foot (fig 2). There was complete syndactyly of the first and second fingers, the third and fourth fingers were fused into one finger with two nails, and the fifth finger was normal (fig 2a). In both feet (fig 2b, c), the second toe was absent and syndactyly of the third and fourth toes was noted. In the grandfather (III.4), there were only three fingers, the first, fourth, and fifth, on both hands. In III.2, there was split hand only on the right with similar findings as in the hand of the proband. Both hands were normal in III.11. In all these three affected subjects, bilateral split foot was present with a malformation similar to that observed in the proband.

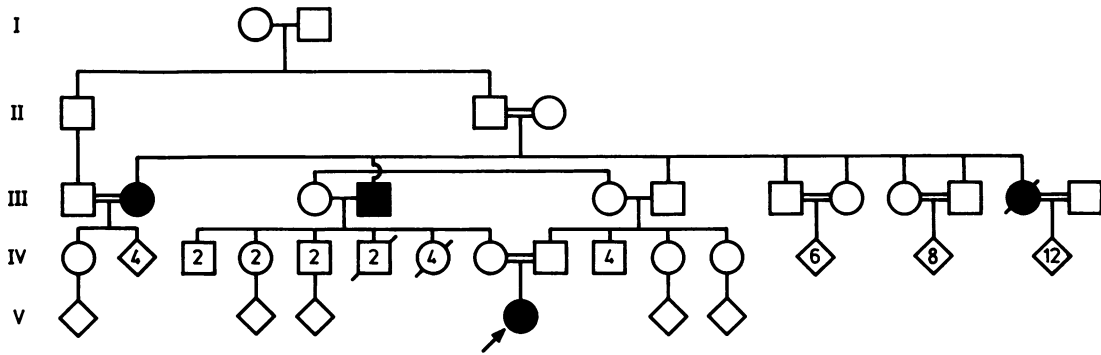


FIG 1 Pedigree of the family.

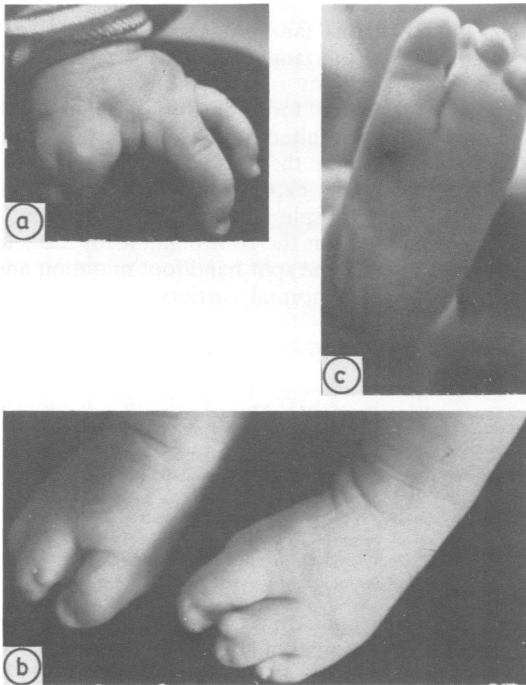


FIG 2 (a) Left hand; (b) feet; and (c) left foot of the proband.

## Discussion

Split hand is frequently associated with split foot and is relatively rare. Many cases are sporadic, but in most familial cases of split hand autosomal dominant inheritance can be shown. In many of the

families in which more than one affected child was born to normal parents, it was possible that the split hand/foot malformation was also dominant, and the explanation was the existence of a germinal mutation in one of the parents.<sup>1</sup> We were able to find reports of only two pedigrees in which the split hand/foot malformation seems to be inherited as an autosomal recessive trait. Verma *et al*<sup>2</sup> reported a family in which atypical, very unusual split hand and split foot deformity occurred in four children from two related sibships, each resulting from a marriage between first cousins. In this family, the only child who was examined presented also with fused radius and ulna, and it is possible that this represents a distinct syndrome. Freire-Maia<sup>3</sup> reported a family in which five children were born with ectrodactyly in two related sibships; therefore the malformation appears to show autosomal recessive inheritance. In the family presented here, the malformation was present in four subjects in two related sibships. In favour of autosomal recessive inheritance are the observations that both males and females were affected, all the affected subjects were born to normal parents, and all the 30 children born to affected parents were normal. Therefore, this family, together with the family reported by Freire-Maia,<sup>3</sup> suggest the existence of an autosomal recessive form of the split hand/foot malformation which clinically cannot be distinguished from the autosomal dominant form of the malformation.

Another possibility to explain the inheritance of the malformation in these families is that the split hand/foot malformation is always the result of a dominant mutation, but that there is another locus which controls its expression. In the mouse, Chay<sup>4</sup> described a dominant mutation which led to dactyl-aplasia, a condition characterised by the absence of digits on each foot, typically the three middle digits,

giving the appearance of a 'lobster claw'. Chay was able to show that the manifestations of the mutant gene are controlled by another locus in which there are two alleles, one dominant, inhibiting dactylaplasia gene expression, and the other recessive, allowing its expression. If this model is applied to humans, then the dominant mutation leading to split hand/foot malformation could be controlled by another locus. If, in the general population, only the recessive allele at the controlling locus is present, then the dominant mutation for split hand/foot will always be expressed. A rare dominant mutation at the controlling locus will lead to occasional asymptomatic carriers of the split hand/foot mutation who may then transmit the malformation to more than one of their children. Since these affected children have lost the dominant mutation at the controlling locus, they will transmit the malformation to their own children as a typical dominant trait. This two

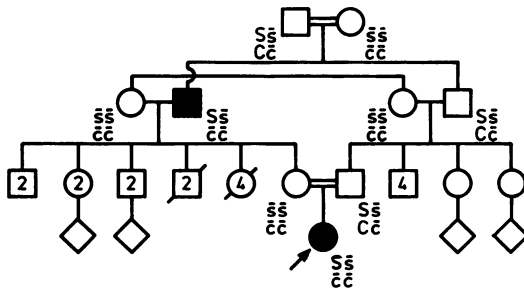


FIG 3 The two locus model. A part of the pedigree (fig 1) is presented. At the locus *s* a dominant mutation *S* leads to split hand/foot malformation if at the controlling locus the subject is homozygous *cc*. The split hand/foot malformation is present in subjects *Ss, cc*. In subjects *Ss, Cc* the split hand/foot mutation is non-penetrant and they are asymptomatic carriers. Subjects with the malformation are *cc* and therefore have lost the mutation at the controlling locus *C*; in their children the mutation *S* is present and will always be penetrant. The reappearance of the malformation in the girl in the last generation is the result of her parents being related. While her mother must be *ss, cc* since she is healthy and she was born to an affected subject, her father is *Ss, Cc*, a healthy carrier of the split hand/foot malformation.

locus model may therefore be an alternative explanation to the germinal mutations proposed to explain the observation of unaffected parents who have more than one child with the dominant mutation leading to split hand/foot malformation. In consanguineous families, the appearance of the dominant mutation at the controlling locus may lead to pseudorecessive inheritance of the split hand/foot malformation, as seen in the family reported by Freire-Maia<sup>3</sup> or the family presented here. The interaction and inheritance of the two loci in the family reported here are shown in fig 3. The observation that all 30 children of affected subjects are healthy may be explained in two of them by the fact that the spouse is from the same family and therefore may be heterozygous, or even homozygous, for the mutation at the controlling locus and homozygous for the normal allele at the main locus. However, this observation is not in favour of the two locus model in this family.

In conclusion, the family reported here seems to confirm the possibility raised by Freire-Maia<sup>3</sup> that there is a recessive form of the split hand/foot malformation. An alternative possibility is presented, namely that there is an additional locus which controls the expression of the dominant mutation leading to split hand/foot malformation; a dominant mutation at the controlling locus leads to non-penetrance of the split hand/foot mutation and the appearance of normal carriers.

#### References

- 1 Temtamy S, McKusick VA. The genetics of hand malformations. *Birth Defects* 1969;14(3):53-71.
- 2 Verma IC, Joseph R, Bhargava S, Metha S. Split hand and split foot deformity inherited as an autosomal recessive trait. *Clin Genet* 1976;9:8-14.
- 3 Freire-Maia N. A recessive form of ectrodactyly and its implications in genetic counselling. *J Hered* 1971;62:53.
- 4 Chay CK. Dactylaplasia in mice. A two-locus model for developmental anomalies. *J Hered* 1981;72:234-7.

Correspondence and requests for reprints to Dr Joel Zlotogora, Department of Human Genetics, Hadassah Medical Centre, PO Box 12 000, il 91120 Jerusalem, Israel.