

# Case reports

Journal of Medical Genetics 1989, 26, 642-663

## Familial mental retardation associated with balanced chromosome rearrangement rcp t(8;11)(q24.3;p15.1)

HITOMI SATO\*, KIYOSHI TAKAYA†, SHIZUHIRO NIHIRA‡, AND HIROKO FUJITA‡

\*Department of Education for Handicapped Children, Shiga University; †Biwako Institute for Severely Handicapped Children; and ‡Department of Child Health, Faculty of Science of Living, Osaka City University, Japan.

**SUMMARY** We report three sisters and their father with a reciprocal balanced translocation, rcp t(8;11)(q24.3;p15.1) and the same abnormal phenotypes, including mental retardation, growth disturbance, and amblyopia. It is considered that the abnormal phenotypes in our four cases might result from a tiny deletion or gene mutation at the breakpoints in 8q or 11p or both. Our cases showed no resemblance, apart from mental retardation, to Langer-Giedion syndrome, which is caused by the deletion of 8q23.3 and 8q24. Furthermore, our patients did not have the cardinal features of Beckwith-Wiedemann syndrome or WAGR which are caused by deletion of 11p. It is suggested that the amblyopia in our four cases might have resulted from the breakpoints at 11p15.1.

The incidence of balanced translocation, either reciprocal or Robertsonian, is about one in 500 newborn infants.<sup>1</sup> Generally such translocations do not cause an abnormal phenotype. However, they have been reported in association with mental retardation, low fertility, and congenital malformations.<sup>2,3</sup> In most cases, the translocation is de novo, but in some cases it is familial with one of the parents being clinically normal. As indicated by Funderburk *et al*<sup>2</sup> and Aymé *et al*,<sup>3</sup> it is important to know the incidence of cases with apparently balanced familial translocations and abnormal phenotypes and the phenotypic-karyotypic correlation. In this paper, we report three sisters and their father with

apparently balanced reciprocal translocations who were all detected because of abnormal phenotypes.

### Case reports

#### CASE 1 (IV.2, FIG 1)

The six year old proband was the second child. At her birth the father and mother were 32 and 25 years old, and were healthy and non-consanguineous. At 41 weeks of gestation, her birth weight was 2890 g and length was 49.0 cm. At the age of two years, she was referred for chromosomal analysis because of psychomotor and growth retardation (fig 2). At the age of five years, her DQ was 46 and her poor visual acuity was noticed, but facial malformations were not noticed.

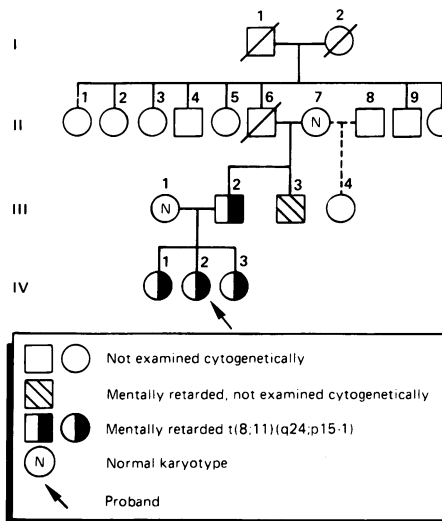


FIG 1 Family pedigree.

Received for publication 10 February 1989.

Revised version accepted for publication 13 April 1989.

Chromosomal preparations from peripheral blood lymphocyte cultures showed an apparently balanced translocation between chromosomes 8 and 11 with breakpoints at 8q24.3 and 11p15.1. Her karyotype was interpreted as 46,XX,t(8;11)(q24.3;p15.1) (fig 3). Her parents, grandmother, and two sisters were also examined cytogenetically. The karyotypes of her father and two sisters were identical to that of the proband. The karyotypes of the mother and grandmother were normal. The pedigree is shown in fig 1.

CASES 2 AND 3 (IV.1 AND IV.3)

Case 2 was the proband's eight year old older sister and case 3 was her three year old younger sister. They were born uneventfully at term weighing 2950 g and 3050 g respectively. Their gain in weight and height was as poor as that of the proband. They also had psychomotor retardation, the older sister's DQ being 88 and the younger sister's 60. They also had poor visual acuity.

CASE 4 (III.2)

This mentally retarded, 39 year old man is the father of the three sisters. He has poor visual acuity and colour blindness, but no growth retardation or history of severe illness. He has one brother who is also mildly mentally retarded and has colour blind-

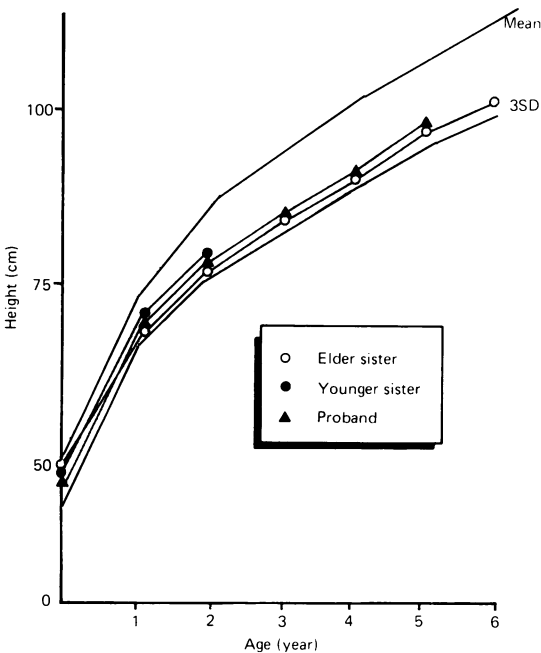


FIG 2 Growth curves of the three sisters.

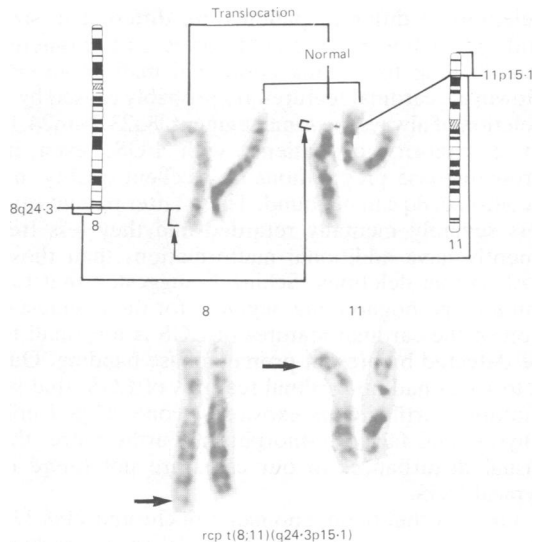


FIG 3 Partial karyotype showing *rcp t(8;11)(q24.3;p15.1)*.

ness and amblyopia (III.3). Chromosome analysis was unable to be performed.

Discussion

To explain the relationship between balanced chromosomal rearrangements and phenotypic anomalies, several hypotheses have been suggested by Jacobs<sup>4</sup>: (1) a gene mutation at the breakpoint; (2) a submicroscopic recombination aneusomy; or (3) a position effect.

Recently, using high resolution prometaphase chromosome banding, tiny deletions or duplications have been detected in some well established malformation syndromes: an interstitial deletion in 15q11/12 in the majority of patients with Prader-Willi syndrome, an interstitial deletion of 8q23.3/24.1 in some patients with Langer-Giedion syndrome (LGS), and an interstitial deletion of 11p13 in virtually all patients with Wilms' tumour-aniridia-gonadoblastoma-retardation syndrome (WAGR).<sup>5</sup> In our four cases, it is suggested that the abnormal phenotypes might have resulted from a tiny deletion or gene mutation at the breakpoints of chromosome 8q or 11p or both. Patients with typical LGS have coarse hair, bulbous nasal tip, mental retardation, multiple cartilaginous exostoses, protruding ears, postnatal growth retardation, microcephaly, and cone shaped phalangeal epiphyses. It is known that the clinical features vary depending on the size of the deletion of chromosome 8. It is likely that the

deletions in different patients are different in size and extent towards the centromere and telomere, thus leading to varying additional malformations. However, cardinal features are probably caused by a deletion of always the same segment, 8q23.2→q24.1. In a minority of patients with LGS, even in prometaphase preparations of excellent quality, no deletion in 8q can be found. These latter patients are less severely mentally retarded and they less frequently have additional malformations than those with visible deletions. Schinzel<sup>5</sup> suggested that the minimal pathognomonic segment for the manifestation of the cardinal features of LGS is too small to be detected by present prometaphase banding. Our four cases had no cardinal features of LGS, that is, multiple cartilaginous exostoses, cone shaped epiphyses, and facial dysmorphism. Furthermore, the visual disturbances in our cases are not found in typical LGS.

On the other hand, anomalies of chromosome 11p have been reported in Beckwith-Wiedemann syndrome (BWS) and in WAGR. Duplication of 11p has been found in over a dozen patients with cardinal features of BWS and mental retardation. Schmutz<sup>6</sup> reported a case of deletion of chromosome 11p13 with BWS and macroglossia, umbilical hernia, high birth weight, facial naevus flammeus, and mental retardation. The clinical features of WAGR are Wilms' tumour, aniridia, mental retardation, and gonadoblastoma. Our four cases showed no resemblance to BWS or WAGR except for mental retardation. From a review of previously reported patients with del(11)(p15.1p13) or del(11)(p15.1p12),

Gilgenkrantz *et al*<sup>7</sup> confirmed many ophthalmic symptoms, such as glaucoma, cataracts, nystagmus, ptosis, and exotropia, in addition to aniridia. Furthermore, most of these patients had growth deficiency, mental retardation, abnormal genitalia, and nephroblastoma. From these findings, it is likely that a break in band 11p15.1 caused growth and mental retardation and amblyopia in our four cases.

#### References

- Evans JA, Canning A, Hunter AGW, *et al*. A cytogenetic survey of 14,069 newborn infants: an analysis of the significance and cytogenetic behavior of the Robertsonian and reciprocal translocations. *Cytogenet Cell Genet* 1978;20:96-123.
- Funderburk SJ, Spence MA, Sparkes RS. Mental retardation associated with 'balanced' chromosome rearrangements. *Am J Hum Genet* 1977;29:136-41.
- Aymé S, Mattei MG, Mattei JF, Giraud F. Abnormal childhood phenotypes associated with the same balanced chromosome rearrangements as in the parents. *Hum Genet* 1979;48:7-12.
- Jacobs PA. Correlation between euploid structural chromosome rearrangements and mental subnormality in humans. *Nature* 1974;249:164-5.
- Schinzel A. Microdeletion syndromes, balanced translocations, and gene mapping. *J Med Genet* 1988;25:454-63.
- Schmutz S. Deletion of chromosome 11(p11p13) in a patient with Beckwith-Wiedemann syndrome. *Clin Genet* 1986;30:154-6.
- Gilgenkrantz S, Vigneron C, Gregoire MJ, Pernot C, Raspiller A. Association of del(11)(p15.1p12), aniridia, catalase deficiency, and cardiomyopathy. *Am J Med Genet* 1982;13:39-49.

Correspondence to Dr H Sato, Department of Education for Handicapped Children, Shiga University, 2-5-1 Hiratsu, Otsu, Shiga, Japan.

## A new interstitial deletion of 4q (q21.1::q22.1)

KERRY FAGAN\* AND ANDREW GILL†

\*Cytogenetics Laboratory and †Department of Neonatology, Mater Hospital, Waratah, NSW 2298, Australia.

**SUMMARY** A unique case of de novo interstitial deletion of chromosome 4 is described involving loss of band q21. The male newborn had multiple abnormalities including frontal bossing, prominent occiput, low set ears, micrognathia, short sternum, short, broad hands and feet, agenesis of the corpus callosum, and cardiac defects. The phenotypic abnormalities are compared with other reported cases of deletion 4q involving adjacent regions.

Interstitial deletions of the long arm of chromosome 4 are said to be relatively rare; in fact, 16 cases have been published to date with most of these reports having different breakpoints. So far, attempts at deletion mapping in this portion of the human genome have only indicated a tentative assignment of the piebald trait<sup>1</sup> gene to band 4q12 and the locus of the group component (Gc) system<sup>2</sup> (vitamin D binding protein) to 4q11→q13.

#### Case report

The proband was born at term after an uneventful pregnancy to unrelated parents. The G1P0 mother